

# Validation of Definitions for Structural Lesions Detected by Magnetic Resonance Imaging in the Spine of Patients with Spondyloarthritis

PRAVEENA CHIOWCHANWISAWAKIT, MIKKEL ØSTERGAARD, SUSANNE J. PEDERSEN, ROBERT G.W. LAMBERT, BARBARA CONNER-SPADY, and WALTER P. MAKSYMOWYCH

**ABSTRACT.** *Objective.* Assessment of structural features of spondyloarthritis (SpA) on magnetic resonance imaging (MRI) has proven to be no more reliable than plain radiography, which may reflect a lack of standardization and application of rigorous definitions. The Canada-Denmark MRI Working Group has developed a comprehensive list of definitions for the structural MRI changes in the spine of patients with SpA. We conducted a systematic evaluation of the frequency and reliability of detection of structural lesions.

*Methods.* Chronic lesions were independently recorded dichotomously (present/absent) from lower C2 to the upper sacrum on T1-weighted MRI scans of 20 patients with ankylosing spondylitis by 4 readers. Prior to the exercise, a series of reference images was developed in which structural lesions were assigned by consensus. We tested a method for scoring new bone formation based on assigning a score of 2 for a bone spur and a score of 6 for intervertebral ankylosis [Canada-Denmark Spur and Ankylosis score (CanDen SAS)].

*Results.* Focal fat infiltration and non-corner vertebral endplate erosions were observed in the majority of patients and were reliably detected. Vertebral corner erosions were not reliably detected. New bone lesions were also detected in almost all patients, and intervertebral ankylosis was detected with good reliability. Bone spurs were not reliably detected. The CanDen SAS demonstrated excellent interobserver reliability (ICC = 0.93) across 4 readers.

*Conclusion.* Definitions for focal fat infiltration, non-corner vertebral erosions, and intervertebral ankylosis function well as regards reliability. Despite rigorous standardization of definitions, substantial calibration is required for vertebral corner erosions and bone spurs. (J Rheumatol 2009;36 Suppl 84:39-47; doi:10.3899/jrheum.090619)

*Key Indexing Terms:*

SPONDYLOARTHRTITIS  
EROSION

FAT INFILTRATION

MAGNETIC RESONANCE IMAGING  
ANKYLOSIS

Three principal types of structural lesions in spondyloarthritis (SpA) have been the focus of the Canada-Denmark MRI Working Group, namely, fat

---

*From the Department of Medicine, University of Alberta, Edmonton, Alberta, Canada; Faculty of Medicine, Siriraj Hospital, Mahidol University, Bangkok, Thailand; Departments of Rheumatology, Copenhagen University Hospitals at Hvidovre, Glostrup, and Gentofte; Department of Radiology, Copenhagen University Hospital at Herlev, Copenhagen, Denmark; and Department of Radiology and Diagnostic Imaging and Department of Medicine, University of Alberta, Edmonton, Alberta, Canada.*

*We are grateful for the support provided through the Nathional Research Initiative from The Arthritis Society.*

*W.P. Maksymowych is a Scientist of the Alberta Heritage Foundation for Medical Research.*

*P. Chiowchanwisawakit, MD, Rheumatologist, Department of Medicine, University of Alberta, and Faculty of Medicine, Siriraj Hospital, Mahidol University; M. Østergaard, MD, PhD, DMSc, Professor, Departments of Rheumatology, Copenhagen University Hospitals at Hvidovre and Glostrup; S.J. Pedersen, MD, Rheumatology Fellow, Department of Rheumatology, Copenhagen University Hospital at Gentofte and Department of Radiology, Copenhagen University Hospital at Herlev; R.G.W. Lambert, FRCPC, Professor, Department of Radiology and Diagnostic Imaging, University of Alberta; B. Conner-Spady, PhD, Biostatistician, University of Alberta; W.P. Maksymowych, FRCPC, Professor, Department of Medicine, University of Alberta.*

*Address correspondence to Dr. W.P. Maksymowych, 562 Heritage Medical Research Building, University of Alberta, Edmonton, Alberta T6G 2S2, Canada. E-mail: walter.maksymowych@ualberta.ca*

replacement, bone erosion, and new bone formation. Fat replacement of the bone marrow has not been well described or evaluated in the rheumatological literature. However, it is a frequent observation in established SpA. It is observed in the sacroiliac joint (SIJ) adjacent to subchondral bone and is present at vertebral corners, adjacent to vertebral endplates, and within the bone marrow of the costovertebral and facet joints. It is assumed to be a post-inflammatory characteristic, although formal prospective study has not been conducted. Its diagnostic utility and pathophysiological and prognostic significance are unclear. Before these questions can be addressed, the reliability of detection of these lesions must be established. We tested the definitions proposed in this supplement series to see if they can be used as a basis for reliable detection of these lesions.

Osteodestructive lesions in the form of bone erosions are a well described feature of SpA, although they have been primarily assessed radiographically. They are primarily observed at vertebral corners on lateral radiographs of the spine, and clinical practice indicates that they occur very infrequently. Radiographs do not readily depict erosions of the vertebral endplate because the endplate is only visible as a summation image, which makes a small lesion in the center of a flat structure difficult to see. MRI on the other hand allows visualization of

---

Personal non-commercial use only. The Journal of Rheumatology Copyright © 2009. All rights reserved.

erosions occurring at any point in the endplate without superimposition of intact bone as well as the associated loss of marrow fat. The frequency of different types of erosions, their distribution in the spine, and their reliability of detection using the definitions proposed by the Canada-Denmark MRI Working Group remain to be established. This is a prerequisite to further examination of their prognostic significance, their relationship to new bone formation, and their potential use as endpoints in trials of disease modifying therapies.

Bone proliferation is one of the principal pathologic features of SpA, becoming evident as both sclerosis of existing bone and new bone formation in the form of syndesmophytes and bridging ankylosis across joints and disc spaces. Detection of new bone on lateral radiographs of the spine constitutes the primary basis for the modified Stoke Ankylosing Spondylitis Spinal Score (mSASSS) used to assess structural changes in the spine of patients with SpA<sup>1</sup>. MRI may be superior in the evaluation of new bone formation due to its ability to assess new bone formation throughout the entire perimeter of the vertebral rim as well as throughout the vertebral endplate in the interior of the disc. On the other hand, the dark appearance of compact bone on MRI sequences is a potential impediment to its reliable detection. The MRI definitions and new scoring system for new bone formation in the spine proposed by the Canada-Denmark MRI Working Group now need to be tested to determine if they facilitate reliable detection of new bone formation. This is an essential step before MRI can be further examined as a potential tool for monitoring structural changes in the spine of patients with SpA and response to disease-modifying therapy.

## PATIENTS AND METHODS

*Patients.* We studied 20 patients recruited to an observational cohort of patients with SpA who were systematically assessed every 6 months according to clinical, laboratory, and imaging outcomes. Patients fulfilled the modified New York criteria for AS<sup>2</sup>. There were 14 men of mean (SD) age 43.8 (14.6) years and mean (SD) disease duration of 17.1 (11.3) years. Mean Bath AS Disease Activity Index (BASDAI) was 4.3 (range 3.1–5.9) and mean Bath AS Functional Index (BASFI) was 4.0 (range 2.2–6.4). The study was approved by the University of Alberta ethics committee, and all patients provided informed consent.

*Magnetic resonance imaging.* All MRI of the spine were performed with 1.5 Tesla systems (Siemens, Erlangen, Germany) using appropriate surface coils. Sagittal sequences were obtained with 3–4 mm slice thickness and 11–15 slices were acquired. Sequence parameters were: (1) T1-weighted spin-echo [repetition time (TR) 517–618 ms, echo time (TE) 13 ms]; (2) Short-tau inversion recovery

(STIR; TR 3000–3170 ms, inversion time (TI) 140 ms, TE 38–61 ms). Field of view was 380 to 400 mm and matrix was 512 X 256 pixels. The spine was imaged in 2 parts: (1) Upper half comprising the entire cervical and most of the thoracic spine; (2) lower half comprising the lower portion of the thoracic spine and entire lumbar spine. The specific MRI parameters for acquiring spinal images are provided on our website (<http://www.arthritisdoctor.ca/spine.php>).

*MRI reading exercises.* The formal evaluation of the reliability of structural lesions was preceded by a feasibility exercise in which the formal definitions of structural changes in the spine were applied to the systematic evaluation of MR images from 4 patients with AS. Reference images described in part 3 of this supplement<sup>3</sup> were used to facilitate the recording of lesions, particularly those at the limits of detection. The scoring of lesions in this feasibility exercise was followed by 2 video teleconference discussions in which significant discrepancies were addressed in the context of systematic application of the proposed definitions. Thereafter, a unique MRI study number was allocated to each of the 20 patients whose MR images were subsequently assessed in this study, ensuring blinding to all patient demographics. Allocation was done by a technologist unconnected with the study using computer-generated random numbers. Assessment was performed on a 3-monitor review station by 4 readers (3 for the assessment of fat replacement) using computer software well suited for this type of review (Merge Healthcare eFilm, Milwaukee, WI, USA) and viewing conditions were standardized. Each subject was identified only by MRI study number, and scans were read in random order. MR images for each patient were evaluated at 25 spinal levels from C1 to S1, and lesions were evaluated on the T1-weighted sequence. We recorded the following structural lesions dichotomously (present/absent) at each spinal level (see part 4 of this supplement series for details<sup>4</sup>):

1. Focal fat infiltration (dichotomous yes/no) in anterior and posterior vertebral corners (aFAT, pFAT)
2. Bone erosion at anterior and posterior vertebral corners (aCOBE, pCOBE), and non-corner bone erosion of vertebral endplates observed in central (NOBE central) and lateral (NOBE lateral) sagittal slices
3. Bone spurs at anterior and posterior vertebral corners (aCOS, pCOS), and non-corner bone spurs of vertebral endplates observed in central (NOS central) and lateral (NOS lateral) sagittal slices
4. Ankylosis across anterior and posterior vertebral corners (aCANK, pCANK), and non-corner ankylosis extending from one vertebral endplate to the adjacent endplate in central (NANK central) and lateral (NANK lateral) sagittal slices.

We distinguished between non-corner bone erosions where the diameter of the neck at the cortical break was less (Type A) or at least equal to (Type B) the maximum diameter of loss of the high signal in bone marrow adjacent to the vertebral endplate. Facet joint bone erosions (FABE) and ankylosis (FANK) were recorded only as being present/absent at a spinal segment level because deliberations during selection of reference images led the group to conclude that reliability assessed at the level of individual spinal levels would be poor. Data sheets were designed to separately identify the 3 types of structural lesions on central and lateral slices as defined by the Working Group.

**Statistics.** The distribution of structural lesions was assessed descriptively according to patient, spinal segment, and vertebral level. The data provided represent the mean scores for the readers. Analysis of interobserver reliability for detection of structural changes addressed reliability according to detection of lesions (yes/no) at individual spinal levels as well as at spinal segments. Interobserver reliability was assessed using kappa statistics and percentage agreement. Kappa values  $> 0.75$ ,  $0.40$ – $0.75$ , and  $< 0.40$  were designated as representing excellent, fair to good, and poor reliability, respectively.

We also conducted preliminary analysis of a new scoring method for quantifying new bone formation on spine MRI in which a bone spur is assigned a score of 2 while intervertebral ankylosis is assigned a score of 6 [Canada-Denmark Spur and AnkyloSis score (CanDen SAS)]. This is analogous to scoring by the mSASSS. The maximal score per spinal level was set at 12. Reliability of the total new bone formation spine MRI score per patient was then assessed with the intraclass correlation coefficient (ICC), which was calculated using an analysis of variance model with total new bone formation spine MRI score as the dependent variable, and patient and reader (fixed factor) as independent variables. An ICC value  $> 0.6$ ,  $> 0.8$ , and  $> 0.9$  indicates good, very good, and excellent reproducibility, respectively.

## RESULTS

**Focal fat infiltration.** Vertebral corner focal fat infiltration was observed in 19 (95%), 18 (90%), and 16 (80%) patients by the 3 readers, respectively. Anterior and posterior vertebral corners had similar numbers of lesions per patient [mean (standard deviation, SD) for anterior vertebral corner = 8.3 (7.5) and for posterior vertebral corner = 7.9 (8.2)]. The mean (SD) (range) number of fat lesions per patient (anterior and posterior vertebral corners combined) was 17.3 (17.9) (0–68), 15.7 (16.1) (0–63), and 16.1 (18.3) (0–67) for the 3 readers, respectively. The 3 most commonly affected vertebral corners were C2 lower (65%), C3 lower (50%), C4 lower (50%) for reader 1; C2 lower (65%), C3 lower (55%), and

T12 upper (45%) for reader 2; and C2 lower (55%), L5 lower (55%), and T12 upper (40%) for reader 3. The highest frequency of focal fat lesions in anterior vertebral corners was observed in the upper cervical spine by all 3 readers (Figure 1), but lesions in posterior vertebral corners were more commonly recorded in the lumbar spine (Figure 2). Reliability was good for all reader pairs (Table 1).

**Erosions.** The majority of patients had at least one non-corner vertebral endplate erosion (mean = 70% for the 4 readers). Erosions were less common in the anterior (mean = 45% for 4 readers) and posterior (mean = 26.3% for 4 readers) vertebral corners. The number of spinal levels per patient with non-corner erosions was also consistently greater than for corner erosions (Table 2). Non-corner bone erosions were most common in the lower thoracic and upper lumbar spinal levels, with the 3 most commonly affected sites being T12 upper, T8 lower, and T10 lower; corner erosions were most frequent in the lumbar spine, the most commonly affected levels being L3 lower, L4 upper, and L5 upper (Figure 3). Reliability was good for all reader pairs for non-corner erosions and poor for corner erosions (Table 3).

**New bone formation.** The majority of patients had at least one new bone lesion (mean for 4 readers = 96.7%). A bone spur was recorded in a mean of 7.2 spinal levels per patient (range 3.3–14.5), while intervertebral ankylosis was recorded in a mean of 4.3 spinal levels per patient (range 0–16.3). The frequency of spurs and ankylosis was highest in the cervical spine (mean 23.6% and 26.6% of spinal levels per patient, respectively; Table 4). The most commonly affected sites per spinal level were upper C3 for spurs (Figure 4) and C6/C7 for ankylosis (Figure 5). Facet joint ankylosis was evident in a mean of 45% of patients and affected a mean of 5.3 (26.3%) cervical, 6 (30%) thoracic, and 2.3 (11.5%) lumbar spinal segments. Reliability was poor for all reader pairs and for all spinal regions for bone spurs, but good for ankylosis (Table 5).

The mean for the CanDen SAS score per patient was 40.3 (SD 31.5, range 6.5–126.5), the highest score being recorded at the upper C7 level and in the thoracic spine, mean 21.4 (SD 19.1, range 4–75). Overall interobserver reliability for the CanDen SAS score among all 4 readers was excellent (ICC 0.93, 95% CI 0.79–0.98), and was very good (cervical spine ICC = 0.85) to excellent (thoracic and lumbar spine ICC = 0.91 and 0.96, respectively) for spinal segment scores (Table 6). Mean ICC values for interobserver reliability among the 6 reader pairs was also very good to excellent for thoracic (mean 0.85, range 0.74–0.95) and lumbar (mean 0.91, range 0.80–0.97) segments, while it was good for the cervical spine (mean 0.74, range 0.63–0.88).

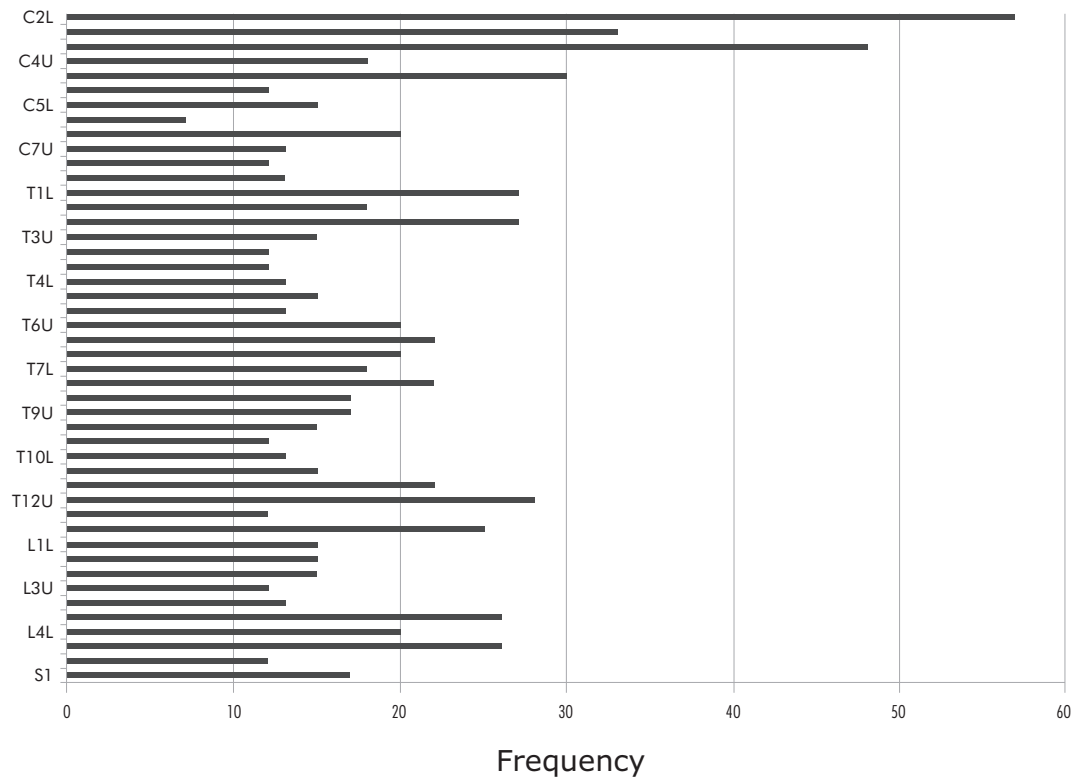


Figure 1. Distribution (mean of 3 readers) of focal fat lesions in the anterior vertebral corners according to spinal level (C: cervical, T: thoracic; L: lumbar; S: sacral; U: upper; L: lower) in 20 patients with SpA.

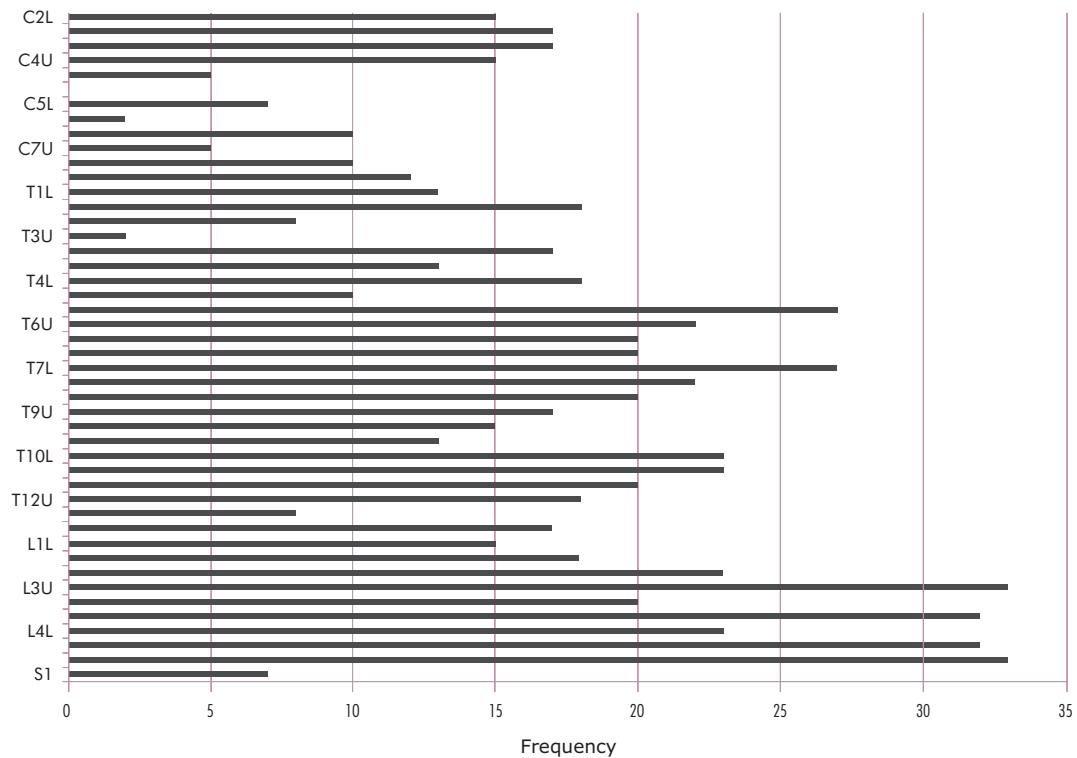


Figure 2. Distribution (mean of 3 readers) of focal fat lesions in the posterior vertebral corners according to spinal level (see legend to Figure 1) in 20 patients with SpA.

Table 1. Interobserver reliability across all spinal levels of detection of focal fat lesions in anterior and posterior vertebral corners of the spine in 20 patients with SpA.

	Anterior Focal Fat Lesions		Posterior Focal Fat Lesions	
	% Agreement	Kappa	% Agreement	Kappa
Inter-reader Pairs				
Raters 1 and 2	88.59	0.64	89.35	0.60
Raters 1 and 3	89.02	0.65	90.43	0.66
Raters 2 and 3	90.22	0.67	92.17	0.72

Table 2. Descriptive data for frequency per patient of spinal levels with vertebral corner and non-corner erosions.

Readers	NOBE			aCOBE			pCOBE		
	Mean (SD)	Median (IQ)	Range	Mean (SD)	Median (IQ)	Range	Mean (SD)	Median (IQ)	Range
A	3.6 (3.7)	2.5 (1.0/5.5)	0–15	0.7 (1.4)	0.0 (0.0/0.8)	0–4	0.2 (0.5)	0.0 (0.0/0.0)	0–2
B	3.4 (3.3)	3.0 (0.0/5.0)	0–11	2.1 (3.0)	1.5 (0.0/2.8)	0–13	0.6 (0.6)	0.5 (0.0/1.0)	0–2
C	3.6 (3.5)	3.0 (0.0/6.8)	0–12	0.6 (1.0)	0.0 (0.0/1.0)	0–3	0.1 (0.3)	0.0 (0.0/0.0)	0–1
D	3.0 (3.2)	2.0 (0.0/5.8)	0–9	2.2 (3.8)	1.0 (0.0/2.8)	0–17	0.7 (1.3)	0.0 (0.0/1.0)	0–5

aCOBE: anterior vertebral corner erosion; pCOBE: posterior vertebral corner bone erosion; NOBE: non-corner vertebral erosion.

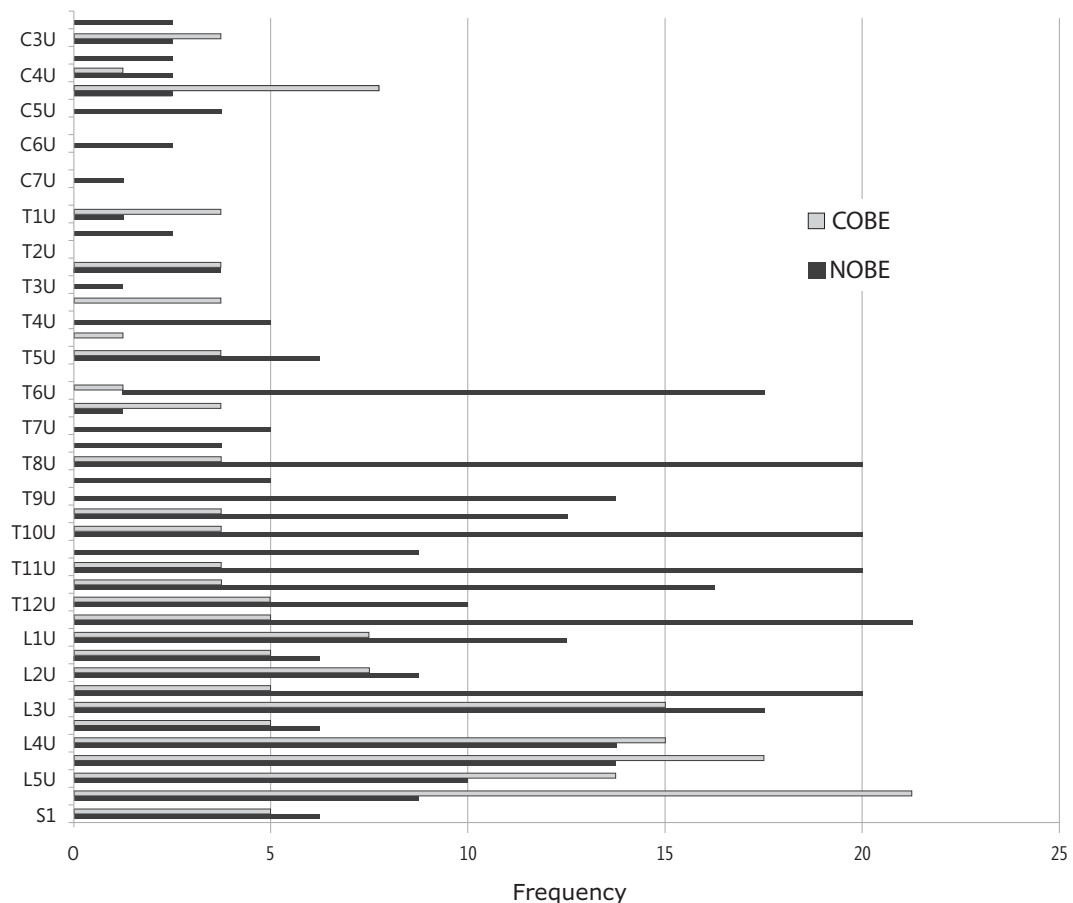


Figure 3. Distribution (mean of 4 readers) of non-corner vertebral endplate bone erosions (NOBE) and vertebral corner erosions (COBE) (anterior and/or posterior vertebral corners) according to spinal level (see legend to Figure 1) in 20 patients with SpA.

Table 3. Interobserver reliability of detection of vertebral corner (anterior, posterior) erosions and non-corner vertebral endplate erosions across all spinal levels in 20 patients with SpA.

Reader Pairs	Vertebral Corner Erosions						Non-corner Vertebral Endplate Erosions		
	Kappa	Anterior % Agreement	ICC*	Kappa	Posterior % Agreement	ICC*	Kappa	% Agreement	ICC*
A and B	0.26	95.5	0.45	0.23	98.9	0.41	0.65	95.1	0.84
A and C	0.26	95.5	0.38	0.23	98.6	0.22	0.52	93.6	0.65
A and D	0.47	98.4	0.64	0.28	99.5	0.25	0.67	95.3	0.91
B and C	0.61	96.5	0.91	0.39	98.4	0.34	0.63	95.2	0.88
B and D	0.33	95.9	0.76	0.26	98.8	0.60	0.59	94.3	0.91
C and D	0.29	95.7	0.74	0.22	98.5	0.23	0.53	93.7	0.79
Mean	0.37	96.3	0.68	0.29	98.8	0.31	0.60	94.6	0.83

\* Intraclass correlation coefficient for total lesion count per patient.

Table 4. Descriptive data for frequency per patient of spinal levels with bone spurs and ankylosis.

	Bone Spur, mean no. (%)	aCOS, mean no. (%)	pCOS, mean no. (%)	NOS, mean no. (%)	Ankylosis, mean no. (%)	aCANK, mean no. (%)	pCANK, mean no. (%)	NANK, mean no. (%)
Cervical spine	2.6 (23.6)	1.5 (13.3)	1.5 (13.3)	0.01 (0.09)	1.3 (26.6)	0.7 (14)	1.0 (19.6)	0.5 (9.8)
Thoracic spine	3.4 (14.2)	2.1 (8.8)	1.4 (5.6)	0.1 (0.6)	2.4 (20.2)	1.6 (13.2)	0.9 (7.5)	0.9 (7.5)
Lumbar spine	1.2 (10.7)	0.4 (3.5)	0.8 (7.3)	0.03 (0.3)	0.6 (9.7)	0.5 (7.7)	0.3 (4.3)	0.08 (1.3)
Total	7.2 (15.6)	3.9 (8.6)	3.6 (7.8)	0.2 (0.4)	4.3 (18.8)	2.7 (11.9)	2.1 (9.3)	1.5 (6.4)

aCOS: anterior vertebral corner spur; pCOS: posterior vertebral corner spur; NOS: non-corner spur; aCANK: anterior vertebral corner ankylosis; pCANK: posterior vertebral corner ankylosis; NANK: non-corner ankylosis.

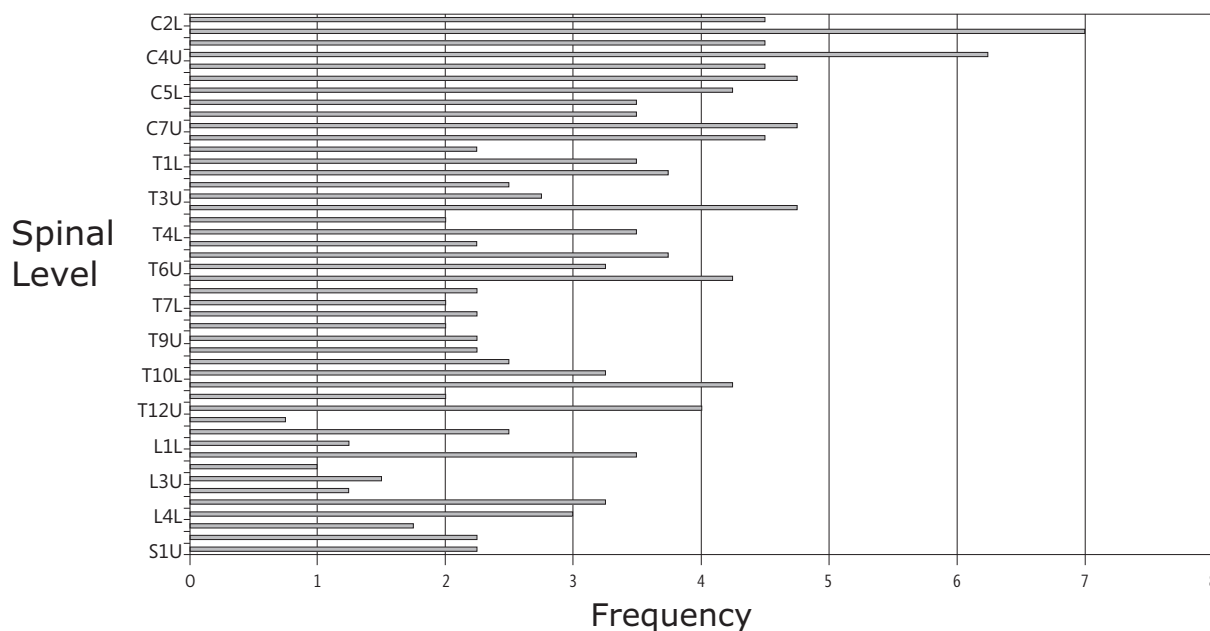


Figure 4. Distribution (mean of 4 readers) of vertebral corner bone spurs (anterior and/or posterior) according to spinal level (see legend to Figure 1) in 20 patients with SpA.



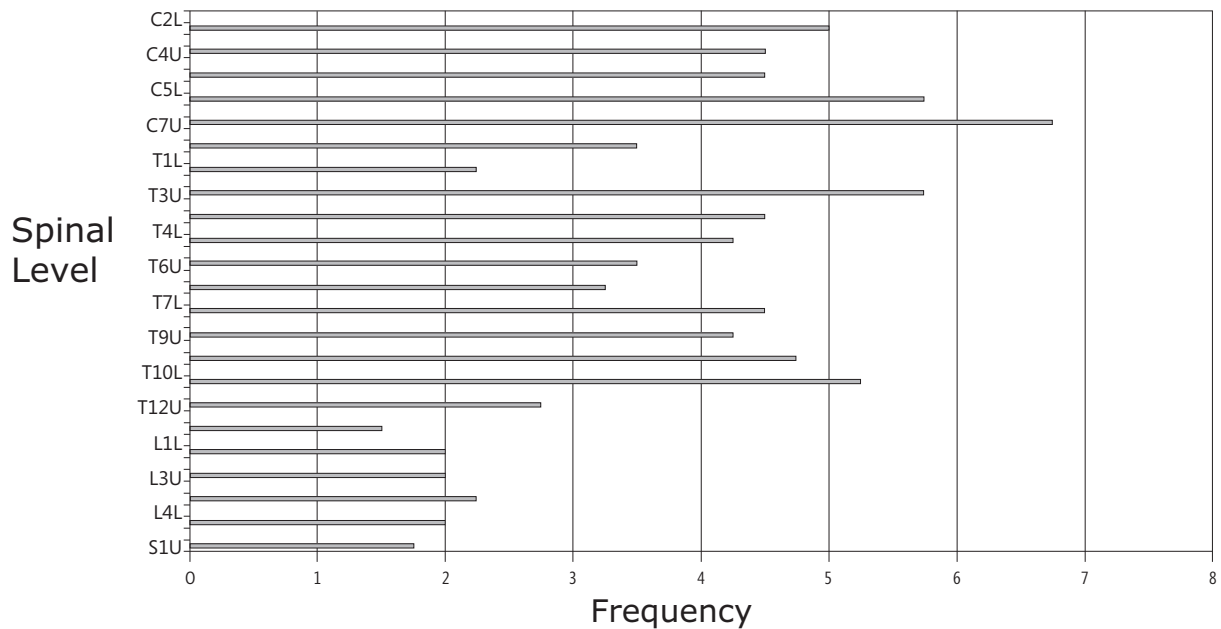


Figure 5. Distribution (mean of 4 readers) of vertebral corner ankylosis (anterior and/or posterior) according to spinal level in 20 patients with SpA.

Table 5. Interobserver reliability of detection of vertebral corner (anterior, posterior) spurs and ankylosis in 20 patients with SpA. Values represent the mean scores for 6 reader pairs.

	Bone Spurs			Ankylosis		
	% Agreement	Kappa	ICC*	% Agreement	Kappa	ICC*
Cervical spine	71.9	0.24	0.25	81.3	0.53	0.82
Thoracic spine	79.2	0.33	0.26	86.5	0.59	0.90
Lumbar spine	84.6	0.17	0.36	93.6	0.62	0.94
Total spine	78.7	0.21	0.29	87.3	0.59	0.93

\*Total lesion count reliability analyzed by intraclass correlation coefficient.

Table 6. Descriptive data for the Canada-Denmark Spur and Ankylosis Score (CanDen SAS) (bone spur = 2, ankylosis = 6) and interobserver reliability among 4 readers of scores from 20 patients with SpA.

	Mean (SD)	Median (IQ range)	Range	ICC (95% CI)
Total spine	40.3 (31.5)	29.8 (20, 43.5)	6.5–126.5	0.93 (0.79, 0.98)
Cervical spine	13.2 (9.3)	9.8 (6.5, 19.5)	2.5–30.5	0.85 (0.70, 0.93)
Thoracic spine	21.4 (19.1)	15 (9.3, 27.5)	4–75	0.91 (0.72, 0.97)
Lumbar spine	5.8 (10.0)	1.8 (0.8, 6.3)	0–41	0.96 (0.91, 0.98)

## DISCUSSION

Testing the proposed definitions for structural lesions in the spine of patients with AS has shown that these definitions function well with respect to reliability in the detection of focal fat infiltration, non-corner vertebral endplate bone erosions, and ankylosis. They function less well in the reliable detection of vertebral corner erosions and bone spurs. Descriptive analysis also shows

that focal fat infiltration is very common in the spine of patients with established AS, while erosions more frequently affect vertebral endplates than vertebral corners, especially at the thoracolumbar junction. A simple new MRI scoring method for quantification of new bone formation in the spine, the CanDen SAS, that relies on detection of bone spurs and ankylosis performs reliably, particular in the thoracic and lumbar spine.

Focal fat infiltration is reliably detected at vertebral corners, most likely because of the contrast between the dark signal from cortical bone and the increased fat signal on T1 sequences. There is a slight increase in the frequency of focal fat infiltration in the cervical spine, but it is likely that this varies according to stage of disease. Some lesions are clearly very small, and it was agreed among readers that reliable detection was facilitated by the availability of reference images depicting lesions at the threshold of detection. The importance of detection and enumeration of these lesions is presently unclear due to their uncertain pathophysiological significance, and there are as yet no data on their sensitivity and specificity for SpA, particularly in relation to other causes of spinal pain. It is assumed that these lesions reflect a postinflammatory reparative phenomenon that, while common in degenerative disc disease, has a frequency and distribution that are relatively unique to SpA, although prospective studies confirming this hypothesis are needed. Most important, their prognostic significance with respect to the eventual development of new bone is unclear, although a preliminary report has suggested that they may have predictive validity for subsequent development of syndesmophytes on radiography<sup>5</sup>. If confirmed, this lesion may require further scrutiny and consideration as a potential target in the evaluation of disease-modifying therapies.

Osteodestructive changes in the spine of patients with SpA have been described in detail on histopathological grounds and on radiography. However, radiographic evidence of erosions in routine practice is uncommon. Our systematic radiographic evaluation of 74 patients with established AS showed that only 6.8% had at least one visible erosion, and the reliability of detection was poor (mean kappa for 4 readers = 0.08)<sup>6</sup>. The present analysis using MRI shows that erosions are in fact quite common, especially vertebral endplate erosions that are not readily detected by radiography but are reliably detected by MRI. Again, the availability of reference images that included images of erosions at the threshold of detection was considered to be a crucial factor in promoting reliable detection. The principal difficulty in verifying that a lesion met the proposed definition of an erosion related to a lack of confidence that there was a clear breach of cortical bone. This was especially difficult at the vertebral corner, where resolution is limited due to the large field of view in scanning the entire spine and the dark appearance of bone on T1-weighted scans. The sensitivity and specificity of these lesions need to be addressed. Similar lesions may be observed in patients with mechanical causes of spinal pain, although there may be a preferential localization for the thoracolumbar junction in patients with SpA. Their relationship to inflammation and new bone formation remains to be established in

prospective studies. Cross-sectional imaging studies of the spine using MRI frequently show erosions associated with inflammation adjacent to vertebral endplates and at vertebral corners. It is unknown if new bone formation is a feature of repair at these sites.

Systematic evaluation of new bone formation in the spine by MRI has been limited. An index has been proposed that scores sclerosis, squaring of vertebrae, syndesmophytes, and ankylosis, the AS-spi-MRI chronicity index<sup>7</sup>. Reliability was shown to be poor, and comparative study showed that MRI was not superior to radiography in the reliable detection of new bone formation<sup>8</sup>. Definitions for syndesmophytes and ankylosis seen on MRI were not specifically proposed, and it was not clear whether the poor reliability was due to unreliable detection of all or only some lesions since data were reported only for the index as a whole. We show that ankylosis is reliably detected, while bone spurs are not. Several factors might account for this. The detection of a bone spur is primarily based on a change in the normal contour of a vertebral corner visible on MRI. The horizontal spurs associated with degenerative disease are therefore more readily apparent than the vertical spurs that are characteristic of SpA. The inferior vertebral endplate is concave in certain regions of the spine, especially the cervical segment, and it may be difficult to discern whether the appearance at the anteroinferior vertebral corner reflects new bone formation or normal variation in the anatomy. Ossification in the anterior and posterior longitudinal ligaments may elicit further uncertainty.

In contrast to the AS-spi-MRI chronicity index<sup>7</sup>, the CanDen SAS score for new bone formation in the spine showed excellent interobserver reliability. In contrast to the mSASSS, which is based on spine radiographs that evaluate only the anterior cervical and lumbar vertebral corners, the CanDen SAS score evaluates all spinal segment levels and includes anterior and posterior vertebral corners. Further study is needed to determine if this new scoring method may be more sensitive to change.

Unlike active inflammatory lesions, which have been studied extensively by MRI, little attention has been paid to structural lesions. It is possible that reliability may be improved by further training and development of additional reference images that not only depict lesions at the threshold of detection, but are also obtained from patients that have had concomitant examination of the spine with computed tomography, to better define the structural abnormalities.

In conclusion, the validation MRI reads of definitions for structural lesions in the spine of patients with SpA have shown that our definitions perform well for focal fat infiltration, vertebral endplate bone erosions, and ankylosis. The CanDen SAS score also performed well. The poor reliability of definitions for vertebral corner erosions



and bone spurs may partly reflect the limitations of the imaging modality and the approach to imaging, the specific morphology of the lesions, and limitations in reader training and calibration, which, although considerable,

were insufficient to achieve good reliability. Further training together with comparative studies using both conventional and computed radiography is warranted.

## REFERENCES

1. Creemers MC, Franssen MJ, van't Hof MA, Gribnau FW, van de Putte LB, van Riel PL. Assessment of outcome in ankylosing spondylitis: an extended radiographic scoring system. *Ann Rheum Dis* 2005;64:127-9.
2. van der Linden S, Valkenburg HA, Cats A. Evaluation of diagnostic criteria for ankylosing spondylitis. A proposal for modification of the New York Criteria. *Arthritis Rheum* 1984;27:361-8.
3. Ostergaard M, Maksymowych WP, Pedersen SJ, Chiowchanwisawakit P, Lambert RGW. Structural lesions detected by magnetic resonance imaging in the spine of patients with spondyloarthritis – definitions, assessment system, and reference image set. *J Rheumatol* 2009;36 Suppl 84:18-34.
4. Pedersen SJ, Østergaard M, Chiowchanwisawakit P, Lambert RGW, Maksymowych WP. Validation of definitions for active inflammatory lesions detected by MRI in the spine of patients with spondyloarthritis. *J Rheumatol* 2009;36 Suppl 84:35-8.
5. Chiowchanwisawakit P, Lambert RGW, Clare T, Maksymowych WP. Post-inflammatory focal fat lesions in the spine of patients with AS predict the development of new syndesmophytes [abstract]. *Arthritis Rheum* 2008;Suppl 58:S356.
6. Maksymowych WP, Powell A, Keeling SO, Russell AS, Conner-Spady B, Lambert RGW. Reappraisal of the mSASSS: exclusion of squaring, sclerosis, and erosions, and inclusion of facet joint damage improves reliability [abstract]. *Ann Rheum Dis* 2008;67 Suppl II:511.
7. Braun J, Baraliakos X, Golder W, Brandt J, Rudwaleit M, Listing J, et al. Magnetic resonance imaging examinations of the spine in patients with ankylosing spondylitis, before and after successful therapy with infliximab: evaluation of a new scoring system. *Arthritis Rheum* 2003;48:1126-36.
8. Braun J, Baraliakos X, Golder W, Hermann K-G, Listing J, Brandt J, et al. Analysing chronic spinal changes in ankylosing spondylitis: a systematic comparison of conventional x rays with magnetic resonance imaging using established and new scoring systems. *Ann Rheum Dis* 2004;63:1046-55.