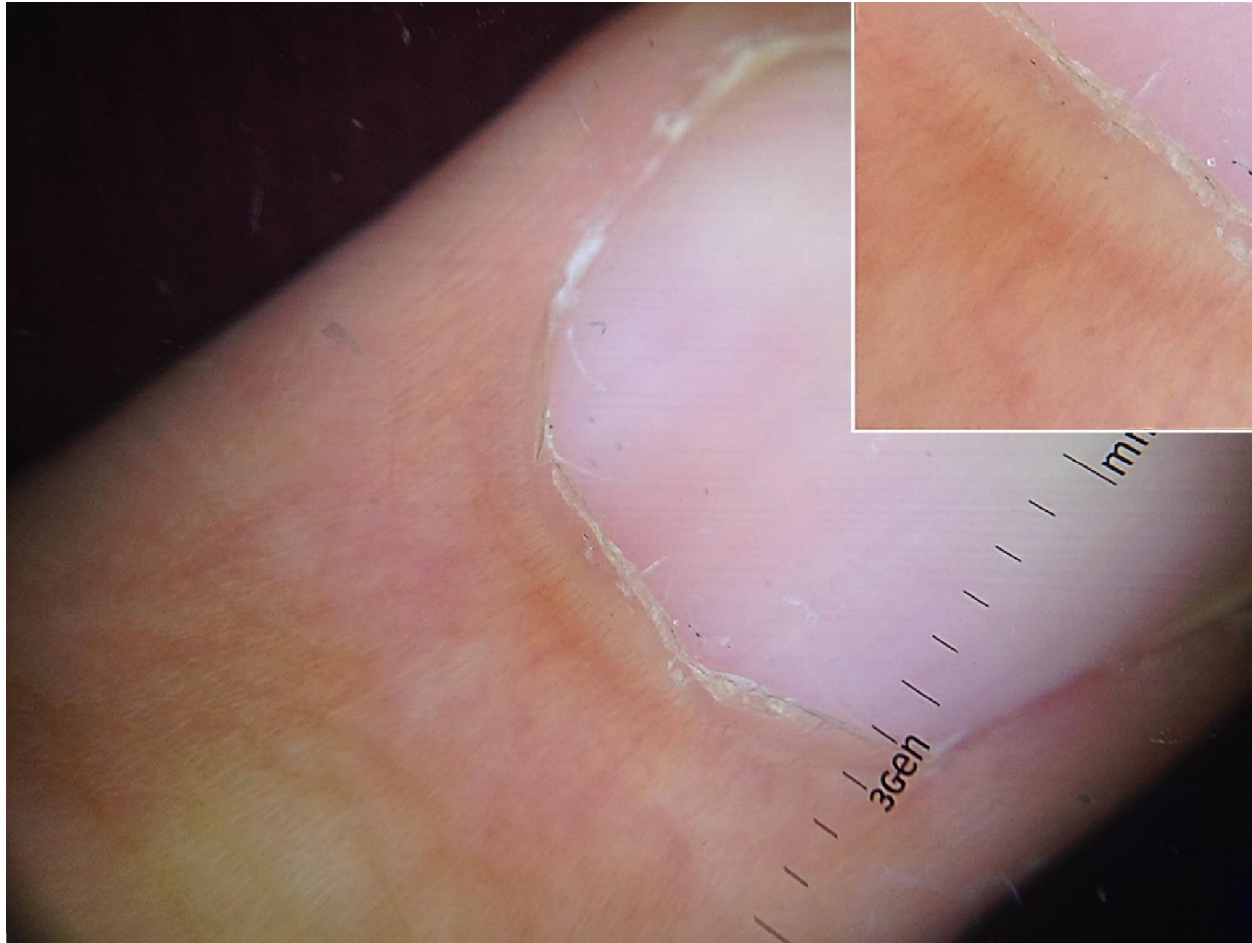


Online supplement to: Early Psoriatic Arthritis Versus Early Seronegative Rheumatoid Arthritis: Role of Dermoscopy Combined with Ultrasonography for Differential Diagnosis. *The Journal of Rheumatology*. doi:10.3899/jrheum.170962.

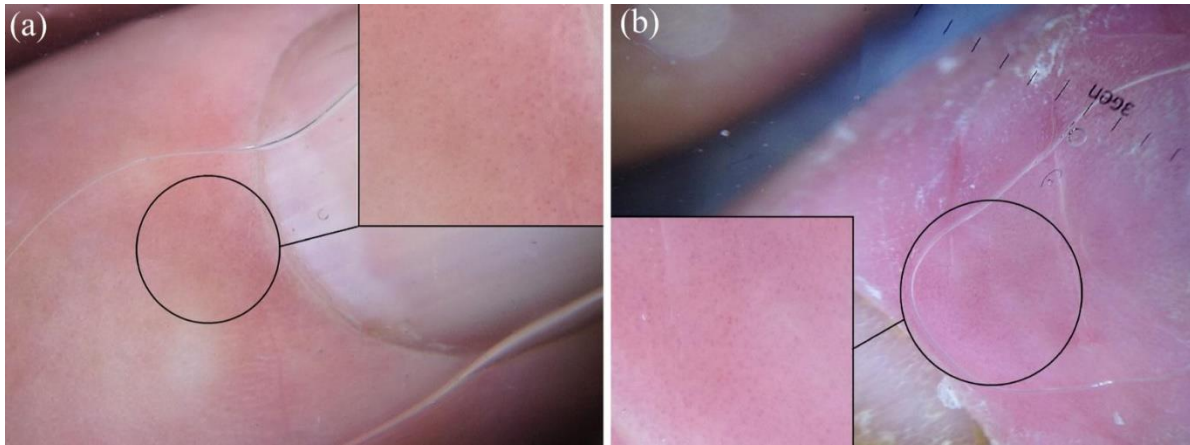
ONLINE SUPPLEMENTARY DATA

Supplementary Figure 1. Proximal nailfold dermoscopy.



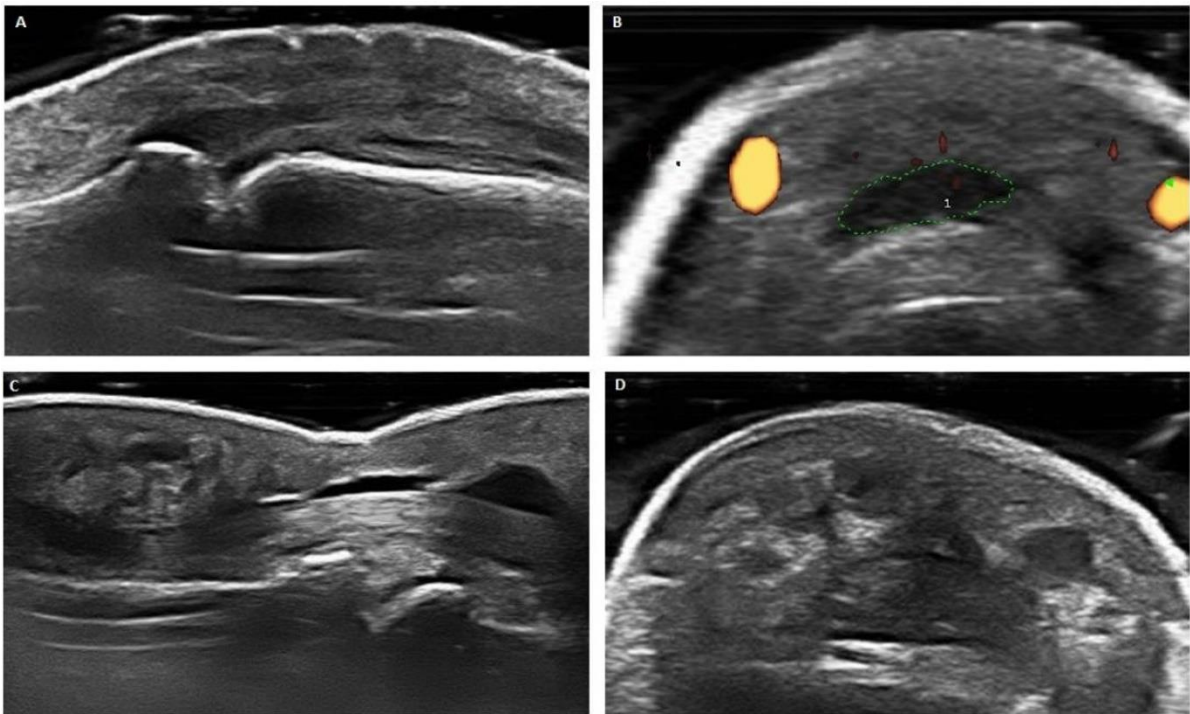
Proximal nailfold dermoscopic examination of a healthy control display a single row of uniform capillary loops located just above the cuticle in controls (magnified in box).

Supplementary Figure 2. Proximal nailfold dermoscopy.



Proximal nailfold dermoscopic examination of one of the six patients initially diagnosed as seronegative RA and then reclassified as PsA on combined rheumatological-dermatological assessment displays diffuse dotted vessels (a; magnification in the box); the same vascular pattern is visible in a PsA patient (b; magnification in the box).

Supplementary Figure 3. Hands ultrasonography.



Ultrasonographic features specific for PsA: enthesitis of central slip at PIP joint in long axis (a) and short axis (b); soft tissue edema around essudative flexor tenosynovitis in long axis (c) and short axis (d).