

Accepted Article

Clinical and LASCA preliminary data on selexipag efficacy for the treatment of digital vasculopathy in systemic sclerosis

Marco Di Battista^{1,2*}, Alessandra Della Rossa¹, Mattia Da Rio¹, Giammarco De Mattia¹, Riccardo Morganti³, Marta Mosca¹

¹Rheumatology Unit; University of Pisa; Pisa; Italy

²Department of Medical Biotechnologies; University of Siena; Siena; Italy

³Section of Statistics; University of Pisa; Pisa; Italy

*Corresponding author: Marco Di Battista; via Roma 67, Pisa 56123, Italy. E-mail address:

dibattista.marco91@gmail.com

Running head: Selexipag for SSc microangiopathy

Key indexing terms: Systemic sclerosis; Selexipag; Vasculopathy; Digital ulcers; Raynaud's phenomenon; Laser speckle contrast analysis.

Funding: None to declare.

Conflict of interest: None to declare.

Authors' list:

M. Di Battista, MD (ORCID ID 0000-0002-4788-5729)

A. Della Rossa, MD, PhD

M. Da Rio, MD

G. De Mattia, MD

R. Morganti, ScD, PhD

M. Mosca, MD, PhD, Prof (ORCID ID 0000-0001-5937-4574)

Downloaded on April 24, 2024 from www.jrheum.org

This article has been accepted for publication in The Journal of Rheumatology following full peer review. This version has not gone through proper copyediting, proofreading and typesetting, and therefore will not be identical to the final published version. Reprints and permissions are not available for this version. Please cite this article as doi: 10.3899/jrheum.2022-1113. This accepted article is protected by copyright. All rights reserved.

Abstract

Objectives: Systemic sclerosis (SSc) is burdened by Raynaud's phenomenon (RP) and digital ulcers (DUs) and sometimes standard vasoactive therapies are ineffective or contraindicated. Selexipag is an oral selective IP prostacyclin receptor agonist approved for the treatment of SSc-related pulmonary arterial hypertension. We aimed to evaluate clinical and instrumental efficacy of selexipag in SSc digital vasculopathy.

Methods: SSc patients with severe digital vasculopathy refractory or with contraindication to all other vasoactive therapies were administered selexipag, evaluating at baseline and after 3 months clinical outcomes regarding RP and DUs and digital perfusion assessed by laser speckle contrast analysis (LASCA).

Results: Selexipag was administered to 9 SSc patients (66.6% female, mean age 52.3 ± 16.6 years). One of them had to stop the drug for adverse effects. After three months selexipag determined a significant reduction of RP daily episodes ($p=0.012$) and RP mean duration ($p=0.044$). DUs decreased from 10 to 4 without reaching the statistical significance. A significant improvement in the mean perfusion of the fingers ($p=0.016$) was observed at LASCA.

Conclusion: Selexipag showed good potential for the treatment of SSc-digital vasculopathy. Our results are certainly preliminary but yet quite encouraging. New trials for the evaluation of selexipag efficacy in SSc-digital vasculopathy are needed.

Accepted Article

Introduction

Systemic sclerosis (SSc) is a chronic autoimmune connective tissue disease characterized by a severe vasculopathy which typically determines burdensome manifestations as Raynaud's phenomenon (RP) and digital ulcers (DUs) with a negative impact on morbidity and quality of life [1]. A group of oral and intravenous vasoactive therapies, namely calcium channel blockers, phosphodiesterase-5 inhibitors (PDE5-i), endothelin receptor antagonists (ERA) and intravenous iloprost, were approved for the treatment of digital vasculopathy in SSc [2]. However, some patients are resistant to these therapies or cannot take them due to contraindications or intolerance. Selexipag is an oral selective IP prostacyclin receptor agonist approved for the treatment of SSc-related pulmonary arterial hypertension (PAH) [3,4]. Given its action on the prostacyclin pathway, the aim of this study was to evaluate the clinical and instrumental efficacy of selexipag in SSc digital vasculopathy.

Methods

Study population

We report the results of an experimental study conducted on patients affected by SSc according to 2013 ACR/EULAR criteria [5] from October 2020 to March 2021 and from October 2021 to March 2022 at the Rheumatology Unit of the University of Pisa. Patients were considered eligible for selexipag only if they presented a severe digital vasculopathy with RP and/or DUs impairing daily activities and if all the other vasoactive therapies were ineffective or contraindicated. This off-label compassionate use of the drug was approved by hospital officials (CEAVNO) in accordance with the local rules for rare diseases (law 648/96). Each subject gave written informed consent to participate and to publish the material.

Selexipag was started at a dosage of 200 µg twice daily and was then titrated with weekly increases of 200 µg up to the maximum tolerated dose, with an upper limit dosage of 1200 µg twice daily.

Other ongoing vasoactive therapies were stable in the six previous months and were not modified during the study period.

Each patient was evaluated at baseline and after three months of therapy with selexipag.

Epidemiological and SSc-specific data were collected, especially regarding digital vasculopathy with a self-reported assessment of RP (number of daily episodes, mean duration and VAS pain 0-10 during RP attacks) and with evaluation of the number of DUs and their area measured with a ruler.

Laser speckle contrast analysis (LASCA)

After 15 minutes acclimatization in a temperature-controlled room at $24 \pm 1^\circ \text{C}$, peripheral blood perfusion of the hands was assessed by LASCA (PeriCam PSI, Perimed, Järfälla, Sweden). Subjects were asked not to smoke or to take caffeine or alcohol for 3 hours prior to the examination. The scanner was placed 20 cm perpendicularly above the dorsal side of the hand. The instrument was calibrated according to manufacturer's instructions. A 1-minute recording was obtained for each hand (image acquisition rate: 10 images per second; frames: 11 x 11 cm). Afterwards, regions of interest were drawn from II to V finger bilaterally to evaluate the whole digital perfusion (expressed as arbitrary perfusion units – PU) and the proximal-distal gradient (PDG) of perfusion as previously defined [6].

Statistical analysis

Categorical data were described by absolute and relative frequency, continuous data by mean and standard deviation. To compare clinical and LASCA factors between baseline and 3-months t-test

for paired data (two-tailed) was applied and ladder plot was used as graphic representation.

Significance was fixed at 0.05 and all analyses were carried out with SPSS v.28 technology.

Results

Out of 300 SSc patients routinely followed-up during the study period, 9 of them presented a severe digital vasculopathy refractory or intolerant to other vasoactive drugs and therefore started selexipag. Most of them were female (66.6%) with a mean age of 52.3 ± 16.6 years and a mean disease duration of 13.2 ± 9.7 years. Most of them had limited cutaneous subset (77.7%) and positivity for anti-centromere autoantibodies (55.5%). Notably, all patients previously presented a history of DUs and seven (77.7%) of them had active ulcerations at baseline. Two subjects were smokers and two had concomitant PAH. PDE5-i and ERA were ongoing in 22.3% and 44.5% of the cohort, respectively (combined in PAH cases); whereas no one was taking concomitant calcium channel blockers.

All patients completed the three months of therapy except for one who had to stop the drug after three weeks for headache, arthromyalgias and hypotension, which were the same adverse effects previously experimented with iloprost: these data were no further analysed. Another patient complained of jaw pain, also in this case already present with iloprost, but this adverse effect was made bearable with paracetamol. The final dosage ranged from 800 to 1200 μg twice daily.

Regarding the eight SSc patients evaluated, as reported in Table 1 and Figure 1 from a clinical point of view selexipag determined a significant reduction of RP daily episodes ($p=0.012$) and RP mean duration ($p=0.044$). Although not significantly, VAS pain showed decreasing values (5.00 vs 3.29). The same for followed DUs, which in three months decreased from 10 to 4 with no new DUs, anyway without reaching the statistical significance. Notably, 3 out of 6 patients with baseline DUs completely healed, and the other half showed a reduction in all DUs areas. Evaluating LASCA

Accepted Article
results (Figure 2), we observed a significant improvement in the mean perfusion of the fingers (p=0.016), whereas PDG showed a little increase but with no significance.

Discussion

Since digital vasculopathy represents a major cause of morbidity and quality of life worsening in SSc and some patients have no benefit or cannot take current vasoactive therapies, we sought to investigate the efficacy of selexipag administered off-label for compassionate use. Selexipag is approved for the treatment of SSc-PAH but, given its action on the same prostacyclin pathway as iloprost, it is reasonable to expect also a peripheral vasodilating effect. Unlike iloprost, selexipag offers some additional benefits. First of all, oral administration solves the problem of difficulty in finding venous access in SSc patients. The titration of the dosage ensures that each patient can take the maximum tolerated dose of the drug. Finally, the daily intake guarantees a constant presence of the drug in the body, thus overcoming the debate on the short half-life of iloprost which affects an administration scheme that is not yet completely standardized [7].

Our results showed that selexipag can determine an improvement both on clinical manifestations, reducing and mitigating the severity of RP with an overall healing trend of DUs, and on digital perfusion, as revealed by LASCA. The safety profile was consistent with that observed in previously PAH studies [3]. So far, a couple of case reports reported the efficacy of selexipag in the treatment of RP and DUs [8,9]. The only randomized placebo-controlled trial was published in 2017 but failed in its primary aim to demonstrate a reduction in RP frequency [10]. However, as also stated by the Authors themselves, there were several issues that may have influenced the trial. Among them, the study was designed with a fast titration and a treatment period of only 8 weeks, with 83.3% of patients taking a final selexipag dosage ≤ 800 μg twice daily. It is conceivable that a

longer observation period with a higher drug dosage could have led to more significant results.

Moreover, that trial was not designed to assess the impact of selexipag on DUs.

Our study has several limitations, mainly due to its open-label nature with few patients and without a control group. The small number of the cohort and the short period of observation may have negatively affected some outcomes as DUs healing. The observation period was limited to cold months, anyway seasonal variability could have been a potential biasing factor. Moreover, an upper limit dosage of 1600 μg twice daily as in PAH could have led to even better results. Finally, we could have had Raynaud's parameters self-assessed continuously during the follow-up period.

In conclusion, the results obtained so far are certainly preliminary but yet quite encouraging, thus laying the foundations for the design of a new trial that could evaluate, with a standardized titration and an adequate observation time, the efficacy of selexipag in SSc digital vasculopathy. In this context, the use of LASCA as a tool to quantify the perfusion benefit of a vasoactive therapy should be promoted.

References

1. Matucci-Cerinic M, Kahaleh B, Wigley FM. Evidence that systemic sclerosis is a vascular disease. *Arthritis Rheum.* 2013;65:1953–62.
2. Kowal-Bielecka O, Fransen J, Avouac J, et al. Update of EULAR recommendations for the treatment of systemic sclerosis. *Ann. Rheum. Dis.* 2017;76:1327–39.
3. Sitbon O, Channick R, Chin KM, et al. Selexipag for the Treatment of Pulmonary Arterial Hypertension. *N. Engl. J. Med.* 2015;373:2522–33.
4. Gaine S, Chin K, Coghlan G, et al. Selexipag for the treatment of connective tissue disease-associated pulmonary arterial hypertension. *Eur. Respir. J.* 2017;50:1602493.
5. Van Den Hoogen F, Khanna D, Fransen J, et al. 2013 classification criteria for systemic sclerosis: An american college of rheumatology/European league against rheumatism collaborative initiative. *Arthritis Rheum.* 2013;65:2737–47.
6. Di Battista M, Morganti R, Tani E, Da Rio M, Della Rossa A, Mosca M. Definition and application of proximal-distal gradient finger perfusion in systemic sclerosis by laser speckle contrast analysis. *Microvasc. Res.* 2022;140:104307.
7. Ingegnoli F, Schioppo T, Allanore Y, et al. Practical suggestions on intravenous iloprost in Raynaud's phenomenon and digital ulcer secondary to systemic sclerosis: Systematic literature review and expert consensus. *Semin. Arthritis Rheum.* 2019;48:686–93.
8. Del Papa N, Vitali C, Bilia S, et al. Selexipag may be effective in inducing digital ulcer healing in patients with systemic sclerosis. *Clin. Exp. Rheumatol.* 2020;38:S181–2.
9. Langleben D, Berkson L, Chartrand S. Selexipag therapy for raynaud phenomenon-induced severe digital Ischemia in intravenous epoprostenol responders with connective tissue disease. *J. Rheumatol.* 2021;48:616–7.

10. Denton CP, Hachulla É, Riemekasten G, et al. Efficacy and Safety of Selexipag in Adults With Raynaud's Phenomenon Secondary to Systemic Sclerosis: A Randomized, Placebo-Controlled, Phase II Study. *Arthritis Rheumatol.* 2017;69:2370–9.

Figure legends

Figure 1. Individual and mean trend of clinical and LASCA parameters during selexipag therapy.

Figure 2. Visual chromatic difference of perfusion obtained with LASCA before and after 3 months of selexipag.

Table 1. Clinical and LASCA comparison between baseline and 3-months selexipag therapy.

Mean \pm SD	Baseline	3-months	p-value
Daily RP episodes (n)	5.71 \pm 2.50	3.43 \pm 1.90	0.012
RP duration (min)	32.43 \pm 25.91	18.14 \pm 16.76	0.044
RP VAS pain (0-10)	5.00 \pm 3.79	3.29 \pm 3.59	0.165
DUs (n)	1.25 \pm 1.04	0.50 \pm 0.75	0.079
Whole digital perfusion (PU)	36.02 \pm 16.05	67.61 \pm 26.28	0.016
PDG perfusion	1.42 \pm 0.23	1.76 \pm 0.48	0.161

RP: Raynaud's phenomenon; DUs: digital ulcers; PDG: proximal-distal gradient perfusion.

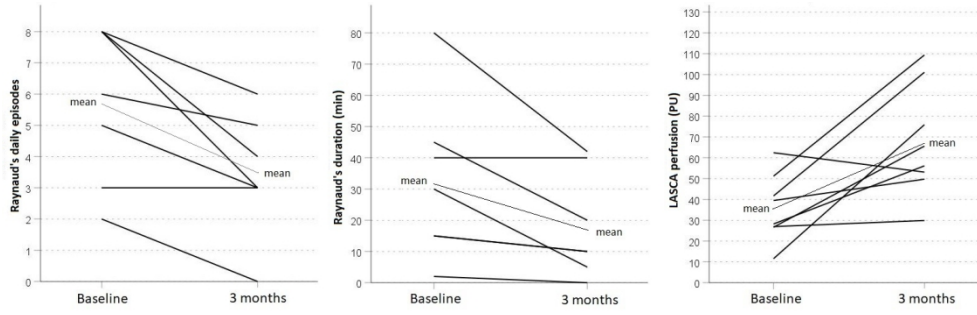


Figure 1

68x21mm (600 x 600 DPI)

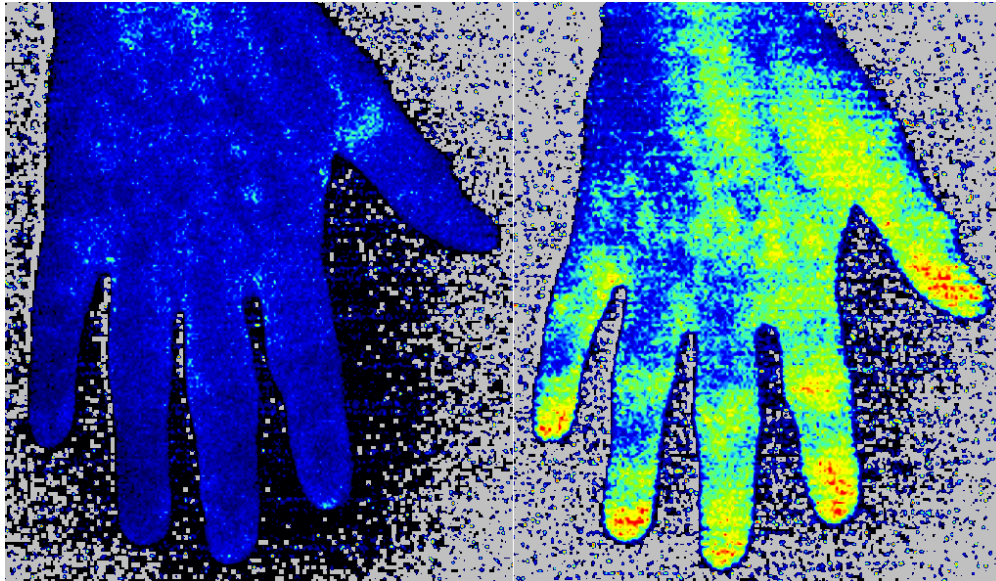


Figure 2

43x25mm (600 x 600 DPI)