


## Images in Rheumatology

# Disseminated *Mycobacterium haemophilum* Infection Mimicking Rheumatoid Nodules

Kyosuke Yamamoto , MD, Ryo Rokutanda, MD, Kameda Medical Center, Chiba, Japan. Address correspondence to Dr. K. Yamamoto, 929 Higashi-cho, Kamogawa City, Chiba Prefecture, 296-0041, Japan. Email: yamamoto.kyosuke@kameda.jp. The authors declare no conflicts of interest relevant to this article. Ethics approval was granted by the Clinical Research Review Committee, Kameda General Hospital, Medical Corporation Tesshoukai (Case 22-030). Informed consent for publication of materials was obtained from the patient.

Disseminated nontuberculous mycobacterium (NTM) infection is rare in the differential diagnosis of rheumatoid nodules. The infection is seen primarily in immunosuppressed patients and has been reported in patients with rheumatoid arthritis. Skin lesions including disseminated nodules are the most common clinical presentation in immunosuppressed patients.<sup>1</sup>

An 82-year-old man was referred with a 1-month history of multiple subcutaneous nodules on the fingers of both hands. He had a 13-year history of rheumatoid arthritis and had been on methotrexate 6 mg/week and prednisolone 10 mg/day. Physical examination revealed that vital signs were stable. There were multiple subcutaneous nodules on the fingers (Figure 1), both lower extremities, and the back, varying in consistency from soft to hard and in size up to 1 cm in diameter. Laboratory results showed a white blood cell count of 6200/mm<sup>3</sup> (reference range 3500-9800/mm<sup>3</sup>), a C-reactive protein level of 2.18 mg/dL (reference range 0.00-0.14 mg/dL), a blood glucose level of 271 mg/dL (reference range 70-110 mg/dL), and a hemoglobin A1c level of 9.4% (reference range 4.6-6.2%). Needle aspiration of a soft nodule on the right hand yielded purulent fluid. On Ziehl-Neelsen staining of the fluid, numerous acid-fast

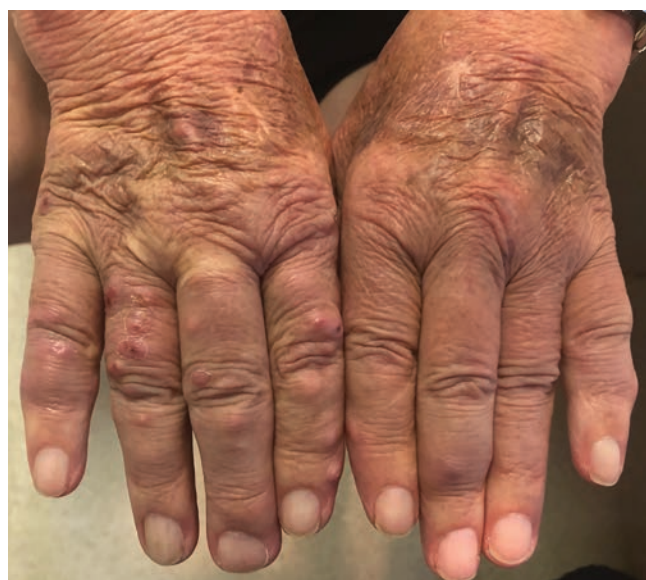

Figure 1. Multiple subcutaneous nodules on the fingers.




Figure 2. Ziehl-Neelsen staining of the fluid showed numerous acid-fast bacilli.

bacilli were observed (Figure 2). *Mycobacterium haemophilum* was isolated from the abscess and blood culture. Disseminated *M. haemophilum* infection was diagnosed. A follow-up 3 months later revealed that antibiotic therapy had diminished the nodules in size and number.

*M. haemophilum* is an acid-fast bacillus belonging to the group of NTM frequently found in the environment. It grows at a temperature lower than that at which other mycobacteria grow, with a unique culture requirement of iron supplementation.<sup>2</sup> In immunocompromised patients with atypical multiple skin nodules, it is important to consider aspiration or biopsy of a nodule. Ziehl-Neelsen staining and acid-fast bacilli culture should be performed.

## REFERENCES

1. Liao TL, Lin CF, Chen YM, Liu HJ, Chen DY. Risk factors and outcomes of nontuberculous mycobacterial disease among rheumatoid arthritis patients: a case-control study in a TB endemic area. *Sci Rep* 2016;6:29443.
2. Lindeboom JA, Bruijnesteijn van Coppenraet LE, van Soolingen D, Prins JM, Kuijper EJ. Clinical manifestations, diagnosis, and treatment of *Mycobacterium haemophilum* infections. *Clin Microbiol Rev* 2011;24:701-17.