


## Images in Rheumatology

# Melorheostosis or “Dripping Candle Wax” Bone Disease

Solène Remize, MD candidate, Genetics Department, University Hospital of Tours; Benoit De Courtivron, MD, Department of Pediatric Surgery, University Hospital of Tours; Médéric Jeanne , MD, Genetics Department, University Hospital of Tours, and INSERM UMR 1253 Imaging and Brain, Tours, France. Address correspondence to Dr. M. Jeanne, Service de Génétique, CHRU de Tours, 2 Boulevard Tonnellé, 37044 Tours cedex, France. Email: mederic.jeanne@univ-tours.fr. The authors declare no conflicts of interest relevant to this article. Written consent was obtained from the patient. Ethical approval for this study was obtained from the Ethics Committee in Human Research of the University of Tours.

Melorheostosis, also known as Leri-Joanny disease,<sup>1</sup> is a very rare skeletal dysplasia manifesting as regions of bone sclerosis with a characteristic flowing candle wax appearance in the classical form of the disease. In addition to this classical pattern, 3 other types of melorheostosis have been described: osteoma-like, osteopathia striata-like, and myositis ossificans-like. The condition usually affects 1 limb and has a pseudosclerotomal distribution. Both female and male individuals are equally affected. The disease usually presents in childhood or adolescence when the lesions are often rapidly progressive, and 50% will have been diagnosed by the age of 20 years.<sup>2</sup> Recent studies have identified somatic mutations in *MAP2K1*, *KRAS*, *LEMD3*, or *SMAD3* as the cause of melorheostosis.<sup>3,4,5</sup> As pathogenic variants are somatic, the risk to other family members is the same as that of the general population.

A 15-year-old female presented to the clinic for a progressive and painful ankylosis of the right thumb. The physical examination was notable for shortening and stiffness of the right thumb. Laboratory studies showed no biological inflammatory syndrome. The upper limb radiographies showed extensive

osteoma-like lesions with endosteal thickening of the humerus, radius, and first and second fingers (Figure 1). These peculiar features led to the diagnosis of melorheostosis.

Melorheostosis is of variable severity but follows a chronic progression occasionally resulting in joint contracture and deformity. Treatments are based mainly on pain management but bisphosphonates and surgery may be required in severe cases.

## REFERENCES

1. Léri A, Joanny J. An undescribed condition of the bones: “casting” hyperostosis over the entire length of a limb or “melorheostosis”. [Article in French] Bull Mem Soc Med Hosp Paris 1922;46:1141-5.
2. Suresh S, Muthukumar T, Saifuddin A. Classical and unusual imaging appearances of melorheostosis. Clin Radiol 2010; 65:593-600.
3. Kang H, Jha S, Iovic A, et al. Somatic SMAD3-activating mutations cause melorheostosis by up-regulating the TGF- $\beta$ /SMAD pathway. J Exp Med 2020;217:e20191499.
4. Kang H, Jha S, Deng Z, et al. Somatic activating mutations in MAP2K1 cause melorheostosis. Nat Commun 2018;9:1390.
5. De Ridder R, Boudin E, Zillikens MC, et al. A multi-omics approach expands the mutational spectrum of MAP2K1-related melorheostosis. Bone 2020;137:115406.

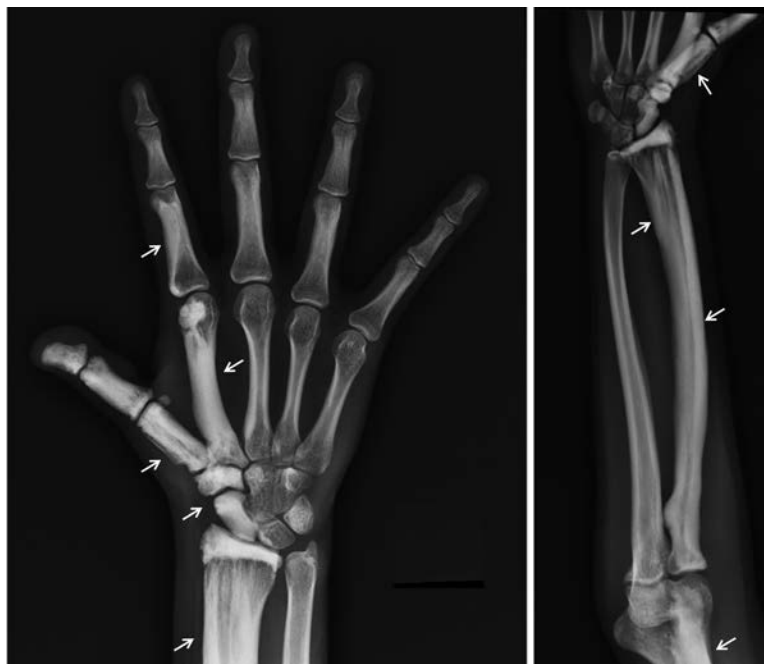

Figure 1. Radiography of the right upper limb showing extensive osteoma-like lesions. Arrows indicate the main areas of melorheostosis.