The Journal of Rheumatology 2021;48:247–50
doi.10.3899/jrheum.191371
First Release December 1 2020

The Journal of Rheumatology

Raynaud Phenomenon in Systemic Sclerosis: Does Digital Thermal Monitoring Correlate to Specific Nailfold Videocapillaroscopy Abnormalities?

Julie K. Thomas[1], Mislav Radic[2], Jordan R. Tucker[3], Rebecca Overbury[4], and Tracy M. Frech[5]

ABSTRACT. ***Objective.*** Early diagnosis of systemic sclerosis (SSc) is imperative, and Raynaud phenomenon (RP) is an important component of progressive vasculopathy. Nailfold videocapillaroscopy (NVC) is a well-established tool that can quantify structural vascular abnormalities. Digital thermal monitoring (DTM) assesses microvascular functional dysfunction related to thermoregulation. In this study, we investigated the correlation of NVC patterns and DTM variables in patients with SSc.

Methods. Patients with SSc according to the 2013 American College of Rheumatology/European League Against Rheumatism criteria who consented and enrolled in the clinical care registry had NVC and DTM performed. For NVC, the number of capillaries (density), measurement of apical diameter (dimension), presence or absence of hemorrhages, and number of abnormal shapes were assessed to categorize 3 different qualitative patterns: early, active, and late. For DTM, Doppler ultrasound hyperemic, low frequency, blood velocity of radial artery, and fingertip vascular function were assessed, and a vascular reactivity index (VRI) measurement was automated. Statistical evaluation was performed by nonparametric tests to assess the correlation of NVC and VRI.

Results. Thirty-one SSc subjects with interpretable NVC and DTM performed on the same day were included in the study. VRI was progressively higher in SSc patients with early, active, and late NVC patterns of microangiopathy ($P < 0.0001$). There was a significant negative correlation between VRI and microhemorrhages scores ($r = -0.363$, $P = 0.044$).

Conclusion. Our study suggests that more advanced vasculopathy correlates to reduced microvascular function as detected by DTM and more advanced structural abnormalities detected by NVC. NVC and DTM may provide different aspects of vasculopathy quantification and complement each other as investigative tools.

Key Indexing Terms: capillaries, Raynaud phenomenon, systemic sclerosis

Systemic sclerosis (SSc) is an autoimmune disease characterized by vasculopathy that precedes fibrosis. The most common clinical feature of SSc is Raynaud phenomenon (RP), which is usually the earliest symptom and is present in nearly all patients with SSc[1]. In fact, according to the Very Early Diagnosis of Systemic Sclerosis (VEDOSS) criteria, the presence of RP in a patient with puffy fingers should prompt the evaluating physician to assess that patient with antinuclear antibodies, SSc-specific autoantibodies, and capillaroscopy, so that proper screening for SSc-related internal organ involvement is completed[2]. There is a clear understanding that early diagnosis of SSc is imperative and that RP is an important component of progressive vasculopathy.

The fingers, toes, and tips of the nose and ears have specialized structural and functional features for thermoregulation, and are the most common areas of RP[3]. The skin on the hand, where the physician most commonly evaluates RP, is notable for the nonhairy (glabrous) palm, dense vascularization, presence of arteriovenous anastomoses, and a large surface-to-volume ratio[4]. This vascular structure is capable of mounting 2 opposite thermoregulatory responses: cutaneous vasodilation where anastomoses can increase the flow to a finger by up to 500%, or cutaneous vasoconstriction when the anastomoses shut and the cutaneous blood flow decreases to nearly zero[5]. The thermoregulation system is an integrative, spatially distributed temperature signal, which incorporates the autonomic nervous system, core body temperatures of the brain and viscera, and peripheral

This work was supported by awards from the National Institutes of Health (NIH; K23AR067889) and the U.S. Department of Veterans Affairs (I01 CX001183). The content is solely the responsibility of the authors and does not necessarily represent the official views of the NIH.

[1]J.K. Thomas, MD, University of Utah, Department of Internal Medicine, Division of Rheumatology, Salt Lake City, Utah, USA; [2]M. Radic, MD, University of Utah, Department of Internal Medicine, Division of Rheumatology, Salt Lake City, Utah, USA, and University Hospital Split, Split, Croatia; [3]J.R. Tucker, Salt Lake Veterans Affair Medical Center, Utah Vascular Research Laboratory, Salt Lake City, Utah, USA; [4]R. Overbury, MD, University of Utah, Department of Internal Medicine, Division of Rheumatology, and University of Utah, Department of Pediatrics, Division of Rheumatology, Salt Lake City, Utah, USA; [5]T. Frech, MD, MS, University of Utah, Department of Internal Medicine, Division of Rheumatology, and Salt Lake Veterans Affair Medical Center, Utah Vascular Research Laboratory, Salt Lake City, Utah, USA.

J.K. Thomas and M. Radic contributed equally to this manuscript.

Address correspondence to Dr. T.M. Frech, 1900 E 30 N, SOM 4b200, Salt Lake City, UT 84132, USA. Email: tracy.frech@hsc.utah.edu.

Accepted for publication June 1, 2020.

Personal non-commercial use only. The Journal of Rheumatology Copyright © 2021. All rights reserved.

Downloaded on April 19, 2024 from www.jrheum.org

temperatures of the skin and subcutaneous tissues; these make studying its dysregulation a challenging process[6].

Nailfold videocapillaroscopy (NVC) is the gold standard for the quantification of vascular abnormalities in SSc-RP and describes the number of capillaries (density), measurement of apical diameter (dimension), presence or absence of hemorrhages, and number of abnormal shapes[7]. With the combination of these findings, the NVC can be categorized into 3 different qualitative patterns: early, active, and late. Few giant capillaries, few capillary microhemorrhages, and no evident loss of capillaries characterize the early pattern. The active pattern comprises frequent giant capillaries, frequent capillary microhemorrhages, and moderate loss of capillaries. The late pattern is characterized by irregular enlargement of capillaries, almost absent giant capillaries and microhemorrhages, severe loss of capillaries with extensive avascular areas, ramified capillaries, and intense disorganization of the normal capillary array. SSc vasculopathy starts from the early pattern and proceeds to the late pattern[8]. Digital thermal monitoring (DTM) of vascular reactivity assesses Doppler ultrasound hyperemic, low frequency, blood velocity of the radial artery, and fingertip vascular function[9]. DTM is an automated, portable, easy-to-perform measure of both cutaneous microvascular and vascular reactivity, which our group has reported as a potential vasculopathy measurement tool in SSc[10]. DTM is different from thermography[11], which measures the infrared radiation from the skin in that it provides a single, automated functional measurement, or vascular reactivity index (VRI).

Table 1. SSc clinical features.

	Values
Age, yrs, mean (SD)	58 (12)
Sex, female	30 (97)
Duration of RP, yrs, mean (SD)	13.1 (5)
Duration of SSc (from first non-RP symptom), yrs, mean (SD)	10.8 (8)
Limited cutaneous SSc	22 (71)
mRSS, mean (SD)	13 (3)
White	30 (97)
ANA-positive	31 (100)
RNAPIII antibody–positive	6 (19)
Anti-Scl-70–positive	4 (13)
Presence of digital ulcers	0
ACA-positive	18 (58)
Capillaroscopy patterns	
Early	8 (26)
Active	11 (35)
Late	12 (38)
Vasodilator therapy	
Calcium channel blocker	30 (97)
Angiotensin receptor blocker	1 (3)
ACE inhibitor	2 (6)
Phosphodiesterase inhibitor	3 (10)
Endothelin receptor antagonist	1 (3)

Values are n (%) unless otherwise indicated. ACA: anticentromere antibody; ACEi: angiotensin-converting enzyme; ANA: antinuclear antibody; mRSS: modified Rodnan skin score; RNAPIII: RNA polymerase III; RP: Raynaud phenomenon; Scl-70: topoisomerase antibody; SSc: systemic sclerosis.

In this study, we investigated the correlation of NVC patterns and DTM variables in patients with SSc in order to assess if microvascular structural changes were related to a microvascular functional measurement of thermoregulation.

MATERIALS AND METHODS

Patients enrolled in a single-center SSc [2013 American College of Rheumatology/European League Against Rheumatism (EULAR) classification criteria[12]] registry who had NVC and DTM performed at the time standard care visit were included in this analysis. This registry has institutional review board (IRB 38705) ethics board approval for the procedures conducted, and written informed consent to publish the material was obtained. Patients enrolled were instructed to clean their hands prior to assessment. Patients with manicures or artificial nail coating applied within 4 weeks of the assessment were excluded. The temperature of the room was set per hospital clinical engineering at 70°F, and patients were acclimated for 15 minutes prior to procedures, during which the SSc clinical features were recorded. The microcirculation was evaluated by the Inspectis capillaroscopy device with a 200× probe. Immersion oil was placed on each digit, and 2 images of the central nailfold of the second, third, fourth, and fifth fingers were captured. The variables analyzed for each image included the number of capillaries per 1 mm, the number of enlarged capillaries (loop width of 50–100 μm), giant loops (apical limb diameter > 100 μm), the number of microhemorrhages, area of capillary disorganization, and area of ramifica-

Table 2. Capillaroscopy patterns in participants.

Participant	VRI	NVC
1	1.31	Early
2	1.47	Early
3	1.42	Early
4	1.06	Active
5	0.54	Late
6	0.84	Active
7	0.83	Active
8	0.7	Active
9	0.94	Active
10	0.2	Late
11	1.19	Early
12	0.82	Active
13	0	Late
14	1.09	Active
15	1.75	Active
16	0.41	Late
17	0.44	Late
18	0.15	Late
19	0	Late
20	1.25	Early
21	0.39	Late
22	0	Late
23	0.25	Late
24	0.85	Active
25	1.1	Active
26	0.88	Active
27	0.04	Late
28	0.09	Late
29	3.5	Early
30	1.78	Early
31	1.92	Early

VRI: vascular reactivity index; NVC: nailfold videocapillaroscopy.

Personal non-commercial use only. The Journal of Rheumatology Copyright © 2021. All rights reserved.

Downloaded on April 19, 2024 from www.jrheum.org

tion. The certified rheumatologist (MR) who completed the EULAR capillaroscopy course performed image collection and analysis.

DTM of both hands was obtained during 5-minute stabilization, 5-minute cuff inflation to 50 mmHg greater than systolic blood pressure, and 5-minute deflation using an automated, operator-independent protocol (VENDYS, Endothelix Inc.). Thermal changes during a 5-minute arm-cuff–induced reactive hyperemia test were monitored continuously in the fingertips of both the occluded and nonoccluded arms using the VENDYS software. Dual-channel temperature data were simultaneously recorded at a 1Hz sampling rate. Temperature rebound is defined as temperature prior to cuff inflation subtracted from maximum temperature after cuff relief. Temperature rebound area under the curve is provided as a single value of VRI.

Continuous data are presented as means with SD. Categorical data are presented as number (%). Statistical evaluation was performed by nonparametric tests to assess the correlation of NVC and VRI.

RESULTS

Thirty-one SSc subjects with interpretable NVC and DTM performed on the same day were included in the study. Thirty subjects (97%) were female, with a mean age (SD) of 58 (12) years and a mean duration (SD) from RP 13.1 (5) years, and duration from first non-RP symptom was 10.8 (SD 8) years. All patients were on vasodilator therapy. VRI was progressively higher in SSc patients with early, active, and late NVC patterns of microangiopathy ($P < 0.0001$, Kruskal-Wallis test), suggesting that more advanced vasculopathy correlates to reduced microvascular function as detected by DTM and more advanced structural abnormalities detected by NVC (Table 2). There was a significant negative correlation between VRI and microhemorrhages scores ($r = -0.363$, $P = 0.044$, Spearman rank correlation), suggesting that this feature of vasculopathy may not be correlated with thermoregulation. In our study, there was no significant correlation between VRI (Figure 1) and number of capillaries/mm, number of enlarged and giant capillaries, or avascular score (Figure 2).

DISCUSSION

It is critical to understand the microvascular structural and functional vascular changes in SSc from the standpoint of both disease severity quantification as well as response to therapeutics. As such, the practical use of bedside tools that quantify vasculopathy are imperative in SSc. NVC is a well-established and valuable tool for the morphologic and structural quantification of vascular damage in RP. Our study suggests that DTM may supplement this tool for understanding the functional

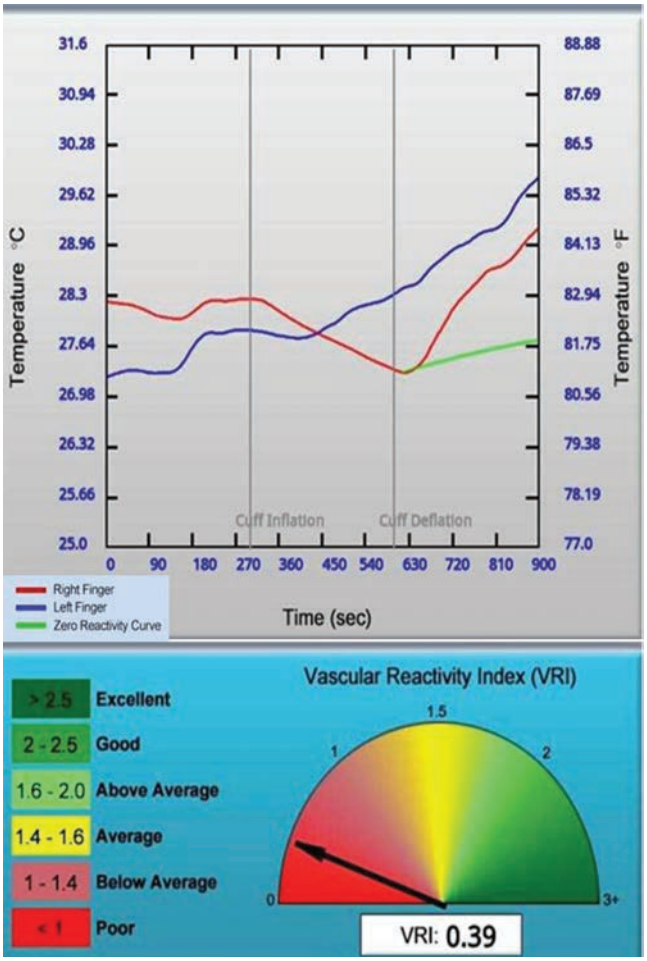

Figure 1. Digital thermal monitoring report from participant.

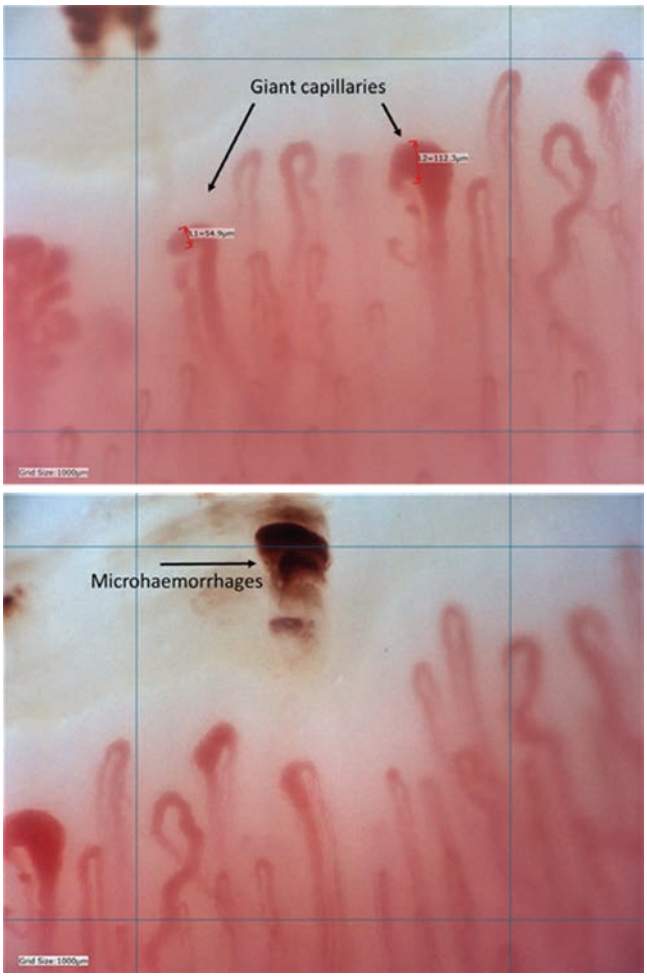

Figure 2. Nailfold videocapillaroscopy findings from participant.

Personal non-commercial use only. The Journal of Rheumatology Copyright © 2021. All rights reserved.

Downloaded on April 19, 2024 from www.jrheum.org

significance of dysregulated vasculopathy. Importantly, the positive correlation of progressive NVC patterns with VRI suggests thermoregulation is important for this aspect of SSc structural vasculopathy. Interestingly, the negative correlation of NVC microhemorrhages variable with VRI suggests this feature may not be related to thermal changes.

Our study has limitations. This was a single-center study with a small sample size in an ethnically similar population of primarily limited cutaneous SSc patients. Nonetheless, our findings are significant in establishing DTM as a potential vasculopathy assessment tool in patients with SSc. NVC and DTM may provide different aspects of microangiopathy quantification and complement each other as investigative tools. While there is a lack of complete correlation between functional and morphological microvascular abnormalities measured by DTM and NVC, the importance of understanding thermoregulation in SSc-RP and progressive vasculopathy is supported by our study.

REFERENCES

1. Wigley FM, Flavahan NA. Raynaud's Phenomenon. N Engl J Med 2016;375:556-65.
2. Guiducci S, Bellando-Randone S, Matucci-Cerinic M. A new way of thinking about systemic sclerosis: The opportunity for a very early diagnosis. Isr Med Assoc J 2016;18:141-3.
3. Flavahan NA. A vascular mechanistic approach to understanding Raynaud phenomenon. Nat Rev Rheumatol 2015;11:146-58.
4. Romanovsky AA. Thermoregulation: some concepts have changed. Functional architecture of the thermoregulatory system. Am J Physiol Regul Integr Comp Physiol 2007;292:R37-46.
5. Romanovsky AA. Skin temperature: its role in thermoregulation. Acta Physiol 2014;210:498-507.
6. Fealey RD. Interoception and autonomic nervous system reflexes thermoregulation. Handb Clin Neurol 2013;117:79-88.
7. Kubo S, Smith V, Cutolo M, Tanaka Y. The role of nailfold videocapillaroscopy in patients with systemic sclerosis. Immunol Med 2018;41:113-9.
8. Sulli A, Pizzorni C, Smith V, Zampogna G, Ravera F, Cutolo M. Timing of transition between capillaroscopic patterns in systemic sclerosis. Arthritis Rheum 2012;64:821-5.
9. Ahmadi N, McQuilkin GL, Akhtar MW, Hajsadeghi F, Kleis SJ, Hecht H, et al. Reproducibility and variability of digital thermal monitoring of vascular reactivity. Clin Physiol Funct Imaging 2011;31:422-8.
10. Frech TM, Murtaugh MA. Non-invasive digital thermal monitoring and flow-mediated dilation in systemic sclerosis. Clin Exp Rheumatol 2019;37 Suppl 119:97-101.
11. Herrick AL, Murray A. The role of capillaroscopy and thermography in the assessment and management of Raynaud's phenomenon. Autoimmun Rev 2018;17:465-72.
12. van den Hoogen F, Khanna D, Fransen J, Johnson SR, Baron M, Tyndall A, et al. 2013 classification criteria for systemic sclerosis: an American College of Rheumatology/European League Against Rheumatism collaborative initiative. Arthritis Rheum 2013;65:2737-47.

Personal non-commercial use only. The Journal of Rheumatology Copyright © 2021. All rights reserved.

Downloaded on April 19, 2024 from www.jrheum.org