


Images in Rheumatology

# Unrecognized Pneumatosis Intestinalis in Antimelanoma Differentiation-Associated Gene 5 Antibody–Associated Dermatomyositis

Ken Nagahata , MD, Masanari Sugawara, MD, Masatoshi Kanda, MD, PhD, Hiroki Takahashi, MD, PhD, Department of Rheumatology and Clinical Immunology, School of Medicine, Sapporo Medical University, Sapporo, Japan. Address correspondence to Dr. K. Nagahata, Department of Rheumatology and Clinical Immunology, Sapporo Medical University School of Medicine, South 1-West 16, Chuo ku, Sapporo, Hokkaido 060-8543, Japan. Email: nagahata.ken@sapmed.ac.jp. The authors declare no conflicts of interest relevant to this article. Informed consent from the patient was obtained. Ethical approval for this study was waived by Sapporo Medical University Hospital Institutional Review Board, based on the “Ethical Guidelines for Medical and Biological Research Involving Human Subjects,” which states that case reports that can be considered part of medical care not for research purposes do not constitute research, prepared by the Japanese Ministry of Health, Labour and Welfare, Ministry of Education, Culture, Sports, Science and Technology, and Ministry of Economy, Trade and Industry.

Pneumatosis intestinalis (PI) is the presence of gas within the bowel wall and may result from several autoimmune diseases, including dermatomyositis (DM).<sup>1</sup>

A 55-year-old man with antimelanoma differentiation-associated gene 5 antibody (MDA5)-associated DM and interstitial lung disease (ILD) presented with a 1-week history of swallowing difficulty. After having undergone surgical resection for renal cell carcinoma, the patient had received immunosuppressive therapies (high-dose glucocorticoids, tacrolimus, and cyclophosphamide) for 2 months.

Three weeks prior to the current presentation, computed tomography (CT) revealed significant gas within the walls of the ascending colon; however, the diagnosis was not determined at this time (Figure 1A).

On examination, the patient had intermittent inspiratory crackles but no abdominal tenderness. Chest radiographs showed new infiltrations in the bilateral lower lobes, and swallowing angiography revealed dysphagia and aspiration. CT revealed gas spreading within the colon wall, which was diagnosed as PI (Figure 1B), a rare complication of DM. Oxygen, ampicillin-sulbactam, and, for dysphagia due to DM, high-dose intravenous Ig therapy were administered. After 2 weeks, the patient’s dysphagia and radiological findings of PI had improved (Figure 1C).

This is the first report, to our knowledge, of a patient with anti-MDA5-associated DM presenting with PI. In this patient, ILD or immunosuppressive therapies may have provoked PI.<sup>2</sup> PI typically improves with conservative treatment, although surgery is necessary in patients with colorectal perforation or intestinal obstruction.<sup>3</sup> The detection of PI is challenging as patients may be asymptomatic or occasionally show symptoms derived from underlying diseases.<sup>4</sup> Clinicians should be aware of PI progressing undetected in patients with DM who are receiving immunosuppressive therapy.

## ACKNOWLEDGMENT

We thank Editage ([www.editage.jp](http://www.editage.jp)) for the English language editing.

## REFERENCES

1. Khalil P, Huber-Wagner S, Ladurner R, et al. Natural history, clinical pattern, and surgical considerations of pneumatosis intestinalis. *Eur J Med Res* 2009;14:231-9.
2. Zarbalian Y, von Rosenvinge EC, Twadell W, Mikdashi J. Recurrent pneumatosis intestinalis in a patient with dermatomyositis. *BMJ Case Rep* 2013;2013:bcr2013200308.
3. Wu LL, Yang YS, Dou Y, Liu QS. A systematic analysis of pneumatosis cystoids intestinalis. *World J Gastroenterol* 2013;19:4973-8.
4. Boerner RM, Fried DB, Warshauer DM, Isaacs K. Pneumatosis intestinalis. *Digest Dis Sci* 1996;41:2272-85.

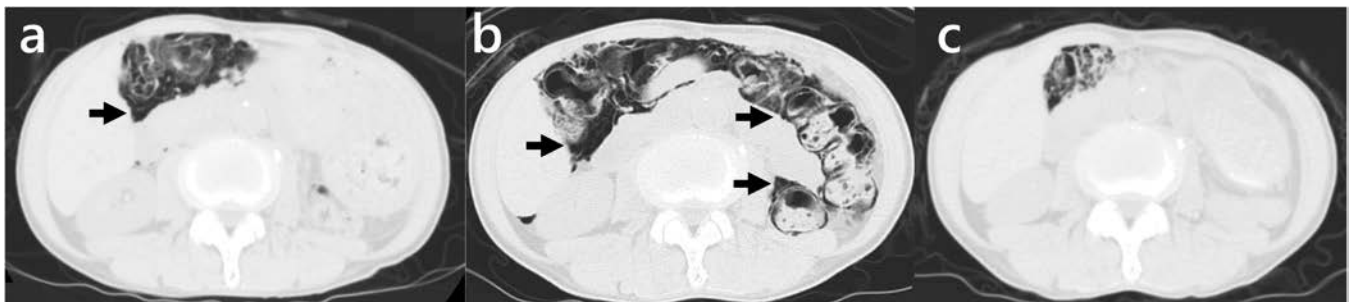


Figure 1. An axial computed tomography image (lung window) showing (A) bowel distension and gas accumulation within the walls of the ascending colon (arrow) 3 weeks prior to the current presentation. (B) The gas had markedly spread on diagnosis (arrows) but (C) improved 2 weeks after treatment.