

Images in Rheumatology

Eosinophilic Granulomatosis With Polyangiitis With a Pathologically Proven Calcified Lung Nodule

Norihisa Tada¹, MD, Division of Rheumatology, Department of Medicine, Showa University School of Medicine, Tokyo; Yajima Nobuyuki², MD, MPH, PhD, Division of Rheumatology, Department of Medicine, Showa University School of Medicine, Tokyo, Department of Healthcare Epidemiology, School of Public Health, Kyoto University Graduate School of Medicine, Kyoto, and Center for Innovative Research for Communities and Clinical Excellence, Fukushima; Noriko Konishi, MD, Division of Rheumatology, Department of Medicine, Showa University School of Medicine, Tokyo; Eisuke Shiozawa, MD, PhD, Division of Pathology, Showa University School of Medicine, Tokyo, Japan. Address correspondence to Dr. N. Yajima, Division of Rheumatology, Department of Medicine, Showa University School of Medicine 1-5-8 Hatanodai, Shinagawa-ku, Tokyo, 142-8666, Japan. Email: n.yajima@med.showa-u.ac.jp. The authors have declared no conflicts of interest relevant to this article. This report was approved by the Ethics Review Board of Showa University (ethics approval no. 21-220-A). The patient provided informed consent to publish this report.

Calcified intrapulmonary nodule is a rare finding of eosinophilic granulomatosis with polyangiitis (EGPA).¹

A 39-year-old Asian man with a 2-year history of allergic asthma developed fever and right-sided chest pain upon inhalation. There was a painful erythema, decreased sensation, and weakness in the right first toe. Blood tests showed the following: eosinophil count, 2770/ μ L; C-reactive protein, 24.1 mg/dL, IgE, 2187 mg/dL; and negative antineutrophil cytoplasm antibody, troponin, and tuberculosis (TB) blood test. Urinalysis, electrocardiography, and echocardiography were normal. Chest computed tomography (CT) showed right-sided pleural effusion, calcification of the intrapulmonary nodules (Figure 1), and mediastinal lymphadenopathy with internal calcification. The nodule was resected under pleuroscopy, and pathological examination showed marked eosinophilic infiltration of the lung interstitium and eosinophilic vasculitis in the small-to-medium-sized vessels, suggestive of EGPA. However, large necrotic foci, epithelioid cells, and Langhans giant cells—suggestive of TB—were consistent with pulmonary nodules (Figure 2). Calcified lesions were observed inside the necrotic foci. Ziehl-Neelsen staining

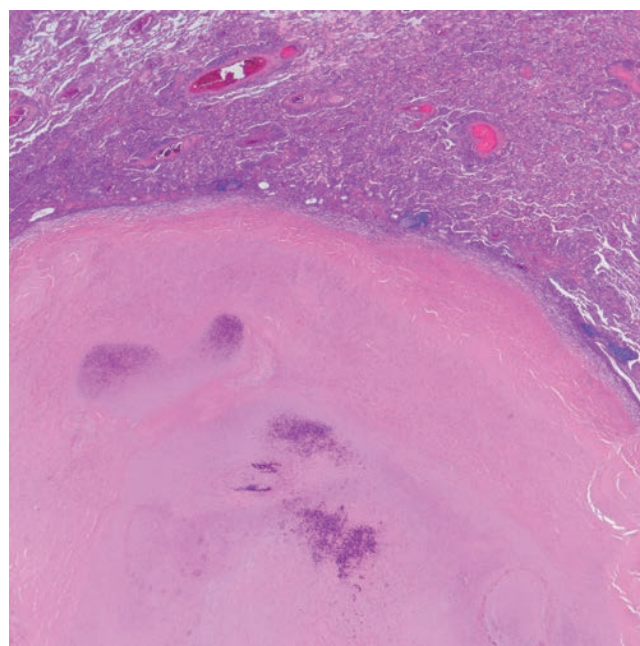


Figure 2. Histopathological findings of the lung nodule. Massive necrosis with granulomas (10 \times).

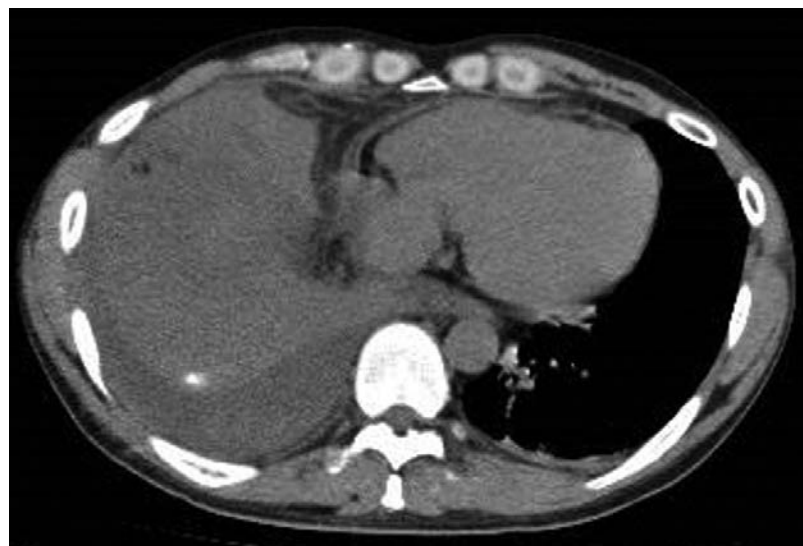


Figure 1. Chest computed tomography of calcified lung nodule and right massive pleural effusion.

was negative and, together with the negative TB test result, TB was ruled out. The patient was diagnosed with EGPA and started on steroids and intravenous cyclophosphamide, which rapidly decreased the eosinophil count. Chest CT 3 months after treatment showed no pleural effusion, improved mediastinal lymphadenopathy, and mildly increased internal calcification, which was considered as an old inflammatory change due to EGPA.

Although the uterus and pericardium can reportedly be calcified by EGPA,^{2,3} eosinophilic necrotizing granulomatous vasculitis has not been pathologically proven. To our knowledge, this is the first case to demonstrate pathologically that calcification can occur in EGPA.

ACKNOWLEDGMENT

We thank Dr. Ryo Yanai for engaging in helpful discussions.

REFERENCES

1. Furuta S, Iwamoto T, Nakajima H. Update on eosinophilic granulomatosis with polyangiitis. *Allergol Int* 2019;68:430-6.
2. Itagane M, Yano H, Kinjo M. Bilateral calcified ureteral stenosis in eosinophilic granulomatosis with polyangiitis. *BMJ Case Rep* 2019;12:e231813.
3. Aboukhoudir F, Pansieri M, Rekik S. Chronic calcific constrictive pericarditis complicating Churg–Strauss syndrome: first reported case. *Thorac Cardiovasc Surg* 2014;62:631-3.

Corrections

Eosinophilic Granulomatosis With Polyangiitis With a
Pathologically Proven Calcified Lung Nodule

Norihisa Tada, Yajima Nobuyuki, Noriko Konishi, and Eisuke
Shiozawa

J Rheumatol 2022;doi:10.3899/jrheum.220378

The correct name of the second author is Yajima Nobuyuki. This
correction applies only to the First Release published on October
1, 2022. The correct text appears in the print and online issues.

doi:10.3899/jrheum.220378.C1