The Journal of Rheumatology 2023;50:456–7
doi:10.3899/jrheum.210647
First Release February 1 2023

The Journal of Rheumatology

Images in Rheumatology

# Cardiac Magnetic Resonance Imaging Contributes to the Accurate Diagnosis of Lupus Myocarditis

Chia-Ling Helen Wei, MD, Division of Nephrology, Department of Internal Medicine, Tri-Service General Hospital, National Defense Medical Center, Taipei, Taiwan; Sin-Yi Lyu, MD, Division of Radiology, Tri-Service General Hospital Keelung Branch, Taipei, Taiwan; Chun-Chi Lu, MD, Division of Rheumatology, Immunology and Allergy, Department of Internal Medicine, Tri-Service General Hospital, National Defense Medical Center, Taipei, Taiwan, and Department of Pathology, University of Washington, Seattle, Washington, USA. Address correspondence to Dr. C.C. Lu, Division of Rheumatology/Immunology and Allergy, Department of Internal Medicine, Tri-Service General Hospital, National Defense Medical Center, No. 325, Sec 2, Cheng-Gong Rd, Neihu Dist., 114, Taipei, Taiwan. Email: jameslutaiwan@gmail.com, chunchi@uw.edu. The authors declare no conflicts of interest relevant to this article. The clinical research was approved by Tri-Service General Hospital, Taiwan (TSGHIRB no.: 1-106-05-132). The authors have obtained the patient's written informed consent to publish the material.

Systemic lupus erythematous (SLE) is a multisystem autoimmune disease, with up to 50% of cases having cardiac involvement.[1] Myocarditis is one of the cardiac presentations in SLE. Cardiac magnetic resonance imaging (cMRI) is a noninvasive diagnostic technique that provides evidence of acute myocardial inflammation by showing myocardial edema on T2-based imaging and myocardial injury on T1-based imaging. Pericardial effusion and abnormal wall motion are also supportive characteristics of myocarditis.[2,3] Here we present the sequential cMRI in a case of lupus myocarditis.

A 41-year-old woman complained of SLE-related polyarthralgia, exertional dyspnea, and chest pain unrelated to exertion. Electrocardiography showed a heart rate of 91 beats per minute without the abnormal ST segment (Figure 1). No abnormal wall motion was seen through echocardiogram. Serum tests did not identify microbial infections and demonstrated a high serum troponin level of 7224 pg/mL, C-reactive protein of 1.79 mg/dL, and high SLE activity (Supplementary Table, available from the authors upon request). Cardiac catheterization showed unobstructed coronary arteries and a ventilation-perfusion scan did not identify pulmonary embolism. cMRI revealed the edema and enhancement of the anterior, lateral, and inferior walls of the left ventricle (LV; Figures 2A,B), with focal pericardial effusion and a calculated left ventricular ejection fraction (LVEF) of 73%. Myocarditis was diagnosed and the patient responded well to pulse methylprednisolone therapy. The follow-up cMRI in 10 months demonstrated delayed enhancement of the lateral wall, with focal fibrosis in the LV (Figure 2). Although decreased LVEF (50%) was found, the patient's clinical presentation improved.

## REFERENCES

1. Al-Nokhatha SA, Khogali HI, Al Shehhi MA, Jassim IT. Myocarditis as a lupus challenge: two case reports. J Med Case Rep 2019;13:343.
2. Friedrich MG, Sechtem U, Schulz-Menger J, et al; International Consensus Group on Cardiovascular Magnetic Resonance in Myocarditis. Cardiovascular magnetic resonance in myocarditis: a JACC white paper. J Am Coll Cardiol 2009;53:1475-87.
3. Ferreira VM, Schulz-Menger J, Holmvang G, et al. Cardiovascular magnetic resonance in nonischemic myocardial inflammation: expert recommendations. J Am Coll Cardiol 2018;72:3158-76.

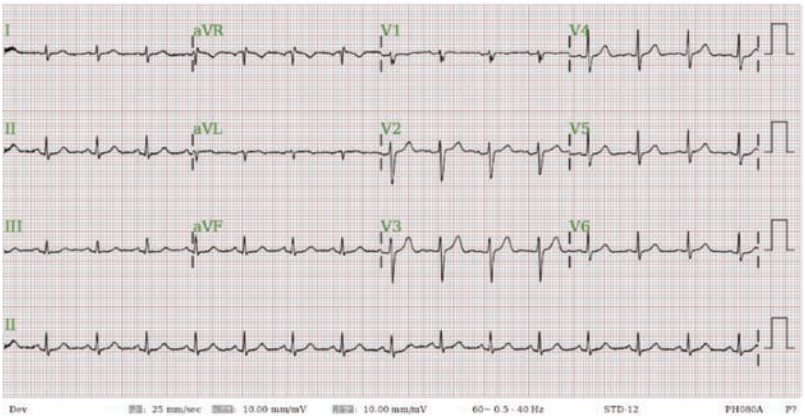


*Figure 1.* Electrocardiography shows a heart rate of 91 beats per minute without the abnormal ST segment.

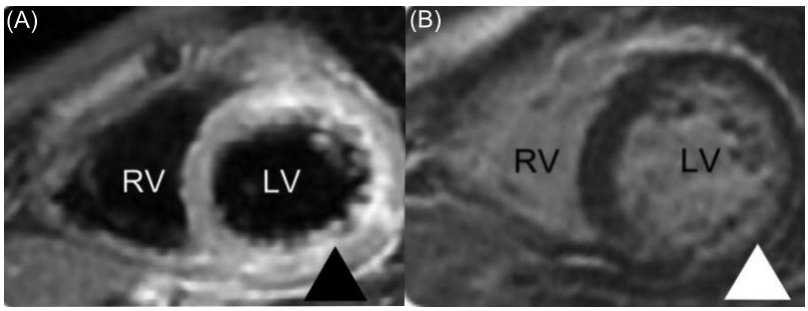


*Figure 2*. Cardiac magnetic resonance imaging (cMRI) of myocardial edema and injury. (A) The black arrowhead indicates increased myocardial enhancement at the anterior, lateral, and inferior walls of the LV on 2-chamber short-axis view. (B) The white arrowhead shows the delayed gadolinium enhancement of the lateral wall of LV at the follow-up cMRI in 10 months. LV: left ventricle; RV: right ventricle.