

# Research Letter

## Anakinra for the Treatment of Antisynthetase Syndrome: A Monocentric Case Series and a Systematic Literature Review

To the Editor:

Antisynthetase syndrome (AS) is a rare autoimmune disorder whose treatment remains a challenge.<sup>1</sup> In refractory cases, treatment escalation from glucocorticoids (GCs) and immunosuppressants to rituximab (RTX) is recommended.<sup>1</sup> However, this biologic agent is associated with worse outcomes in regard to SARS-CoV-2 infection and vaccination.<sup>2</sup> Further, this therapy may not effectively induce remission in some patients with AS.<sup>3</sup> Hence, alternative drugs for patients with refractory AS are necessary. Interleukin (IL)-1 blockade with anakinra might represent a suitable option due to its potent antiinflammatory properties and favorable safety profile.<sup>4</sup>

To evaluate the therapeutic potential of IL-1 inhibition in AS, clinical data of patients with AS referred to our center were revised. AS was diagnosed in the presence of 1 aminoacyl-transfer RNA synthetase (detected with an ELISA), along with at least 2 of the following manifestations: arthritis, interstitial lung disease, mechanic's hands, myocarditis, myositis, and Raynaud phenomenon. Three patients who had been started on anakinra were identified. Written informed consent was collected, and the study was approved by the San Raffaele Ethics Committee

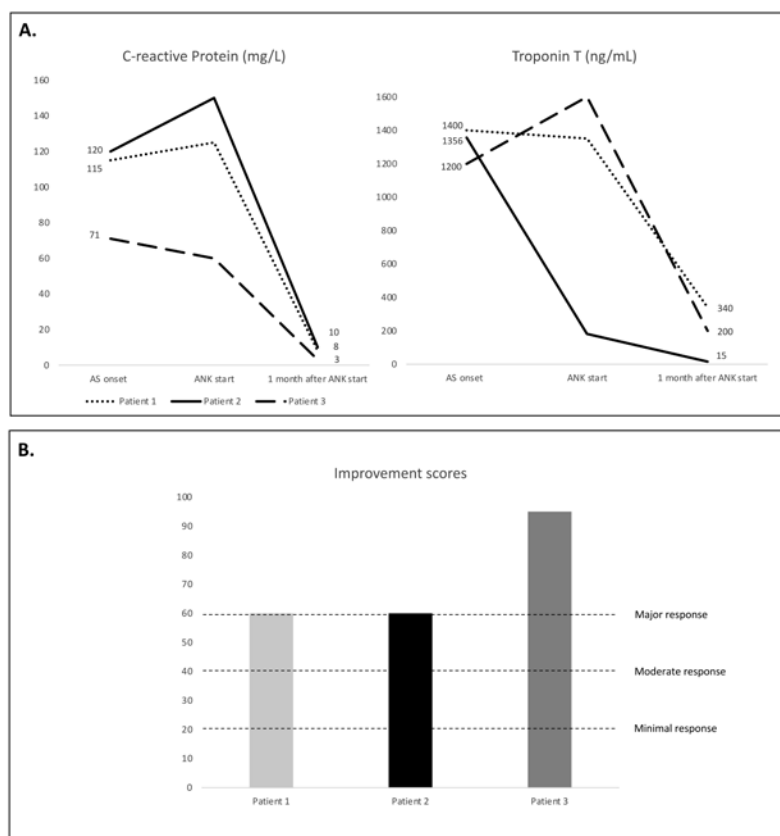
(approval no. DSAN854-A-OS/1). Patient features are reported in the Table. All patients received subcutaneous (SC) anakinra 200 mg daily. This regimen was selected due to the presence of myocarditis, in light of the available data regarding the efficacy of anakinra in patients with heart failure.<sup>5</sup> All patients were concomitantly treated with GCs (median starting dose 75 [IQR 50-80] mg daily, prednisone equivalent), and patient 3 also received SC methotrexate 20 mg weekly. Anakinra led to a major response, as defined according to the criteria based on the International Myositis Assessment and Clinical Studies Group core set measures,<sup>6</sup> in all cases (Figure). Additionally, no adverse reactions were observed over a median follow-up of 8 (IQR 5-9) months. Disease relapse during prednisone tapering < 10 mg daily was observed only in patient 2. However, anakinra was the first treatment that effectively induced a major improvement in this multitherapy-refractory patient.

To further evaluate the potential beneficial effect of anakinra in patients with AS highlighted in our cohort, a systematic literature review (SLR) was performed according to the PRISMA (Preferred Reporting Items for Systematic Reviews and Meta-Analyses) 2020 guidelines. The following criteria were used to search MEDLINE/PubMed and EMBASE databases: (interleukin-1)OR(anakinra) AND (antisynthetase syndrome)OR(antisynthetase antibody)OR(interstitial lung disease)OR(myocarditis). Four patients with AS who were treated with anakinra were identified accordingly.<sup>7-10</sup> Patients' clinical and biochemical features are summarized in the Table. The first report was published in 2008. It described the case of a

Table. Clinical features of patients with antisynthetase syndrome treated with anakinra.

	Patient/ Cohort	Sex and Age, Yrs	Clinical Manifestations and Antibody Profile	Acute-Phase Reactants and Ferritin Levels	Treatment Prior to Anakinra	Daily Dosage of Anakinra, mg	Concomitant Treatment
Our cohort	Patient 1	Male, 66	Arthritis, fever, ILD, myopericarditis anti-PL12+	Increased	GC	200	GC
	Patient 2	Male, 55	Fever, ILD, myocarditis, rash, Raynaud anti-PL12+	Increased	GC, AZA, MMF	200	GC
	Patient 3	Female, 54	Fever, myocarditis, myositis, rash anti-Jo1+	Increased	GC, IVIG, MTX	200	GC, MTX
Literature review	Furlan <sup>7</sup>	Female, 60	Arthritis, fever, ILD, myositis, rash anti-Jo1+	Increased	GC, CYA, CYC, MTX	100	GC, MTX
	Zong <sup>8</sup>	Male, 54	Clinical manifestations NR anti-Jo1+	NR	AZA, CYC, IFX, IVIG, MTX	100	GC, AZA
	Meudec <sup>9</sup>	Female, 55	Arthritis, ILD, myopericarditis, myositis anti-Jo1+	NR	MTX, RTX	NR	GC, MTX
	Ahmad <sup>10</sup>	Female, 65	Arthritis, fever, ILD, rash anti-Jo1+	Increased	AZA, RTX, MMF	100	GC

AZA: azathioprine; CYC: cyclophosphamide; GC: glucocorticoid; IFX: infliximab; ILD: interstitial lung disease; IVIG: intravenous immunoglobulins; MMF: mycophenolate mofetil; MTX: methotrexate; NR: not reported; RTX: rituximab.



**Figure.** Modifications over time of (A) C-reactive protein and troponin T levels, and (B) improvement scores according to the American College of Rheumatology/European Alliance of Associations for Rheumatology response criteria (dotted lines correspond to cut-off scores that define minimal, moderate, and major clinical response [ $\geq 20$ , 40, and 60, respectively]) after anakinra start in patients from our cohort. ANK: anakinra. AS: antisynthetase syndrome.




60-year-old woman with AS and multiorgan involvement who had not responded to multiple immunosuppressants. Once started, anakinra rapidly controlled clinical manifestations.<sup>7</sup> A few years later, Zong et al investigated this therapeutic approach in a monocentric cohort of inflammatory myopathies that included 1 patient with AS.<sup>8</sup> Anakinra was effective in more than half of patients at 12-month follow-up.<sup>8</sup> Recently, Meudec et al reported the case of a patient with AS and pericardial involvement who had not responded to RTX. Heart inflammation promptly resolved after the addition of anakinra.<sup>9</sup> In a recent report,<sup>10</sup> a patient with AS had to stop RTX—which was effectively keeping joint and lung inflammation under control—due to risks associated with the coronavirus disease 2019 (COVID-19) pandemic. She subsequently developed macrophage activation syndrome. This life-threatening complication of AS was effectively treated with steroids, cyclosporine, and anakinra.

Overall, both our SLR and cases series highlight that anakinra may effectively control clinical manifestations in AS. Though the pathogenesis of AS is still poorly understood and IL-1 levels have never been measured in these patients, this cytokine is a key mediator in the development of systemic, lung, and heart inflammation.<sup>4,5</sup> As shown by both our case

series and SLR, these manifestations are prominent features of AS, and they identify a difficult-to-treat disease phenotype that may not even respond to RTX.<sup>3</sup> Hence, the encouraging findings of our study are in line with the plausible pathogenic role of IL-1 in AS. Further, patients featuring biochemical (ie, increased acute-phase reactants) and clinical (ie, fever, myocarditis, and interstitial lung disease) signs of prominent inflammation possibly represent a disease subset that could benefit the most from this approach. However, larger-scale studies are warranted to properly evaluate the efficacy of anakinra in the treatment of AS.

Of note, a higher-than-usual dosage of anakinra (ie, 200 mg daily) was preferred in our patients in light of the presence of myocarditis. Indeed, this intensified regimen might have played a key role in achieving such positive results in our cohort. Nevertheless, even a normal dosage was effective in inducing clinical response in previous reports.<sup>7-10</sup>

In conclusion, IL-1 blockade might be an effective therapeutic alternative in patients with AS. Difficult-to-treat patients with an inflammatory milieu and concomitant myocardial involvement may represent the most suitable target for anakinra, though trials are mandatory to confirm this.

Corrado Campochiaro<sup>1,2</sup> , MD  
Nicola Farina<sup>1,2</sup> , MD  
Giacomo De Luca<sup>1,2</sup> , MD  
Giorgia Trignani<sup>2</sup>, MD  
Alessandro Tomelleri<sup>1,2</sup>, MD  
Marco Matucci-Cerinic<sup>1,3</sup>, MD  
Lorenzo Dagna<sup>1,2</sup>, MD

<sup>1</sup>Unit of Immunology, Rheumatology, Allergy and Rare Diseases, IRCCS San Raffaele, Milan;

<sup>2</sup>Vita-Salute San Raffaele University, Milan;

<sup>3</sup>Department of Rheumatology, University of Florence, Florence, Italy.

C. Campochiaro and N. Farina contributed equally as first authors.

CC, GDL, and LD received speaking fees from SOBI. The remaining authors declare no conflicts of interest relevant to this article.

Address correspondence to Dr. C. Campochiaro, Unit of Immunology, Rheumatology, Allergy and Rare Diseases, IRCCS San Raffaele, Via Olgettina 60, 20132, Milan, Italy. Email: campochiaro.corrado@hsr.it.

## REFERENCES

1. Langlois V, Gillibert A, Uzunhan Y, et al. Rituximab and cyclophosphamide in antisynthetase syndrome-related interstitial lung disease: an observational retrospective study. *J Rheumatol* 2020;47:1678-86.
2. Arnold J, Winthrop K, Emery P. COVID-19 vaccination and antirheumatic therapy. *Rheumatology* 2021;60:3496-502.
3. Sun S, Chen Z, Zhang D, et al. Description and analysis of a novel subtype of the anti-synthetase syndrome characterized by frequent attacks of fever and systemic inflammation in a single-center cohort study. *Front Immunol* 2021;12:729602.
4. Cavalli G, Farina N, Campochiaro C, et al. Repurposing of biologic and targeted synthetic anti-rheumatic drugs in COVID-19 and hyper-inflammation: a comprehensive review of available and emerging evidence at the peak of the pandemic. *Front Pharmacol* 2020;11:598308.
5. van Tassel BW, Abouzaki NA, Erdle CO, et al. Interleukin-1 blockade in acute decompensated heart failure: a randomized, double-blinded, placebo-controlled pilot study. *J Cardiovasc Pharmacol* 2016;67:544-51.
6. Aggarwal R, Rider LG, Ruperto N, et al. 2016 American College of Rheumatology/European League Against Rheumatism criteria for minimal, moderate, and major clinical response in adult dermatomyositis and polymyositis: an International Myositis Assessment and Clinical Studies Group/Paediatric Rheumatology International Trials Organisation Collaborative Initiative. *Arthritis Rheumatol* 2017;69:898-910.
7. Furlan A, Botsios C, Ruffatti A, Todesco S, Punzi L. Antisynthetase syndrome with refractory polyarthritis and fever successfully treated with the IL-1 receptor antagonist, anakinra: a case report. *Joint Bone Spine* 2008;75:366-7.
8. Zong M, Dorph C, Dastmalchi M, et al. Anakinra treatment in patients with refractory inflammatory myopathies and possible predictive response biomarkers: a mechanistic study with 12 months follow-up. *Ann Rheum Dis* 2014;73:913-20.
9. Meudec L, Jelin G, Forien M, Palazzo E, Dieudé P, Ottaviani S. Antisynthetase syndrome and cardiac involvement: a rare association. *Joint Bone Spine* 2019;86:517-8.
10. Ahmad N, Parmar A, Kitchen J. A case of macrophage activation syndrome in a patient with anti-synthetase syndrome. *Oxf Med Case Reports* 2021;2021:omab045.