











Whole-Body Macrophage Positron Emission Tomography Imaging for Disease Activity Assessment in Early Rheumatoid Arthritis

Nicki J.F. Verweij¹ , Jerney de Jongh¹, Marieke M. ter Wee² , Gerben J.C. Zwezerijnen³ ,
Maqsood Yaqub³ , Alexandre E. Voskuyl¹ , Adriaan A. Lammertsma³ ,
Dirkjan van Schaardenburg⁴ , Maarten Boers² , Willem F. Lems¹ , and Conny J. van der Laken¹ 

ABSTRACT. Objective. To investigate the potential of whole-body positron emission tomography/computed tomography (PET/CT) with a macrophage tracer to image arthritis in patients with early rheumatoid arthritis (RA).

Methods. Thirty-five previously untreated, clinically active patients with early RA underwent whole-body PET/CT scanning with the macrophage tracer (*R*)-[¹¹C]PK11195 in addition to clinical assessment (Disease Activity Score in 44 joints [DAS44]). Tracer uptake was assessed quantitatively as standardized uptake values (SUVs). In addition, 2 readers blinded to clinical assessment visually scored tracer uptake in joints. Clinical and PET variables were compared using Cohen κ , linear regression/correlation, and *t* tests, where appropriate.

Results. All but 1 patient showed enhanced tracer uptake in at least 1 joint. Twelve percent of all joints (171/1470) were visually positive on the PET scan, most frequently the small joints in feet (40%) and hands (37%), followed by wrists (15%). Correlations of visual scores with clinical findings both at patient and joint levels were absent or weak. In contrast, average SUVs in the hands, feet, and whole body showed significant correlations with DAS44 scores, with the best correlation seen in the feet ($R^2 = 0.29, P < 0.01$).

Conclusion. Clinically active patients with early RA had increased joint uptake of a macrophage PET tracer, especially in the feet. Quantitative, but not visual PET measures of whole body and joint groups, particularly the feet, showed moderate and statistically significant correlations with clinical outcome.

Key Indexing Terms: diagnostic imaging, radionuclide imaging, rheumatoid arthritis

Rheumatoid arthritis (RA) is a chronic autoimmune disease characterized by inflammation of the synovial joints.¹ The disease is progressive by nature, causing permanent damage to bone and cartilage in the absence of timely treatment.² Clinical assessment of arthritis is the cornerstone in both diagnosis and treatment

monitoring of RA, and the Disease Activity Score (DAS) is a valid tool to assess and monitor clinical disease activity.³ Nevertheless, reliable clinical determination of (sub)clinical arthritis can be difficult.⁴ More objective tools to facilitate early diagnosis and disease activity assessment of RA are needed.

Advanced imaging techniques may contribute to early diagnosis and therapy monitoring through sensitive detection of synovitis, and several techniques have been investigated. Although ultrasonography has shown promise for predicting development of clinical arthritis and therapy response through sensitive detection of inflammation and erosions,^{5,6} it is time consuming and prone to interobserver variability.⁷ Magnetic resonance imaging (MRI) provides high sensitivity for detecting (changes in) RA disease activity and joint damage and is not operator dependent. However, the field of view (FOV) for scanning is limited and the specificity of MRI findings in joints is low in the early phase of RA.⁸ Molecular imaging methods have shown promise as an alternative for early disease activity assessment and monitoring of RA.^{9,10}

Positron emission tomography (PET) allows for highly sensitive depiction of targets at the molecular level and can be used to specifically visualize immune cells of interest through the use of specific tracers.¹¹ Importantly, the whole body can be visualized in a single imaging session. The value of PET for imaging

This work was supported by Pfizer, AbbVie, ReumaNederland (14-1-302), and ZonMw (436001001).

¹N.J.F. Verweij, MD, J. de Jongh, MSc, A.E. Voskuyl, MD, Professor, W.F. Lems, MD, Professor, C.J. van der Laken, MD, PhD, Department of Rheumatology, Amsterdam Rheumatology and Immunology Center, Amsterdam UMC, Vrije Universiteit; ²M.M. ter Wee, PhD, M. Boers, MD, Professor, Department of Rheumatology, Amsterdam Rheumatology and Immunology Center, and Department of Epidemiology and Data Science, Amsterdam Public Health, Amsterdam UMC, Vrije Universiteit; ³G.J.C. Zwezerijnen, MD, M. Yaqub, PhD, A.A. Lammertsma, PhD, Professor, Department of Radiology & Nuclear Medicine, Amsterdam UMC, Vrije Universiteit; ⁴D. van Schaardenburg, MD, Professor, Department of Rheumatology, Amsterdam Rheumatology and Immunology Center, Reade, Amsterdam, the Netherlands.

The authors declare no conflicts of interest relevant to this article.

Address correspondence to Dr. J. van der Laken, Department of Rheumatology, Amsterdam UMC - location VUmC, P.O. Box 7057, 1007 MB Amsterdam, the Netherlands. Email: j.vanderlaken@amsterdamumc.nl. Accepted for publication April 5, 2022.

of inflammatory arthritis has previously been studied with the general tracer ^{18}F fluorodeoxyglucose (FDG), which proved to accurately and sensitively represent inflammatory activity in large joints in patients with RA.¹² Additionally, early changes in FDG uptake proved to predict clinical outcome at a later stage of treatment.^{9,13} However, even though FDG is a sensitive tracer, it is not specific to arthritic activity. Tracers that bind specifically to activated macrophages have been very promising in this regard.¹⁴

(*R*)-[^{11}C]PK11195 (1-(2-chlorophenyl)-*N*-methyl-*N*-(1-methylpropyl)-3-isoquinoline carboxamide) is a PET macrophage tracer that allows for highly sensitive and specific imaging of disease activity in patients with RA. Inflammatory activity was visualized in the hands and knees, providing predictive value for both early disease development and flares in patients that were clinically considered to be in remission.^{10,15-17} Whole-body macrophage PET imaging has not yet been evaluated for RA disease activity assessment. Including the feet during imaging provides special interest, as they are notoriously hard to assess clinically and are involved very early in the disease onset.¹⁸

In this proof-of-concept study, the potential of whole-body (*R*)-[^{11}C]PK11195 PET/computed tomography (CT) to image RA disease activity in clinically active patients with early RA was investigated. Three main aspects were assessed: (1) feasibility of whole-body PET to image arthritis in multiple joints; (2) comparison of visual and quantitative PET variables; and (3) relationship of PET assessments with clinical data.

METHODS

Patients. Thirty-five patients (aged 54 [SD 12] yrs, 51% male) of at least 18 years of age with de novo RA based on the 2010 American College of Rheumatology/European League Against Rheumatism criteria¹⁹ were included between April 2015 and December 2017. Patients were eligible if they had at least 2 swollen joints (as determined by a physician) in the hands, wrists, feet, and/or knees. Exclusion criteria were symptom duration exceeding 2 years, prior treatment with disease-modifying antirheumatic drugs (with the exception of hydroxychloroquine), treatment with glucocorticoids at a dose > 7.5 mg per day in the 4 weeks prior to inclusion, exposure to radioactivity for research purposes > 5 mSv in the last year, the use of experimental drugs in the previous 3 months, pregnancy, and breastfeeding. Patients were asked not to use benzodiazepines for at least 10 days prior to inclusion because of possible interaction with tracer binding to the translocator protein target on macrophages.

All patients gave written informed consent prior to inclusion. Ethical approval was obtained from the medical ethics review committee of the Amsterdam UMC location VUmc (project no. 2013.341).

Clinical assessment. Standard demographical and clinical data were collected by an experienced clinical investigator blinded to the imaging data. Disease activity was expressed as Disease Activity Score in 44 joints (DAS44). Blood withdrawal for the assessment of inflammation markers (erythrocyte sedimentation rate [ESR] and C-reactive protein [CRP]) was performed.

PET/CT imaging. (*R*)-[^{11}C]PK11195 was synthesized according to good manufacturing practices. The tracer is routinely used for clinical studies and was synthesized on site, as described previously.¹⁵ PET/CT scanning was performed with either a Gemini TF scanner or an Ingenuity TF scanner (Philips Healthcare). Fasting or premedication were not required. Patients received 1 venous cannula for injection of $370 \pm 10\%$ MBq of (*R*)-[^{11}C]PK11195. Immediately after injection, the cannula was flushed with 20 mL NaCl 0.9%.

Scanning was started 20 minutes after injection of (*R*)-[^{11}C]PK11195. Patients were scanned in the supine position with the ventral side of the hands on the upper legs. Hands were placed in a special vacuum pouch for immobilization, knees were supported by a small cushion, and feet were placed in a special fixation apparatus for immobilization. Three consecutive static emission scans of the upper body (shoulders to fingertips), knees, and feet were obtained. Patients were scanned for 4 minutes per FOV. Each emission scan was preceded by a low-dose CT scan, which was used for attenuation correction purposes and for anatomical localization. Patients were scanned for 45 minutes to 60 minutes, depending on their height. All scan data were corrected for decay, scatter, random coincidences, and photon attenuation through established procedures.²⁰ After reconstruction, images were transferred to off-line workstations for further analysis.

Image analysis. Two experienced readers (GJCZ and CJvdL), blinded to the clinical data, independently performed semiquantitative visual scoring, using a dedicated workstation (Intellispace Portal 9.0). A consensus round was used to resolve any differences in rating between the 2 readers. The 44 joints included in the DAS44 score were scored for visual tracer uptake on a scale from 0 to 3, with 0 for no increased uptake, 1 for low uptake, 2 for moderate uptake, and 3 for high uptake, as compared to the surrounding background uptake.^{10,16,17} Joints were scored positive on articular tracer uptake, with periarticular and tendon uptake being disregarded.

Further, tracer uptake in joints was quantified by drawing fixed size volumes of interest (VOIs) over 42 predefined joints (on joints both visually positive and visually negative on the PET scan): shoulders, elbows, wrists, metacarpophalangeal joints (MCPs), proximal interphalangeal joints (PIPs), hips, knees, ankles, and metatarsophalangeal joints (MTPs). The size and position of these VOIs were determined in consensus by 2 analysts (NJFV and JdJ) prior to analysis. VOIs were drawn with data analysis software developed in-house, using the low-dose CT as anatomical reference, and with exact positioning being dependent on the focus of tracer accumulation in the joint (in the case of joints visually positive on the PET scan). Standardized uptake values (SUVs) were calculated by dividing the radioactive concentration in each VOI by the injected radioactivity normalized to body weight. The value used to represent tracer uptake was SUV_{peak} defined as the highest average uptake within a sphere of 1.2 mL (hereafter referred to as SUV).

Statistical analysis. At joint level, the agreement between visual PET assessment and clinical assessment values of swollen joint count (SJC) and tender joint count (TJC) was calculated using Cohen κ . First, the original ordinal visual score (0-3) was used, calculating weighted κ . Second, the ordinal score was dichotomized (a score of 0 remained 0, and any PET positivity was marked as 1), and joints were grouped, combining left and right, and grouping smaller joints (MCP2 to MCP5, all hand PIP joints, and MTP2 to MTP5), resulting in the following groups: shoulders, elbows, wrists, MCP1 joints, MCP2 to MCP5 joints, hand PIP joints, hips, knees, ankles, MTP1 joints, and MTP2 to MCP5 joints. Two-by-two tables of the groups were generated with visual scores vs SJC and TJC, in order to compare visual positivity to clinical positivity. At the patient level, the number of joints visually positive on the PET scan in the hands (wrists, MCP joints, and PIP joints), feet (ankles and MTP joints), and the whole body (hands, feet, shoulders, elbows, hips, and knees) were compared with the DAS44 score, as well as with DAS components (ESR, SJC, TJC, and pain score) and CRP. All variants were compared using univariate linear regression.

The quantitative PET dataset was analyzed with the same groups as mentioned above. SUVs in the groups were compared with the clinical values of SJC and TJC using independent *t* tests. Boxplots were used to visualize differences in average SUV. At patient level, quantitative tracer uptake was expressed as average SUV in the hands (wrists, MCP joints, and PIP joints), feet (ankles and MTP joints), and the whole body (hands, feet, shoulders, elbows, hips, and knees). Similar to the analysis of the visual data, the correlation between SUV in the hands, feet, and whole body, and the previously mentioned clinical values, was assessed through univariate

linear regression. To assess the added value of both hands and feet to the whole-body protocol, an analysis of the correlation of clinical values with the average SUV in the whole body minus hands and minus feet was performed through univariate linear regression.

Continuous variables with Gaussian distribution were summarized as mean (SD) and 95% CI. Variables that were nonnormally distributed were summarized as median and IQR. Visual interpretation of the PET/CT data was performed with descriptive statistics. The visual score was reported at an individual joint level or in groups (for MCP2 to MCP5 joints, PIP joints, and MTP2 to MTP5 joints). IBM SPSS Statistics for Windows, Version 22.0 (IBM Corp) was used to assess the distribution of both clinical and PET data. $P < 0.05$ was considered to be significant. As this is an exploratory study, no corrections for multiple testing were applied. The analyses presented in this study incorrectly assume that all observations on joints are independent, where in fact they are “nested” within patients and thus potentially correlated. However, given the exploratory nature of this study and the small sample size, we decided against the use of more advanced (ie, multilevel) modeling because of the burden of increased complexity of the model in analysis and interpretation.

RESULTS

Clinical data. PET/CT scans were obtained for 35 patients. Patients demonstrated moderate to high disease activity, with a mean DAS44 score of 3.2 (SD 1.0). Baseline characteristics of the 35 patients are shown in Table 1.

Visual PET data. Twelve percent of all joints (171/1470) in 35 patients were PET positive, with 1 patient showing no positive joints (only periarticular joint uptake, which was not included in the PET assessment; see Methods section), and the rest showing between 1 to 18 PET-positive joints per patient. The interobserver variability before consensus, as determined by a weighted Cohen κ calculation, was $\kappa = 0.86$. Greater than 90% of PET-positive sites were located in either wrists (15%; Figure 1), small hand joints (37%), or small feet joints (40%; Figure 1). Uptake was rare in shoulders and knees, and absent in elbows and hips. Uptake was low in 102, moderate in 54, and high in 15 joints. Moderate or high scores were mainly seen in MTPs,

Table 1. Baseline patient demographics together with clinical and functional characteristics.

| | N = 35 |
|-------------------------|-----------|
| Male | 18 (51) |
| Age, yrs | 54 ± 12 |
| Height, cm | 173 ± 9 |
| Weight, kg | 80 ± 15 |
| BMI, kg/m ² | 27 ± 4 |
| IgM RF positivity | 24 (69) |
| Anti-CCP positivity | 27 (77) |
| DAS44 | 3.2 ± 1.0 |
| SJC44, median (IQR) | 5 (7) |
| TJC44, median (IQR) | 6 (5) |
| CRP, mg/L, median (IQR) | 14 (20) |
| ESR, mm/h, median (IQR) | 22 (28) |

Values are mean ± SD or n (%) unless otherwise indicated. Anti-CCP: anticyclic citrullinated peptide; CRP: C-reactive protein; DAS44: Disease Activity Score in 44 joints; ESR: erythrocyte sedimentation rate; RF: rheumatoid factor; SJC44: swollen joint count in 44 joints; TJC44: tender joint count in 44 joints.

PIPs, and wrists (41%, 20%, and 19% of total moderate or high scores, respectively). An image of whole-body uptake is included in Supplementary Figure 1 (available with the online version of this article).

At the joint level, the presence or absence of visual PET signal corresponded with the presence or absence of tenderness or swelling in 74% and 75% of the joints, respectively, with varying but generally low levels of agreement per joint ($\kappa < 0.40$; Supplementary Table 1, available with the online version of this article). At the patient level, in general, the sum of the number of joints visually positive on the PET scan in the hands, feet, or whole body did not correlate with the DAS44 score or its components. Only the sum of visual PET scores in the hands correlated with SJC ($R^2 = 0.13$, $P = 0.03$), and the sum of the whole body with ESR ($R^2 = 0.11$, $P = 0.05$). All calculated correlations are summarized in Supplementary Table 2.

Quantitative PET data. Quantitative data showed a large range in SUVs, from 0.07 to 4.97 (in a PIP5 and shoulder joint, respectively). With the exception of shoulders and knees, visually positive joints/joint groups had significantly higher SUVs than negative joints (Table 2).

At the joint level, all groups of the hand and feet joints (but not large joints outside of these groups) showed significant SUV differences between clinically tender and nontender, and between clinically swollen and nonswollen joints (as summarized in Table 3). The largest SUV differences were seen in ankles (0.7 vs 1.3, $P = 0.04$), MTP1 joints (0.7 vs 1.3, $P < 0.01$), and MTP2 to MTP5 joints (0.6 vs 0.8, $P = 0.03$) when comparing nonswollen with swollen joints, as depicted in Figure 2.

At the patient level, average SUV of the feet group had the highest correlation with the DAS44 score ($R^2 = 0.29$, $P < 0.01$; Figure 3). The SUV of the hands group had a slightly lower, and the SUV of the whole body showed the lowest, but still statistically significant, correlation with the DAS44 score ($R^2 = 0.22$, $P < 0.01$ and $R^2 = 0.15$, $P = 0.02$, respectively). Correlation of average whole-body SUV with DAS44 decreased significantly from an R^2 of 0.15 to 0.03 and 0.04 without hands and feet, respectively. Apart from a correlation with DAS44, SUV hands also showed significant correlations with SJC and CRP ($R^2 = 0.31$, $P < 0.01$ and $R^2 = 0.23$, $P < 0.01$, respectively), and SUV feet with TJC and ESR ($R^2 = 0.19$, $P < 0.01$ and $R^2 = 0.29$, $P < 0.01$, respectively). The average whole-body SUV also showed a weak correlation with ESR ($R^2 = 0.14$, $P = 0.03$). All calculated correlations are summarized in Supplementary Table 2 (available with the online version of this article).

DISCUSSION

To our knowledge, this is the first whole-body macrophage PET study of patients with RA that specifically included the feet. PET/CT with the macrophage targeting tracer (R)-[¹¹C]PK11195 proved feasible and provided clear visualization of inflammatory activity in multiple joints in this group of patients with early RA. The high signal in the feet is clinically very relevant, as arthritis in the feet is often difficult to detect. Quantitative PET data allowed for more precise differentiation between clinically active and nonactive joints than visual assessments. The combined

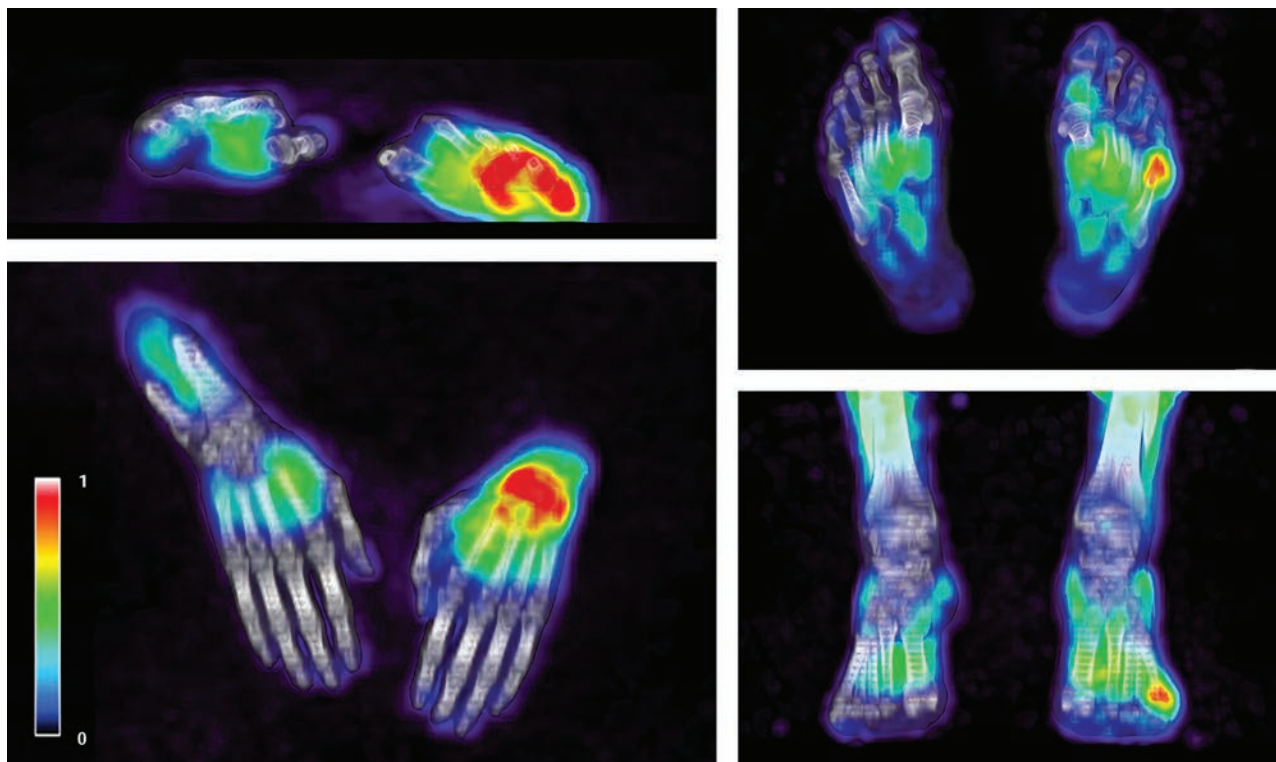


Figure 1. (R)-[¹¹C]PK11195 uptake in the left wrist (left) and the left MTP5 joint (right). MTP: metatarsophalangeal.

Table 2. Average SUVs in individual and groups of joints, divided into joints visually negative and visually positive on PET.

| Joint | Average SUV for Joints Visually Negative on PET | Joints Visually Negative on PET, n | Average SUV for Joints Visually Positive on PET | Joints Visually Positive on PET, n | P |
|----------------|---|------------------------------------|---|------------------------------------|--------|
| Shoulders | 2.1 ± 0.9 | 67 | 2.4 ± 0.3 | 3 | 0.67 |
| Elbows | 1.1 ± 0.3 | 70 | NA | 0 | NA |
| Wrists | 0.8 ± 0.3 | 44 | 1.0 ± 0.3 | 26 | < 0.01 |
| MCP1 joints | 0.6 ± 0.2 | 64 | 0.9 ± 0.2 | 6 | < 0.01 |
| MCP2, 5 joints | 0.5 ± 0.2 | 264 | 0.8 ± 0.2 | 16 | < 0.01 |
| PIP joints | 0.4 ± 0.2 | 309 | 0.7 ± 0.2 | 41 | < 0.01 |
| Hips | 2.5 ± 0.8 | 70 | NA | 0 | NA |
| Knees | 1.1 ± 0.6 | 66 | 1.4 ± 0.4 | 4 | 0.48 |
| Ankles | 0.7 ± 0.3 | 63 | 1.4 ± 0.3 | 7 | < 0.01 |
| MTP1 joints | 0.6 ± 0.3 | 52 | 1.1 ± 0.3 | 18 | < 0.01 |
| MTP2, 5 joints | 0.6 ± 0.3 | 230 | 1.0 ± 0.3 | 50 | < 0.01 |

Values are mean ± SD. MCP: metacarpophalangeal; MTP: metatarsophalangeal; NA: not applicable; PET: positron emission tomography; PIP: proximal interphalangeal; SUV: standardized uptake value.

PET outcome of the feet showed the best correspondence with disease activity at the patient level.

Several studies have shown the feasibility of whole-body PET to assess disease activity in patients with RA.^{12,21-26} Most studies have used FDG as tracer, which is sensitive but not specific for imaging arthritis. Some studies have looked only at visually enhanced uptake, whereas in other studies, quantitative analyses were performed. The tracer used in this study targets macrophages and is thus more specific for arthritis.¹⁵ In addition, both visual and quantitative analyses of an extensive number of joints, including all MTP joints, were explored.

Although some previous FDG studies^{23,25} have described a correlation between visual PET data and clinical disease activity measures at a patient level, poor correlations were described at a joint level.²⁵ In the present study, visual assessment of PET positivity and clinical findings in individual joints showed κ values between visual PET and clinical data of < 0.40, which correspond with those of Fosse et al.²⁵ The discordance between PET and clinical findings may appear disappointing at first sight but could also indicate added value of PET. Previously, it has been shown that (R)-[¹¹C]PK11195 uptake can precede clinical arthritis in patients at risk of RA or in remission.^{17,27} Visual analysis depends

Table 3. Average SUV in groups of joints, divided into swollen and nonswollen and tender and nontender joints.

| Joint | Average SUV for Nonswollen Joints | Average SUV for Swollen Joints | <i>P</i> | Average SUV for Nontender Joints | Average SUV for Tender Joints | <i>P</i> |
|----------------|-----------------------------------|--------------------------------|----------|----------------------------------|-------------------------------|----------|
| Shoulders | 2.1 ± 0.9 | 1.6 ± 0.3 | 0.23 | 2.1 ± 0.9 | 2.4 ± 1.3 | 0.65 |
| Elbows | 1.1 ± 0.3 | 1.0 ± 0.3 | 0.32 | 1.1 ± 0.4 | 1.0 ± 0.2 | 0.09 |
| Wrists | 0.8 ± 0.3 | 1.0 ± 0.3 | 0.08 | 0.9 ± 0.3 | 0.9 ± 0.3 | 0.40 |
| MCP1 joints | 0.5 ± 0.2 | 0.7 ± 0.2 | < 0.01 | 0.6 ± 0.2 | 0.8 ± 0.2 | < 0.01 |
| MCP2, 5 joints | 0.4 ± 0.2 | 0.6 ± 0.2 | < 0.01 | 0.4 ± 0.2 | 0.6 ± 0.2 | < 0.01 |
| PIP joints | 0.4 ± 0.2 | 0.6 ± 0.2 | < 0.01 | 0.4 ± 0.2 | 0.5 ± 0.2 | 0.04 |
| Hips | 2.5 ± 0.8 | NA | NA | 2.5 ± 0.8 | 2.5 | NA |
| Knees | 1.1 ± 0.6 | 1.3 ± 0.7 | 0.41 | 1.1 ± 0.6 | 1.3 ± 0.6 | 0.42 |
| Ankles | 0.7 ± 0.3 | 1.3 ± 0.5 | 0.04 | 0.7 ± 0.3 | 1.2 ± 0.6 | 0.09 |
| MTP1 joints | 0.7 ± 0.3 | 1.3 ± 0.5 | < 0.01 | 0.6 ± 0.3 | 0.8 ± 0.4 | 0.11 |
| MTP2, 5 joints | 0.6 ± 0.3 | 0.8 ± 0.4 | 0.03 | 0.6 ± 0.3 | 0.8 ± 0.4 | < 0.01 |

Values are mean ± SD. MCP: metacarpophalangeal; MTP: metatarsophalangeal; NA: not applicable; PIP: proximal interphalangeal; SUV: standardized uptake value.




Figure 2. Boxplot figures of SUV values in ankles (left), MTP1 joints (middle), and MTP2 to MTP5 joints (left) that were clinically unaffected or swollen. MTP: metatarsophalangeal; SUV: standardized uptake value.

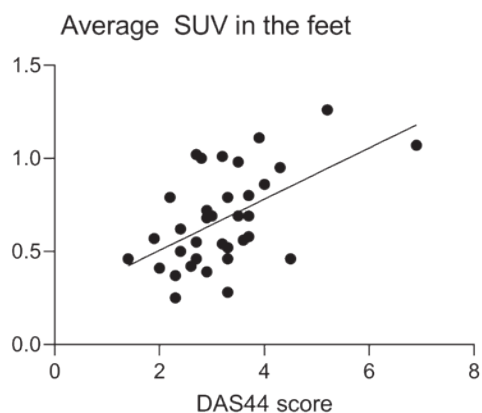


Figure 3. Correlation of the average SUV in the feet with the DAS44 score. DAS44: Disease Activity Score in 44 joints; SUV: standardized uptake value.

on the expertise of the reader(s) and is limited by a relatively high intraobserver coefficient of variation in smaller joints.²³ In theory, quantitative PET data may provide more accurate measures of tracer uptake than visual analysis. By including both visual and quantitative analysis in this study, it was possible to demonstrate that quantitative PET assessments indeed outperformed visual PET assessments with respect to agreement and correlation with clinical findings. Quantitative assessment of

42 joints per patient is labor intensive. In the future, however, the development of artificial intelligence methods may automate this assessment and facilitate implementation of quantitative PET in clinical practice. Based on the results of this study, macrophage PET could have clinical value for early assessment of (changes in) disease activity to enable early diagnosis and early assessment of treatment outcome response. However, validation in additional longitudinal cohorts is necessary before this could be implemented in clinical practice.

In the present cohort, most PET positivity was seen in small hand and feet joints, with only low incidence in large joints such as hips, shoulders, elbows, and knees. Other than inclusion of MTP1 by Beckers et al,²³ no previous studies have included MTP joints. The pattern of inflammation found in the present study corresponds with the typical clinical presentation of early RA in small hand and feet joints, although large joints may also be involved, in particular in more severe RA.²⁸ Since quantitative PET outcomes of the feet and hands groups each corresponded most with clinical disease activity at patient level, future studies should investigate whether PET imaging can be limited to a scanning protocol of feet or hands alone. A simplified scanning protocol of only feet or hands could allow for faster scanning and lower radiation dose for patients.

There are some limitations to this study. First, the limited involvement of large joints in this cohort of patients limits the assessment of the value of PET scanning of these joints. Second,

the patients included had, on average, moderate disease activity, potentially affecting the correlation with imaging. Third, although macrophage tracers are more specific for arthritis than FDG, (R)-[¹¹C]PK11195 still shows high periarticular background uptake that negatively affects specificity,^{15,16} which may be improved by using second-generation macrophage tracers.^{14,27} Fourth, the measure for visual tracer uptake, assessed as “none,” “low,” “moderate,” or “high” by the readers, is subjective in nature. Future studies should further focus on development of more objective classification of the intensity of the visual tracer uptake. Fifth, in-depth analysis of the best PET measure to assess disease activity was not included in the current study set-up as it was outside the scope of this paper. This analysis should be performed in future studies for further evaluation toward potential clinical application. In the current analysis, “average whole-body SUV” was selected as a measure for PET activity in the whole body because the closest representation of visual PET positivity was found when using average whole-body SUV as a summary measure, as compared to summation, median, and maximum. Additionally, this measure showed the least outliers. Finally, positioning of the hand joints may need further improvement. To minimize discomfort, hands were positioned with fingers semiflexed in a vacuum pouch on the abdomen, but this still allowed for small movements and is therefore not optimal for accurate delineation of tracer uptake.

Whole-body macrophage PET imaging in patients with early RA showed clear uptake of (R)-[¹¹C]PK11195 in multiple joints, and specifically in the feet. Correlations with clinical arthritis were modest both at joint and the whole-body level, but with quantitative PET data outperforming visual scoring. These findings should stimulate future studies using second-generation macrophage tracers.

ACKNOWLEDGMENT

We would like to thank Stefan Bruijnen for his help in establishing the study protocol, Judith van Es for all of her time and effort in planning the PET/CT scans, and Linda Rasch, Samina Turk, and Ewa Platek for excellent patient care.

ONLINE SUPPLEMENT

Supplementary material accompanies the online version of this article.

REFERENCES

- Smolen JS, Aletaha D, McInnes IB. Rheumatoid arthritis. *Lancet* 2016;388:2023-38.
- McWilliams DF, Marshall M, Jayakumar K, et al. Erosive and osteoarthritic structural progression in early rheumatoid arthritis. *Rheumatology* 2016;55:1477-88.
- Fransen J, van Riel PL. The Disease Activity Score and the EULAR response criteria. *Clin Exp Rheumatol* 2005;23 Suppl 39:S93-9.
- Orozco C, Olsen NJ. Identification of patients with early rheumatoid arthritis: challenges and future directions. *Clin Dev Immunol* 2006;13:295-7.
- Di Matteo A, Mankia K, Azukizawa M, Wakefield RJ. The role of musculoskeletal ultrasound in the rheumatoid arthritis continuum. *Curr Rheumatol Rep* 2020;22:41.
- Nozaki Y, Ri J, Sakai K, et al. Prediction of therapeutic responses with ultrasonography in RA patients treated with an anti-TNF drug: a retrospective cohort study. *Immunol Med* 2018;41:129-35.
- Cheung PP, Dougados M, Gossec L. Reliability of ultrasonography to detect synovitis in rheumatoid arthritis: a systematic literature review of 35 studies (1,415 patients). *Arthritis Care Res* 2010;62:323-34.
- Wouters F, Matthijssen X, Boeters DM, Ten Brinck RM, Van Der Helm-Van Mil A, Niemantsverdriet E. Do magnetic resonance imaging-detected erosions predict progression to rheumatoid arthritis in patients presenting with clinically suspect arthralgia? A longitudinal study. *Scand J Rheumatol* 2020;49:461-7.
- Roivainen A, Hautaniemi S, Möttönen T, et al. Correlation of 18F-FDG PET/CT assessments with disease activity and markers of inflammation in patients with early rheumatoid arthritis following the initiation of combination therapy with triple oral antirheumatic drugs. *Eur J Nucl Med Mol Imaging* 2013;40:403-10.
- Gent YY, ter Wee MM, Voskuyl AE, et al. Subclinical synovitis detected by macrophage PET, but not MRI, is related to short-term flare of clinical disease activity in early RA patients: an exploratory study. *Arthritis Res Ther* 2015;17:266.
- Jones T, Townsend D. History and future technical innovation in positron emission tomography. *J Med Imaging* 2017;4:011013.
- Kubota K, Ito K, Morooka M, et al. Whole-body FDG-PET/CT on rheumatoid arthritis of large joints. *Ann Nucl Med* 2009;23:783-91.
- Elzinga EH, van der Laken CJ, Comans EF, et al. 18F-FDG PET as a tool to predict the clinical outcome of infliximab treatment of rheumatoid arthritis: an explorative study. *J Nucl Med* 2011;52:77-80.
- Bruijnen ST, Verweij NJ, Gent YY, et al. Imaging disease activity of rheumatoid arthritis by macrophage targeting using second generation translocator protein positron emission tomography tracers. *PLoS One* 2019;14:e0222844.
- van der Laken CJ, Elzinga EH, Kropholler MA, et al. Noninvasive imaging of macrophages in rheumatoid synovitis using 11C-(R)-PK11195 and positron emission tomography. *Arthritis Rheum* 2008;58:3350-5.
- Gent YY, Voskuyl AE, Kloet RW, et al. Macrophage positron emission tomography imaging as a biomarker for preclinical rheumatoid arthritis: findings of a prospective pilot study. *Arthritis Rheum* 2012;64:62-6.
- Gent YY, Ahmadi N, Voskuyl AE, et al. Detection of subclinical synovitis with macrophage targeting and positron emission tomography in patients with rheumatoid arthritis without clinical arthritis. *J Rheumatol* 2014;41:2145-52.
- Tenten-Diepenmaat M, van der Leeden M, Vliet Vlieland TP, Dekker J; RA Foot Expert Group. Multidisciplinary recommendations for diagnosis and treatment of foot problems in people with rheumatoid arthritis. *J Foot Ankle Res* 2018;11:37.
- Aletaha D, Neogi T, Silman AJ, et al. 2010 Rheumatoid arthritis classification criteria: an American College of Rheumatology/ European League Against Rheumatism collaborative initiative. *Arthritis Rheum* 2010;62:2569-81.
- Boellaard R, Hoekstra OS, Lammertsma AA. Software tools for standardized analysis of FDG whole body studies in multi-center trials. *J Nucl Med* 2008;49 Suppl 1:159P.
- Goerres GW, Forster A, Uebelhart D, et al. F-18 FDG whole-body PET for the assessment of disease activity in patients with rheumatoid arthritis. *Clin Nucl Med* 2006;31:386-90.
- de Groot M, Patel N, Manavaki R, et al. Quantifying disease activity in rheumatoid arthritis with the TSPO PET ligand 18F-GE-180 and comparison with 18F-FDG and DCE-MRI. *EJNMMI Res* 2019;9:113.
- Beckers C, Ribbens C, André B, et al. Assessment of disease activity in rheumatoid arthritis with (18)F-FDG PET. *J Nucl Med* 2004;45:956-64.

24. Raynor WY, Jonnakuti VS, Zirakchian Zadeh M, et al. Comparison of methods of quantifying global synovial metabolic activity with FDG-PET/CT in rheumatoid arthritis. *Int J Rheum Dis* 2019;22:2191-8.
25. Fosse P, Kaiser MJ, Namur G, de Seny D, Malaise MG, Hustinx R. ¹⁸F- FDG PET/CT joint assessment of early therapeutic response in rheumatoid arthritis patients treated with rituximab. *Eur J Hybrid Imaging* 2018;2:6.
26. Lee SJ, Jeong JH, Lee CH, et al. Development and validation of an ¹⁸F-fluorodeoxyglucose-positron emission tomography with computed tomography-based tool for the evaluation of joint counts and disease activity in patients with rheumatoid arthritis. *Arthritis Rheumatol* 2019;71:1232-40.
27. Verweij NJ, Yaqub M, Bruijnen ST, et al. First in man study of [¹⁸F] fluoro-PEG-folate PET: a novel macrophage imaging technique to visualize rheumatoid arthritis. *Sci Rep* 2020;10:1047.
28. Linn-Rasker SP, van der Helm-van Mil AH, Breedveld FC, Huizinga TW. Arthritis of the large joints - in particular, the knee - at first presentation is predictive for a high level of radiological destruction of the small joints in rheumatoid arthritis. *Ann Rheum Dis* 2007;66:646-50.