

Toward a Sonographic Composite Index for Diagnosis in Psoriatic Arthritis: Highlights From the GRAPPA Ultrasound Workshop

Sibel Zehra Aydin¹ , Lihi Eder² , and Gurjit S. Kaeley³ 

ABSTRACT. The ability to visualize musculoskeletal structures with high-resolution ultrasound is an asset to understanding the complexity of psoriatic arthritis (PsA). During the 2021 Annual Group for Research and Assessment of Psoriasis and Psoriatic Arthritis (GRAPPA) meeting, 3 topics were presented and discussed in the ultrasound workshop: (1) the progress on the Diagnostic Ultrasound Enthesitis Tool (DUET) project; (2) the sonographic evaluation of joints in PsA–GRAPPA joint project; and (3) extrasynovial lesions in PsA. The ultrasound group aims to develop sonographic tools that are feasible and can be used in standard care to diagnose PsA early. The discussions around these topics will shape the group's work toward developing a composite index to diagnose PsA early.

Key Indexing Terms: GRAPPA, psoriasis, psoriatic arthritis

Introduction

Musculoskeletal (MSK) ultrasound (US) has been increasingly used in the field of psoriatic arthritis (PsA). Numerous studies have been published in the last decade that improve our understanding of the pathogenesis of this disease.^{1,2} Further, advances in PsA have triggered discussions around the prevention of PsA by treating high-risk populations.³ Thus, earlier diagnosis—even detection in the preclinical phase—becomes an essential target in research, putting MSK US in a critical position. With the aim of carrying the bench to the bedside, the Group for Research and Assessment of Psoriasis and Psoriatic Arthritis (GRAPPA) US group is working on developing feasible US tools that will improve the care of patients with psoriatic disease (PsD) in clinical practice that can be easily adopted by physicians. In this article, we summarize the current agenda of the GRAPPA US group to achieve that goal.

Update on the Diagnostic Ultrasound Enthesitis Tool Project

The Diagnostic Ultrasound Enthesitis Tool (DUET) project is a

As part of the supplement series GRAPPA 2021, this report was reviewed internally and approved by the Guest Editors for integrity, accuracy, and consistency with scientific and ethical standards.

¹S.Z. Aydin, MD, Associate Professor of Medicine, University of Ottawa Faculty of Medicine, Rheumatology, The Ottawa Hospital Research Institute, Ottawa, Ontario, Canada; ²L. Eder, MD, PhD, Associate Professor of Medicine, Women's College Research Institute, Department of Medicine, University of Toronto, Toronto, Ontario, Canada; ³G.S. Kaeley, MD, MBBS, MRCP, RbMSUS, Professor of Medicine, University of Florida College of Medicine, Jacksonville, Florida, USA.

The authors declare no conflicts of interest relevant to this article.

This paper does not require institutional review board/animal approval.

Address correspondence to Dr. S.Z. Aydin, 1967 Riverside Drive, Ottawa, ON K1H 7W9, Canada. Email: saydin@toh.ca

Accepted for publication December 9, 2021.

GRAPPA-supported study aiming to create a new sonographic enthesitis tool to distinguish patients with PsA from non-PsA patients and to assess its validity and reliability. This tool should help with the early diagnosis of PsA by identifying enthesitis, an important PsA domain that is difficult to diagnose in physical examination. The DUET study is a multicenter, international study involving 23 sites led by GRAPPA members with US expertise. The study will recruit 200 patients with PsA and 200 controls (100 patients with psoriasis [PsO] without arthritis and 100 patients with noninflammatory rheumatic conditions). US assessment involves the evaluation of 16 enthesal sites for signs of enthesitis. Central reading by 3 sonographers (LE, GSK, SZA) will be performed to reduce variation in scoring. We aim to identify the optimal combination of enthesal sites and sonographic lesions that distinguish patients with PsA from controls (DUET score). Updates regarding the progress of the study were presented during the meeting.

Training materials, including videos demonstrating scanning of the entheses and atlas with definitions of elementary lesions of enthesitis, were developed and are available as open resources.⁴ A virtual training workshop for the study investigators was conducted in September 2020. The workshop included 53 participants from 11 countries. The participants reviewed the study procedures and scanning protocols. An interrater reliability exercise was conducted involving the 3 central readers and showed good agreement among the 3 readers for scoring enthesal sites.⁵ Recruitment of participants to DUET started in March 2021. Thirty-nine participants recruited from 9 active sites were enrolled in the study (as of September 2021). Recruitment of patients for this study continues, with an anticipated interim analysis in July 2022.

Sonographic Evaluation of Joints in PsA — GRAPPA Joint Project
Diagnosing early PsA may help attenuate early morbidity and

joint damage.⁶ Up to 15% of patients with PsO may have undiagnosed PsA,⁷ and subclinical synovitis may be underestimated in early PsA.⁸ Strategies to identify early PsA include patient questionnaires, use of clinical risk factors, and genetic factors. Imaging may improve the sensitivity of detection of early PsA. Longitudinal studies in patients with PsO have suggested that the baseline presence of US signs of synovitis and enthesitis predict the future development of PsA.^{9,10} However, evaluating entheses with advanced imaging may not provide sufficient diagnostic certainty and may underestimate the degree of inflammatory disease burden. Diagnostic tools aid in increasing diagnostic confidence and may also help in making decisions for treatment. Thus, there is a need to include other domains such as synovial structures and the adjacent perienthesal structures.

Difficulties in evaluating joints in PsA include the heterogeneous distribution of synovitis, the presence of erosive and osteoproliferative changes, and confounding with coexisting osteoarthritis.¹¹ Small studies have suggested the frequent prevalence of synovitis at the hand, wrist, knees, and metatarsophalangeal joints.^{12,13} Formal scoring systems range from examining large joints only to an extensive investigation of multiple joints, which may not be feasible in daily practice.^{14,15} There is a need to develop a strategy to examine sentinel or most symptomatic joints as well as a candidate set of joints and their perisynovial structures in patients with PsO to diagnose early evolving PsA. Imaging may also detect early signs of damage at these sites, which may provide prognostic information.

Extrasynovial Lesions in PsA

Within the last 5 years, it has been well recognized that rheumatoid arthritis (RA) leads to more intracapsular inflammation, whereas for PsA, the inflammation is not limited to the capsule and tends to affect the adjacent structures. The literature on the extraarticular domains highlights the importance of several structures, as summarized below.

The small entheses. Most of the literature on enthesitis is based on the large entheses rather than the small entheses.¹⁶ That is most likely due to the relative ease of assessment of the large entheses. The clinical assessment of small entheses is challenging due to their anatomical proximity to the small joints, which are frequently involved in PsA. When a small joint is tender or swollen due to synovitis, it can be difficult to understand the contribution of enthesitis within the same digit. Moreover, enthesitis of the digits may be the only underlying pathology in a patient, whereas the physical examination may lead to mislabeling as joint inflammation. In a previous project in which the aim was to understand explicitly the ability of physical examination to differentiate enthesitis/tendon abnormalities from synovitis of the hand, taking high-resolution US as a gold standard, the agreement between the 2 modalities was found to be very poor for all of these lesions, raising the concern of what does it really mean when there is pain in the hands.¹⁷

There are multiple small entheses within the hands that are relatively easily explorable with high-resolution US, and pathologies have been demonstrated in PsA (Figure 1 and Figure 2); flexor tendon enthesitis, specifically new bone formation at the

insertion, has been shown to differentiate PsA from RA.¹⁸ In another study, the extensor tendon enthesitis was found more often in PsA vs PsO.¹⁹ Another enthesis that captured significant interest among sonographers was the extensor tendon insertion to the distal phalanx. Zabotti et al demonstrated that extensor tendon central slip enthesitis is seen exclusively in early PsA vs RA.²⁰ Also, nail disease has been shown to be related to the adjacent extensor tendon enthesitis.²¹ In addition to the increased prevalence of enthesitis, the latter finding is critical for potentially explaining why nail disease is more frequently associated with PsA.

Flexor mechanism. Both flexor tendons and pulleys play an important role in the function of flexing the fingers. Flexor tenosynovitis is a well-recognized abnormality in PsA. Although it can also be seen in RA, Zabotti et al found that the frequency of flexor tenosynovitis was more common in PsA.²² The increased resolution of the US machines allows for the visualization of structures that could not be easily explored before, and therefore provides new insights into our knowledge of the pathogenesis of PsA. The pulleys are an example of that advancement. Despite the small dimensions of the pulleys, the thickening of the A1 and A2 pulleys can be reliably detected, and was found to be more frequent in patients with PsA than those with RA and healthy people.²³ In another study, the Doppler signals within the pulleys were increased in the setting of dactylitis.²⁴ Therefore, the ability to look at smaller structures other than the joints allows for the appreciation of the extensiveness of inflammation and provides further data on the role of the functional enthesis in the process and testing of the synovio-enthesal complex theory.

Skin and subcutaneous edema. In the study mentioned earlier by Zabotti et al,²⁰ the group was also able to demonstrate that the peritendinous edema is exclusively seen in PsA (compared to RA), which may potentially contribute to patients' stiffness and the inability to flex the fingers fully. In addition to the palmar surface, the epidermal and dermal thickening on the dorsum of the hand has also been shown to be increased in PsA compared to PsO.²¹

The extensor mechanism. Different from the flexor mechanism, the extensor tendon does not have a tendon sheath but is surrounded by a paratenon layer, which can also be inflamed in the setting of PsA. Macía-Villa et al investigated the link between paratenonitis and synovitis vs systemic enthesitis on US and found that it is associated with enthesitis as opposed to synovitis.²⁵

Nail US. This area has been heavily investigated due to clinical nail disease being a predictor of PsA. The high-resolution US can visualize the nail plate as 2 hyperechoic white bands surrounding a well-defined anechoic layer between the trilaminar appearance.²⁶ The abnormalities of the nail can be seen in various ways, including the thickening of the nail plate and the nail bed. In addition, the structural changes within the nail plate can lead to the absence of trilaminar appearance, either due to the thickening of the deeper layer or the lack thereof. Although studies have constantly found more nail lesions in patients with PsA and PsO than in healthy people, and there is a good agreement

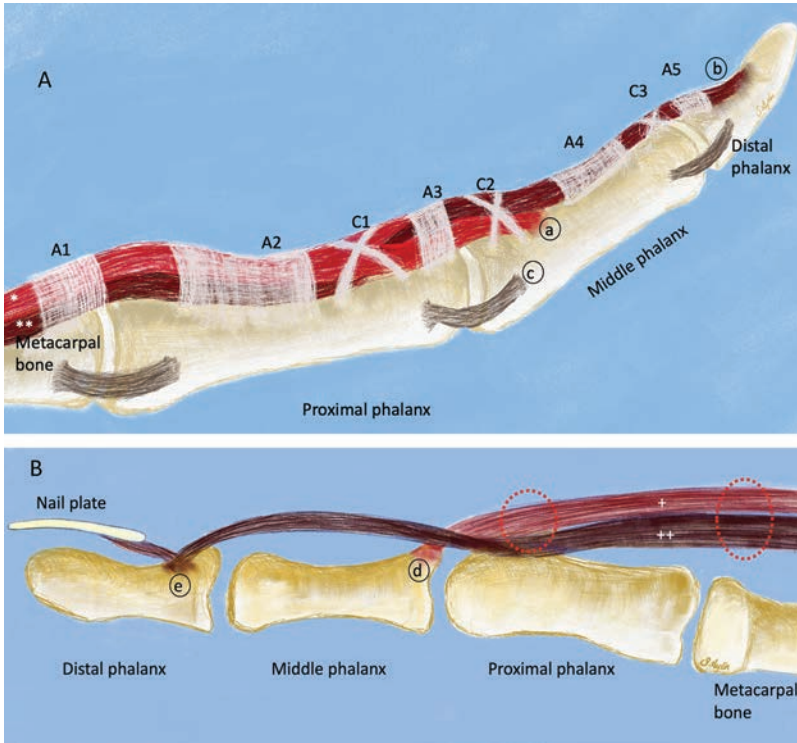


Figure 1. Extrasynovial structures of the hand that can be involved in psoriatic arthritis and can be explored with high-resolution ultrasound. (A) The flexor mechanism and the collateral ligaments of the digits. (B) The extensor mechanism and the nail matrix. Annular pulleys: A1, A2, A3, A4, and A5; cruciate pulleys: C1, C2, and C3. The flexor digitorum superficialis tendon (*) inserts into the middle phalanx (a), whereas the flexor digitorum profundus tendon (**) inserts into the distal phalanx (b). Collateral ligament entheses can also be seen on ultrasound (c). The extensor tendon central slip (+) inserts into the middle phalanx (d), whereas the lateral bands (++) insert into the distal phalanx in anatomical proximity to the nail matrix (e). The paratenonitis is usually seen proximal to the metacarpophalangeal and proximal interphalangeal joints (dashed circles).

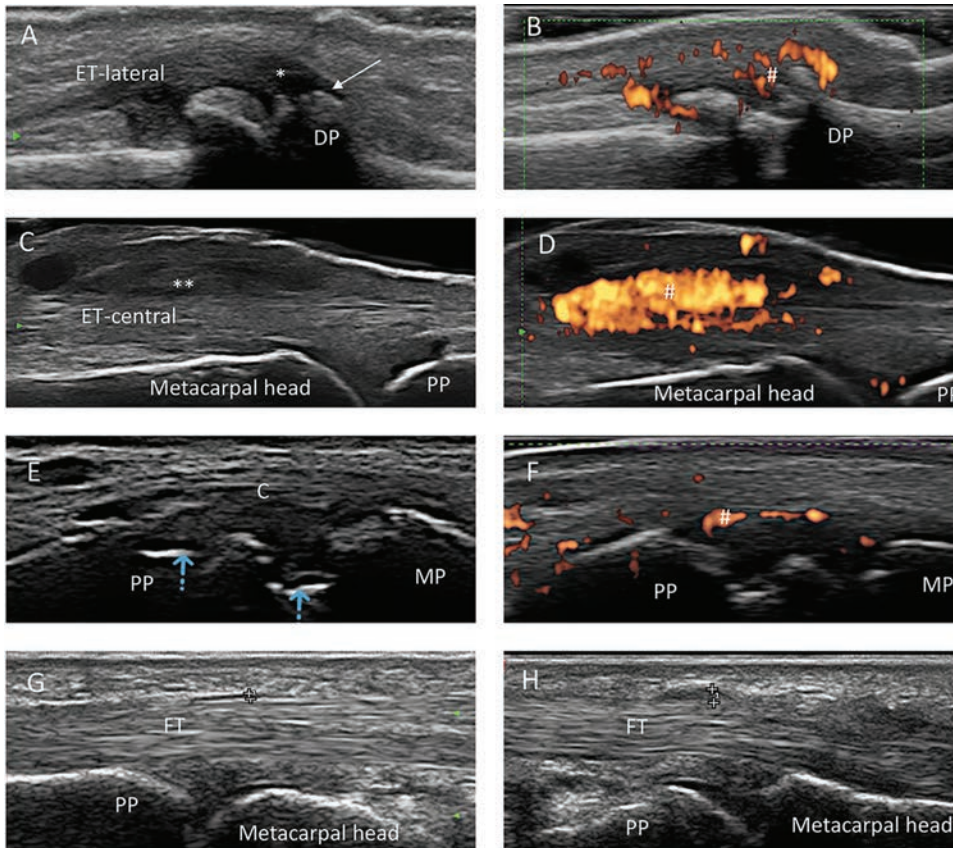


Figure 2. Examples of the extrasynovial lesions seen on ultrasound. Longitudinal ultrasound scans of the digit from (A–D) dorsal, (E–F) lateral, and (G–H) volar surface. (A–B) Hypoechoogenicity and thickening (*) at the extensor tendon lateral bands' insertion to the distal phalanx (DP), enthesophyte (arrow), and enthesal Doppler signals (#). (C–D) Hypoechoogenicity and thickening (**) of the extensor tendon paratenon, proximal to the metacarpal head with Doppler signals (#). (E–F) Erosions at the collateral ligament origins (blue arrows) and Doppler signals (#). (G–H) Normal thickness of the A1 pulley (calipers in panel G) and increased thickness in a patient with PsA (calipers in panel H). Reproduced with permission: C–F: CRUS (Canadian Rheumatology Ultrasound Society) Ultrasonography Guide, Volume 3, (Educational Resources — Canadian Rheumatology Ultrasound Society [crusurc.ca]). G–H: Ilaria Tinazzi, Unità Semplice di Reumatologia, Ospedale Sacro Cuore-Don Calabria Negrar (VR; ilariatinazzi@yahoo.it). C: collateral ligament; DP: distal phalanx; ET-central: extensor tendon central slip; ET-lateral: extensor tendon lateral band; FT: flexor tendon; MP: middle phalanx; PP: proximal phalanx; PsA: psoriatic arthritis.

between the US and the physical exam of the nail, there are also discrepancies between the 2 methods.^{27,28,29} It is unclear whether sonographic data add information beyond what is found in the physical examination of the nails in PsD. The value of detecting Doppler signals on the nail bed on US is also debatable due to the high vasculature of the nail bed in healthy individuals.³⁰

In summary, the extraarticular domains on sonography have been demonstrated to be important in PsA. However, most of the literature differentiates PsA from RA, with limited data on PsA vs PsO with joint pain (eg, early diagnosis). In addition, there is little information on the reliability of detecting these extraarticular lesions, and the individual contributions of these lesions to diagnosis have not been studied.

Recognizing the importance of extraarticular domains in PsA, the GRAPPA US group is proceeding with the development of a diagnostic tool that will incorporate these considerations in the screening of patients. Our starting point for these extraarticular domains will be the hands, because of (1) all of the data on extraarticular domains being available for the hands in the US of patients with PsA, and (2) the importance of having a feasible tool that can be used by a large group of healthcare professionals.

Conclusion

The GRAPPA US group is expanding its horizons beyond enthesitis in identifying early PsA. Including synovial structures and the accompanying perienthesal structures may improve diagnostic confidence and provide correlation with patient symptoms. An estimate of inflammatory burden and signs of damage may provide prognostic information and inform therapeutic choices. The candidate US instrument will need to include structures based on a data-driven approach, and those that are feasible and applicable across a broad clinical setting. Thus, widening the scope of use of US moves us a step closer to the holy grail of efficiently identifying early PsA.

REFERENCES

1. Stober C. Pathogenesis of psoriatic arthritis. *Best Pract Res Clin Rheumatol* 2021;35:101694.
2. Rahmati S, Li Q, Rahman P, Chandran V. Insights into the pathogenesis of psoriatic arthritis from genetic studies. *Semin Immunopathol* 2021;43:221-34.
3. Scher JU, Ogdie A, Merola JF, Ritchlin C. Preventing psoriatic arthritis: focusing on patients with psoriasis at increased risk of transition. *Nat Rev Rheumatol* 2019;15:153-66.
4. Eder L, Kaeley GS, Aydin S. The Diagnostic Ultrasound Enthesitis Tool (DUET) study: development of a sonographic enthesitis score for early diagnosis of psoriatic arthritis. [Internet. Accessed October 25, 2021]. Available from: <https://www.grappanetwork.org/duet-study>
5. Eder L, Aydin S, Kaeley G. The reliability of scoring sonographic enthesal abnormalities – the diagnostic ultrasound enthesitis tool (DUET) study [abstract]. *Arthritis Rheumatol* 2020;72 Suppl 10.
6. Gladman DD, Thavaneswaran A, Chandran V, Cook RJ. Do patients with psoriatic arthritis who present early fare better than those presenting later in the disease? *Ann Rheum Dis* 2011;70:2152-4.
7. Villani AP, Rouzaud M, Sevrain M, et al. Prevalence of undiagnosed psoriatic arthritis among psoriasis patients: systematic review and meta-analysis. *J Amer Acad Dermatol* 2015;73:242-8.
8. Freeston JE, Coates LC, Nam JL, et al. Is there subclinical synovitis in early psoriatic arthritis? A clinical comparison with grey-scale and power Doppler ultrasound. *Arthritis Care Res* 2014;66:432-9.
9. Elnady B, El Shaarawy NK, Dawoud NM, et al. Subclinical synovitis and enthesitis in psoriasis patients and controls by ultrasonography in Saudi Arabia; incidence of psoriatic arthritis during two years. *Clin Rheumatol* 2019;38:1627-35.
10. Faustini F, Simon D, Oliveira I, et al. Subclinical joint inflammation in patients with psoriasis without concomitant psoriatic arthritis: a cross-sectional and longitudinal analysis. *Ann Rheum Dis* 2016;75:2068-74.
11. Rida MA, Chandran V. Challenges in the clinical diagnosis of psoriatic arthritis. *Clin Immunol* 2020;214:108390.
12. Solmaz D, Bakirci S, Al Onazi A, Al Osaimi N, Fahim S, Aydin SZ. Musculoskeletal ultrasound can improve referrals from dermatology to rheumatology for patients with psoriasis. *Br J Dermatol* 2020;182:804-6.
13. Tang Y, Cheng S, Yang Y, et al. Ultrasound assessment in psoriatic arthritis (PsA) and psoriasis vulgaris (non-PsA): which sites are most commonly involved and what features are more important in PsA? *Quant Imaging Med Surg* 2020;10:86-95.
14. Ficjan A, Husic R, Gretler J, et al. Ultrasound composite scores for the assessment of inflammatory and structural pathologies in Psoriatic Arthritis (PsASon-Score). *Arthr Res Ther* 2014;16:1-3.
15. Schäfer VS, Fleck M, Kellner H, et al. Evaluation of the novel ultrasound score for large joints in psoriatic arthritis and ankylosing spondylitis: six month experience in daily clinical practice. *BMC Musculoskelet Disord* 2013;14:358.
16. Kaeley GS, Eder L, Aydin SZ, Gutierrez M, Bakewell C. Enthesitis: a hallmark of psoriatic arthritis. *Semin Arthritis Rheum* 2018; 48:35-43.
17. Gazel U, Solmaz D, Ayan G, Ivory C, Karsh J, Aydin SZ. Accuracy of physical examination to detect synovial and extra-synovial pathologies in psoriatic arthritis in comparison to ultrasonography. *J Clin Med* 2020;9:2929.
18. Tinazzi I, McGonagle D, Zabotti A, Chessa D, Marchetta A, Macchioni P. Comprehensive evaluation of finger flexor tendon enthesal soft tissue and bone changes by ultrasound can differentiate psoriatic arthritis and rheumatoid arthritis. *Clin Exp Rheumatol* 2018;36:785-90.
19. Acosta-Felquer ML, Ruta S, Rosa J, et al. Ultrasound enthesal abnormalities at the distal interphalangeal joints and clinical nail involvement in patients with psoriasis and psoriatic arthritis, supporting the nail-enthesitis theory. *Semin Arthritis Rheum* 2017;47:338-42.
20. Zabotti A, Salvin S, Quartuccio L, De Vita S. Differentiation between early rheumatoid and early psoriatic arthritis by the ultrasonographic study of the synovio-enthesal complex of the small joints of the hands. *Clin Exp Rheumatol* 2016;34:459-65.
21. Aydin SZ, Castillo-Gallego C, Ash ZR, et al. Ultrasonographic assessment of nail in psoriatic disease shows a link between onychopathy and distal interphalangeal joint extensor tendon enthesopathy. *Dermatology* 2012;225:231-5.
22. Zabotti A, Errichetti E, Zuliani F, et al. Early psoriatic arthritis versus early seronegative rheumatoid arthritis: role of dermoscopy combined with ultrasonography for differential diagnosis. *J Rheumatol* 2018;45:648-54.
23. Tinazzi I, McGonagle D, Aydin SZ, Chessa D, Marchetta A, Macchioni P. 'Deep Koebner' phenomenon of the flexor tendon-associated accessory pulleys as a novel factor in tenosynovitis and dactylitis in psoriatic arthritis. *Ann Rheum Dis* 2018;77:922-5.
24. Tinazzi I, McGonagle D, Macchioni P, Aydin SZ. Power doppler enhancement of accessory pulleys confirming disease localization in psoriatic dactylitis. *Rheumatology* 2020;59:2030-4.

25. Macía-Villa C, Falcao S, Gutierrez M, Medina J, Hammer HB, De Miguel E. Peritenon extensor tendon inflammation in psoriatic arthritis is an enthesitis-related lesion. *J Rheumatol* 2019;46:1295-8.
26. Mendonça JA, Aydin SZ, D'Agostino MA. The use of ultrasonography in the diagnosis of nail disease among patients with psoriasis and psoriatic arthritis: a systematic review. *Adv Rheumatol* 2019;59:41.
27. Aydin SZ, Castillo-Gallego C, Ash ZR, et al. Potential use of optical coherence tomography and high-frequency ultrasound for the assessment of nail disease in psoriasis and psoriatic arthritis. *Dermatology* 2013;227:45-51.
28. Sandobal C, Carbó E, Iribas J, Roverano S, Paira S. Ultrasound nail imaging on patients with psoriasis and psoriatic arthritis compared with rheumatoid arthritis and control subjects. *J Clin Rheumatol* 2014;20:21-4.
29. El Miedany Y, El Gaafary M, Youssef S, Ahmed I, Nasr A. Tailored approach to early psoriatic arthritis patients: clinical and ultrasonographic predictors for structural joint damage. *Clin Rheumatol* 2015;34:307-13.
30. Aydin SZ, Castillo-Gallego C, Ash ZR, Marzo-Ortega H, Wakefield R, McGonagle D. Vascularity of nail bed by ultrasound to discriminate psoriasis, psoriatic arthritis and healthy controls. *Clin Exp Rheumatol* 2017;35:872.