

Letter

New-Onset Salt-and-Pepper Skin Changes Associated With Vaccination and Trauma in Systemic Sclerosis: Immunity Matters

To the Editor:

In the recent issue of *The Journal of Rheumatology*, Chung et al¹ reported the associations of perifollicular hypopigmentation with disease subtypes and organ involvement in a systemic sclerosis (SSc) cohort in the United States. Perifollicular hypopigmentation, also termed *salt-and-pepper appearance*, is a typical manifestation in SSc. However, as the authors mentioned,¹ the etiopathogenesis is not well understood and relatively unexplored. Herein, we report 2 interesting cases that shed light on the pathogenesis of salt-and-pepper appearance. This study was approved by the Committee of Renji Hospital, Shanghai, China (ID: 2017[201]). The patients gave written informed consent to publish their case details.

The first case was an Asian woman in her 40s with SSc who developed salt-and-pepper skin changes on her injected arm after influenza vaccination (Figure A). She reported that patches of erythematous swelling appeared soon after she got vaccinated, followed by pruritus and skin color change. The affected areas gradually became thicker. Physical examination showed sclerodactyly and salt-and-pepper appearance on the right arm. Laboratory examinations revealed positive anti-Scl70 antibodies.

The second case was an Asian woman in her 60s with SSc who presented with arc-shaped salt-and-pepper skin changes on the left forearm for a week (Figure B). Her forearm was

burned by moxa sticks when she was performing thunder-fire moxibustion, a form of heat therapy in traditional Chinese medicine (Figure B). When her arm recovered, there appeared an arc-shaped depigmented lesion, fully matching the burned area. Physical examination revealed periungual erythema; skin thickening of hands, neck, and anterior chest; pitting scars on fingertips; and calcific deposits in the left middle finger. Salt-and-pepper appearance was also present on dorsal hands, forehead, neck, clavicles, back, and retroauricular area. Immunologic investigations also revealed positive anti-Scl70 antibodies. Of note, cutaneous fibrosis of the arc-shaped depigmented area was not found at the 1-year follow-up visit.

We present for the first time, to our knowledge, 2 cases of new-onset salt-and-pepper skin changes associated with external factors in patients with SSc. These 2 cases provide insights into the pathogenesis of salt-and-pepper appearance. In case 1, the strong temporal and spatial association between salt-and-pepper appearance and influenza vaccination prompted us to suspect a causal connection. With the activation of cellular and humoral immune factors in SSc, the immunogenic components of the vaccine might have triggered an abnormal immune response that resulted in the destruction of melanocytes. In case 2, the immune system was activated and immune cells were recruited to the wounded area to promote the healing process after tissue injury. Hence, it is likely that the depigmentation in salt-and-pepper appearance arises on an immunological basis. Of note, deposits of IgG and IgM were observed in the depigmented areas in some patients with SSc.²

Intriguingly, a recent study³ reported a case series of effective treatment of salt-and-pepper appearance with mycophenolate mofetil (MMF) in autoimmune sclerosing disease. MMF is a

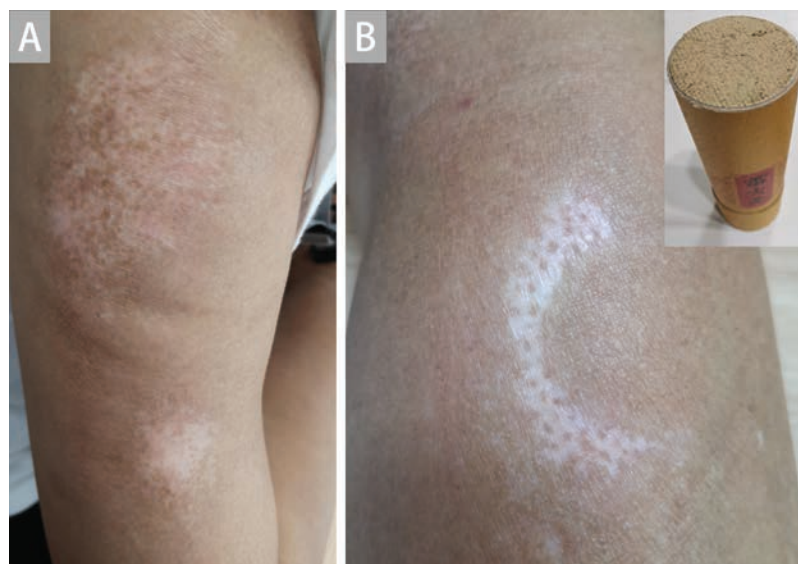


Figure. New-onset salt-and-pepper appearance secondary to vaccination or trauma. (A) Salt-and-pepper skin changes on the injected arm after influenza vaccination. (B) Arc-shaped salt-and-pepper skin changes after being burned by the edge of cylindrical moxa sticks (upper right, inset) during moxibustion treatment.

lymphocyte selective immunosuppressive agent that inhibits de novo purine synthesis, on which T cell and B cell proliferation rely almost solely. MMF was later found to have antifibrotic effects; however, on the molecular level, the therapeutic effect of MMF on skin thickening was paralleled by the reduction of inflammatory gene signatures in the skin.⁴ Therefore, the immunosuppressive effects of MMF likely explained the efficacy. Also, there is another report that suplatast tosilate, a drug that selectively inhibits the T helper type 2 cytokines, showed great efficacy in the treatment of salt-and-pepper skin pigmentation changes.⁵

The current study by Chung et al¹ provided important information that perifollicular hypopigmentation occurred on nonsclerotic skin as well. This finding was mentioned in a case report previously⁶ and applied to our case 2 as well. Hence, it is more likely that salt-and-pepper appearance occurs on an autoimmune basis rather than on a fibrotic basis.

Chung et al argued that perifollicular hypopigmentation also occurred in regions unlikely to experience significant trauma (chest, abdomen).¹ We think it is an interesting question for further exploration; meanwhile, microtrauma caused by friction, pressure, and the like should also be considered.

Salt-and-pepper appearance is strongly associated with diffuse SSc and higher modified Rodnan skin score, and disproportionately affects people with skin of color. In White people, the contrast between depigmented and normal skin may be minimal due to the light skin. However, it is a major aesthetic problem to people with darker skin.^{7,8} Despite this fact, salt-and-pepper appearance is rarely included in clinical studies or basic research. Hence, we applaud the efforts of the authors to thrust it into the limelight. Our cases provide clues that external factors such as trauma and inflammation might contribute to the genesis of salt-and-pepper appearance under the aberrant immune microenvironment in individuals with SSc. Actually, many interesting questions regarding salt-and-pepper appearance are waiting to be answered. One example is the “sparing phenomenon,” in which pigment can be preserved in perifollicular areas, over the superficial veins,⁹ or in skin creases and folds.¹⁰ More studies are warranted, and we believe the investigation into this unique finding would certainly advance our knowledge of SSc pathogenesis.

Hanlin Yin¹ , MD

Liangjing Lu¹ , MD, PhD

¹Department of Rheumatology, Renji Hospital, Shanghai Jiao Tong University School of Medicine, Shanghai, China.

The authors declare no conflicts of interest relevant to this article.

Address correspondence to Dr. L. Lu, Department of Rheumatology, Renji Hospital, Shanghai Jiao Tong University School of Medicine, Shanghai, China, 145 Middle Shandong Rd, Shanghai 200001, China.

Email: lu_liangjing@163.com.

ACKNOWLEDGMENT

We thank the patients for participating in our case presentation. We also thank Ruonan She, MD (Longhua District People's Hospital, Shenzhen, China), for her assistance in the work.

REFERENCES

1. Chung MP, Mecoli CA, Perin J, Richardson C, McMahan ZH. Perifollicular hypopigmentation in systemic sclerosis: associations with clinical features and internal organ involvement. *J Rheumatol* 2022;49:475-81.
2. Sánchez JL, Vázquez M, Sánchez NP. Vitiligo-like macules in systemic scleroderma. *Arch Dermatol* 1983;119:129-33.
3. Min MS, Mazori DR, Kassamali B, et al. Treatment with mycophenolate mofetil for salt-and-pepper dyspigmentation caused by autoimmune sclerosing disease. *JAMA Dermatol* 2022; 158:327-9.
4. Hinchcliff M, Toledo DM, Taroni JN, et al. Mycophenolate mofetil treatment of systemic sclerosis reduces myeloid cell numbers and attenuates the inflammatory gene signature in skin. *J Invest Dermatol* 2018;138:1301-10.
5. Fujimoto N, Hamaguchi Y, Tanaka T. Vitiligo-like depigmentation with perifollicular pigment retention in systemic sclerosis treated successfully with suplatast tosilate. *Eur J Dermatol* 2016;26:110-2.
6. De Villiers WJS, Jordaan HF, Bates W. Systemic sclerosis sine scleroderma presenting with vitiligo-like depigmentation and interstitial pulmonary fibrosis. *Clin Exp Dermatol* 1992;17:127-31.
7. Jewett LR, Kwakkenbos L, Carrier ME, et al. Examination of the association of sex and race/ethnicity with appearance concerns: a Scleroderma Patient-centered Intervention Network (SPIN) cohort study. *Clin Exp Rheumatol* 2016;34 Suppl 100:92-9.
8. Nusbaum JS, Gordon JK, Steen VD. African American race associated with body image dissatisfaction among patients with systemic sclerosis. *Clin Exp Rheumatol* 2016;34 Suppl 100:70-3.
9. Yin H, Lu L. Salt-and-pepper appearance with supravenuous pigment retention in systemic sclerosis. *Clin Exp Dermatol* 2022 Mar 9 (Epub ahead of print).
10. Ghosh SK, Mondal S. Sparing phenomenon in salt and pepper pigmentation of systemic sclerosis: an unusual observation. *Clin Exp Dermatol* 2022;47:967-9.