

Case Report

Clinical and Radiological Remission of Osteoarticular and Cutaneous Lesions in SAPHO Patients Treated With Secukinumab: A Case Series

SAPHO (synovitis, acne, pustulosis, hyperostosis, and osteitis) syndrome is a rare chronic inflammatory disease involving bone, joints, and skin¹. No consensus has been reached on the treatment of SAPHO syndrome and the current options may lead to variable outcomes². Secukinumab, an antiinterleukin (IL)-17A monoclonal antibody, is a promising novel biologic approved for plaque psoriasis, psoriatic arthritis, and ankylosing spondylitis (AS)³. Only a few cases on the use of secukinumab in SAPHO syndrome were reported and have not yielded a unified conclusion⁴.


To further clarify the efficacy of secukinumab in SAPHO syndrome, we report here a case series of 4 patients from our single-center dynamic cohort of SAPHO syndrome (a permanently open cohort continuously accumulating patients)⁵. All 4 patients were treated with 24-week secukinumab (150 mg subcutaneous once weekly for 4 wks and every 4 wks thereafter), without concomitant nonsteroidal antiinflammatory drugs (NSAIDs), conventional synthetic disease-modifying antirheumatic drugs (csDMARDs), or other biologics. Their clinical conditions, skin lesions, and the whole-body magnetic resonance imaging (MRI) before and after treatment were prospectively collected and evaluated as the preliminary result of a clinical trial, which prematurely ceased due to the outbreak of the coronavirus disease 2019 (COVID-19; caused by SARS-CoV-2). The original clinical trial was registered in the Chinese Clinical Trial Register (ChiCTR1900028064; Supplementary Data 1, available with the online version of this article). Written informed consent was obtained from all patients. The study was approved by the Ethics Committee of Peking Union Medical College Hospital, Peking Union Medical College and Chinese Academy of Medical Sciences (S-K1316), and was conducted in accordance with the principles of the Declaration of Helsinki.

The osteitis revealed by bone marrow edema (BME) on MRI and the severity of skin lesions were assessed by radiologists and dermatologists blinded to the therapeutic and clinical information. The change of BME at each site was evaluated as follows: (1) complete resolution (disappearance of BME); (2) significant ($\geq 50\%$) remission; (3) partial ($< 50\%$) remission; (4) stable (no change); and (5) deterioration. Two independent readers were involved in the MRI evaluation and a third reader was responsible for adjudication.

There were 3 tumor necrosis factor inhibitor (TNFi)-naïve patients with insufficient response to NSAIDs, and 1 difficult-to-treat case who was refractory to NSAIDs, csDMARDs, and TNFi (Table 1). All 4 patients had skin involvement and were at very high disease activity before the treatment (visual analog score [VAS] ≥ 6 , AS Disease Activity Score based on C-reactive protein [ASDAS-CRP] ≥ 3.5). Their whole-body MRI revealed osteitis at multiple sites of the anterior chest wall and axial skeleton, which were consistent with their clinical manifestations and results of whole-body bone scintigraphy. After the 24-week treatment, they had achieved significant and comprehensive disease remission, evidenced by the improvement in osteoarticular manifestations (VAS, Bath AS Disease Activity Index [BASDAI], ASDAS-CRP), physical function (Bath AS Functional Index, Health Assessment Questionnaire for the Spondylarthropathies), cutaneous manifestations (Palmoplantar Pustulosis Area and Severity Index, Palmoplantar Pustulosis Severity Index, and Psoriasis Area and Severity Index), quality of life (AS Quality of Life questionnaire, EuroQol 5 dimensions questionnaire, Medical Outcomes Study 36-item Short Form survey), inflammatory markers (erythrocyte sedimentation rate, high-sensitivity CRP), and biochemical marker for bone metabolism (C-terminal telo-

peptide of β -I collagen; Figure 1; Supplementary Table 1, Supplementary Figures 1–5, available with the online version of this article). Almost all the BME on MRI exhibited remarkable alleviation or even complete resolution after the treatment, and no deterioration or new lesions were observed (Table 1, Supplementary Figures 6–9). For adverse events, 3 patients complained of infections, including otitis media, tonsillitis, herpes zoster, and fungal external otitis. Dyslipidemia was recorded in 1 patient. No severe adverse events were observed.

This is currently the largest case series of secukinumab treatment in SAPHO syndrome, to our knowledge. Our study showed that secukinumab has the potential to induce comprehensive remission of both osteoarticular and cutaneous lesions in SAPHO syndrome. First described in 1987, SAPHO syndrome has been associated with the dysregulation of multiple immune cells and proinflammatory cytokines⁶, including T helper 17 and the related IL-23/IL-17 axis⁷. However, IL-17A blockade with secukinumab is only reported in a few cases of SAPHO syndrome and the efficacy remains controversial⁴. It is hard to integrate the existing case reports because of significant heterogeneities in the characteristics of patients, the dose and duration of treatment, and the efficacy evaluation methods. Further, there is almost no radiological evaluation included. Our study provided more convincing evidence by systematically evaluating the outcomes of osteoarticular and cutaneous lesions in patients with comparable features and backgrounds after receiving the same treatment regimen of secukinumab. Further, by using whole-body MRI, our results first showed the remarkable radiological remission of multifocal osteitis in SAPHO patients in response to secukinumab. Because SAPHO syndrome is characterized by repeated episodes of remission and recurrences, effective suppression of the multifocal osteitis might symbolize deeper disease remission and longer recurrence-free time⁸. Due to its high efficiency and its advantages in identifying early and latent lesions⁹, whole-body MRI might serve as an optimizing solution to the dynamic evaluation of multifocal osteitis in patients with SAPHO. For the safety profile, infection is the major issue in our case series and compared with previous studies, the incidence is even higher during a follow-up period of only 24 weeks¹⁰. Therefore, special attention should be paid to adverse events during the treatment, especially the increased risk of infection. The major limitations of the study are the small sample size, short follow-up period, and lack of information about structural damage. Although the observations are descriptive only, the promising outcomes should encourage further larger prospective studies with extended follow-up periods to confirm the efficacy of secukinumab in refractory SAPHO cases or patients who have high disease activity with skin involvement. If conditions permit, whole-body MRI is recommended to facilitate the evaluation of multifocal osteitis.

Lun Wang¹, MD
Boyuan Sun¹, MD student
Chen Li² , MD

¹Institute of Clinical Medicine, Peking Union Medical College Hospital, Peking Union Medical College and Chinese Academy of Medical Sciences;

²Department of Traditional Chinese Medicine, Peking Union Medical College Hospital, Peking Union Medical College and Chinese Academy of Medical Sciences, Beijing, China.

L. Wang and B. Sun contributed equally to the study.

This work was supported by the CAMS Innovation Fund for Medical Sciences (2017-I2M-3-001) and the National Key Research and Development Program of China (2016YFC0901500).

The authors declare no conflicts of interest.

Address correspondence to Dr. C. Li, Department of Traditional Chinese Medicine, Peking Union Medical College Hospital, Chinese Academy of

ACKNOWLEDGMENT

The authors thank Meiyun Yu, Yanan Zhang, Junqiu Li, and Jianwei Huo from Beijing Hospital of Traditional Chinese Medicine for the assessment of MRI; Zhaohui Li, Li Li, and Feng Li from Peking Union Medical College Hospital for the assessment of skin lesions; Hongli Jing from Peking Union Medical College Hospital for the analysis of bone scintigraphy; and Wen Zhang from Peking Union Medical College Hospital for revising the manuscript.

ONLINE SUPPLEMENT

Supplementary material accompanies the online version of this article.

REFERENCES

- Zimmermann P, Curtis N. Synovitis, acne, pustulosis, hyperostosis, and osteitis (SAPHO) syndrome - a challenging diagnosis not to be missed. *J Infect* 2016;72 Suppl:S106-14.
- Firinu D, Garcia-Larsen V, Manconi PE, Del Giacco SR. SAPHO syndrome: current developments and approaches to clinical treatment. *Curr Rheumatol Rep* 2016;18:35.
- Garcia-Montoya L, Marzo-Ortega H. The role of secukinumab in the treatment of psoriatic arthritis and ankylosing spondylitis. *Ther Adv Musculoskelet Dis* 2018;10:169-80.
- Daoussis D, Konstantopoulou G, Kraniotis P, Sakkas L, Lioussis SN. Biologics in SAPHO syndrome: a systematic review. *Semin Arthritis Rheum* 2019;48:618-25.
- Cao Y, Li C, Xu W, Wu X, Sun X, Zhang W, et al. Spinal and

Table 1. Demographics, clinical features, previous treatments, and outcomes after secukinumab treatment in patients with SAPHO syndrome.

Patient No.	1	2	3	4
Age, yrs/sex	30/F	51/M	49/F	42/F
Disease duration, yrs	0.7	1.0	12.0	4.0
Drug treatment before secukinumab	NSAID	NSAID	TNFi, THD, SASP, and NSAID	NSAID
Follow-up, wks	25.1	25.7	24.6	24.4
Osteoarticular pain	ACW, spine, sacroiliac region, and shoulder	ACW, spine, sacroiliac region, shoulder, and hip	ACW, spine, and shoulder	ACW, spine, sacroiliac region, and shoulder
Lesions revealed by whole-body bone scintigraphy	· Sternum · Anterior rib (R, 6th) · T5, T9, T10 · Sacroiliac joint (R, L) · Pubis (R, L)	· Sternoclavicular joint (R, L) · Anterior rib (L, 1st) · T6-12, L1-5	· Sternoclavicular joint (R) · Sternum, sternal angle · Anterior rib (R, 2nd/3rd/4th; L, 2nd/6th/7th/8th) · L1-5 · MTP joint (L, 1st)	· Sternum · Anterior rib (L, 1st), posterior rib (L, 4th) · T10, T11, L2, L3, L5
Lesions revealed by whole-body MRI	· Sternal angle · T4, T5, T9, T10 · Sacroiliac joint (R)	· Sternoclavicular joint (R, L) · Sternocostal joint (L, 1st) · T5-10, L1-4, S1	· Clavicle (R) · Sternocostal joint (L, 6th) · L5	· Sternocostal joint (L, 1st) · T10, T11, L3, L5
Rash	PPP + nail lesions	PPP + PV + nail lesions	PPP + PV + nail lesions	PPP + PV + nail lesions
Patient-reported osteoarticular outcomes				
VAS50	Yes	No	Yes	Yes
BASDAI50	Yes	Yes	Yes	Yes
ASDAS-MI	Yes	Yes	Yes	Yes
MRI outcomes*	Complete resolution of all lesions	· Sternoclavicular joint (R, L): significant remission · Sternocostal joint (L, 1st): significant remission · T10, L3, L4: complete resolution · T5, T8, L1, L2, S1: significant remission · T6, T7: partial remission · T9: stable	· Clavicle (R): significant remission · Sternocostal joint (L, 6th): complete resolution · L5: significant remission	· Sternocostal joint (R, 1st): significant remission · T10, T11, L3, L5: complete resolution
Rash outcomes	· PPP, alleviation · Nail lesions, aggravation	· PPP, alleviation · PV, alleviation · Nail lesions, stable	· PPP, alleviation · PV, alleviation · Nail lesions, alleviation	· PPP, alleviation · PV, resolution · Nail lesions, alleviation
Adverse events	· Otitis media · Tonsillitis	None	Herpes zoster	· Fungal external otitis · Dyslipidemia

* Complete resolution, significant remission, and partial remission were defined as disappearance, ≥ 50% remission, and < 50% remission of the lesion. ACW: anterior chest wall; ASDAS-MI: Ankylosing Spondylitis Disease Activity Score major improvement ≥ 2.0; BASDAI50: ≥ 50% improvement in Bath Ankylosing Spondylitis Disease Activity Index; MRI: magnetic resonance imaging; MTP: metatarsophalangeal joint; NSAID: nonsteroidal antiinflammatory drugs; PPP: palmoplantar pustulosis; PV: psoriasis vulgaris; SAPHO: synovitis, acne, pustulosis, hyperostosis, and osteitis; SASP: salicylazosulfapyridine; THD: thalidomide; TNFi: tumor necrosis factor inhibitor; VAS50: ≥ 50% improvement in visual analog scale.

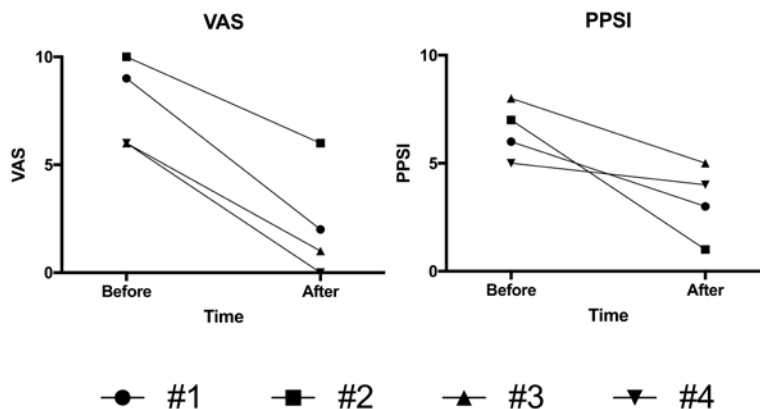


Figure 1. Clinical assessment of osteoarticular pain and skin lesion before and after the 24-week secukinumab treatment. VAS: visual analog scale for osteoarticular pain; PPSI: Palmoplantar Pustulosis Severity Index.

- sacroiliac involvement in SAPHO syndrome: a single center study of a cohort of 354 patients. *Semin Arthritis Rheum* 2019;48:990-6.
- Chamot AM, Benhamou CL, Kahn MF, Beraneck L, Kaplan G, Prost A. [Acne-pustulosis-hyperostosis-osteitis syndrome. Results of a national survey. 85 cases]. [Article in French] *Rev Rhum Mal Osteoartic* 1987;54:187-96.
 - Firinu D, Barca MP, Lorrain MM, Perra S, Cabras S, Muggianu E, et al. Th17 cells are increased in the peripheral blood of patients with SAPHO syndrome. *Autoimmunity* 2014;47:389-94.
 - Leone A, Cassar-Pullicino VN, Casale R, Magarelli N, Semprini A, Colosimo C. The SAPHO syndrome revisited with an emphasis on spinal manifestations. *Skeletal Radiol* 2015;44:9-24.
 - Weckbach S. Whole-body MR imaging for patients with rheumatism. *Eur J Radiol* 2009;70:431-41.
 - Blair HA. Secukinumab: a review in ankylosing spondylitis. *Drugs* 2019;79:433-43.