

# The Dorsal 4-finger Technique: A Novel Method to Examine Metacarpophalangeal Joints in Patients with Rheumatoid Arthritis

Mohammed A. Omair, Pooneh Akhavan, Ali Naraghi, Shikha Mittoo, Juan Xiong, Deborah Weber, Daming Lin, Melissa Weber, and Edward C. Keystone

**ABSTRACT. Objective.** To describe the dorsal 4-finger technique (DFFT) in examining metacarpophalangeal (MCP) joints of patients with rheumatoid arthritis (RA) and compare it to the traditional 2-finger technique (TFT) using ultrasound (US) as a gold standard.

**Methods.** Four rheumatologists evaluated 180 MCP joints of 18 patients with RA. All patients underwent US for greyscale (GSUS) and power Doppler US (PDUS). Agreements between rheumatologists, the 2 techniques, and US were evaluated using Cohen  $\kappa$  and the first-order agreement coefficient (AC1)  $\kappa$  methods.

**Results.** The population comprised 17 females (94.4%) with a mean (SD) age and disease duration of 56.8 (14.4) and 21.8 (12.9) years, respectively. Eight patients (44.4%) were taking methotrexate monotherapy, while 10 patients (55.6%) were receiving biologics. US evaluation revealed 69 (38.3%) and 30 (16.7%) joints exhibited synovitis grade 2–3 by GSUS and PDUS, respectively. Effusion was documented in 30 joints (16.7%). The mean intraobserver agreement using the DFFT and TFT were 80.5% and 86%, respectively. The mean interobserver agreements using the DFFT and TFT were 84% and 74%, respectively.  $\kappa$  agreement with US findings was similar for both techniques in tender joints but was higher for the DFFT in nontender joints (0.33 vs 0.07,  $p = 0.015$  for GSUS) and (0.48 vs 0.11,  $p = 0.002$  for PDUS). The DFFT had a higher sensitivity in detecting ballottement by GSUS (0.47 vs 0.2,  $p < 0.001$ ) and PDUS (0.60 vs 0.27,  $p < 0.001$ ).

**Conclusion.** The DFFT is a novel, reproducible, and reliable method to examine MCP joints, and it has a better correlation with US than the traditional TFT. (First Release January 15 2018; J Rheumatol 2018;45:329–34; doi:10.3899/jrheum.161507)

## Key Indexing Terms:

RHEUMATOID ARTHRITIS  
MUSCULOSKELETAL EXAMINATION

METACARPOPHALANGEAL JOINTS  
ULTRASOUND

*From the Division of Rheumatology, Department of Medicine, College of Medicine, King Saud University, Riyadh, Saudi Arabia; Division of Rheumatology, Department of Medicine, and Division of Musculoskeletal Imaging, Department of Medical Imaging, Mount Sinai Hospital, University of Toronto, Toronto, Ontario, Canada.*

*M.A. Omair, MD, SF Rheum, Division of Rheumatology, Department of Medicine, College of Medicine, King Saud University; P. Akhavan, FRCPC, Division of Rheumatology, Department of Medicine, Mount Sinai Hospital, University of Toronto; A. Naraghi, FRCPC, Division of Musculoskeletal Imaging, Department of Medical Imaging, Mount Sinai Hospital, University of Toronto; S. Mittoo, FRCPC, Division of Rheumatology, Department of Medicine, Mount Sinai Hospital, University of Toronto; J. Xiong, PhD, Division of Rheumatology, Department of Medicine, Mount Sinai Hospital, University of Toronto; D. Weber, RN, Division of Rheumatology, Department of Medicine, Mount Sinai Hospital, University of Toronto; D. Lin, PhD, Division of Rheumatology, Department of Medicine, Mount Sinai Hospital, University of Toronto; M. Weber, RN, Division of Rheumatology, Department of Medicine, Mount Sinai Hospital, University of Toronto; E.C. Keystone, FRCPC, Division of Rheumatology, Department of Medicine, Mount Sinai Hospital, University of Toronto. Dr. Omair and Dr. Akhavan are co-first authors.*

*Address correspondence to Prof. E.C. Keystone, Mount Sinai Hospital, 60 Murray St., Room 2-006, Toronto, Ontario M5T 3L9, Canada.*

*E-mail: Ed.Keystone@sinaihealthsystem.ca*

*Accepted for publication October 12, 2017.*

Joint counts are key elements of outcome measures in rheumatoid arthritis (RA). With the exception of the European League Against Rheumatism (EULAR) 28-joint Disease Activity Score (DAS28)<sup>1,2</sup>, tender and swollen joint counts are given equal weight in other disease activity and response measures, including the Simplified Disease Activity Index<sup>3</sup>, Clinical Disease Activity Index<sup>4</sup>, American College of Rheumatology (ACR) response measures<sup>5</sup>, and Boolean remission criteria<sup>6</sup>. However, the swollen joint count (SJC) remains preeminent, given that it is predictive of structural damage more than the tender joint count<sup>7,8,9,10</sup>. The SJC has also been shown to be more predictive of progression of structural damage in patients near remission than the C-reactive protein (CRP)<sup>8</sup>. A poor correlation between the SJC and CRP suggests that they may be measuring different elements of the pathogenic process in RA<sup>11</sup>. In fact, radiographic progression in patients achieving DAS28 remission appears to be driven by residual swollen joints<sup>12</sup>.

Imaging techniques such as ultrasound (US) and magnetic resonance imaging (MRI) have been shown to be more

sensitive in detecting synovitis than clinical examination<sup>13–18</sup>. Studies have shown a modest correlation between joint swelling and power Doppler US (PDUS) positivity<sup>16</sup>. As might be expected, joint swelling, not joint tenderness, correlated with PDUS positivity<sup>19</sup>. Of importance, PDUS has demonstrated greater predictability of structural damage compared with joint swelling<sup>20,21</sup>. There are some limitations in using US in daily clinical practice<sup>22</sup> and as an outcome measure in clinical trials<sup>23</sup>. Thus, we reasoned that any clinical examination technique to detect joint swelling that improves the correlation between joint swelling and power Doppler positivity would be clinically useful. This would apply particularly to the metacarpophalangeal joints (MCP), which tend to demonstrate erosions early in RA and often lead to significant loss of hand function and disability. Based on these concepts, one of us (ECK) developed a novel 4-finger technique of joint examination to improve the detection of swelling in the MCP. The purpose of our study was to validate this novel clinical examination technique using US.

## MATERIALS AND METHODS

**Clinical assessment.** Our study was carried out by 4 rheumatologists who evaluated joint swelling of 10 MCP joints from 9 patients with RA in random order (2x on the same day, 2 h apart). A second set of 9 different patients was evaluated by the same 4 rheumatologists 2 weeks later. In total, 180 MCP were evaluated in the study. In each joint examination, joint swelling and tenderness by palpation was evaluated. Joint swelling was determined to be ballotable or spongy by the standard 2-finger (TFT) or the dorsal 4-finger (DFFT) technique. A ballotable joint is defined as having a palpable swelling that can be bounced back and forth, while a spongy joint is defined to have a palpable swelling that cannot be mobilized.

Only 1 of the 2 techniques was performed by 2 of the 4 rheumatologists. The technique chosen for our study was the technique used in their clinical practice. ECK trained MO to perform the DFFT. Because we wished to evaluate the techniques as carried out in clinical practice, no standardization of techniques was performed prior to the study.

**Using the TFT.** The TFT was performed by palpating the MCP joint while flexed at about 45°. The medial and lateral side of the joint were palpated simultaneously by the thumbs of each hand to determine its ballotability (Figure 1). If the joint was not ballotable but soft tissue swelling was still felt to be present, the swelling was considered spongy. Both PA and SM used the TFT in our study.

**Using the DFFT.** The DFFT was performed on the MCP using the following steps: The finger is supported by the third to fifth fingers of the examiner's dominant hand (Figure 2A), and then the finger is extended by 45° or the maximum degree of extension possible (Figure 2B). The thumb and index finger of both hands are held on dorsal surface of the MCP and a diamond shape is formed (Figure 2C). Ballotement is then performed using the tips of the 4 fingers (Figure 2D). With the thumb and joints that could not be extended to 45°, the DFFT was performed while the MCP joint was extended to the maximum degree possible.

**US examination.** Within 90 min of the clinical evaluation, all patients underwent US examination by a certified musculoskeletal radiologist blinded to the clinical evaluation. The US examination was performed on all MCP joints with a commercial real-time scanner (Esaote MyLab 70, Biosound) using a multiplanar scale greyscale US (GSUS) and PDUS. Both GSUS and PDUS images were recorded for each joint. Synovitis was defined according to Outcome Measures in Rheumatology (OMERACT) definitions<sup>24,25</sup> as a grade of  $\geq 1$  for GSUS and PDUS mode, separately. Synovitis was scored

on GSUS images using a 0-3 scale, with definitions for each grade as follows: grade 0 (no synovial thickening), and grades 1–3 (mild, moderate, or severe thickening, respectively). For PDUS images a 0-3 scale was also used, where grade 0 showed no signal or intraarticular flow, grade 1 showed mild with signal from 1-2 vessels (including 2 confluent vessels), grade 2 showed moderate vessel confluence accompanying  $< 50\%$  of the normal synovial surface, and grade 3 showed marked vessel confluence accompanying  $> 50\%$  of the normal synovial surface.

**Statistical analysis.** Agreements between examiners and between the TFT and DFFT, as well as the agreement between each technique and US, were examined. To evaluate agreements, US findings were stratified into 2 groups. In GSUS assessment, grades 0 and 1 were considered negative, and the rest positive. In PDUS assessment, grade 0 was considered negative, and the rest positive. Both Cohen  $\kappa$  and the first-order agreement coefficient (AC1)  $\kappa$ , as well as sensitivity, specificity, and positive and negative predictive values were applied to the data to show the degree of agreements.

The study was approved by the Mount Sinai Hospital Research Ethics Board (approval number 12-0077-E).

## RESULTS

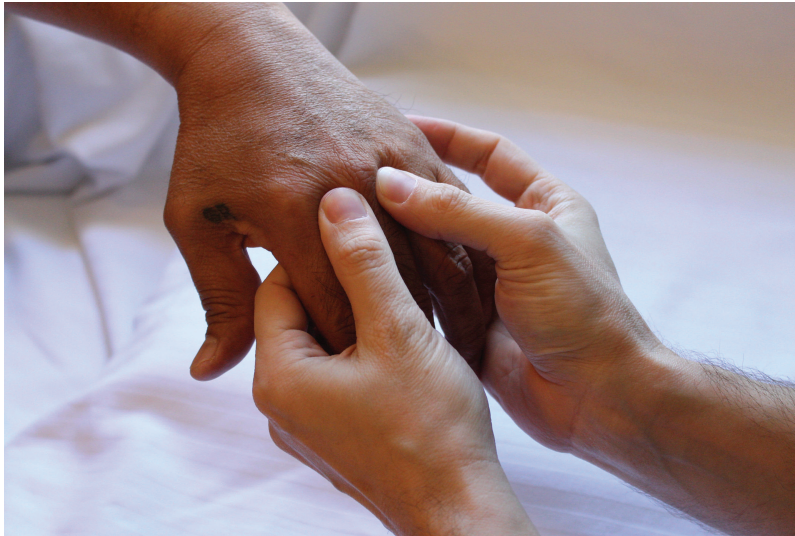**Study population.** The study population consisted of 18 patients with RA who fulfilled the 1987 ACR criteria<sup>26</sup>. The population comprised 17 women (94.4%) with a mean (SD) age and disease duration of 56.8 (14.4) and 21.8 (12.9) years, respectively. Eight patients (44.4%) were receiving methotrexate monotherapy, while 10 patients (55.6%) were receiving biologics monotherapy or combination (Table 1). There was a significant variation in the number of detected inflamed joints among examiners. On average, 49 joints were found to be ballotable (range 14–72), 70 joints were spongy (range 49–86) and 52 were tender (range 49–62).

**Distribution of US findings.** The US findings in the 180 MCP joints evaluated revealed that 95 (52.8%) joints exhibited GSUS synovitis with 69 (38.3%) having grade 2 or 3 on the severity scale; effusions were documented in 30 joints (16.7%). PDUS synovitis was observed in 54 (30%), with 30 (16.7%) exhibiting grade 2 or 3 on the severity scale (Table 1).

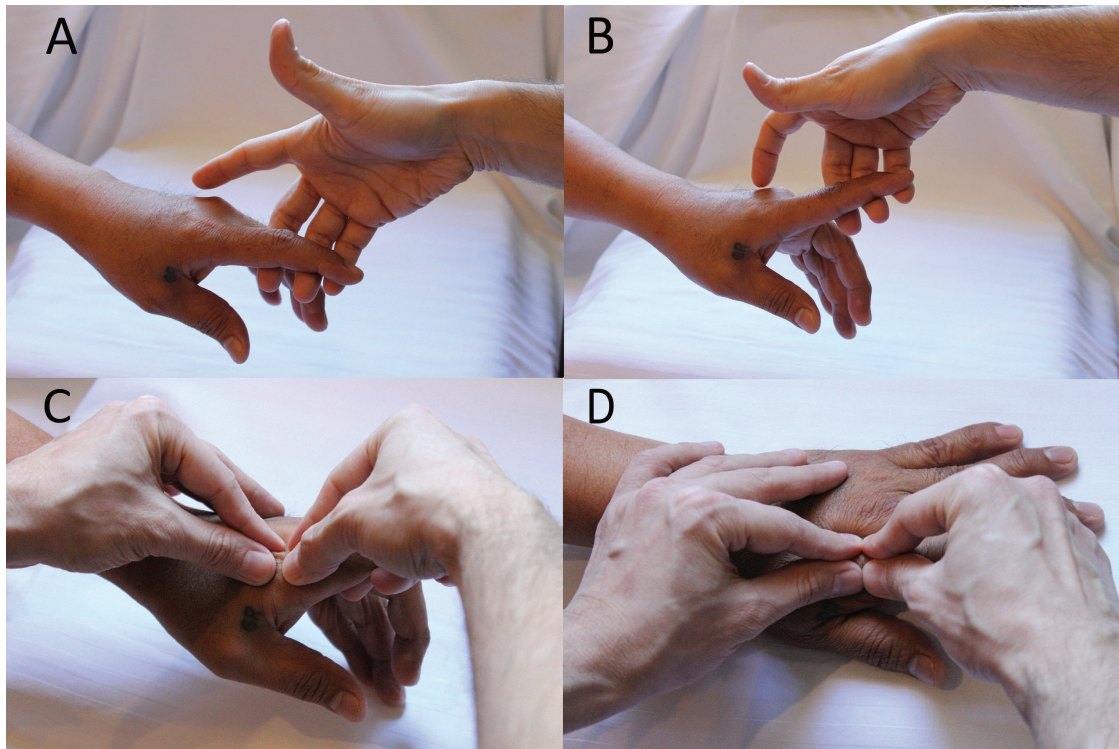
**Intraobserver and interobserver agreement between examiners for ballotement and sponginess.** For the 180 MCP joints evaluated, the mean intraobserver agreement for ballotement using the DFFT and TFT were 80.5% and 86%, respectively. The mean interobserver agreements for ballotement for the DFFT and TFT were (94) 84% and (99) 74%, respectively.

The mean intraobserver agreements for spongy for the DFFT and TFT were 73.5% and 74.5%, respectively. The mean interobserver agreements for spongy for the DFFT and TFT were 75% and 67%, respectively.

**Agreement between clinical and US measures.** Cohen  $\kappa$  agreement between positive ballotement and US findings was greater for the DFFT in both GSUS (0.37 vs 0.19,  $p = 0.078$ ) and PDUS (0.53 vs 0.30,  $p = 0.037$ ). As noted, the clinical finding of ballotement had a stronger agreement with PDUS than GSUS. Ballotement by the DFFT correlated more with positive findings detected by GSUS and PDUS compared to the TFT (Table 2). Both techniques had comparable high specificity in detecting US abnormality when



*Figure 1.* The 2-finger technique was performed by palpating the MCP while flexed at about 45°. The medial and lateral side of the joint were palpated simultaneously by the thumbs of each hand. MCP: metacarpophalangeal joints.



*Figure 2.* The dorsal 4-finger technique is performed on the MCP using the following steps: (A) The finger is supported by the 3rd-5th fingers of the examiner's dominant hand. (B) The finger is extended by 45° or the maximum degree of extension possible. (C) The thumb and index finger of both hands are held on dorsal surface of the MCP. (D) A diamond shape is formed and ballottement is performed using the tip of the 4 fingers. MCP: metacarpophalangeal joints.

joints were determined to be ballotable (Table 2). Similar findings were also observed for the spongy clinical measure with a numerically higher agreement rate with PDUS for the DFFT (39%) compared to the TFT (23%; Table 2).

*Effect of joint tenderness on agreement between clinical and US outcomes.* We next evaluated the influence of joint tenderness on the agreement between joint swelling and the US outcomes. The results showed that ballotable tender joints

Table 1. Demographics and US findings of the study population. Values are n (%) unless otherwise specified.

Variables	Values
Demographics, n = 18	
Age, yrs, mean ± SD	56.8 ± 14.4
Disease duration, yrs, mean ± SD	21.8 ± 12.9
Female	17 (94.4)
Medication	
MTX monotherapy	8 (44.4)
Biologics	10 (55.6)
US findings, n = 180	
GSUS synovitis	95 (52.8)
GSUS synovitis grade 2–3	69 (38.3)
PDUS synovitis	54 (30)
PDUS synovitis grade 2–3	30 (16.7)
Effusion	30 (16.7)

US: ultrasound; GSUS: greyscale US; PDUS: power Doppler US; MTX: methotrexate.

were more likely to be PDUS positive ( $\kappa = 0.63$  for DFFT and 0.49 for TFT) compared to ballotable nontender joints ( $\kappa = 0.48$  for DFFT and 0.11 for TFT) for both techniques. When analyzing ballotability in nontender joints, the DFFT had a better  $\kappa$  agreement with US for both GSUS (0.33 vs 0.07,  $p = 0.015$ ) and PDUS (0.48 vs 0.11,  $p = 0.002$ ). Additionally, the DFFT had a higher sensitivity in nontender joints to detect GSUS (41% vs 6%,  $p = 0.004$ ) and PDUS (53% vs 8%,  $p = 0.004$ ) synovitis. There was no significant difference between both techniques when assessing agreement and sponginess for both tender and nontender joints (Table 3).

## DISCUSSION

Our study evaluated a novel examination technique for MCP joint swelling and assessed its sensitivity for detection and correlation with GSUS and PDUS compared to the traditional TFT. With the increasing use of US and MRI in the daily clinical practice, there has been less emphasis on clinical examination skills by rheumatologists. However, time constraints in a busy clinical practice make it less feasible and cost effective for the rheumatologist to use imaging. We

believe that an improved sensitive technique to detect joint swelling with better US correlation would provide clinicians with more clinically relevant information upon which to base their decisions. This concept is supported by the ability of PDUS and joint swelling to predict structural damage<sup>10,20</sup>. Recently, Gartner, *et al* have shown that clinical inactivity is associated with a low risk of radiographic progression and that silent joint progression occurs in 5.8% of patients<sup>27</sup>. In our study, the DFFT detected more nontender joints. This suggests that in the absence of tenderness, the DFFT might give a more accurate assessment of the activity of the disease and inform treatment decision. To prove this point, a different longitudinal study comparing both techniques as assessment tools of disease activity and guiding treatment change need to be conducted with radiographic progression over time as the primary outcome.

Similar to previously published studies<sup>14,17,28</sup>, our results demonstrated reasonable intraobserver and interobserver agreements between examiners for ballottement, despite the lack of standardization prior to the study. This likely reflected the routine use of these techniques by the examiners in their own clinical practice. Our results demonstrated that agreement between ballotable joint swelling and both GSUS and PDUS using the DFFT was superior to the TFT. Thus, in developing the DFFT, we reasoned that extending the MCP would tighten the flexor tendon and push the soft tissue dorsally to detect ballottement more readily. We assumed that using 4 fingers instead of 2 would be more sensitive in detecting ballottement. Of note, detection of soft tissue swelling or “sponginess” over the joint that was not ballotable correlated to a much lesser extent with US findings. Given that PDUS synovitis is a good predictor of structural joint damage, ballottement of an MCP joint is a clinically relevant finding that would influence clinical decision making. We determined that swollen joints that were tender exhibited the highest likelihood of exhibiting PDUS synovitis. In contrast, tender joints that were not swollen correlated poorly with PDUS synovitis, supporting the concept that only joint swelling, not tenderness, leads to structural damage. Our findings are consistent with those of Szkudlarek, *et al*, who

Table 2. Agreement between clinical findings and US results with pooled assessments of 2 examiners for each physical examination method in 2 rounds.

Clinical Finding	US Technique	Examination Technique	Agreement	Cohen	$\kappa$	AC1	Sensitivity	Specificity	PPV	NPV
Ballottement	GSUS	DFFT	0.73	0.37	0.53	0.47	0.87	0.68	0.75	
		TFT	0.67	0.19	0.48	0.20	0.97	0.79	0.66	
	PDUS	DFFT	0.81	0.53	0.69	0.60	0.90	0.73	0.84	
		TFT	0.77	0.30	0.67	0.27	0.97	0.79	0.77	
Spongy	GSUS	DFFT	0.74	0.43	0.51	0.65	0.78	0.62	0.80	
		TFT	0.68	0.31	0.42	0.49	0.80	0.61	0.72	
	PDUS	DFFT	0.73	0.39	0.51	0.67	0.75	0.53	0.85	
		TFT	0.68	0.23	0.47	0.49	0.76	0.41	0.80	

GSUS: greyscale ultrasound; PDUS: power Doppler ultrasound; DFFT: dorsal 4-finger technique; TFT: 2-finger technique; PPV: positive predictive value; NPV: negative predictive value; US: ultrasound; AC1: first-order agreement coefficient.

Table 3. Agreement between clinical findings and US results in tender and nontender joints.

Clinical Finding	US Technique	Joint Type	Physical Examination Method	Agreement	κ		Sensitivity	Specificity	PPV	NPV
					Cohen	AC1				
Ballottement	Greyscale	Tender	DFFT	0.72	0.41	0.48	0.53	0.86	0.73	0.72
			TFT	0.63	0.27	0.29	0.47	0.80	0.70	0.60
		Nontender	DFFT	0.73	0.33	0.55	0.41	0.89	0.65	0.75
			TFT	0.67	0.07	0.52	0.06	1.00	1.00	0.66
	Doppler	Tender	DFFT	0.83	0.63	0.70	0.69	0.91	0.82	0.84
			TFT	0.77	0.49	0.57	0.64	0.84	0.70	0.80
		Nontender	DFFT	0.81	0.48	0.70	0.53	0.91	0.70	0.84
			TFT	0.76	0.11	0.69	0.08	1.00	1.00	0.76
Spongy	Greyscale	Tender	DFFT	0.70	0.41	0.39	0.86	0.58	0.60	0.85
			TFT	0.65	0.31	0.32	0.77	0.54	0.63	0.70
		Nontender	DFFT	0.74	0.38	0.55	0.53	0.84	0.61	0.79
			TFT	0.69	0.26	0.48	0.38	0.86	0.59	0.72
	Doppler	Tender	DFFT	0.61	0.26	0.22	0.82	0.50	0.45	0.85
			TFT	0.50	0.10	0.01	0.71	0.42	0.31	0.80
		Nontender	DFFT	0.76	0.39	0.60	0.58	0.82	0.54	0.85
			TFT	0.73	0.26	0.58	0.42	0.84	0.45	0.81

DFFT: dorsal 4-finger technique; TFT: 2-finger technique; PPV: positive predictive value; NPV: negative predictive value; US: ultrasound; AC1: first-order agreement coefficient.

showed that joints with swelling and tenderness correlated better with GSUS and PDUS synovitis than tenderness only<sup>15</sup>. Our findings are also consistent with the previous literature on the correlation between joint swelling and PDUS, with the additional finding of the enhanced correlation with tender swollen joints. As with others, we found a lower correlation between GSUS and our clinical findings, compared with PDUS. Salaffi, *et al*<sup>28</sup> found the agreement between joint swelling and US synovitis to be 76.1%, while Le Boedec, *et al*<sup>29</sup> found that the agreement between GSUS synovitis and joint swelling on examination of the first to fifth MCP was lower (0.23–0.41) than for that of PDUS synovitis and joint swelling (0.32–0.49)<sup>29</sup>. Similar to our results with ballotable swollen MCP, Garrigues, *et al*<sup>30</sup> reported that the agreements between GSUS and PDUS synovitis with MCP swelling were 0.47 and 0.51, respectively.

Both US and MRI have been shown to add value for the assessment of synovitis in patients with RA. The EULAR and OMERACT US and MRI working groups have provided important consensus definitions of joint inflammation and damage using these clinical tools<sup>24,31</sup>. The most recent EULAR recommendations on the use of clinical imaging in RA have recommended both tools but have not preferred one over the other<sup>32</sup>. US is more feasible for multijoint scanning in a single setting and is more cost-effective, but it is limited because it is operator-dependent. Studies evaluating MRI and US in patients with RA concluded that both modalities are superior to clinical examination<sup>13,33</sup>. While most studies used MRI as the gold standard, US appears to have a good correlation with MRI and might even be superior in detecting joint and tendon sheath effusions in small joints versus MRI<sup>34</sup>.

Our study suggests that the DFFT is a reliable examination method to examine MCP joints in patients with established RA. These findings need to be validated in early RA and

other forms of inflammatory arthritis. We believe that the DFFT technique is easy to learn and perform. Before disseminating this technique, more studies are required to confirm the current findings from other institutions.

There were several limitations to our study. The sample size was small and MCP joints were examined by only 2 examiners for each technique. Although there was good intraobserver agreement, there was a more modest interobserver variability, likely because of a lack of prior standardization. Moreover, the patients were selected based on availability for the study and not on disease activity. A high proportion of the study population had established RA with predominantly soft tissue swelling rather than effusions.

The DFFT is a novel physical examination technique for detecting MCP joint swelling characterized by ballotability that is more sensitive than the standard TFT detection technique, and it correlates better with US findings.

## REFERENCES

- van der Heijde DM, van 't Hof M, van Riel PL, van de Putte LB. Development of a disease activity score based on judgment in clinical practice by rheumatologists. *J Rheumatol* 1993;20:579-81.
- van Gestel AM, Prevoo ML, van 't Hof MA, van Rijswijk MH, van de Putte LB, van Riel PL. Development and validation of the European League Against Rheumatism response criteria for rheumatoid arthritis. Comparison with the preliminary American College of Rheumatology and the World Health Organization/International League Against Rheumatism Criteria. *Arthritis Rheum* 1996;39:34-40.
- Smolen JS, Breedveld FC, Schiff MH, Kalden JR, Emery P, Eberl G, et al. A simplified disease activity index for rheumatoid arthritis for use in clinical practice. *Rheumatology* 2003;42:244-57.
- Aletaha D, Nell VP, Stamm T, Uffmann M, Pflugbeil S, Machold K, et al. Acute phase reactants add little to composite disease activity indices for rheumatoid arthritis: validation of a clinical activity score. *Arthritis Res Ther* 2005;7:R796-806.

5. Felson DT, Anderson JJ, Boers M, Bombardier C, Furst D, Goldsmith C, et al. American College of Rheumatology. Preliminary definition of improvement in rheumatoid arthritis. *Arthritis Rheum* 1995;38:727-35.
6. Felson DT, Smolen JS, Wells G, Zhang B, van Tuyl LH, Funovits J, et al. American College of Rheumatology/European League Against Rheumatism provisional definition of remission in rheumatoid arthritis for clinical trials. *Arthritis Rheum* 2011;63:573-86.
7. Navarro-Compan V, Gherghe AM, Smolen JS, Aletaha D, Landewe R, van der Heijde D. Relationship between disease activity indices and their individual components and radiographic progression in RA: a systematic literature review. *Rheumatology* 2015; 54:994-1007.
8. Aletaha D, Alasti F, Smolen JS. Rheumatoid arthritis near remission: clinical rather than laboratory inflammation is associated with radiographic progression. *Ann Rheum Dis* 2011;70:1975-80.
9. van Leeuwen MA, van der Heijde DM, van Rijswijk MH, Houtman PM, van Riel PL, van de Putte LB, et al. Interrelationship of outcome measures and process variables in early rheumatoid arthritis. A comparison of radiologic damage, physical disability, joint counts, and acute phase reactants. *J Rheumatol* 1994;21:425-9.
10. Boers M, Kostense PJ, Verhoeven AC, van der Linden S; COBRA Trial Group. Combinatietherapie Bij Reumatoide Artritis. Inflammation and damage in an individual joint predict further damage in that joint in patients with early rheumatoid arthritis. *Arthritis Rheum* 2001;44:2242-6.
11. Keenan RT, Swearingen CJ, Yazici Y. Erythrocyte sedimentation rate and C-reactive protein levels are poorly correlated with clinical measures of disease activity in rheumatoid arthritis, systemic lupus erythematosus and osteoarthritis patients. *Clin Exp Rheumatol* 2008;26:814-9.
12. Aletaha D, Smolen JS. Joint damage in rheumatoid arthritis progresses in remission according to the Disease Activity Score in 28 joints and is driven by residual swollen joints. *Arthritis Rheum* 2011;63:3702-11.
13. Brown AK, Quinn MA, Karim Z, Conaghan PG, Peterfy CG, Hensor E, et al. Presence of significant synovitis in rheumatoid arthritis patients with disease-modifying antirheumatic drug-induced clinical remission: evidence from an imaging study may explain structural progression. *Arthritis Rheum* 2006; 54:3761-73.
14. Szkudlarek M, Klarlund M, Narvestad E, Court-Payen M, Strandberg C, Jensen KE, et al. Ultrasonography of the metacarpophalangeal and proximal interphalangeal joints in rheumatoid arthritis: a comparison with magnetic resonance imaging, conventional radiography and clinical examination. *Arthritis Res Ther* 2006;8:R52.
15. Szkudlarek M, Court-Payen M, Jacobsen S, Klarlund M, Thomsen HS, Ostergaard M. Interobserver agreement in ultrasonography of the finger and toe joints in rheumatoid arthritis. *Arthritis Rheum* 2003;48:955-62.
16. Rees JD, Pilcher J, Heron C, Kiely PD. A comparison of clinical vs ultrasound determined synovitis in rheumatoid arthritis utilizing gray-scale, power Doppler and the intravenous microbubble contrast agent 'Sono-Vue'. *Rheumatology* 2007;46:454-9.
17. Naredo E, Bonilla G, Gamero F, Uson J, Carmona L, Laffon A. Assessment of inflammatory activity in rheumatoid arthritis: a comparative study of clinical evaluation with grey scale and power Doppler ultrasonography. *Ann Rheum Dis* 2005;64:375-81.
18. Tokai N, Ogasawara M, Gorai M, Matsuki Y, Yamada Y, Murayama G, et al. Predictive value of bone destruction and duration of clinical remission for subclinical synovitis in rheumatoid arthritis patients. *Mod Rheumatol* 2015;25:540-5.
19. Ellegaard K, Torp-Pedersen S, Terslev L, Danneskiold-Samsøe B, Henriksen M, Bliddal H. Ultrasound colour Doppler measurements in a single joint as measure of disease activity in patients with rheumatoid arthritis—assessment of concurrent validity. *Rheumatology* 2009;48:254-7.
20. Brown AK, Conaghan PG, Karim Z, Quinn MA, Ikeda K, Peterfy CG, et al. An explanation for the apparent dissociation between clinical remission and continued structural deterioration in rheumatoid arthritis. *Arthritis Rheum* 2008;58:2958-67.
21. Foltz V, Gandjbakhch F, Etchepare F, Rosenberg C, Tanguy ML, Rozenberg S, et al. Power Doppler ultrasound, but not low-field magnetic resonance imaging, predicts relapse and radiographic disease progression in rheumatoid arthritis patients with low levels of disease activity. *Arthritis Rheum* 2012;64:67-76.
22. Delle Sedie A, Riente L, Bombardieri S. Limits and perspectives of ultrasound in the diagnosis and management of rheumatic diseases. *Mod Rheumatol* 2008;18:125-31.
23. Tan YK, Ostergaard M, Conaghan PG. Imaging tools in rheumatoid arthritis: ultrasound vs magnetic resonance imaging. *Rheumatology* 2012;51 Suppl 7:vii36-42.
24. Wakefield RJ, Balint PV, Szkudlarek M, Filippucci E, Backhaus M, D'Agostino MA, et al. Musculoskeletal ultrasound including definitions for ultrasonographic pathology. *J Rheumatol* 2005;32:2485-7.
25. Wakefield RJ, D'Agostino MA, Iagnocco A, Filippucci E, Backhaus M, Scheel AK, et al. The OMERACT Ultrasound Group: status of current activities and research directions. *J Rheumatol* 2007; 34:848-51.
26. Arnett FC, Edworthy SM, Bloch DA, McShane DJ, Fries JF, Cooper NS, et al. The American Rheumatism Association 1987 revised criteria for the classification of rheumatoid arthritis. *Arthritis Rheum* 1988;31:315-24.
27. Gartner M, Sigmund IK, Alasti F, Supp G, Radner H, Machold K, et al. Clinical joint inactivity predicts structural stability in patients with established rheumatoid arthritis. *RMD Open* 2016;2:e000241.
28. Salaffi F, Filippucci E, Carotti M, Naredo E, Meenagh G, Ciapetti A, et al. Inter-observer agreement of standard joint counts in early rheumatoid arthritis: a comparison with grey scale ultrasonography—a preliminary study. *Rheumatology* 2008; 47:54-8.
29. Le Boedec M, Jousse-Joulin S, Ferlet JF, Marhadour T, Chales G, Grange L, et al. Factors influencing concordance between clinical and ultrasound findings in rheumatoid arthritis. *J Rheumatol* 2013;40:244-52.
30. Garrigues F, Jousse-Joulin S, Bouttier R, Nonent M, Bressollette L, Saraux A. Concordance between clinical and ultrasound findings in rheumatoid arthritis. *Joint Bone Spine* 2013;80:597-603.
31. Ostergaard M, Peterfy C, Conaghan P, McQueen F, Bird P, Ejbjerg B, et al. OMERACT Rheumatoid Arthritis Magnetic Resonance Imaging Studies. Core set of MRI acquisitions, joint pathology definitions, and the OMERACT RA-MRI scoring system. *J Rheumatol* 2003;30:1385-6.
32. Colebatch AN, Edwards CJ, Ostergaard M, van der Heijde D, Balint PV, D'Agostino MA, et al. EULAR recommendations for the use of imaging of the joints in the clinical management of rheumatoid arthritis. *Ann Rheum Dis* 2013;72:804-14.
33. Backhaus M, Kamradt T, Sandrock D, Loreck D, Fritz J, Wolf KJ, et al. Arthritis of the finger joints: a comprehensive approach comparing conventional radiography, scintigraphy, ultrasound, and contrast-enhanced magnetic resonance imaging. *Arthritis Rheum* 1999;42:1232-45.
34. Hoving JL, Buchbinder R, Hall S, Lawler G, Coombs P, McNealy S, et al. A comparison of magnetic resonance imaging, sonography, and radiography of the hand in patients with early rheumatoid arthritis. *J Rheumatol* 2004;31:663-75.