

Magnetic Resonance Imaging Bone Edema at Enrollment Predicts Rapid Radiographic Progression in Patients with Early RA: Results from the Nagasaki University Early Arthritis Cohort

Yoshikazu Nakashima, Mami Tamai, Junko Kita, Toru Michitsuji, Toshimasa Shimizu, Shoichi Fukui, Masataka Umeda, Ayako Nishino, Takahisa Suzuki, Yoshiro Horai, Akitomo Okada, Takayuki Nishimura, Tomohiro Koga, Shin-ya Kawashiri, Naoki Iwamoto, Kunihiro Ichinose, Yasuko Hirai, Kazuhiko Arima, Satoshi Yamasaki, Hideki Nakamura, Tomoki Origuchi, Shoichiro Takao, Masataka Uetani, Kiyoshi Aoyagi, Katsumi Eguchi, and Atsushi Kawakami

ABSTRACT. Objective. To clarify whether magnetic resonance imaging (MRI) bone edema predicts the development of rapid radiographic progression (RRP) in the Nagasaki University Early Arthritis Cohort of patients with early-stage rheumatoid arthritis (RA).

Methods. Patients with early-stage RA ($n = 76$) were enrolled and underwent 1.5-T MRI of both wrists and finger joints. Synovitis, bone edema, and bone erosion were evaluated using the Rheumatoid Arthritis Magnetic Resonance Imaging Scoring (RAMRIS). RRP was defined as an annual increment > 3 at 1 year by the Genant-modified Sharp score of plain radiographs. A multivariate logistic regression analysis was performed to establish the risk factors for RRP.

Results. Median disease duration at enrollment was 3 months. RRP was found in 12 of the 76 patients at 1 year. A univariate analysis revealed that matrix metalloproteinase-3, RAMRIS bone edema score, and RAMRIS bone erosion score were associated with RRP. Multivariate logistic regression analyses demonstrated that the RAMRIS bone edema score at enrollment (5-point increase, OR 2.18, 95% CI 1.32–3.59, $p = 0.002$) was the only independent predictor of the development of RRP at 1 year. A receiver-operating characteristic analysis identified the best cutoff value for RAMRIS bone edema score as 5. RRP was significantly rare among the patients with a RAMRIS bone edema score < 5 at enrollment (2 from 50 patients).

Conclusion. Our findings suggest that MRI bone edema is closely associated with the development of RRP in patients with early-stage RA. Physicians should carefully control the disease activity when MRI bone edema is observed in patients with early RA. (First Release May 1 2016; J Rheumatol 2016;43:1278–84; doi:10.3899/jrheum.150988)

Key Indexing Terms:

MAGNETIC RESONANCE IMAGING
RAPID RADIOGRAPHIC PROGRESSION

BONE EDEMA
EARLY-STAGE RHEUMATOID ARTHRITIS

From the Department of Immunology and Rheumatology, and Department of Public Health, and Department of Health Sciences, Nagasaki University Graduate School of Biomedical Sciences; Japanese Red Cross Nagasaki Genbaku Hospital; Department of Radiology and Radiation Research, Nagasaki University Hospital, Nagasaki; Department of Clinical Immunology and Rheumatology, Hiroshima University, Hiroshima; Department of Radiology, Institute of Biomedical Sciences, Tokushima University Graduate School, Tokushima; Sasebo Chuo Hospital, Sasebo, Japan.

Y. Nakashima, MD, Department of Immunology and Rheumatology, Nagasaki University Graduate School of Biomedical Sciences; M. Tamai, MD, PhD, Department of Immunology and Rheumatology, Nagasaki University Graduate School of Biomedical Sciences; J. Kita, MD, PhD, Department of Immunology and Rheumatology, Nagasaki University Graduate School of Biomedical Sciences; T. Michitsuji, MD, Department of Immunology and Rheumatology, Nagasaki University Graduate School of Biomedical Sciences; T. Shimizu, MD, Department of Immunology and Rheumatology, Nagasaki University Graduate School of Biomedical Sciences; S. Fukui, MD, Department of Immunology and Rheumatology,

Nagasaki University Graduate School of Biomedical Sciences; M. Umeda, MD, Department of Immunology and Rheumatology, Nagasaki University Graduate School of Biomedical Sciences; A. Nishino, MD, Department of Immunology and Rheumatology, Nagasaki University Graduate School of Biomedical Sciences; T. Suzuki, MD, PhD, Japanese Red Cross Nagasaki Genbaku Hospital; Y. Horai, MD, PhD, Department of Immunology and Rheumatology, Nagasaki University Graduate School of Biomedical Sciences; A. Okada, MD, PhD, Japanese Red Cross Nagasaki Genbaku Hospital; T. Nishimura, PhD, Department of Public Health, Nagasaki University Graduate School of Biomedical Sciences; T. Koga, MD, PhD, Department of Immunology and Rheumatology, Nagasaki University Graduate School of Biomedical Sciences; S. Kawashiri, MD, PhD, Department of Immunology and Rheumatology, Nagasaki University Graduate School of Biomedical Sciences, and Department of Public Health, Nagasaki University Graduate School of Biomedical Sciences; N. Iwamoto, MD, PhD, Department of Immunology and Rheumatology, Nagasaki University Graduate School of Biomedical Sciences; K. Ichinose, MD, PhD, Department of Immunology and Rheumatology, Nagasaki University Graduate School of Biomedical Sciences; Y. Hirai,

MD, PhD, Department of Immunology and Rheumatology, Nagasaki University Graduate School of Biomedical Sciences; K. Arima, MD, PhD, Department of Public Health, Nagasaki University Graduate School of Biomedical Sciences; S. Yamasaki, MD, PhD, Department of Clinical Immunology and Rheumatology, Hiroshima University; H. Nakamura, MD, PhD, Department of Immunology and Rheumatology, Nagasaki University Graduate School of Biomedical Sciences; T. Origuchi, MD, PhD, Department of Health Sciences, Nagasaki University Graduate School of Biomedical Sciences; S. Takao, MD, PhD, Department of Radiology, Institute of Biomedical Sciences, Tokushima University Graduate School; M. Uetani, MD, PhD, Department of Radiology and Radiation Research, Nagasaki University Hospital; K. Aoyagi, MD, PhD, Department of Public Health, Nagasaki University Graduate School of Biomedical Sciences; K. Eguchi, MD, PhD, Sasebo Chuo Hospital; A. Kawakami, MD, PhD, Department of Immunology and Rheumatology, Nagasaki University Graduate School of Biomedical Sciences.

Address correspondence to Dr. M. Tamai, Unit of Translational Medicine, Department of Immunology and Rheumatology, Nagasaki University Graduate School of Biomedical Sciences, 1-7-1 Sakamoto, Nagasaki City, Nagasaki 852-8501, Japan. E-mail: tamaim@nagasaki-u.ac.jp

Accepted for publication March 31, 2016.

The pattern of bone edema on magnetic resonance imaging (MRI) has a signal quality similar to that of inflamed synovium and has been suggested to reflect true inflammatory infiltrates rather than a pure accumulation of extracellular fluid^{1,2,3,4,5}. Bone edema near sites of rheumatoid synovitis-related inflammation are heavily vascularized, contributing to the high water content and enhanced visibility on MRI^{1,2,3,4,5}. Our previous studies of patients with early-stage rheumatoid arthritis (RA) revealed that the presence of bone edema is associated with anticitrullinated protein antibodies (ACPA) and HLA-DRB1*0405 allele carriership^{6,7}, indicating that bone edema is an important feature that reflects the typical RA phenotype.

The development of rapid radiographic progression (RRP) is considered a poor outcome in patients with RA. RRP is identified by measuring a patient's annual plain radiographic progression. The prevalence as well as the prediction of RRP have been described for patients with RA in Western countries^{8,9,10,11}. The retardation of RRP development was described in Japanese patients with active RA treated with the combination therapy of adalimumab (ADA) with methotrexate (MTX) compared with MTX alone in a clinical trial¹². However, to date, the risk model of RRP in Japanese patients with RA has been unclear.

Considering the therapeutic window of opportunity in RA¹³, the risk estimation of RRP is considered more timely in early RA compared with established RA, and in fact, risk models of RRP in patients with early-stage RA have been developed in Western countries^{8,9,10}. These risk models consist of physical synovitis and serum variables at baseline; MRI findings are not included^{8,9,10}. Our previous study demonstrated that MRI findings including bone edema not only are sensitive but accurately reflect the joint inflammation compared with joint tenderness and swelling in patients with early-stage RA¹⁴.

Since synovitis, bone edema, and bone erosion detected by MRI are known as risk factors for further radiographic

progression^{15,16,17,18,19,20}, we hypothesized that MRI findings could be informative variables that could be used to establish a risk model of RRP in patients with early-stage RA. In our study, we investigated whether MRI findings, especially bone edema, predicted the development of RRP by using the Nagasaki Early Arthritis Cohort, in which both the wrist and finger joints of the cohort were examined by MRI.

MATERIALS AND METHODS

Study population. The Nagasaki Early Arthritis Cohort opened in 2001 as part of the Unit of Translational Medicine, Department of Immunology and Rheumatology, Nagasaki University Graduate School of Biomedical Sciences^{21,22}. The patients in this cohort were referred from an area in the western part of Japan, Nagasaki Prefecture, which had about 450,000 inhabitants. From our ongoing prospective observational study conducted through this unit, 95 patients with early-stage RA whose disease duration at enrollment was <12 months and who had taken disease-modifying antirheumatic drugs (DMARD) within 1 month after MRI examinations were consecutively recruited between 2003 and 2011 for our present study; their disease status was formally confirmed by Japan College of Rheumatology-certified rheumatologists.

Our present study was a prospective and observational cohort study conducted to investigate the variables predicting the development of RRP at 1 year after study enrollment in patients with early-stage RA. We examined the MRI of both the wrists and finger joints of the study subjects, all of whom expressed manifestations of rheumatic disease of the wrist and finger joints at enrollment. The clinical diagnosis of RA (reference standard RA) of the 95 subjects was made according to the 2010 American College of Rheumatology/European League Against Rheumatism (ACR/EULAR) definition: fulfilling both the 1987 criteria of the ACR for RA and the administration of DMARD within the first year²³. Full datasets were available for 76 of the 95 patients. The DMARD administered within the first year among these 76 patients were MTX, 33 patients; sulfasalazine (SSZ), 4; bucillamine (BUC), 3; tacrolimus (TAC) 3; leflunomide, 5; MTX plus SSZ, 2; MTX plus SSZ and BUC, 1; MTX plus SSZ and mizoribine (MZR), 1; MTX plus infliximab, 8; MTX plus tocilizumab (TCZ), 2; MTX plus etanercept (ETN), 2; SSZ plus ETN, 1; TAC plus ETN, 1; TCZ, 1; ADA, 1; switched SSZ to MTX, 2; switched SSZ to BUC, 1; switched SSZ to TAC, 1; switched BUC to MTX, 1; switched TAC to MTX, 2; and switched MZR to TAC, 1.

The baseline clinical manifestations and variables included sex, age, disease duration from onset to entry, morning stiffness, DMARD, glucocorticoid, 28-joint Disease Activity Score with C-reactive protein (DAS28-CRP), CRP (measured by latex turbidimetric immunosorbent assay; Daiichi Pure Chemicals), matrix metalloproteinase-3 (MMP-3; measured by ELISA; the cutoff value was 59.7 ng/ml for women and 121.0 ng/ml for men; Daiichi Pure Chemicals), ACPA (measured by ELISA with a cutoff value of 4.5 U/ml; DIASTAT Anti-CCP, Axis-Shield), rheumatoid factor (RF; measured by latex-enhanced immunonephelometric assay with a cutoff value of 14 IU/ml; Dade Behring), MRI-proven symmetrical synovitis, MRI-proven bone edema, MRI-proven bone erosion, and plain radiographs of both the hands and feet. All variables were examined on the same day, as described^{7,14,21,22}.

Each patient provided a signed consent form to participate in the study, which was approved by the Institutional Review Board of Nagasaki University. Ours was a prospective, observational cohort study, but we advised all of the participating rheumatologists to treat the patients based on the patients' DAS28-CRP values. We did not refer to the choice of DMARD. All of the patients were examined every 3 months, including all the above variables except for MRI and plain radiographs, which were examined at enrollment and at 1 year. We estimated the therapeutic effect at 3 months using the DAS28-EULAR response criteria.

MRI of wrists and finger joints. MRI of both wrists and all finger joints were acquired using a 1.5-T system (Sigma, GE Medical Systems) with an

extremity coil. Coronal T1-weighted spin echo (TR 450, TE 13) and short-tau inversion recovery (TR 3000, TE 12, T1 160) images were acquired. The images were evaluated for synovitis, bone edema, and bone erosion with an injection of 0.1 mmol/kg of gadolinium-diethylenetriamine-pentacetate (Magnevist, Schering). The MRI were semiquantitatively evaluated by experienced radiologists (MU and ST) according to the Rheumatoid Arthritis Magnetic Resonance Imaging Scoring (RAMRIS) as described^{24,25}. RAMRIS scores of synovitis, bone edema, and bone erosion were examined by consensus opinion through 2 experienced radiologists. Inter- and intraobserver reliability of RAMRIS synovitis, bone edema, and bone erosion scores were 0.80, 0.85, 0.81, and 0.88, 0.92, 0.86, respectively, which were considered high enough to study accurately.

Plain radiographs. Plain radiographs of both hands were examined and assessed using the Genant-modified Sharp score (GSS) as described²⁶. RRP in the modified total Sharp score (mTSS; 448 points in total) is usually identified as the Δ (annual) increment of mTSS >3 or $5^{8,9,27}$. Because the total possible GSS score is 290 points, RRP in our present study was defined as an annual increment of >3 points. In fact, a Δ increment of GSS >1.5 is used as the definition of radiographic progression in the ACT-RAY (a double-blind, TCZ versus placebo-controlled clinical trial evaluating X-ray in RA) clinical trial, in which patients with RA were treated with TCZ in the presence or absence of MTX²⁸. We thus consider the Δ increment of GSS >3 appropriate as the definition of RRP in our present study.

Statistical analysis. We used Fisher's exact probability test and the Mann-Whitney U test to assess statistical differences. All statistical analyses were performed using SAS 9.4 software (SAS Institute). The variables with a p value <0.05 were considered significant. We first performed a univariate analysis to select the variables associated with RRP, then included all variables at $p < 0.2$ in a multiple logistic regression model. Positive predictive values (PPV) and negative predictive values (NPV) were calculated, and the area under the curve of the receiver-operating characteristic curve was identified to analyze the discriminative value of the matrix in predicting RRP.

RESULTS

Baseline characteristics of the 76 patients with early RA. Among the 95 patients at enrollment, the full clinical dataset was available for 76 patients at 1 year of followup (Figure 1). The characteristics of these 76 patients at enrollment are shown in Table 1. The median disease duration was 3 months, and that of 65 of the 76 patients (86%) was less than 6 months. In total, 79.0% and 82.9% of the patients were positive for RF and ACPA, respectively. The median DAS28-CRP value at enrollment was 4.31. These data indicate that most of the subjects in our present study were

seropositive early RA with high activity. The median RAMRIS synovitis score, RAMRIS bone edema score, RAMRIS bone erosion score, and GSS score at enrollment were 9, 1, 0, and 0, respectively.

Bone edema at enrollment is the only predictor of RRP development at 1 year. We performed a univariate analysis to select the variables associated with RRP. At 1 year after enrollment, the 76 patients' median Δ increase in the GSS score was 0, with a mean \pm SD of 3.35 ± 16.0 . RRP was observed in 12 patients (16%). The univariate analysis showed that the MMP-3 concentration, RAMRIS bone edema score, and RAMRIS bone erosion score were significantly higher in the RRP group compared with the non-RRP group ($n = 64$; Table 1). The seropositivity of ACPA, CRP concentrations, RAMRIS synovitis score, and GSS score were marginally higher in the RRP group (p values between 0.05 and 0.20). Tender joint count and swollen joint count (SJC) at enrollment (data not shown) were not significantly different between the RRP and non-RRP groups.

The treatment regimen may affect the development of RRP. Because about 70% of the present study's patients were classified as moderate or good responders based on the DAS28-EULAR response criteria at 3 months, the choices of DMARD were considered to be appropriate. The rate of moderate or good responders at 3 months and the use of MTX as the first-line conventional synthetic DMARD (csDMARD) and biological DMARD (bDMARD) use within 6 months of enrollment were comparable between the 2 groups (Table 1), indicating that the treatment regimen may not be significantly associated with the development of RRP in the present patient series.

In the multivariate analysis (Table 2), the MRI bone edema score at enrollment was revealed as the only independent predictor of the development of RRP at 1 year (OR 2.176, 95% CI 1.319–3.590, $p = 0.0023$). There was no statistical significance with analysis for multiple interactions, e.g., synovitis and edema, edema and erosion (Mann-Whitney U test). An MRI bone edema score ≥ 5 at enrollment was associated with the risk of development of RRP, with 83.3% sensitivity, 75% specificity, 38.5% PPV, 96% NPV, and 76% accuracy (Figure 2).

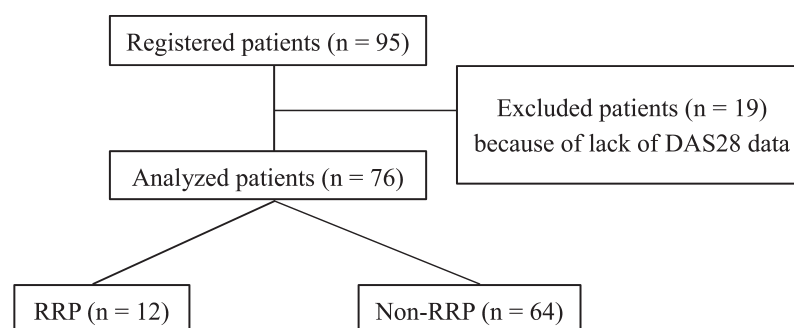


Figure 1. Flow chart of patients with RA enrolled in this study. DAS28: 28-joint Disease Activity Score; RRP: rapid radiographic progression; RA: rheumatoid arthritis.

Table 1. Association between baseline characteristics and RRP (univariate analyses). Values are median (interquartile range) unless otherwise specified.

Characteristics	Total, n = 76	RRP, n = 12	Non-RRP, n = 64	p*
Enrollment variables				
Age, yrs	54.5 (44.0–62.5)	53.5 (51.0–61.0)	55 (42.5–62.5)	0.85
Female, %	80.3	83.3	79.7	0.99
Duration, mos	3.0 (2.0–4.5)	3.0 (2.0–6.0)	3.0 (1.5–4.5)	0.36
RF, U/ml	63.0 (20.0–170.0)	104.9 (17.6–172.5)	57.0 (21.5–169.0)	0.60
Positivity, %	79.0	83.3	78.1	0.99
ACPA, IU/ml	66.8 (14.7–288.5)	130.3 (28.6–304.9)	55.5 (8.3–283.9)	0.27
Positivity, %	82.9	100	79.7	0.11
CRP, mg/dl	0.54 (0.18–1.92)	1.85 (0.36–2.93)	0.52 (0.15–1.72)	0.11
Positivity, %	75.0	91.7	71.9	0.27
MMP-3, ng/ml	72.6 (40.7–157.5)	150.6 (93.3–237.0)	63.2 (35.0–146.8)	0.006
Positivity, %	50.0	72.7	46.0	0.19
DAS28-CRP	4.31 (3.77–5.38)	5.02 (3.98–5.73)	4.23 (3.77–5.36)	0.23
RAMRIS synovitis score	9 (4–15)	12 (5.5–19.5)	9 (4–13)	0.19
Positivity, %	100	100	100	1.00
RAMRIS bone edema score	1 (0–11)	31.5 (5–39.5)	1 (0–4.5)	< 0.0001
Positivity, %	57.9	91.7	51.6	0.011
RAMRIS bone erosion score	0 (0–3)	3.5 (1.5–20)	0 (0–2)	< 0.001
Positivity, %	47.4	91.7	39.1	0.001
Genant-modified Sharp score	0 (0–1.95)	1.45 (0–2.65)	0 (0–1.01)	0.090
Therapies, %				
MTX initiation	53.9	50.0	54.7	0.99
Biologics use within 6 mos	7.9	8.3	7.8	1.00
DAS28-EULAR moderate or good response at 3 mos	72.4	75.0	67.2	0.42

* Fisher's exact probability test or the Mann-Whitney U test. RRP: rapid radiographic progression; RF: rheumatoid factor; ACPA: anticitrullinated protein antibodies; CRP: C-reactive protein; MMP-3: matrix metalloproteinase-3; DAS28: 28-joint Disease Activity Score; RAMRIS: Rheumatoid Arthritis Magnetic Resonance Imaging Scoring; MTX: methotrexate; EULAR: European League Against Rheumatism.

Table 2. Multivariate logistic regression analysis for RRP.

Variables	Unit	OR	95% CI	p
MMP-3 at enrollment	100 ng/ml increase	1.392	0.673–2.879	0.37
RAMRIS bone edema score at enrollment	5 increase	2.176	1.319–3.590	0.0023
RAMRIS bone erosion score at enrollment	3 increase	0.772	0.476–1.252	0.29
GSS at enrollment	1 increase	0.805	0.505–1.281	0.36

RRP: rapid radiographic progression; MMP-3: matrix metalloproteinase-3; RAMRIS: Rheumatoid Arthritis Magnetic Resonance Imaging Scoring; GSS: Genant-modified Sharp score.

We next divided the patients by the RAMRIS bone edema cutoff score of 5 at enrollment and compared the cumulative probability plots of Δ increment of GSS score at 1 year (Figure 3): 26 patients (34.2%) had an MRI bone edema score ≥ 5 , and 50 patients (65.8%) had an MRI bone edema score < 5 . As expected, RRP at 1 year was significantly rare among the patients with a RAMRIS bone edema score < 5 at enrollment (2 of the 50 patients, 4%, $p = 0.0002$ vs MRI bone edema score ≥ 5 at enrollment, 38.5%). Inversely, the rate of no radiographic progression at 1 year (Δ increment of GSS

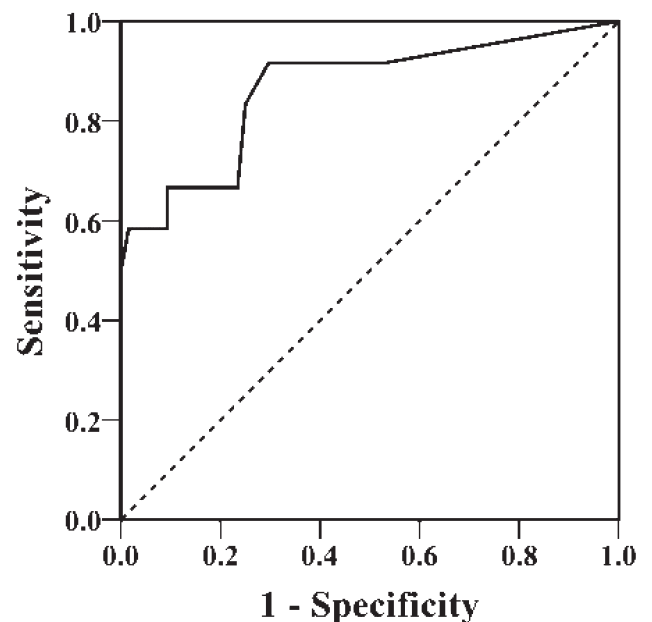


Figure 2. ROC curve for RAMRIS bone marrow edema score for RRP. The area under the ROC curve was 0.86, with cutoff point of RAMRIS bone marrow edema score ≥ 5 . ROC: receiver-operating characteristic; RAMRIS: Rheumatoid Arthritis Magnetic Resonance Imaging Scoring; RRP: rapid radiographic progression.

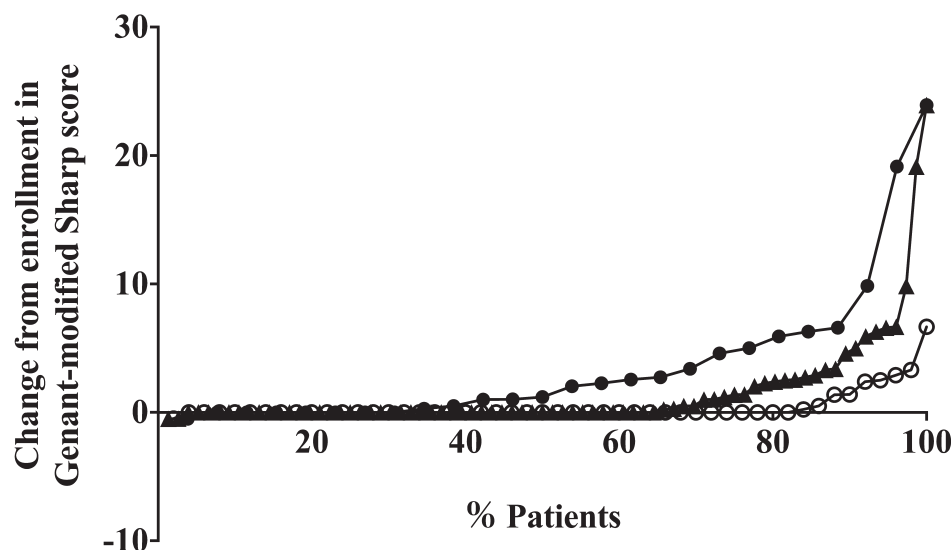


Figure 3. Cumulative probability plots for GSS at 1 year. Triangles: total (n = 76). Open circles: RAMRIS bone marrow edema score < 5 (n = 50). Dark circles: RAMRIS bone marrow edema score ≥ 5 (n = 26). GSS: Genant-modified Sharp score; RAMRIS: Rheumatoid Arthritis Magnetic Resonance Imaging Scoring.

score at 1 yr ≤ 0) was significantly low in the group with an MRI bone edema score ≥ 5 at enrollment compared with the MRI bone edema score < 5 at enrollment group (30.8% vs 84.0%, $p < 0.0001$).

DISCUSSION

As stated in the international treat-to-target (T2T) recommendations²⁹, the EULAR 2013 update³⁰, and the ACR 2012 update³¹, the main objective for the treatment of RA is to improve or maintain the patient's quality of life (QOL). It is well known that the impairment of the QOL of patients with RA largely depends on joint damage³², and thus radiographic damage in patients with RA is one of the most important outcome measures in both clinical practice and clinical trials^{8,9,10,11,12}. Because joint damage has been demonstrated to develop significantly in the early phase of RA³³, the management of the radiographic outcome of patients with early-stage RA is particularly indispensable to improve these patients' prognosis.

In the EULAR recommendations for the use of imaging of the joints in the clinical management of RA, recommendation #5 states that MRI bone edema is a strong independent predictor of subsequent radiographic progression in early RA and should be considered for use as a prognostic indicator²⁰. This statement is drawn from several prospective investigations^{15,16,17,18,19}. Subsequent to these investigations, our present study revealed new information about MRI bone edema as a predictor of radiographic progression.

Indeed, the outcome set in our present study was not the radiographic damage, but the RRP. Effective therapies can reduce the odds of radiographic progression by as much as 78%³⁴, and both early and intensive treatment can alter the

course of the disease by slowing the rate of radiographic progression even in the mid- to longterm observational periods^{35,36,37}. However, RRP occurs in a subset of treated patients with RA, and thus the identification of individual patients with RA at high risk of developing RRP is critical to making appropriate treatment choices, especially in the early stage of RA. Our present findings showed that MRI bone edema is the most significant predictor toward the subsequent development of RRP at 1 year.

Several risk models for the prediction of RRP in early-stage RA have been developed based on clinical trials including the Active-Controlled Study of Patients Receiving Infliximab for the Treatment of Rheumatoid Arthritis of Early Onset⁸ and the BeSt (Behandel Strategieën, i.e., Treatment Strategies Study)⁹ trials and an observational cohort¹⁰. These risk models indicated that the baseline variables such as elevated SJC, CRP, ESR, RF, ACPA, and plain radiographic erosion are risk factors for RRP. Our present investigation also includes the above variables, but even in the univariate analysis, the MRI findings appeared to be significantly associated with RRP compared with SJC, CRP, RF, ACPA, and plain radiographic injuries. These data reinforce the involvement of MRI, which can directly visualize and objectively quantify the synovial inflammatory process in patients with RA, especially those at a very early stage²⁰.

Among MRI findings, MRI bone edema is the best variable to predict the development of RRP. This is consistent with our previous report that MRI bone edema is the most specific variable for classifying patients with early arthritis into an RA group compared with MRI synovitis or bone erosion²¹. In that previous report, the OR of ACPA to classify patients with early arthritis into the RA group was higher than

that of MRI bone edema²¹; however, ACPA was not extracted as a predictor of RRP in our present study. These data suggest that the predictive variables for the early classification/diagnosis of RA are somewhat different from those that could be used for the early prognostic evaluation of radiographic damage.

Because the maturation of osteoclasts, in which the cells preferentially form bone erosion, is detected at the site of MRI bone edema in patients with RA^{1,2,3}, MRI bone edema is likely to be strongly associated with RRP compared with ACPA. Receptor activator of nuclear factor- κ B ligand, an essential cytokine for osteoclast development and activation, does not directly correlate with the clinical disease activity of RA³⁸, and thus no associations of SJC and CRP with RRP were identified in our present study, unlike MRI bone edema. Plain radiographic injuries, and even MRI bone erosion, do not predict the development of RRP compared with MRI bone edema, reflecting the previous finding that bone edema forms earlier than bone erosion¹. The past report³⁹ that MRI bone edema does correspond with regions where there is a cellular infiltrate replacing marrow fat in subchondral trabecular bone may support our study. The effect of bone edema toward RRP was also identified in another aspect of RA in our present study, in that the achievement of structural remission at 1 year as shown by GSS score was preferentially induced in the patients whose RAMRIS bone edema score was low at enrollment.

Our present study includes the following limitations. We extracted the index to predict RRP using multiple variables; however, the number of patients was small, with only 12 developing RRP. Although this was a prospective cohort and we recommended that the participating rheumatologists treat the patients with falling DAS28-CRP values every 3 months, the treatment choice depended on the decision of each rheumatologist. The rate of MTX as the first-line csDMARD or bDMARD use within 6 months and the DAS28-CRP value at 3 months were not predictive of RRP; however, the treatment regimens might have resulted in bias. A randomized placebo-controlled trial of golimumab has clearly shown that a high RAMRIS bone edema score at enrollment is an independent predictor of radiographic progression at 1 year⁴⁰. Such distinctive protocol-driven investigations are necessary to test our present findings.

Bone edema in patients with RA at enrollment is the most significant predictor of RRP at 1 year. Our present data indicate that a RAMRIS bone edema score ≥ 5.0 predicts the development of RRP with 83.3% sensitivity and 75.0% specificity. Importantly, our cohort of patients with early-stage RA included 34.2% with a RAMRIS bone edema score at enrollment ≥ 5.0 , indicating that a substantial population among patients with early-stage RA are at risk of developing RRP. Our findings might be useful for deciding which patients must receive early aggressive therapy with biologic DMARD in daily clinical practice. MRI bone edema may

also be considered as an imaging biomarker that allows triage of patients with RA strictly by T2T therapeutic strategy.

REFERENCES

- Schett G. Bone marrow edema. *Ann N Y Acad Sci* 2009;1154:35–40.
- Bugatti S, Manzo A, Caporali R, Montecucco C. Inflammatory lesions in the bone marrow of rheumatoid arthritis patients: a morphological perspective. *Arthritis Res Ther* 2012;14:229.
- McQueen FM. Bone marrow edema and osteitis in rheumatoid arthritis: the imaging perspective. *Arthritis Res Ther* 2012;14:224.
- McQueen FM. Imaging in early rheumatoid arthritis. *Best Pract Res Clin Rheumatol* 2013;27:499–522.
- Østergaard M, Møller-Bisgaard S. Optimal use of MRI in clinical trials, clinical care and clinical registries of patients with rheumatoid arthritis. *Clin Exp Rheumatol* 2014;32 Suppl 85:S-17–22.
- Tamai M, Kawakami A, Uetani M, Takao S, Tanaka F, Nakamura H, et al. The presence of anti-cyclic citrullinated peptide antibody is associated with magnetic resonance imaging detection of bone marrow oedema in early stage rheumatoid arthritis. *Ann Rheum Dis* 2006;65:133–4.
- Tamai M, Kawakami A, Uetani M, Takao S, Tanaka F, Fujikawa K, et al. Bone edema determined by magnetic resonance imaging reflects severe disease status in patients with early-stage rheumatoid arthritis. *J Rheumatol* 2007;34:2154–7.
- Vastesager N, Xu S, Aletaha D, St Clair EW, Smolen JS. A pilot risk model for the prediction of rapid radiographic progression in rheumatoid arthritis. *Rheumatology* 2009;48:1114–21.
- Visser K, Goekoop-Ruiterman YP, de Vries-Bouwstra JK, Ronday HK, Seys PE, Kerstens PJ, et al. A matrix risk model for the prediction of rapid radiographic progression in patients with rheumatoid arthritis receiving different dynamic treatment strategies: post hoc analyses from the BeSt study. *Ann Rheum Dis* 2010;69:1333–7.
- Fautrel B, Granger B, Combe B, Saraux A, Guillemin F, Le Loet X. Matrix to predict rapid radiographic progression of early rheumatoid arthritis patients from the community treated with methotrexate or leflunomide: results from the ESPOIR cohort. *Arthritis Res Ther* 2012;14:R249.
- Lillegården S, Paynter N, Prince FH, Shadick NA, Haavardsholm EA, Frits ML, et al. Performance of matrix-based risk models for rapid radiographic progression in a cohort of patients with established rheumatoid arthritis. *Arthritis Care Res* 2013;65:526–33.
- Takeuchi T, Yamanaka H, Ishiguro N, Miyasaka N, Mukai M, Matsubara T, et al. Adalimumab, a human anti-TNF monoclonal antibody, outcome study for the prevention of joint damage in Japanese patients with early rheumatoid arthritis: the HOPEFUL 1 study. *Ann Rheum Dis* 2014;73:536–43.
- van Nies JA, Krabben A, Schoones JW, Huizinga TW, Kloppenburg M, van der Helm-van Mil AH. What is the evidence for the presence of a therapeutic window of opportunity in rheumatoid arthritis? A systematic literature review. *Ann Rheum Dis* 2014;73:861–70.
- Tamai M, Kawakami A, Iwamoto N, Kawashiri SY, Fujikawa K, Aramaki T, et al. Comparative study of the detection of joint injury in early-stage rheumatoid arthritis by magnetic resonance imaging of the wrist and finger joints and physical examination. *Arthritis Care Res* 2011;63:436–9.
- Hetland ML, Stengaard-Pedersen K, Junker P, Lottenburger T, Hansen I, Andersen LS, et al; CIMESTRA study group. Aggressive combination therapy with intra-articular glucocorticoid injections and conventional disease-modifying anti-rheumatic drugs in early rheumatoid arthritis: second-year clinical and radiographic results from the CIMESTRA study. *Ann Rheum Dis* 2008;67:815–22.
- Hetland ML, Ejbjerg B, Hørslev-Petersen K, Jacobsen S, Vestergaard A, Jurik AG, et al; CIMESTRA study group. MRI bone

- oedema is the strongest predictor of subsequent radiographic progression in early rheumatoid arthritis. Results from a 2-year randomised controlled trial (CIMESTRA). *Ann Rheum Dis* 2009;68:384–90.
17. Hetland ML, Stengaard-Pedersen K, Junker P, Østergaard M, Ejbjerg BJ, Jacobsen S, et al; CIMESTRA study group. Radiographic progression and remission rates in early rheumatoid arthritis - MRI bone oedema and anti-CCP predicted radiographic progression in the 5-year extension of the double-blind randomised CIMESTRA trial. *Ann Rheum Dis* 2010;69:1789–95.
 18. Haavardsholm EA, Bøyesen P, Østergaard M, Schildvold A, Kvien TK. Magnetic resonance imaging findings in 84 patients with early rheumatoid arthritis: bone marrow oedema predicts erosive progression. *Ann Rheum Dis* 2008;67:794–800.
 19. Bøyesen P, Haavardsholm EA, Østergaard M, van der Heijde D, Sesseng S, Kvien TK. MRI in early rheumatoid arthritis: synovitis and bone marrow oedema are independent predictors of subsequent radiographic progression. *Ann Rheum Dis* 2011;70:428–33.
 20. Colebatch AN, Edwards CJ, Østergaard M, van der Heijde D, Balint PV, D'Agostino MA, et al. EULAR recommendations for the use of imaging of the joints in the clinical management of rheumatoid arthritis. *Ann Rheum Dis* 2013;72:804–14.
 21. Tamai M, Kawakami A, Uetani M, Takao S, Arima K, Iwamoto N, et al. A prediction rule for disease outcome in patients with undifferentiated arthritis using magnetic resonance imaging of the wrists and finger joints and serologic autoantibodies. *Arthritis Rheum* 2009;61:772–8.
 22. Tamai M, Kita J, Nakashima Y, Suzuki T, Horai Y, Okada A, et al. Combination of MRI-detected bone marrow oedema with 2010 rheumatoid arthritis classification criteria improves the diagnostic probability of early rheumatoid arthritis. *Ann Rheum Dis* 2014;73:2219–20.
 23. Radner H, Neogi T, Smolen JS, Aletaha D. Performance of the 2010 ACR/EULAR classification criteria for rheumatoid arthritis: a systematic literature review. *Ann Rheum Dis* 2014;73:114–23.
 24. Lassere M, McQueen F, Østergaard M, Conaghan P, Shnier R, Peterfy C, et al. OMERACT Rheumatoid Arthritis Magnetic Resonance Imaging Studies. Exercise 3: an international multicenter reliability study using the RA-MRI Score. *J Rheumatol* 2003;30:1366–75.
 25. Conaghan P, Lassere M, Østergaard M, Peterfy C, McQueen F, O'Connor P, et al. OMERACT Rheumatoid Arthritis Magnetic Resonance Imaging Studies. Exercise 4: an international multicenter longitudinal study using the RA-MRI Score. *J Rheumatol* 2003;30:1376–9.
 26. Genant HK, Peterfy CG, Westhovens R, Becker JC, Aranda R, Vratsanos G, et al. Abatacept inhibits progression of structural damage in rheumatoid arthritis: results from the long-term extension of the AIM trial. *Ann Rheum Dis* 2008;67:1084–9.
 27. Keystone EC, Haraoui B, Guérette B, Mozaffarian N, Liu S, Kavanaugh A. Clinical, functional, and radiographic implications of time to treatment response in patients with early rheumatoid arthritis: a posthoc analysis of the PREMIER study. *J Rheumatol* 2014;41:235–43.
 28. Dougados M, Kissel K, Conaghan PG, Mola EM, Schett G, Gerli R, et al. Clinical, radiographic and immunogenic effects after 1 year of tocilizumab-based treatment strategies in rheumatoid arthritis: the ACT-RAY study. *Ann Rheum Dis* 2014;73:803–9.
 29. Smolen JS, Aletaha D, Bijlsma JW, Breedveld FC, Boumpas D, Burmester G, et al; T2T Expert Committee. Treating rheumatoid arthritis to target: recommendations of an international task force. *Ann Rheum Dis* 2010;69:631–7.
 30. Smolen JS, Landewé R, Breedveld FC, Buch M, Burmester G, Dougados M, et al. EULAR recommendations for the management of rheumatoid arthritis with synthetic and biological disease-modifying antirheumatic drugs: 2013 update. *Ann Rheum Dis* 2014;73:492–509.
 31. Singh JA, Furst DE, Bharat A, Curtis JR, Kavanaugh AF, Kremer JM, et al. 2012 update of the 2008 American College of Rheumatology recommendations for the use of disease-modifying antirheumatic drugs and biologic agents in the treatment of rheumatoid arthritis. *Arthritis Care Res* 2012;64:625–39.
 32. Aletaha D, Smolen J, Ward MM. Measuring function in rheumatoid arthritis: identifying reversible and irreversible components. *Arthritis Rheum* 2006;54:2784–92.
 33. McQueen FM, Benton N, Perry D, Crabbe J, Robinson E, Yeoman S, et al. Bone edema scored on magnetic resonance imaging scans of the dominant carpus at presentation predicts radiographic joint damage of the hands and feet six years later in patients with rheumatoid arthritis. *Arthritis Rheum* 2003;48:1814–27.
 34. Jones G, Halbert J, Crotty M, Shanahan EM, Batterham M, Ahern M. The effect of treatment on radiological progression in rheumatoid arthritis: a systematic review of randomized placebo-controlled trials. *Rheumatology* 2003;42:6–13.
 35. Landewé RB, Boers M, Verhoeven AC, Westhovens R, van de Laar MA, Markusse HM, et al. COBRA combination therapy in patients with early rheumatoid arthritis: long-term structural benefits of a brief intervention. *Arthritis Rheum* 2002;46:347–56.
 36. Korpela M, Laasonen L, Hannonen P, Kautiainen H, Leirisalo-Repo M, Hakala M, et al. Retardation of joint damage in patients with early rheumatoid arthritis by initial aggressive treatment with disease-modifying antirheumatic drugs: five-year experience from the FIN-RACo study. *Arthritis Rheum* 2004;50:2072–81.
 37. Finckh A, Liang MH, van Herckenrode CM, de Pablo P. Long-term impact of early treatment on radiographic progression in rheumatoid arthritis: a meta-analysis. *Arthritis Rheum* 2006;55:864–72.
 38. Cohen SB, Dore RK, Lane NE, Ory PA, Peterfy CG, Sharp JT, et al; Denosumab Rheumatoid Arthritis Study Group. Denosumab treatment effects on structural damage, bone mineral density, and bone turnover in rheumatoid arthritis: a twelve-month, multicenter, randomized, double-blind, placebo-controlled, phase II clinical trial. *Arthritis Rheum* 2008;58:1299–309.
 39. McQueen FM, Gao A, Østergaard M, King A, Shalley G, Robinson E, et al. High-grade MRI bone oedema is common within the surgical field in rheumatoid arthritis patients undergoing joint replacement and is associated with osteitis in subchondral bone. *Ann Rheum Dis* 2007;66:1581–7.
 40. Baker JF, Østergaard M, Emery P, Hsia EC, Lu J, Baker DG, et al. Early MRI measures independently predict 1-year and 2-year radiographic progression in rheumatoid arthritis: secondary analysis from a large clinical trial. *Ann Rheum Dis* 2014;73:1968–74.