

Rituximab for Primary Angiitis of the Central Nervous System: Report of 2 Patients from the French COVAC Cohort and Review of the Literature

To the Editor:

Primary angiitis of the central nervous system (PACNS) is a rare and severe inflammatory disease affecting the vessels of the brain and sometimes spinal cord. Diagnosis relies on (1) a neurologic deficit that remains unexplained after complete examination; (2) CNS vascular abnormalities on conventional cerebral angiography (CCA) or histopathology; and (3) the exclusion of other differential diagnoses such as reversible cerebral vasoconstriction syndrome or systemic vasculitides^{1,2,3}. Neurologic manifestations usually worsen or relapse in the absence of treatment. Corticosteroids are the cornerstone of therapy and with severe disease are often combined with an immunosuppressant, mainly

cyclophosphamide (CYC). Few patients are refractory to this treatment and/or relapse. To date, only limited information exists on potential rescue and alternative treatments, including rituximab (RTX)⁴.

We describe 2 adult patients with PACNS who showed improvement with RTX and corticosteroids.

Case 1. In a 42-year-old man, progressive cerebellar ataxia developed over a couple of months; then left hemiparesis and binocular diplopia developed. Brain magnetic resonance imaging (MRI) revealed multiple lesions of the cortical and deep subcortical white matter, thalami, cerebellum, and cervical spine. Most lesions and meninges were enhanced after gadolinium injection (Figures 1A, B). Cerebrospinal fluid (CSF) examination revealed protein concentration 600 mg/l and leukocyte count 60/mm³. An open-wedge biopsy revealed a vascular wall lymphocytic infiltrate (Figure 1C). Complete examination (Table 1) was negative for differential diagnoses. Oral prednisone (70 mg/day) was administered with

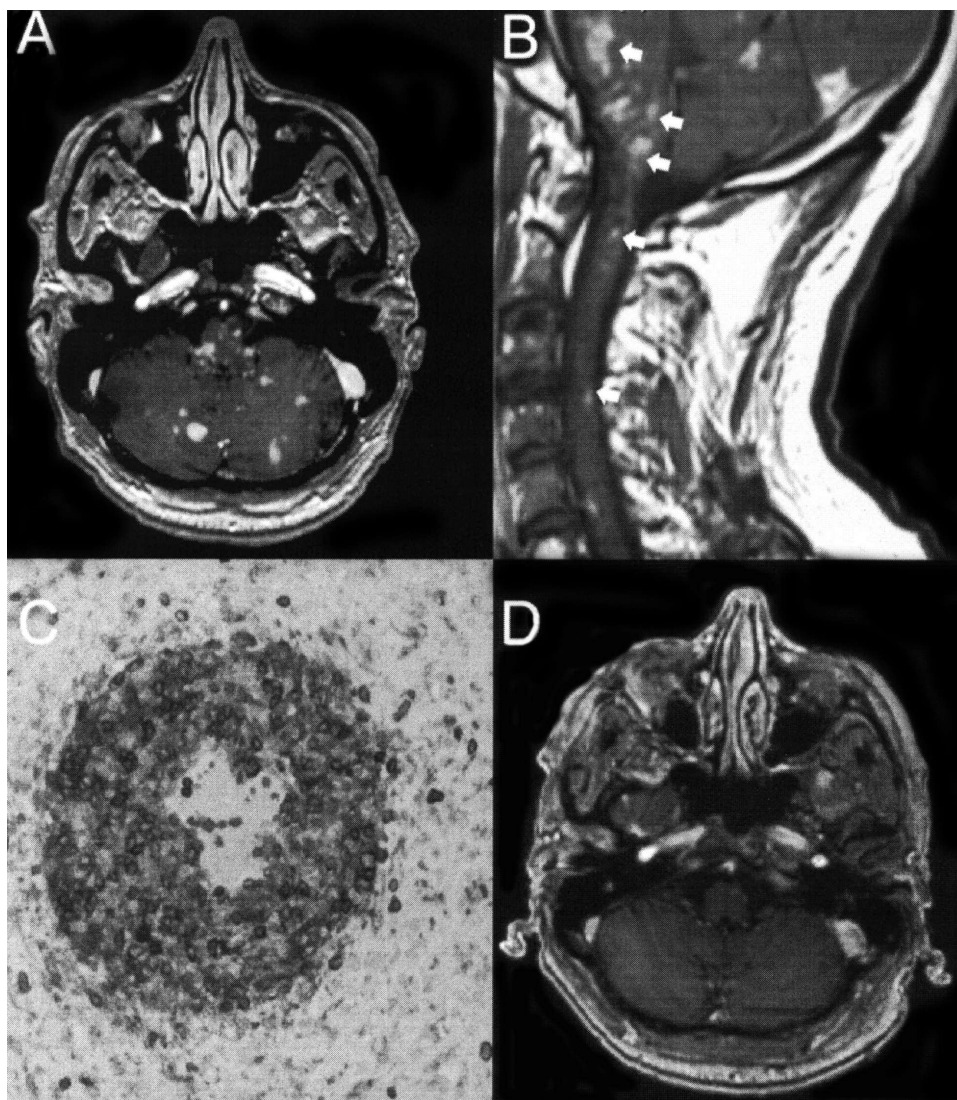


Figure 1. Images for Patient 1. (A, B) Magnetic resonance imaging (MRI) gadolinium-enhanced T1 sequences of brain and cervical spinal cord, respectively, showing lesions in cerebellar lobes as well as vermis, pons, subcortical white matter of anterior temporal lobes and cervical spine at C2 and C4 levels (arrows). C. Histopathology findings of brain biopsy (immunohistochemical staining of CD4+ and CD20+ cells) showing a lymphocytic infiltrate, predominantly CD4+ T cells, of the vessel wall. Staining for amyloid deposits was negative. D. MRI gadolinium-enhanced T1 sequence of brain demonstrating a reduced number of lesions after treatment with rituximab.

Table 1. Investigations performed in our 2 patients diagnosed with primary angiitis of the central nervous system.

Standard laboratory tests	Complete blood count, blood electrolytes, serum creatinine level, liver tests, C-reactive protein level, blood coagulation tests, serum protein electrophoresis, thyroid-stimulating hormone level, urine analysis.
Immunological tests	Antinuclear antibodies. anti-dsDNA antibodies, antineutrophil cytoplasm antibodies, anticardiolipin antibodies, lupus anticoagulant screening, antiphospholipid antibodies, rheumatoid factor, complement exploration (C3, C4, CH50)
Infection screening tests	Blood: Hepatitis B and C virus, HIV, cytomegalovirus, Epstein-Barr virus, toxoplasmosis, Q fever, syphilis, borreliosis, rickettsiosis including Lyme Cerebrospinal fluid: PCR for herpes simplex virus and varicella-zona virus, culture
Other investigations	Whole-body CT, duplex carotid ultrasonography, transthoracic echocardiography, FDG-PET scan for patient 1, somesthetic evoked potentials for patient 1

FDG-PET: 18F-fluorodeoxyglucose positron emission tomography; HIV: human immunodeficiency virus; CT: computed tomography.

monthly intravenous CYC, but at 5 months, ataxia and upper-limb paresis worsened and the number of lesions on repeat MRI had increased. RTX was given (375 mg/m²/week for 4 weeks), followed by azathioprine. Neurological status improved 1 month after RTX completion, with reduced paresthesias and ataxia. Repeat brain and spine MRI showed fewer lesions (Figure 1D), without relapse at the 12-month followup post-RTX.

Case 2. A 57-year-old woman developed balance disorder, dysarthria, focal motor deficit of the right arm, and progressive cognitive decline over 2 weeks. Brain MRI revealed recent and semirecent infarctions in anterior and middle cerebral artery territories. CCA revealed multiple and bilateral stenoses affecting the small arteries. CSF analysis showed protein concentration 700 mg/l and leukocyte count 17/mm³. Complete investigations (Table 1) were negative for differential diagnoses for PACNS. The patient received prednisone (70 mg/day) with RTX (375 mg/m²/week for 4 weeks) rather than CYC because of a history of bladder polyps. The neurologic status improved, and no new flares had occurred 20 months after RTX treatment. Repeat brain MRI revealed decreased size and number of fluid attenuated inversion recovery hyperintense signals.

PACNS is challenging to diagnose. Only a positive biopsy can ascertain the diagnosis, and all appropriate staining, immunohistochemistry studies, and immunophenotyping are needed to rule out related conditions such as amyloid- β -related angiitis or different mimicking diseases such as CNS lymphoma. However, in practice and for more than two-thirds of patients in previously referenced series, biopsy was not performed and diagnosis relied on the combination of vascular changes on CCA and the exclusion, after thorough clinical and laboratory evaluation, of other conditions that can involve brain vessels^{1,5,6,7,8}. Our 2 patients underwent extensive investigations to rule out differential diagnoses. With a followup exceeding 1 year, brain imaging would not likely have shown amelioration of alternative diseases such as infection or intracranial atherosclerosis and under potent immunosuppressive regimens.

Although the optimal treatment for PACNS has not been determined, most patients achieve good outcomes with corticosteroids, with or without CYC^{2,3,8}. Refractory and/or relapsing cases are rare, and require, after

having reconsidered the diagnosis, alternative and/or rescue therapeutic options.

In antineutrophil cytoplasm antibody-associated vasculitides, RTX (a chimeric anti-CD20 antibody) was not inferior to CYC in inducing remission⁹. It was also effective for CNS involvement in some patients with granulomatosis with polyangiitis¹⁰. Recently, RTX treatment was successful in a 3-year-old girl with remitting-relapsing biopsy-proven PACNS after failure of corticosteroids, azathioprine, and CYC⁴. To our knowledge, our 2 cases represent the first reports suggesting the clinical and radiographic efficacy of RTX in adults diagnosed with PACNS.

Further reports and studies are needed to better determine the place of RTX in the treatment of PACNS refractory to corticosteroids and CYC or as an alternative to CYC for first-line therapy.

ACKNOWLEDGMENT

We thank Drs. Anthony Faivre and Guillaume Gondran for their participation in data collection; and Prof. Françoise Gray and Dr. Olivier Naggara for their help in reviewing biopsy samples and neuroimaging.

HUBERT DE BOYSSON, MD, MSc, Department of Internal Medicine, Centre Hospitalier Universitaire de la côte de Nacre, Caen; and Division of Internal Medicine, Hôpital Cochin, AP-HP, Université Paris-Descartes, Paris; CAROLINE ARQUIZAN, MD, Department of Neurology, Hôpital Gui de Chauliac, Université Montpellier, Montpellier; LOIC GUILLEVIN, MD, Division of Internal Medicine, Hôpital Cochin, AP-HP, Université Paris-Descartes, Paris, France; CHRISTIAN PAGNOUX, MD, MSc, MPH, Division of Internal Medicine, Hôpital Cochin, AP-HP, Université Paris-Descartes, and Division of Rheumatology, Mount Sinai Hospital, University Health Network, University of Toronto, Toronto, Ontario, Canada.

Address correspondence to Dr. H. de Boysson, Service de médecine interne, Centre Hospitalier Universitaire de la côte de Nacre, Caen, France. E-mail: hubertdeboysson@yahoo.fr

REFERENCES

- Calabrese LH, Mallek JA. Primary angiitis of the central nervous system. Report of 8 new cases, review of the literature, and proposal for diagnostic criteria. *Medicine* 1988;67:20-39.
- Néel A, Pagnoux C. Primary angiitis of the central nervous system. *Clin Exp Rheumatol* 2009;27:S95-107.
- Salvarani C, Brown RD Jr., Hunder GG. Adult primary central nervous system vasculitis. *Lancet* 2012;380:767-77.
- El M'Kaddem B, Clapuyt P, de Bruycker JJ, Lauwerys B, Raftopoulos C, Godfraind C, et al. Primary cerebral arteritis in a young girl: an unusual cause of acute recurrent neurological deterioration. *Eur J Paediatr Neurol* 2012;16:196-9.
- Salvarani C, Brown RD Jr., Calamia KT, Christianson TJ, Weigand SD, Miller DV, et al. Primary central nervous system vasculitis: analysis of 101 patients. *Ann Neurol* 2007;62:442-51.
- Benseler SM, Silverman E, Aviv RI, Schneider R, Armstrong D, Tyrrell PN, et al. Primary central nervous system vasculitis in children. *Arthritis Rheum* 2006;54:1291-7.
- Birnbaum J, Hellmann DB. Primary angiitis of the central nervous system. *Arch Neurol* 2009;66:704-9.
- Hajj-Ali RA, Singhal AB, Benseler S, Molloy E, Calabrese LH. Primary angiitis of the CNS. *Lancet Neurol* 2011;10:561-72.
- Stone JH, Merkel PA, Spiera R, Seo P, Langford CA, Hoffman GS, et al. Rituximab versus cyclophosphamide for ANCA-associated vasculitis. *N Engl J Med* 2010;363:221-32.
- Holle JU, Gross WL. Neurological involvement in Wegener's granulomatosis. *Curr Opin Rheumatol* 2011;23:7-11.

J Rheumatol 2013;40:12; doi:10.3899/jrheum.130529