

Cerebrospinal Fluid Analysis in Immunoglobulin G4-related Hypertrophic Pachymeningitis

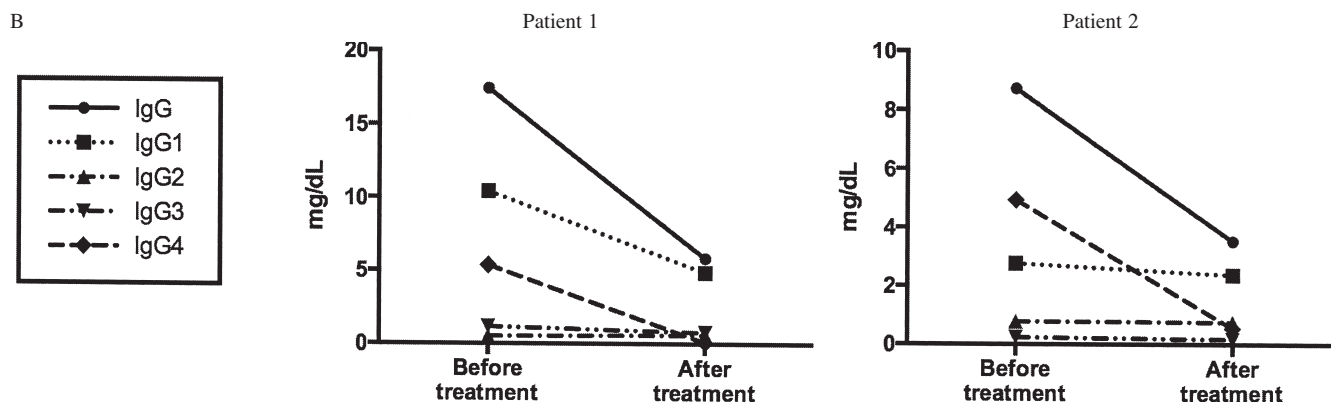
To the Editor:

Immunoglobulin G4-related disease (IgG4-RD) is characterized by fibrous swelling of affected organs, elevations in serum IgG4 concentrations, and responsiveness to glucocorticoid treatment¹. Affected tissues display similar histological features: diffuse lymphoplasmacytic infiltration by numerous IgG4-positive plasma cells, occasional eosinophils, storiform fibrosis, and obliterative phlebitis². IgG4-related hypertrophic pachymeningitis (IgG4-HP) has been identified as a characteristic central nervous system (CNS) manifestation of IgG4-RD, but comprehensive cerebrospinal fluid (CSF) analyses are substantially lacking^{3,4}. Recently, we demonstrated an intrathecal IgG and IgG4 synthesis in the CSF of a patient with IgG4-HP and suggested IgG4 indices as safe potential diagnostic tools for IgG4-HP⁵. Here, we describe 2 new cases of IgG4-HP with CSF evaluation at diagnosis and in response to treatment.

In case 1, March 2007, a 56-year-old man was admitted with a 1-year history of right frontal headache. Magnetic resonance imaging (MRI) showed right frontal pachymeningitis. Granulomatous meningeal inflammation was suspected and oral prednisone (1 mg/kg body weight/day) was started with clinical and radiological improvement. Prednisone was discontinued after 8 months, but in July 2008 the headache recurred. Blood and CSF analyses are shown in Table 1. MRI evidenced a right frontotemporal progression of the pachymeningitis (Figure 1A). A meningeal biopsy fulfilled IgG4-RD diagnostic criteria (Figure 1E)². Prednisone (50 mg/day) was reintroduced with methotrexate (MTX; 20 mg/week) with a sharp radiological improvement after 3 months of therapy (Figure 1C). In January 2009, MTX was withdrawn because of hematological adverse effects. Six months later, frontotemporal pachymeningitis relapsed and oral cyclophosphamide (100 mg/day) was introduced together with prednisone (50 mg/day). Dural inflammation improved and corticosteroid therapy was gradually tapered off. At 44 months of followup the patient remains in remission with oral cyclophosphamide.

Table 1. Cerebrospinal fluid (CSF), serological and microbiological findings in the 2 patients with IgG4 hypertrophic pachymeningitis.

A	Reference Values	Patient 1		Patient 2	
		Before Therapy	After Therapy	Before Therapy	After Therapy
Appearance	Colorless, clear	Colorless, clear	Colorless, clear	Colorless, clear	Colorless, clear
Total proteins (mg/dl)	12–60	76	76	44	73
Glucose (mg/dl)	40–80	42	55	59	56
Cells (μ l)	0–1	32 (lymphocytes)	20 (lymphocytes)	2 (lymphocytes)	1 (lymphocytes)
Cytological analysis		No atypical cells	No atypical cells	No atypical cells	No atypical cells
Microbiological analyses*	Negative	Negative	Negative	Negative	Negative
Autoimmunity and ACE [§]	Negative	Negative		Negative	
CSF albumin (mg/dl)	10–30	85	45	25	37
Serum albumin (mg/dl)	3500–5000	2370	2650	3350	4180
Albumin Quotient [^]	< 0.7	3.6	1.7	0.7	0.9
CSF IgG (mg/dl)	0.8–3.8	17.4	5.8	8.7	3.5
Serum IgG (mg/dl)	840–1600	607	797	651	736
IgG Index	< 0.70	0.84	0.43	1.8	0.53
IgG _{Loc}	0	1	0	5.5	0
CSF IgG4 (mg/dl) [°]	0.01–0.32	5.35	0.07	4.94	0.54
Serum IgG (mg/dl)	3–230	46	19	210	75
IgG4 Index [°]	0.25–0.91	3.21	0.23	3.16	0.81
IgG4 _{Loc}	0	4.1	0	3.91	0.09



A. *PCR for Herpes simplex virus types 1 and 2, varicella-zoster virus, cytomegalovirus, Epstein-Barr virus, enterovirus, *Mycobacterium tuberculosis*; gram, acid-fast stain, and microbiological cultures; search for *Aspergillus fumigatus* and *Cryptococcus neoformans* antigens; serology for Lyme disease, brucellosis, syphilis. [§]Rheumatoid factor, antinuclear, anticyclic citrullinated peptide, and antineutrophil cytoplasmic antibodies; angiotensin converting enzyme (ACE). [^]Albumin quotient measures the blood-CSF barrier permeability. [°]Normal range for CSF IgG4 concentration and IgG4 Index was calculated using 9 patients affected by pituitary nonsecreting adenomas without blood-CSF barrier damage and OCB on CSF analysis, nor evidence of meningitis on magnetic resonance imaging. IgG4-HP: immunoglobulin G4-related hypertrophic pachymeningitis. B. Cerebrospinal fluid concentration of IgG subclasses (IgG1, IgG2, IgG3, and IgG4) show a significant decline after immunosuppressive treatment of IgG4 levels in both patients, as well as of IgG1 levels in Patient 1. IgG2 and IgG3 were not significantly affected by immunosuppressive therapy.

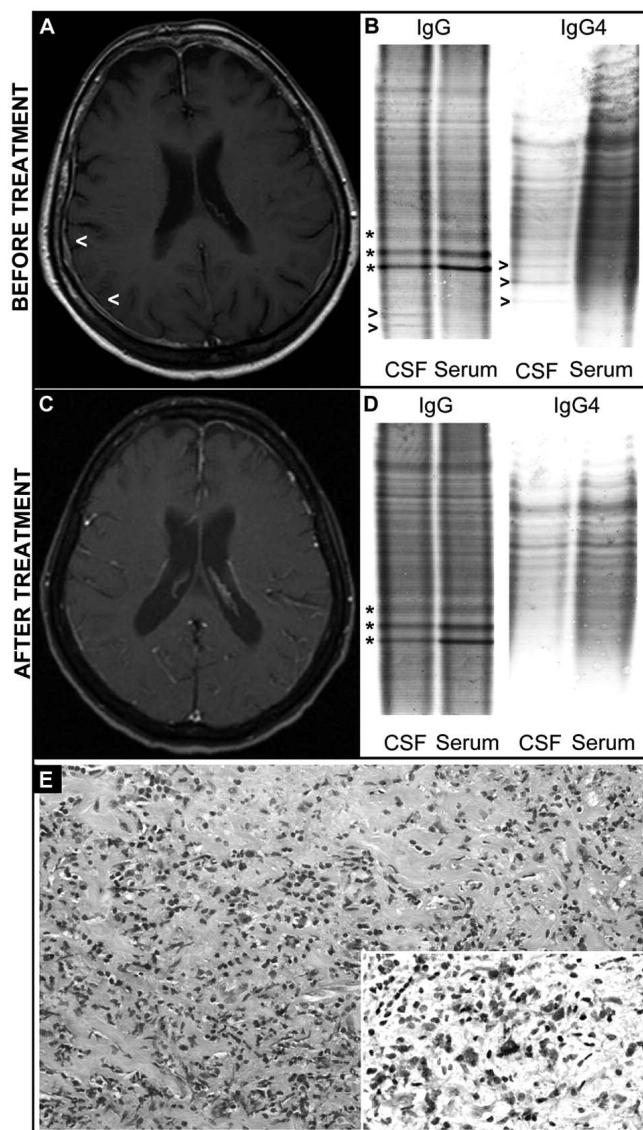


Figure 1. Radiological, immunological, and histological findings in Patient 1 with immunoglobulin G4-related hypertrophic pachymeningitis (IgG4-HP). Gadolinium-enhanced MRI before (A) and after (C) treatment (arrowheads indicate pachymeningeal fibrosis); dural infiltration is almost completely resolved after therapy. Oligoclonal total IgG/IgG4 bands (OCB, arrowheads) in paired CSF and serum samples before (B) and after (D) treatment; OCB are no longer detectable after therapy. Hematoxylin-eosin staining of the meningeal specimens (E) shows a dural perivascular dense lymphoplasmacytic infiltrate surrounded by storiform fibrosis ($\times 200$); immunohistochemistry reveals numerous IgG4-positive plasma cells with an IgG4/IgG ratio ranging from 40% to 70% (inserts $\times 400$). CSF: cerebrospinal fluid.

In case 2, October 2009, a 48-year-old woman was hospitalized for acute left peripheral facial nerve palsy and throbbing headache; these symptoms presented over a 7-month history of progressive dizziness, subacute onset of left trigeminal neuralgia, bilateral sensorineural hearing loss, and dysphagia. MRI showed a diffuse thickening and enhancement of the dura mater involving the posterior cranial fossa and the foramen magnum with extension to the first vertebra of the cervical spinal canal. Prednisone (1 mg/kg body weight/day) was started and gradually tapered off over 2 months with marked improvement. Recurrent flares of headache

were treated with cycles of low-dose prednisone (< 25 mg/day). In November 2011, the patient came to our attention because of right peripheral facial nerve palsy, ocular motor nerve palsies involving the IV and VI nerves, and severe headache. Diagnostic evaluation is shown in Table 1. Brain MRI showed enhancement at the right orbital apex and extension of the pachymeningitis to right temporal regions. Meningeal biopsies confirmed IgG4-HP. Cyclophosphamide (1 g/m²/month) was introduced in April 2012 with gradual improvement; a followup MRI after 8 infusions demonstrated a reduction in the meningeal thickness. At present, the disease remains stable.

The CSF results of both cases are shown in Table 1. Before treatment, intrathecal inflammation was evidenced by moderate to severe damage of the blood-CSF barrier. Quantitative analyses performed by measuring IgG/IgG4 Index⁶ and IgG/IgG4_{Loc}⁷ demonstrated intrathecal production of the 4 IgG subclasses, with IgG4 expressing the highest values of specific indices. Qualitative studies evidenced 2 IgG oligoclonal bands (OCB) with 3 IgG4 OCB in the CSF of Patient 1 (Figure 1B) and a single IgG OCB with 2 IgG4 OCB in the CSF of Patient 2; no corresponding bands were detected in the patients' sera. OCB are the expression of a CNS and CSF compartmentalization of a highly restricted number of antigen specific B-cell clones that were transformed, after affinity maturation, into Ig-secreting plasma cells^{8,9}. Therefore, our results demonstrate that oligoclonally restricted IgG4-positive plasma cells residing in meningeal inflammatory niches are involved in the pathogenesis of IgG4-HP and support a pathogenetic model in which a fibroinflammatory immune reaction is initially triggered by a specific response against a still unknown antigen.

The patients' response to immunosuppression was evaluated after 3 months of prednisone and MTX treatment in Patient 1 and after 8 infusions of cyclophosphamide in Patient 2. CSF analysis revealed an improvement in blood-CSF barrier permeability and a decrease in intrathecal IgG and IgG4 production, as measured both qualitatively (disappearance of OCB; Figure 1D) and quantitatively (IgG/IgG4 Index and IgG/IgG4_{Loc}; Table 1A). The reduction in CSF total IgG levels was attributable to a decrease in IgG1 and IgG4 concentrations in Patient 1 and IgG4 concentration in Patient 2 (Table 1B). Taken together, these data describe an immunological "CSF response" that corresponds to the favorable clinical and radiological outcome (Figure 1C).

Recently, Carruthers, *et al* developed an IgG4-RD Responder Index aimed at quantifying the objective efficacy of treatments in patients with systemic disease involvement¹⁰. However, the comprehensive evaluation of patients with exclusive pachymeningeal involvement and/or normal serum IgG4 levels (Patient 1) could be extremely challenging. In this sense, by introducing the new concepts of IgG4 Indices and CSF response, we provide additional tools for the diagnosis and monitoring of therapeutic outcomes in patients affected by IgG4-HP.

Our work confirms IgG4 Index and IgG4_{Loc} as solid indicators of intrathecal IgG4 synthesis. Given the lack of established criteria for defining unusual extrapancreatic IgG4-RD involvement and the risks associated with invasive diagnostic procedures in CNS, the analysis of CSF for IgG4 production could represent a useful tool for diagnosing IgG4-HP and monitoring the response to specific therapies.

ACKNOWLEDGMENT

The authors thank Professor John H. Stone (Massachusetts General Hospital, Boston, Rheumatology Unit) for his helpful review of the manuscript.

EMANUEL DELLA-TORRE, MD, Università Vita-Salute San Raffaele, School of Medicine, and Unit of Medicine and Clinical Immunology, San Raffaele Scientific Institute, Milan; GABRIELLA PASSERINI, MD, Diagnostica e ricerca, San Raffaele Scientific Institute; ROBERTO FURLAN, MD, Clinical Neuroimmunology Unit, Institute of Experimental Neurology, Division of Neuroscience, San Raffaele Scientific Institute; LUISA ROVERI, MD; RAFFAELLA CHIEFFO, MD, Department of

Neurology, San Raffaele Scientific Institute; NICOLETTA ANZALONE, MD, Neuroradiology Department, San Raffaele Scientific Institute; CLAUDIO DOGLIONI, Professor, MD, Università Vita-Salute San Raffaele, School of Medicine, and Department of Pathology, San Raffaele Scientific Institute; ELISABETTA ZARDINI, PhD, University of Pavia, Pavia; MARIA GRAZIA SABBADINI, Professor, MD, Università Vita-Salute San Raffaele, School of Medicine, and Department of Medicine and Clinical Immunology, San Raffaele Scientific Institute; DIEGO FRANCIOTTA, MD, IRCCS, National Institute of Neurology "C. Mondino", Pavia, Italy. Address correspondence to Dr. E. Della-Torre, Department of Medicine and Clinical Immunology, San Raffaele Scientific Institute, Via Olgettina 60, 20132, Milan, Italy. E-mail: dellatorre.emanuel@hsr.it

REFERENCES

1. Cheuk W, Chan JK. IgG4-related sclerosing disease: a critical appraisal of an evolving clinicopathologic entity. *Adv Anat Pathol* 2010;17:303-32.
2. Deshpande V, Zen Y, Chan JK, Yi EE, Sato Y, Yoshino T, et al. Consensus statement on the pathology of IgG4-related disease. *Mod Pathol* 2012;25:1181-92.
3. Chan SK, Cheuk W, Chan KT, Chan JK. IgG4-related sclerosing pachymeningitis: a previously unrecognized form of central nervous system involvement in IgG4-related sclerosing disease. *Am J Surg Pathol* 2009;33:1249-52.
4. Stone JH, Zen Y, Deshpande V. IgG4-related disease. *N Engl J Med* 2012;366:539-51.
5. Della-Torre E, Bozzolo EP, Passerini G, Doglioni C, Sabbadini MG. IgG4-related pachymeningitis: evidence of intrathecal IgG4 on cerebrospinal fluid analysis. *Ann Intern Med* 2012;156:401-3.
6. Tibbling G, Link H, Ohman S. Principles of albumin and IgG analyses in neurological disorders. I. Establishment of reference values. *Scand J Clin Lab Invest* 1977;37:385-90.
7. Reiber H, Peter JB. Cerebrospinal fluid analysis: disease-related data patterns and evaluation programs. *J Neurol Sci* 2001; 184:101-22.
8. Winter O, Dame C, Jundt F, Hiepe F. Pathogenic long-lived plasma cells and their survival niches in autoimmunity, malignancy, and allergy. *J Immunol* 2012;189:5105-11.
9. Franciotta D, Salvetti M, Lolli F, Serafini B, Aloisi F. B cells and multiple sclerosis. *Lancet Neurol* 2008;7:852-8.
10. Carruthers MN, Stone JH, Deshpande V, Khosroshahi A. Development of an IgG4-RD Responder Index. *Int J Rheumatol* 2012;2012:259408.

J Rheumatol 2013;40:11; doi:10.3899/jrheum.130678