Failure to Control Progression of Rheumatoid Arthritis After a Decade of Biologic Therapy

To the Editor:

Rheumatoid arthritis (RA) is a chronic disease of unspecified etiology that is manifested by persistent inflammation of the synovium. Proinflammatory cytokines such as tumor necrosis factor (TNF), interleukin 6 (IL-6), and B cells are involved in the pathogenesis and chronicity of the inflammatory process in RA, and lead to development of antagonists to treat the disease[1].

Although the use of anticytokine and B cell therapy benefits a substantial number of patients, in some these therapies tend to lose response after the initial benefit[2]. We describe a patient for whom all available biologic therapies, with different mechanisms of action, failed to inhibit progress of the disease throughout a decade. The patient underwent several orthopedic procedures in small and large joints during that period.

Symptoms in our patient started in 1998, when she was 35 years old. She was positive for rheumatoid factor. When anticyclic citrullinated peptide measures became available, she had titers above 200 U on several occasions. In 2002, after she underwent a partial synovectomy of the wrist, she was started on 2 anti-TNF inhibitors sequentially, followed by rituximab, abatacept, and lastly tocilizumab, in 2009. A series of surgical procedures was also performed in the same period, the last in mid-2010 for a total knee replacement (Table 1; Figure 1). At that time a synovial biopsy showed the inflamed synovium with hypertrophy of the lining layer (3–4 layers thick). Cell expression was also increased in the subsynovial lining and large follicle-like aggregates were visible in the tissue. Immunochemical staining (Figure 2) showed the presence of CD3 (T cells), CD20 (B cells), CD68 (macrophages), and CD138 (plasma cells). In one of the germinal center-like structures one can see paracortical T cells surrounding B and plasma cells (CD3, CD68).

Efforts have been undertaken to evaluate the cellular components of the inflamed synovium, in an attempt to determine the precise etiologies of RA. Examination of serial synovial biopsies is now being done for screening purposes and also to establish patterns of drug resistance[3]. In our case, we were able to show that the synovial biopsy obtained during the last surgical procedure was associated with the presence of abundant CD68-positive macrophages and large follicle-like aggregates in the subsynovial lining. Increased numbers of CD68-positive macrophages and the presence of ectopic florid lymphoid neogenesis in the synovium have been reported to be associated with resistance to therapy; this was apparent in our case, after 10 years of biologic treatment[4,5,6]. Similarly, the presence of subtypes of B cells such as CD79a-positive B cells has recently been shown to be increased in the synovial membrane; the investigators suggest that may be a helpful biomarker for disease activity in RA[7].

Current findings support the notion that synovial cellular markers may be used in the future to identify patients who are at risk of having destructive disease. The gradual introduction of new biologics as targeted therapies in the early phase of disease is needed to prevent disease progression and irreversible joint damage. The lack of such early targeted therapy is clearly demonstrated in our patient, who had active disease in spite of a decade of biologic therapy with compounds with different mechanisms of action[8].

Table 1. Orthopedic surgical procedures in our patient.

1999	Elbow synovectomy
2000	Elbow joint replacement
2001	Repair elbow replacement
2002	Right knee synovectomy
2003	Right wrist synovectomy
2004	Shoulder joint replacement
2005	Hand joint replacement
2006	Right knee joint replacement
2007	Ankle joint replacement
2008	Ankle arthrodesis
2009	Wrist arthroplasty
2010	Knee joint replacement

Figure 1. Computed tomography whole-body scan reveals surgical procedures of the shoulder, elbows, wrists, hands, knees, and ankles during a decade.

MORTON SCHEINBERG, MD, PhD, FACP; RENEE ZON FILIPPI, MD, Hospital Israelita Albert Einstein, Sao Paulo, Brazil; REBBECA HANDS, PhD; COSTANTINO PITZALIS, MD, PhD, FRCP, William Harvey Institute, St. Barts and London School of Medicine, London, UK.
Address correspondence to Dr. M. Scheinberg, Hospital Israelita Albert Einstein, Avenida Albert Einstein 627, Sao Paulo, 5651901 Brazil.
E-mail: morton@osite.com.br

REFERENCES

1. Emery P, Dörner T. Optimising treatment in rheumatoid arthritis: A review of potential biological markers of response. Ann Rheum Dis 2011;70:2063-70.

Personal non-commercial use only. The Journal of Rheumatology Copyright © 2012. All rights reserved.

Downloaded on April 24, 2024 from www.jrheum.org

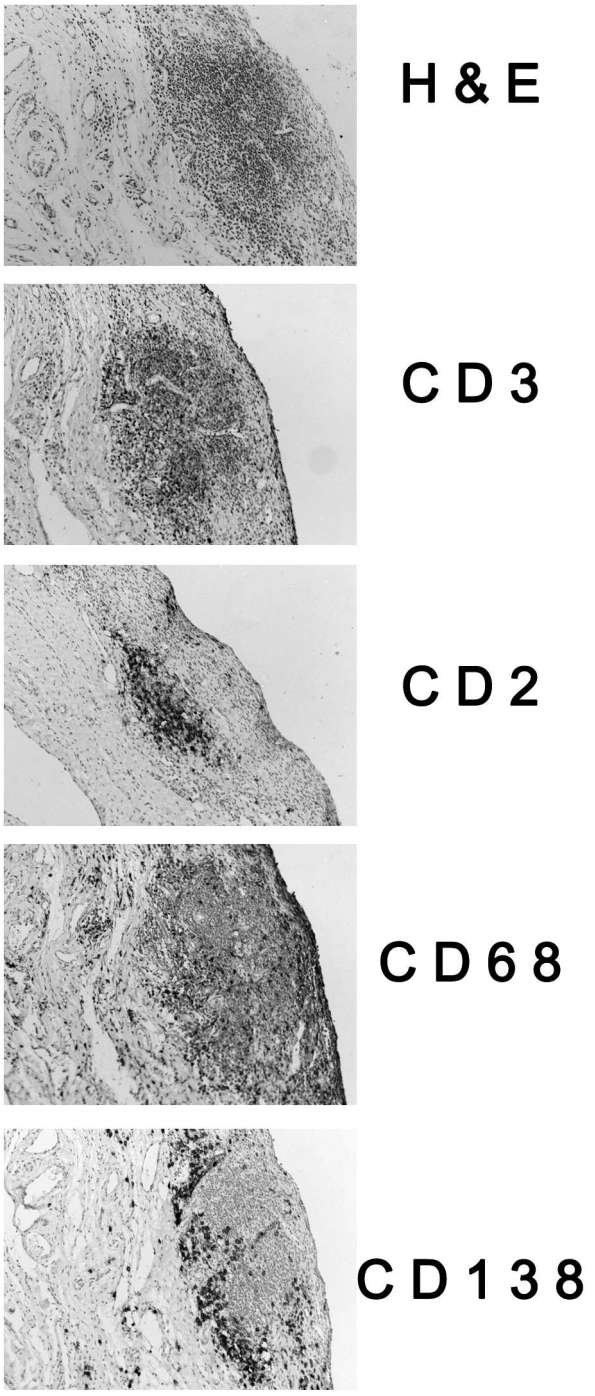

Figure 2. Results from immunohistochemistry analysis with all 4 conjugates that show significant staining; one shows germinal center-like follicles stained for CD20 and "paracortical" T cells, and infiltration of macrophages and plasma cells (CD3, CD138).

2. Scheinberg M, Goldenberg J, Feldman DP, Nóbrega JL. Retrospective study evaluating dose standards for infliximab in patients with rheumatoid arthritis at Hospital Israelita Albert Einstein, São Paulo, Brazil. Clin Rheumatol 2008;27:1049-52.
3. de Hair MJ, Harty LC, Gerlag DM, Pitzalis C, Veale DJ, Tak PP. Synovial tissue analysis for the discovery of diagnostic and prognostic biomarkers in patients with early arthritis. J Rheumatol 2011;38:2068-72.
4. Manzo A, Bombardieri M, Humby F, Pitzalis C. Secondary and ectopic lymphoid tissue responses in rheumatoid arthritis: From inflammation to autoimmunity and tissue damage/remodeling. Review. Immunol Rev 2010;233:267-85.
5. Anolik JH. B cells in the pathogenesis and treatment of rheumatoid arthritis. Curr Opin Rheumatol 2010;3:307-5.
6. Bresnihan B, Pontifex E, Thurlings RM, Vinkenoog M, El-Gabalawy H, Fearon U, et al. Synovial tissue sublining CD68 expression is a biomarker of therapeutic response in rheumatoid arthritis clinical trials: Consistency across centers. J Rheumatol 2009;36:800-2.
7. Mo YQ, Daí L, Zheng DH, Zhu LJ, Wei XN, Pessler F, et al. Synovial infiltration with CD79a-positive B cells, but not other B cell lineage markers, correlates with joint destruction in rheumatoid arthritis. J Rheumatol 2011;38:2301-8.
8. Klareskog L, Gregersen PK, Huizinga TW. Prevention of autoimmune rheumatic disease: State of the art and future perspectives. Review. Ann Rheum Dis 2010;69:2062-6.

J Rheumatol 2012;39:10; doi:10.3899/jrheum.120385

Personal non-commercial use only. The Journal of Rheumatology Copyright © 2012. All rights reserved.

Downloaded on April 24, 2024 from www.jrheum.org