Review

IgG4-related Diseases Including Mikulicz's Disease and Sclerosing Pancreatitis: Diagnostic Insights

YASUFUMI MASAKI, SUSUMU SUGAI, and HISANORI UMEHARA

ABSTRACT. Since the first report of serum IgG4 elevation in sclerosing pancreatitis in 2001, various systemic disorders have been reported to elevate IgG4, and many names have been proposed from the perspective of the systemic condition. Despite similarities in the organs damaged in IgG4-related Mikulicz's disease and Sjögren's syndrome, there are marked clinical and pathological differences between the 2 entities. The majority of cases diagnosed with autoimmune pancreatitis in Japan are IgG4-related sclerosing pancreatitis, and it should be recognized that this is distinct from the Western type. Diagnosis of IgG4-related disease is defined by both elevated serum IgG4 (> 1.35 g/l) and histopathological features, including lymphocyte and IgG4+ plasma cell infiltration (IgG4+ plasma cells/IgG+ plasma cells > 50% on a highly magnified slide checked at 5 points). Differential diagnosis from other distinct disorders is necessary: these include sarcoidosis, Castleman's disease, Wegener's granulomatosis, lymphoma, cancer, and other existing conditions. The Japanese IgG4 research group has begun multicenter prospective studies to improve diagnostic criteria and treatment strategies. (First Release May 1 2010; J Rheumatol 2010;37:1380–5; doi:10.3899/jrheum.091153)

Key Indexing Terms:
MIKULICZ'S DISEASE SJÖGREN'S SYNDROME AUTOIMMUNE PANCREATITIS
GLUCOCORTICOID IgG4-RELATED DISEASES

Mikulicz's disease (MD) was first described in 1892 in a man with symmetrical swelling of the lacrimal, submandibular, and parotid glands[1]. Morgan, *et al* reported 18 cases of MD and concluded that it was not a distinct clinical and pathological disease entity but merely one manifestation of a more generalized symptom complex known as Sjögren's syndrome (SS)[2]. With the wide acceptance of the conclusions of Morgan, *et al* there have been few reports of MD in Western countries. However, many cases of MD have been reported in Japan, and there has been considerable discussion regarding the differences between MD and SS[3-7]. Patients with MD have been reported to have a point mutation in the *FasL* gene, which may account for their mild sicca symptoms despite massive lymphocytic infiltration[3]. Further, high IgG4 concentrations have been reported in the sera of patients with MD[4], suggesting that MD is an IgG4-related disease.

We describe the differences between MD (especially IgG4-related MD) and SS, and refer to other systemic complications of IgG4-related diseases.

Differences between IgG4+ MOLPS and SS. As so-called MD may include various conditions[3-6] and consist of IgG4-related or unrelated subtypes, the IgG4+ multiorgan lymphoproliferative syndrome (MOLPS)/MD research group has established tentative criteria for IgG4+ MD (Table 1).

MATERIALS AND METHODS

We collected data on 64 patients with IgG4+ MOLPS including MD and performed retrospective analysis to clarify the differences between IgG4+ MOLPS and definite SS (Table 2)[7]. Despite similarities in the involved organs, there are marked differences between IgG4+ MOLPS and SS. For example, their sex distributions were quite different. Men with SS were very rare (2 of 31), while almost half (31 of 64) the patients with IgG4+ MOLPS were men.

RESULTS

Significantly fewer patients with IgG4+ MOLPS than with SS showed symptoms of xerostomia, xerophthalmia, and arthralgia. Patients with IgG4+ MOLPS showed significantly lower incidences of rheumatoid factor (RF), antinuclear

From the Department of Hematology and Immunology, Kanazawa Medical University, Kudo General Hospital, Ishikawa, Japan.

Supported by grants from Intractable Diseases, the Health and Labor Sciences Research Grants from the Ministry of Health, Labor, and Welfare, and the Japanese Ministry of Education, Culture, Sports, Science, and Technology (13557160, 15024236, 15390313, and 13877075 to H. Umehara and 17591060 to Y. Masaki), Umehara Memorial Foundation (to H. Umehara), The Vehicle Racing Commemorative Foundation, and the Kanazawa Medical University Research Foundation (C2009-4 to H. Umehara and S2004-16 and S2007-5 to Y. Masaki).

Y. Masaki, MD, PhD, Associate Professor; H. Umehara, MD, PhD, Professor, Department of Hematology and Immunology, Kanazawa Medical University; S. Sugai, MD, PhD, Professor, Department of Hematology and Immunology, Kanazawa Medical University, President, Kudo General Hospital.

Address correspondence to Dr. Y. Masaki, Department of Hematology and Immunology, Kanazawa Medical University, 1-1 Daigaku, Uchinada, Kahoku-gun, Ishikawa, 920-0293, Japan.
E-mail: yasum@kanazawa-med.ac.jp

Accepted for publication February 8, 2010.

Personal non-commercial use only. The Journal of Rheumatology Copyright © 2010. All rights reserved.

Downloaded on April 19, 2024 from www.jrheum.org

Table 1. Diagnostic criteria of IgG4+ Mikulicz's disease (Japanese Sjögren's Syndrome Society, 2008). Differential diagnosis is necessary from other distinct disorders, including sarcoidosis, Castleman's disease, Wegener's granulomatosis, lymphoma, and cancer. The diagnostic criteria for Sjögren's syndrome (SS) may also include some patients with IgG4+ Mikulicz's disease; however, the clinicopathological conditions of patients with typical SS and IgG4+ Mikulicz's disease are different.

1. Symmetrical swelling of at least 2 pairs of the lacrimal, parotid, or submandibular glands continuing for more than 3 months.

AND

2. Elevated serum IgG4 (> 135 mg/dl), OR
3. Histopathological features including lymphocyte and IgG4+ plasma cell infiltration (IgG4+ plasma cells/IgG+ plasma cells > 50%) with typical tissue fibrosis or sclerosis.

Table 2. Comparison of symptoms, complaints, and laboratory findings in IgG4+ MOLPS and typical SS. Data are percentage (number) unless stated otherwise. Incidence rates (numbers of positive patients) are shown for xerophthalmia, xerostomia, arthralgia, allergic rhinitis, bronchial asthma, sclerosing pancreatitis, interstitial nephritis, interstitial pneumonitis, RF, ANA, A-SSA, A-SSB, and low CH50. Masaki Y, *et al*[7]. Ann Rheum Dis 2009; 68:1310-5. Adapted with permission.

Feature	IgG4+ MOLPS	Typical SS	Japanese, %	p
No. of Patients	64	31		
Xerophthalmia	32.8 (21)	93.5 (29)		< 0.001
Xerostomia	37.5 (24)	87.1 (27)		< 0.001
Arthralgia	15.6 (10)	48.4 (15)		0.001
Allergic rhinitis	40.6 (26)	6.5 (2)	5–10	0.001
Bronchial asthma	14.1 (9)	3.2 (1)	3–5	0.158
Sclerosing pancreatitis	17.2 (11)	0 (0)	< 0.001	0.014
Interstitial nephritis	17.2 (11)	6.5 (2)	< 0.005	0.210
Interstitial pneumonitis	9.4 (6)	32.3 (10)	< 0.005	0.008
RF	26.6 (17)	87.1 (27)		< 0.001
ANA	23.4 (15)	90.3 (28)		< 0.001
A-SSA	1.6 (1)	100 (31)		< 0.001
A-SSB	0 (0)	100 (31)		< 0.001
Low CH50	57.8 (37)	48.4 (15)		0.510
IgG, mg/dl	2960.1 (1.7)	2473.4 (1.4)	870–1700	0.042
IgG1, mg/dl	1155.3 (1.6)	1437.1 (1.5)	320–748	0.039
IgG2, mg/dl	786.5 (1.5)	566.6 (1.6)	208–754	0.001
IgG3, mg/dl	57.6 (2.8)	81.9 (1.8)	6.6–88.3	0.047
IgG4, mg/dl	697.7 (2.6)	23.5 (2.1)	4.8–105	< 0.001
IgA, mg/dl	194.7 (1.80)	389.7 (1.7)	110–410	< 0.001
IgM, mg/dl	63.0 (2.0)	147.3 (1.7)	35–220	< 0.001
IgE, IU/ml	307.4 (4.0)	15.3 (1.4)	< 173	0.005

P values are for comparisons of all IgG4+ MOLPS with typical SS. MOLPS: multiorgan lymphoproliferative syndrome; SS: Sjögren's syndrome; RF: rheumatoid factor; ANA: antinuclear antibody. Japanese: Incidence rates of the entire Japanese study population for allergic rhinitis, bronchial asthma, sclerosing pancreatitis, interstitial nephritis, interstitial pneumonitis, and ranges of normal laboratory values of total IgG, IgG1, IgG2, IgG3, IgG4, IgA, IgM, and IgE. IgE was measured in 50 patients (not all), and IgG1, IgG2, and IgG3 were measured in 58 patients (not all), with IgG4+ MOLPS. Geometric means (geometric SD) are shown for IgG, IgG1, IgG2, IgG3, IgG4, IgE, IgA, and IgM concentrations. Patients with typical SS fulfilled both Japanese[8] and European[9] SS criteria, and were positive for both anti-SSA/Ro and anti-SSB/La antibodies.

antibody (ANA), anti-SSA/Ro antibody, and anti-SSB/La antibody than patients with SS. We found that not only IgG4 but also total IgG, IgG2, and IgE concentrations were significantly higher in patients with IgG4+ MOLPS than in patients with SS[7]. Almost half of patients with IgG4+ MOLPS demonstrated low CH50, which apparently correlated with hyper-IgG (especially IgG1 and IgG2).

Histological specimens from patients with IgG4+ MOLPS showed marked IgG4+ plasma cell infiltration with occasional lymphocyte follicular formation, but without lymphoepithelial lesions (Figure 1)[7]. This may explain the marked glandular swelling without severe dryness in patients with IgG4+ MOLPS. Importantly, treatment with glucocorticoids resulted in marked clinical improvements in almost all patients with IgG4+ MOLPS, while the effects of glucocorticoids on SS were not so dramatic[10].

Personal non-commercial use only. The Journal of Rheumatology Copyright © 2010. All rights reserved.

Downloaded on April 19, 2024 from www.jrheum.org

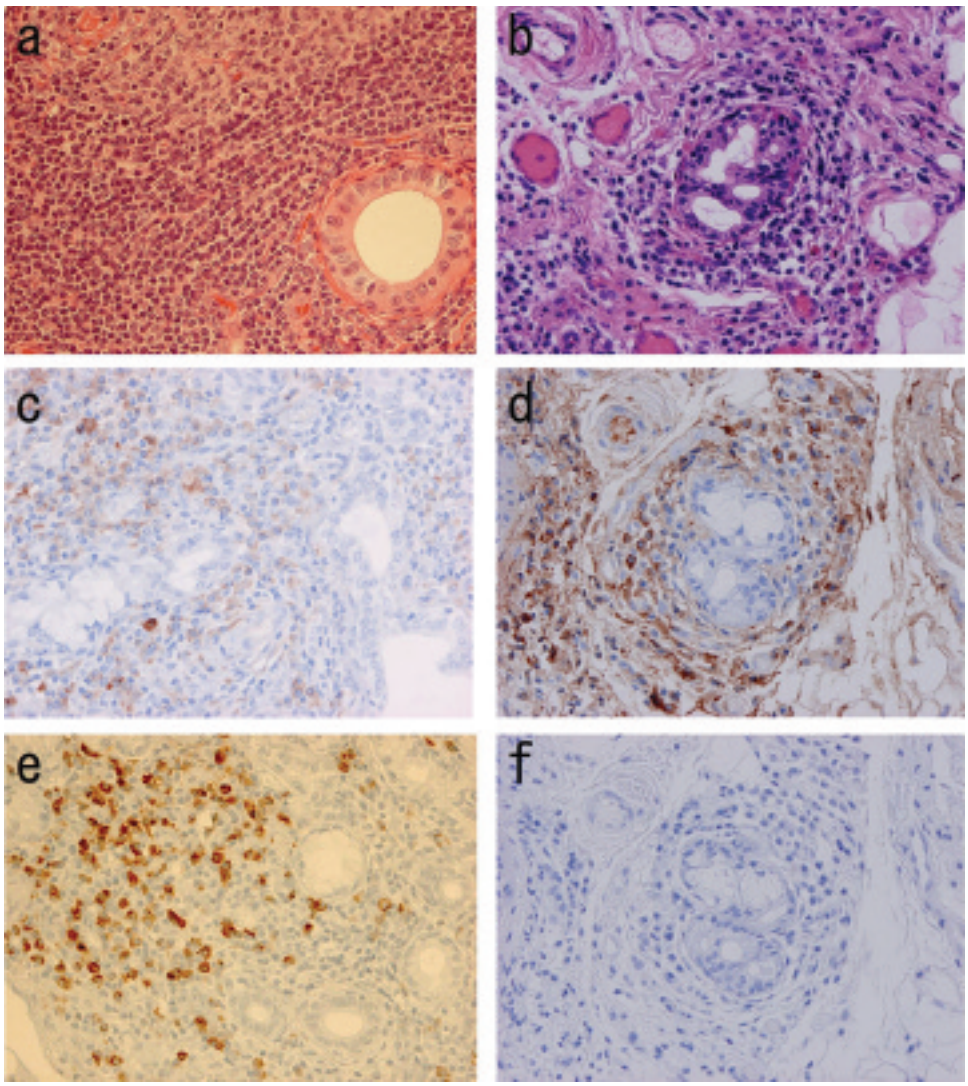

Figure 1. Histopathological findings of labial minor salivary gland biopsy in patients with IgG4+ MOLPS/Mikulicz's disease (a, c, e) and Sjögren's syndrome (b, d, f). (a, b) Hematoxylin and eosin staining; (c, d) IgG immunostaining; (e, f) IgG4 immunostaining. (a) Massive lymphocyte and plasmacyte infiltration and lymphoid follicle formation were seen in IgG4+ MOLPS. The ducts remained clear without lymphocytic infiltration. Both IgG+ and IgG4+ plasma cells were scattered in the periphery of the follicles (c, e). In contrast, there were few or no IgG4+ cells in typical SS (d, f), not even in patients with severe lymphocytic infiltration (b).

Autoimmune pancreatitis and IgG4. Autoimmune pancreatitis (AIP) is a unique form of chronic pancreatitis, first described by Sarles, *et al* in 1961[11] and characterized by infrequent attacks of abdominal pain, jaundice, irregular narrowing of the pancreatic duct, and swelling of the pancreatic parenchyma[11-22]. Kawaguchi, *et al* described cases complicated with similar pathological features in the common bile duct, gall bladder, and minor salivary glands, suggesting a systemic disorder[12]. Yoshida, *et al* described the typical features of AIP as hyper-γ-globulinemia, the presence of autoantibodies (RF and ANA), lymphocytic infiltration of pancreas tissue, coexistence of other manifestations such as sicca complex, and good responsiveness to glucocorticoids[13]. AIP is now known to be associated with types of sialadenitis and cholangitis distinct from SS and primary sclerosing cholangitis.

In 2001, Hamano, *et al* first reported high serum IgG4 concentrations in patients with sclerosing pancreatitis[14]. Further, massive IgG4+ plasmacytic infiltration in the pancreatic tissue was reported[15]. There have been many recent reports of AIP in Asia[12-19] and in Western countries[20,21].

Various diagnostic criteria for AIP have been proposed in Japan[23], Korea[17], and the United States (Mayo Clinic)[21]. In 2008, the Japan-Korea Symposium on AIP proposed Asian diagnostic criteria[19]. Further international criteria are currently under discussion.

Personal non-commercial use only. The Journal of Rheumatology Copyright © 2010. All rights reserved.

Downloaded on April 19, 2024 from www.jrheum.org

IgG4 and other clinical conditions (Figure 2). Hyper-IgG4-γ-globulinemia and IgG4+ plasma cell infiltration with sclerotic lesions, although first reported in patients with sclerosing pancreatitis, have also been reported in patients with many other disorders, including sclerosing cholangitis[15,16]; inflammatory pseudotumors of the lung[24], liver[16], and breast[16,25]; retroperitoneal or mediastinal fibrosis[26]; interstitial nephritis[27]; hypophysitis[5]; sclerosing dacryoadenitis[28]; sialadenitis (MD and Küttner's tumor)[4,5,29]; inflammatory aortic aneurysm[30,31]; tumorous lesions of the coronary artery[31]; lymphadenopathy[32]; and many other inflammatory conditions in multiple organs.

In addition, various systemic involvements have been reported in each disorder. Kawaguchi, *et al*[12] noted the same etiology between autoimmune pancreatitis and multifocal idiopathic fibrosclerosis (MIF) reported by Comings, *et al*[33] because both conditions include occlusive phlebitis and sclerotic lesions.

DISCUSSION

Proposal of a new clinical entity, IgG4+ MOLPS, as a more generalized disorder. In addition to the term "IgG4+ MOLPS," there are many synonyms, such as MIF, IgG4-related autoimmune disease[15], IgG4-related plasmacytic disease[6], and IgG4-related sclerosing disease[18], all of which may refer to the same conditions.

Although various other disorders have been associated with hyper-IgG4-γ-globulinemia, including multicentric Castleman's disease[34], Wegener's granulomatosis[35], lymphoma[36,37], and cancer[38], IgG4+ MOLPS should be defined as a distinct clinicopathological entity, characterized by sclerosing sialadenitis and dacryoadenitis, AIP, sclerosing cholangitis, and other clinical conditions with good response to glucocorticoids.

Hypothetical mechanism of IgG4+ MOLPS. At present, the pathogenesis of IgG4+ MOLPS is not clear. Although some patients are positive for RF and ANA, these incidences are significantly lower than in SS, suggesting that RF and ANA positivity may be due to nonspecific immunoglobulin binding. Although IgG4+ MOLPS is accompanied by various immunological disorders, including AIP, there is little evidence that IgG4+ MOLPS is an autoimmune disorder because of the lack of disease-specific autoantibodies.

The role of IgG4 in IgG4+ MOLPS is still unknown. IgG4 represents the smallest population among IgG subclasses in the sera of normal subjects (3%–6% of total IgG), and is unique among the IgG subclasses in its inability to bind with the C1q complement[39]. IgG4 is associated with the pathogenicity of a small number of disorders, such as atopic dermatitis, parasitic disease, pemphigus vulgaris, and pemphigus foliaceus.

In clonality analysis, most tissue-infiltrating and circulating IgG4-positive cells are polyclonal[40]. These findings have suggested that IgG4 does not play a major pathological role in IgG4+ MOLPS, and that there may be other upstream regulators in its pathogenesis.

Zen, *et al* reported that the pathogenesis of IgG4-related AIP was characterized by the infiltration of T helper 2 and regulatory T cells (Treg), which secrete various cytokines such as interleukin 10 (IL-10) and tumor growth factor-ß (TGF-ß)[41]. Moreover, the level of Foxp3 messenger RNA expression was significantly increased in patients with AIP, and immunohistochemical staining revealed increases in the numbers of CD4+ CD25+ Foxp3+ cells. Treg may be

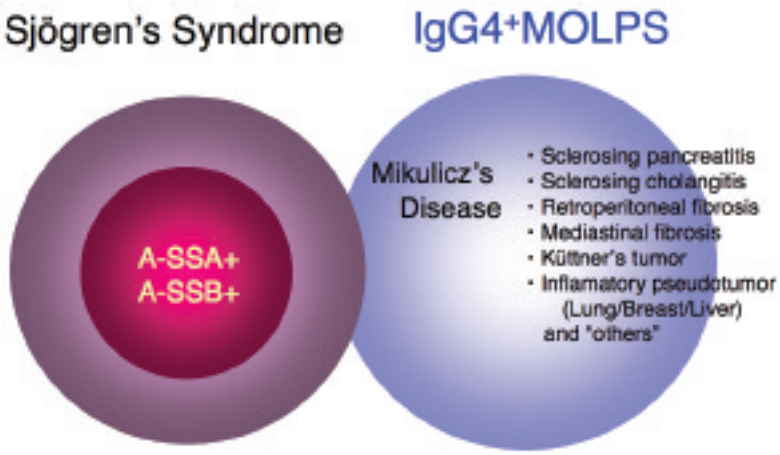

Figure 2. IgG4+ MOLPS should be defined as a distinct clinicopathological entity that includes Mikulicz's disease (MD), autoimmune pancreatitis (AIP), sclerosing cholangitis, and other clinical conditions with good response to glucocorticoids. Although the diagnostic criteria of SS may include some patients with IgG4+ MOLPS/MD, typical SS and IgG4+ MOLPS/MD are different clinical conditions.

Personal non-commercial use only. The Journal of Rheumatology Copyright © 2010. All rights reserved.

Downloaded on April 19, 2024 from www.jrheum.org

involved in the *in situ* production of IL-10 and TGF-ß, which could be followed by IgG4 class switching and fibroplasia[41].

The concentrations of IgG2, IgG4, and IgE have been shown to be significantly higher in patients with IgG4+ MOLPS than in those with typical SS, while the concentrations of IgG1, IgG3, IgA, and IgM were significantly higher in patients with typical SS than in those with IgG4+ MOLPS[7]. The immunoglobulin gene fragments $C\mu$, $C\delta$, $C\gamma3$, $C\gamma1$, $C\alpha1$, $C\gamma2$, $C\gamma4$, $C\varepsilon$, and $C\alpha2$, which encode IgM, IgD, IgG3, IgG1, IgA1, IgG2, IgG4, IgE, and IgA2, respectively, are arranged linearly in this order from upstream to downstream. Gene linkage and different class-switch mechanisms may cause the hyperproduction of the different immunoglobulin subclasses observed in these 2 diseases, which may contribute to the pathophysiology of IgG4+ MOLPS.

Future perspectives. Although IgG4+ MOLPS may be distributed worldwide, this disease entity has not been well recognized to date. Most reports on IgG4-related diseases have been from Japan, while many reports on AIP have come from Western countries, especially the Mayo Clinic[21] in the United States. Therefore, we believe that an international consensus regarding IgG4-related diseases as new clinical entities is required.

In this regard, the Japanese IgG4 research group (Research Committee of Intractable Diseases, Health and Labor Sciences Research Grants, Ministry of Health, Labor and Welfare, Japan) has begun multicenter prospective clinical studies (UMIN: R000002820, R000002823) to formulate better diagnostic criteria, to identify novel diagnostic and prognostic factors, and to design better treatment strategies.

ACKNOWLEDGMENT

We thank all participants in the IgG4+ MOLPS/Mikulicz's Disease Research Group and the researchers of the Autoimmune Pancreatitis Group for critical discussion.

REFERENCES

1. Mikulicz J. Über eine eigenartige symmetrische erkrankung der tränen und mundspeicheldrüsen. Stuttgart: Beitr.z.Chir.Fesrschr.f. Theodor Billroth; 1892:610-30.
2. Morgan WS, Castleman B. A clinicopathologic study of Mikulicz's disease. Am J Pathol 1953;29:471-503.
3. Tsubota K, Fujita H, Tadano K, Onoda N, Tsuzaka K, Takeuchi T. Abnormal expression and function of Fas ligand of lacrimal glands and peripheral blood in Sjögren's syndrome patients with enlarged exocrine glands. Clin Exp Immunol 2002;129:177-82.
4. Yamamoto M, Ohara M, Suzuki C, Naishiro Y, Yamamoto H, Takahashi H, et al. Elevated IgG4 concentrations in serum of patients with Mikulicz's disease. Scand J Rheumatol 2004;33:432-3.
5. Yamamoto M, Ohara M, Suzuki C, Naishiro Y, Yamamoto H, Takahashi H, et al. A case of Mikulicz's disease (IgG4-related plasmacytic disease) complicated by autoimmune hypophysitis. Scand J Rheumatol 2006;35:410-1.
6. Yamamoto M, Takahashi H, Ohara M, Suzuki C, Naishiro Y, Yamamoto H, et al. A new conceptualization for Mikulicz's disease as an IgG4-related plasmacytic disease. Mod Rheumatol 2006;16:335-40.
7. Masaki Y, Dong L, Kurose N, Kitagawa K, Morikawa Y, Yamamoto M, et al. Proposal for a new clinical entity, IgG4-positive multiorgan lymphoproliferative syndrome: Analysis of 64 cases of IgG4-related disorders. Ann Rheum Dis 2009;68:1310-5.
8. Fujibayashi T, Sugai S, Tojo T, Miyawaki S, Miyasaka N, Ichikawa Y, et al. Revised Japanese criteria for Sjögren's syndrome (1999): availability and validity. Mod Rheumatol 2004;14:425-34.
9. Vitali C, Bombardieri S, Jonsson R, Moutsopoulos HM, Alexander EL, Carsons SE, et al. European Study Group on Classification Criteria for Sjögren's Syndrome. Classification criteria for Sjögren's syndrome: a revised version of the European criteria proposed by the American-European Consensus Group. Ann Rheum Dis 2002;61:554-8.
10. Miyawaki S, Nishiyama S, Matoba K. Efficacy of low-dose prednisolone maintenance for saliva production and serological abnormalities in patients with primary Sjögren's syndrome. Intern Med 1999;38:938-43.
11. Sarles H, Sarles JC, Muratore R, Guien C. Chronic inflammatory sclerosis of the pancreas — an autonomous pancreatic disease? Am J Dig Dis 1961;6:688-98.
12. Kawaguchi K, Koike M, Tsuruta K, Okamoto A, Tabata I, Fujita N. Lymphoplasmacytic sclerosing pancreatitis with cholangitis: a variant of primary sclerosing cholangitis extensively involving pancreas. Hum Pathol 1991;22:387-95.
13. Yoshida K, Toki F, Takeuchi T, Watanabe S, Shiratori K, Hayashi N. Chronic pancreatitis caused by an autoimmune abnormality. Proposal of the concept of autoimmune pancreatitis. Dig Dis Sci 1995;40:1561-8.
14. Hamano H, Kawa S, Horiuchi A, Unno H, Furuya N, Akamatsu T, et al. High serum IgG4 concentrations in patients with sclerosing pancreatitis. N Engl J Med 2001;344:732-8.
15. Kamisawa T, Funata N, Hayashi Y, Eishi Y, Koike M, Tsuruta K, et al. A new clinicopathological entity of IgG4-related autoimmune disease. J Gastroenterol 2003;38:982-4.
16. Zen Y, Harada K, Sasaki M, Sato Y, Tsuneyama K, Haratake J, et al. IgG4-related sclerosing cholangitis with and without hepatic inflammatory pseudotumor, and sclerosing pancreatitis-associated sclerosing cholangitis: do they belong to a spectrum of sclerosing pancreatitis? Am J Surg Pathol 2004;28:1193-203.
17. Kim KP, Kim MH, Kim JC, Lee SS, Seo DW, Lee SK. Diagnostic criteria for autoimmune chronic pancreatitis revisited. World J Gastroenterol 2006;12:2487-96.
18. Kamisawa T, Okamoto A. Autoimmune pancreatitis: proposal of IgG4-related sclerosing disease. J Gastroenterol 2006;41:613-25.
19. Otsuki M, Chung JB, Okazaki K, Kim MH, Kamisawa T, Kawa S, et al. Research Committee of Intractable Pancreatic Diseases provided by the Ministry of Health, Labor and Welfare of Japan and the Korean Society of Pancreatobiliary Diseases. Asian diagnostic criteria for autoimmune pancreatitis: consensus of the Japan-Korea Symposium on Autoimmune Pancreatitis. J Gastroenterol 2008;43:403-8.
20. Notohara K, Burgart LJ, Yadav D, Chari S, Smyrk TC. Idiopathic chronic pancreatitis with periductal lymphoplasmacytic infiltration: clinicopathologic features of 35 cases. Am J Surg Pathol 2003;27:1119-27.
21. Chari ST, Smyrk TC, Levy MJ, Topazian MD, Takahashi N, Zhang L, et al. Diagnosis of autoimmune pancreatitis: The Mayo Clinic experience. Clin Gastroenterol Hepatol 2006;4:1010-6.
22. Okazaki K, Kawa S, Kamisawa T, Ito T, Inui K, Irie H, et al. Japanese clinical guidelines for autoimmune pancreatitis. Pancreas 2009;38:849-66.

Personal non-commercial use only. The Journal of Rheumatology Copyright © 2010. All rights reserved.

Downloaded on April 19, 2024 from www.jrheum.org

23. Okazaki K, Kawa S, Kamisawa T, Naruse S, Tanaka S, Nishimori I, et al. Research Committee of Intractable Diseases of the Pancreas. Clinical diagnostic criteria of autoimmune pancreatitis: revised proposal. J Gastroenterol 2006;41:626-31.
24. Zen Y, Kitagawa S, Minato H, Kurumaya H, Katayanagi K, Masuda S, et al. IgG4-positive plasma cells in inflammatory pseudotumor (plasma cell granuloma) of the lung. Hum Pathol 2005;36:710-7.
25. Zen Y, Kasahara Y, Horita K, Miyayama S, Miura S, Kitagawa S, et al. Inflammatory pseudotumor of the breast in a patient with a high serum IgG4 level: histologic similarity to sclerosing pancreatitis. Am J Surg Pathol 2005;29:275-8.
26. Zen Y, Sawazaki A, Miyayama S, Notsumata K, Tanaka N, Nakanuma Y. A case of retroperitoneal and mediastinal fibrosis exhibiting elevated levels of IgG4 in the absence of sclerosing pancreatitis (autoimmune pancreatitis). Hum Pathol 2006;37:239-43.
27. Saeki T, Saito A, Yamazaki H, Emura I, Imai N, Ueno M, et al. Tubulointerstitial nephritis associated with IgG4-related systemic disease. Clin Exp Nephrol 2007;11:168-73.
28. Cheuk W, Yuen HK, Chan JK. Chronic sclerosing dacryoadenitis: part of the spectrum of IgG4-related sclerosing disease? Am J Surg Pathol 2007;31:643-5.
29. Kitagawa S, Zen Y, Harada K, Sasaki M, Sato Y, Minato H, et al. Abundant IgG4-positive plasma cell infiltration characterizes chronic sclerosing sialadenitis (Küttner's tumor). Am J Surg Pathol 2005;29:783-91.
30. Kasashima S, Zen Y, Kawashima A, Konishi K, Sasaki H, Endo M, et al. Inflammatory abdominal aortic aneurysm: close relationship to IgG4-related periaortitis. Am J Surg Pathol 2008;32:197-204.
31. Matsumoto Y, Kasashima S, Kawashima A, Sasaki H, Endo M, Kawakami K, et al. A case of multiple immunogloblin G4-related periarteritis: a tumorous lesion of the coronary artery and abdominal aortic aneurysm. Hum Pathol 2008;39:975-80.
32. Cheuk W, Yuen HK, Chu SY, Chiu EK, Lam LK, Chan JK. Lymphadenopathy of IgG4-related sclerosing disease. Am J Surg Pathol 2008;32:671-81.
33. Comings DE, Skubi KB, Van Eyes J, Motulsky AG. Familial multifocal fibrosclerosis. Findings suggesting that retroperitoneal fibrosis, mediastinal fibrosis, sclerosing cholangitis, Riedel's thyroiditis, and pseudotumor of the orbit may be different manifestations of a single disease. Ann Intern Med 1967;66:884-92.
34. Ishida F, Kitano K, Kobayashi H, Saito H, Kiyosawa K. Elevated IgG4 levels in a case with multicentric Castleman's disease. Br J Haematol 1997;99:981-2.
35. Brouwer E, Tervaert JW, Horst G, Huitema MG, van der Giessen M, Limburg PC, et al. Predominance of IgG1 and IgG4 subclass of anti-neutrophil cytoplasmic autoantibodies (ANCA) in patients with Wegener's granulomatosis and clinically related disorders. Clin Exp Immunol 1991;83:379-86.
36. Cheuk W, Yuen HK, Chan AC, Shih LY, Kuo TT, Ma MW, et al. Ocular adnexal lymphoma associated with IgG4+ chronic sclerosing dacryoadenitis: a previously undescribed complication of IgG4-related sclerosing disease. Am J Surg Pathol 2008;32:1159-67.
37. Sato Y, Ohshima K, Ichimura K, Sato M, Yamadori I, Tanaka T, et al. Ocular adnexal IgG4-related disease has uniform clinicopathology. Pathol Int 2008;58:465-70.
38. Oh HC, Kim JG, Kim JW, Lee KS, Kim MK, Chi KC, et al. Early bile duct cancer in a background of sclerosing cholangitis and autoimmune pancreatitis. Intern Med 2008;47:2025-8.
39. van der Zee JS, van Swieten P, Aalberse RC. Inhibition of complement activation by IgG4 antibodies. Clin Exp Immunol 1986;64:415-22.
40. Yamada K, Kawano M, Inoue R, Hamano R, Kakuchi Y, Fujii H, et al. Clonal relationship between infiltrating immunoglobulin G4 (IgG4)-positive plasma cells in lacrimal glands and circulating IgG4-positive lymphocytes in Mikulicz's disease. Clin Exp Immunol 2008;152:432-9.
41. Zen Y, Fujii T, Harada K, Kawano M, Yamada K, Takahira M, et al. Th2 and regulatory immune reactions are increased in immunoglobulin G4-related sclerosing pancreatitis and cholangitis. Hepatology 2007;45:1538-46.

Personal non-commercial use only. The Journal of Rheumatology Copyright © 2010. All rights reserved.

Downloaded on April 19, 2024 from www.jrheum.org