Cardiovascular Magnetic Resonance Imaging of Myocardial Fibrosis in Dermatomyositis

CHRISTIANE ARNOLD, Dipl. Sport Science, German Sports University, Cologne; HASSAN ABDEL-ATY, MD; CHRISTOPH TILLMANNS, MD, Cardio Imaging Center, Diagnostikum Berlin, Berlin, Germany. Address correspondence to Dr. C. Tillmanns, Cardio Imaging Center Berlin, Paretzer Str. 12, 10713 Berlin-Wilmersdorf, Germany. E-mail: tillmanns@cardiomrt.de. J Rheumatol 2010;37:1056; doi:10.3899/jrheum.090946

Cardiac involvement in dermatomyositis (DM) is infrequent but is associated with poor prognosis[1]. Myocardial fibrosis has been observed in histopathological studies of DM and has been attributed to myocardial inflammation[2]. Reports describing its noninvasive *in vivo* visualization in DM are lacking. Fibrosis represents a common substrate of ventricular arrhythmias in an array of non-ischemic cardiomyopathies and possibly in DM as well[3].

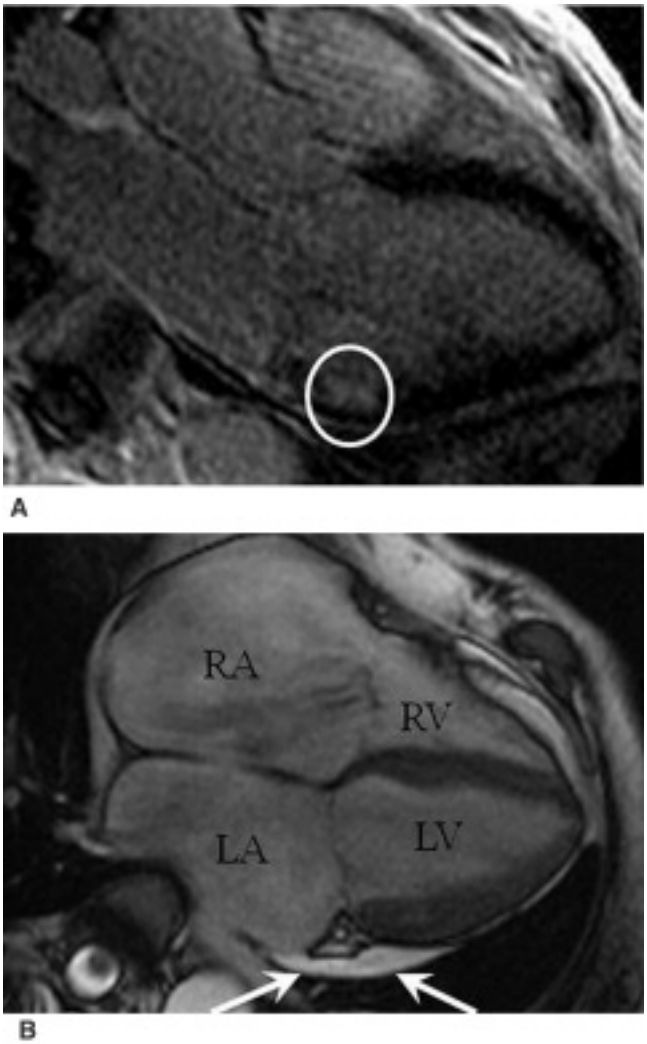

Figure 1. Myocardial late enhancement was noted in the basal posterolateral wall (A: circle), together with a small pericardial effusion (B: arrows). RA: right atrium; RV: right ventricle; LA: left atrium; LV: left ventricle.

A 58-year-old woman with DM first diagnosed 6 years earlier was referred for cardiovascular magnetic resonance imaging (MRI) because of progressive exertional dyspnea. Examination revealed bilateral atrial enlargement, which was much more pronounced in the right atrium (steady-state free precession). In addition, an area of myocardial late enhancement (inversion-recovery gradient echo) was noted in the basal posterolateral wall, together with a small pericardial effusion (Figure 1). There was no evidence of myocardial edema (T2-weighted image) or hyperemia (early contrast-enhancement), considering the skeletal muscle as an internal reference. Coronary angiography revealed no significant coronary artery stenosis, indicating that the fibrosis was non-ischemic.

The unique ability of cardiovascular MRI to visualize focal myocardial fibrosis noninvasively in this setting may offer a novel method of risk stratification.

REFERENCES

1. Lundberg IE. The heart in dermatomyositis and polymyositis. Rheumatology 2006;45:18-21.
2. Pardo J, Meruane J, Staeding J, Drago G, Etchart M. Cardiac involvement in polymyositis — dermatomyositis associated with Sjogren's syndrome. Rev Med Chil 1995;122:550-5.
3. Abdel-Aty H, Boyé P, Zagrosek A, Wassmuth R, Kumar A, Messroghli D, et al. Diagnostic performance of cardiovascular magnetic resonance in patients with suspected acute myocarditis: comparison of different approaches. J Am Coll Cardiol 2005;45:1815-22.