

Lipoma Arborescens: Recurrent Knee Effusions with Positive Cyclic Citrullinated Peptide

ELAINE A. YACYSHYN, MD, FRCPC, Department of Medicine; ROBERT G.W. LAMBERT, MB, FRCR, FRCPC, Department of Radiology and Diagnostic Imaging, University of Alberta. Address correspondence to Dr. E. Yacyshyn, 562 Heritage Medical Research Center 9440 – 112 Street, Edmonton, Alberta T6G 2S2, Canada. E-mail: eyacyshyn@ualberta.ca *J Rheumatol* 2010;37:2188–9; doi:10.3899/jrheum.100326

Lipoma arborescens is commonly associated with osteoarthritis (OA) and joint trauma, although inflammatory arthritis has also been described¹. This is the first known description of a positive anti-cyclic citrullinated peptide (anti-CCP) antibody in conjunction with lipoma arborescens².

A 32-year-old woman presented with left knee pain. Symptoms that had begun 7 years previously had resolved with pregnancy and then recurred post-partum. Left knee corticosteroid injection was beneficial. She described recurrent swelling and difficulty kneeling and ascending stairs. She had a distant history of childhood idiopathic thrombocytopenic purpura and intermittent carpal tunnel symptoms. Physical examination showed a prominent Baker's cyst, and left knee and bilateral wrist synovitis. Laboratory results including erythrocyte sedimentation rate, C-reactive protein, rheumatoid factor, and antinuclear antibodies were normal. Radiographs and bone scans were negative; aspiration was declined. Magnetic resonance imaging (MRI) scan of the knee showed evidence of lipoma arborescens. Bilateral wrist MRI showed bilateral diffuse tenosynovitis of flexor and extensor tendons, which responded to corticosteroid injections.

Knee synovectomy performed one year later resolved

symptoms and confirmed the diagnosis. She was later found to be positive for anti-CCP antibody; she has early rheumatoid arthritis.

She declined disease modifying therapy. MRI of the knee showed a large suprapatellar effusion with frond-like fatty proliferation originating from the synovial membrane. This appearance is typical of lipoma arborescens, a rare benign intraarticular synovial lipoma that is metaplastic in nature (Figure 1). Typically, this condition affects a single knee joint³.

We describe a positive anti-CCP antibody in conjunction with lipoma arborescens². This condition should be considered in patients who have recurrent symptoms and atypical presentations. MRI is diagnostic of this condition.

REFERENCES

1. Weston WJ. The intra-synovial fatty masses in chronic rheumatoid arthritis. *Br J Radiol* 1973;46:213-6.
2. Santiago M, Passos AS, Medeiros AF, Sá D, Correia Silva TM, Fernandes JL. Polyarticular lipoma arborescens with inflammatory synovitis. *J Clin Rheumatol* 2009;15:306-8.
3. Siva C, Brasington R, Totty W, Sotelo A, Atkinson J. Synovial lipomatosis (lipoma arborescens) affecting multiple joints in a patient with congenital short bowel syndrome. *J Rheumatol* 2002;29:1088-92.

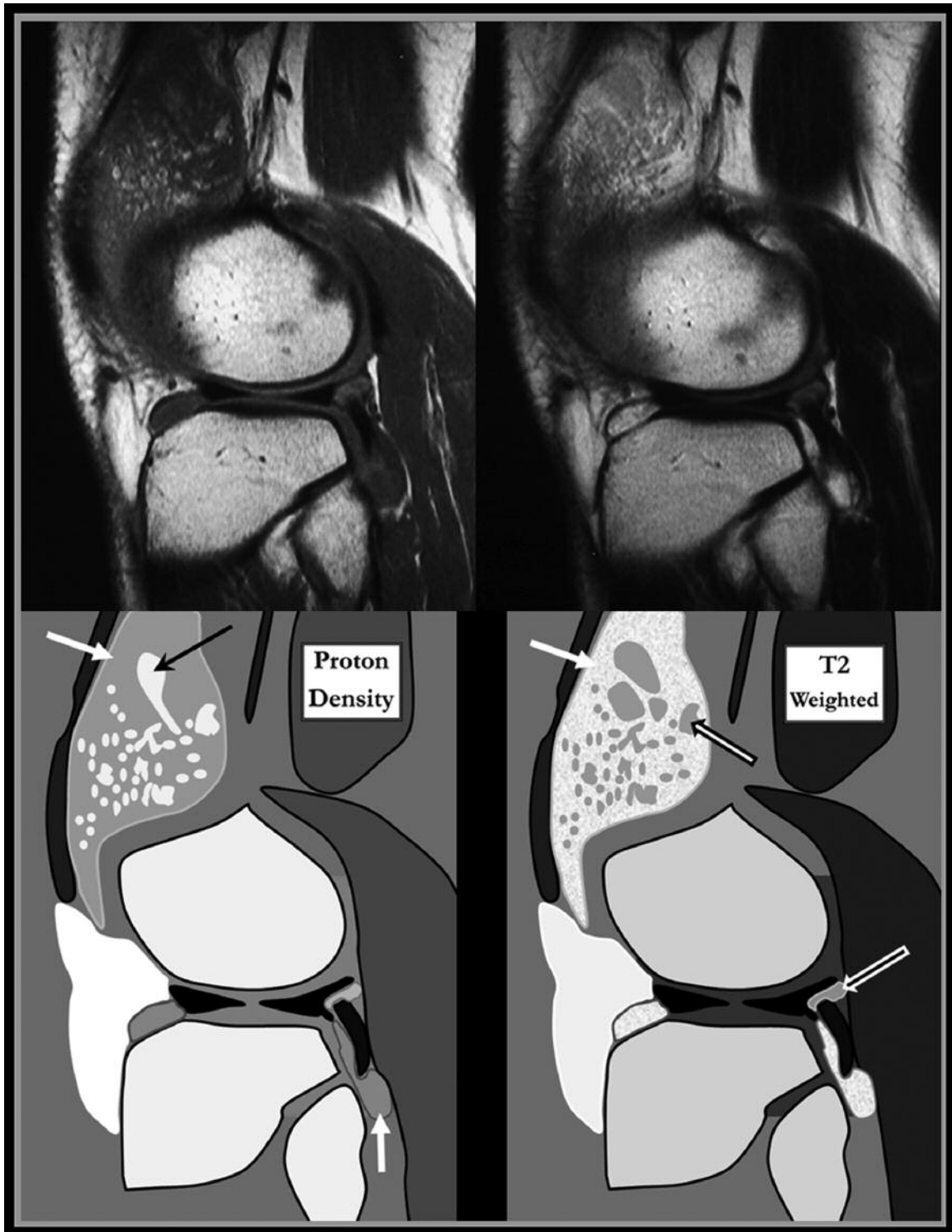


Figure 1. On magnetic resonance imaging, synovial fluid in the knee joint appears grey in signal intensity on proton density images (PD; left panels) and bright on T2 weighted images (T2w; right; white arrows at suprapatellar bursa and popliteus tendon sheath). Synovial thickening is usually isointense to joint fluid on PD, but is grey on T2w images and stands out from the synovial fluid on this sequence (black-white arrows on T2w at suprapatellar bursa and popliteus tendon sheath). In our case, multiple small foci of bright signal intensity are seen in the synovial space on the PD image. This is typical of fat signal arising from the synovium in lipoma arborescens (black arrow).