

Longstanding Remission of Adult Onset Still's Disease Under Imatinib Therapy in a Patient with Chronic Myelogenous Leukemia

To the Editor:

Imatinib mesylate is a potent and selective inhibitor of tyrosine kinases such as Bcr-Abl, platelet-derived growth factor (PDGF) receptor, and c-Kit, and it is widely used to treat chronic myeloid leukemia (CML) and c-Kit-positive gastrointestinal stromal tumors. Imatinib also exerts potent immunomodulatory effects *in vitro* and *in vivo*<sup>1</sup>. Recent reports described the efficacy of imatinib in treating patients with various autoimmune and inflammatory diseases such as rheumatoid arthritis (RA), systemic sclerosis, pulmonary arterial hypertension, and lupus nephritis<sup>2-5</sup>.

We describe a patient with steroid-resistant adult onset of Still's disease (AOSD), who incidentally developed CML. Treatment with imatinib induced hematological remission of CML as well as improvement of symptoms of AOSD. Immunosuppressants were tapered and discontinued 2 years after the initial imatinib treatment. The patient has maintained remission of AOSD for 5 years under imatinib treatment.

In August 2000, a 25-year-old Japanese man was admitted to the Department of General Medicine, Kyushu University Hospital, due to fever of unknown origin. He exhibited symptoms of pharyngitis, arthralgia, typical rash, leukocytosis, high level of C-reactive protein (CRP; 33.0 mg/dl), and hyperferritinemia (19,777 ng/ml). A diagnosis of AOSD was made based on his symptoms and these results. He was treated with prednisolone (PSL; 1 mg/kg daily). However, the disease proved to be steroid-resistant. Treatment with methylprednisolone pulse therapy (1000 mg for 3 days) in combination with cyclosporine (CSP) and cyclophosphamide resulted in gradual clinical improvement (Figure 1). Cyclophosphamide was discontinued, and PSL (0.25 mg/kg/day) and CSP (5 mg/kg/day) were taken daily as outpatient medication. However, he was frequently readmitted because of high fever, rash, and arthralgia. He experienced frequent AOSD flares, for which he eventually received treatment with pulse methylprednisolone along with increased doses of PSL and CSP (Figure 1).

In July 2002, he was referred to the Department of Hematology, Kyushu University Hospital, for evaluation of leukocytosis. A peripheral blood test revealed a white blood cell count of  $69.9 \times 10^9/l$  (0.4% blasts, 0.4% promyelocytes, 14.4% myelocytes, 5.4% metamyelocytes, 70.3% neutrophils, 7% eosinophils, 1.7% basophils, and 3.8% lymphocytes). A bone marrow aspirate showed hypercellular marrow with marked myeloid predominance. Chromosomal and molecular analyses revealed 46,XY,t(9;22)(q34;q11) in all metaphases and the presence of major-BCR/ABL

fusion transcript. He was diagnosed with chronic-phase CML. Treatment with imatinib 400 mg daily was initiated, resulting in a prompt decrease in the number of white blood cells; he exhibited a hematological and molecular response to CML. Following treatment with imatinib, he experienced no more high fevers, rashes, and arthralgia as in previous episodes. In July 2003, he was finally cured of these symptoms and had a marked decrease in serum levels of ferritin and CRP (Figure 1). Immunosuppressants were tapered, and PSL and CSP were discontinued in January and July 2004, respectively (Figure 1). Thereafter, he has maintained a molecular remission of CML. Since imatinib treatment he has completed 4 years with no symptoms of AOSD.

To our knowledge, this is the first report of the efficacy of imatinib in a patient with AOSD. Despite the standard immunosuppressive treatment for AOSD, our patient exhibited frequent flares that required increased dosage of corticosteroids and calcineurin inhibitors, in addition to methylprednisolone pulse therapy and cyclophosphamide therapy. Alternative therapy of biological agents such as interleukin 1 (IL-1) receptor antagonist, IL-6 receptor antibody, and tumor necrosis factor (TNF) inhibitors might have been considered for this patient. However, 2 years after the diagnosis of AOSD, he incidentally developed CML. Treatment with imatinib 400 mg daily resulted in a hematological and molecular remission of CML as well as a gradual clinical improvement of AOSD, allowing tapering of CSP and PSL. One year after imatinib treatment, AOSD symptoms had completely disappeared, and after 2 years of treatment, immunosuppressants were finally discontinued with no signs of AOSD flares.

Our case suggests that, in contrast to PSL and CSP, imatinib might be useful for treatment of AOSD. Selective inhibition of tyrosine kinases could provide a potent therapeutic option for a variety of autoimmune and inflammatory disorders<sup>1</sup>. Imatinib mesylate is a signal transduction inhibitor that targets Bcr-Abl, c-Kit, PDGF receptor, c-fms, and LCK. Recent reports have shown that imatinib proved beneficial in patients with various autoimmune disorders, including RA, systemic sclerosis, pulmonary arterial hypertension, lupus nephritis, ankylosing spondylitis, psoriasis, and Crohn's disease<sup>1-5</sup>. Consistent with the clinical findings, *in vitro* studies demonstrated that imatinib can inhibit multiple signaling pathways implicated in the pathogenesis of various autoimmune disorders, including T-cell proliferation, macrophage c-fms activation and cytokine production, c-Kit-mediated mast-cell release of TNF- $\alpha$  and IL-6, and synovial fibroblast PDGF receptor signaling and proliferation<sup>3,7-10</sup>. AOSD is a systemic inflammatory disease that includes the participation of various cytokines such as IL-1, IL-6, IL-18, TNF- $\alpha$ , macrophage colony-stimulating factor, PDGF, and interferon- $\gamma$ . Biological agents such as anti-TNF- $\alpha$

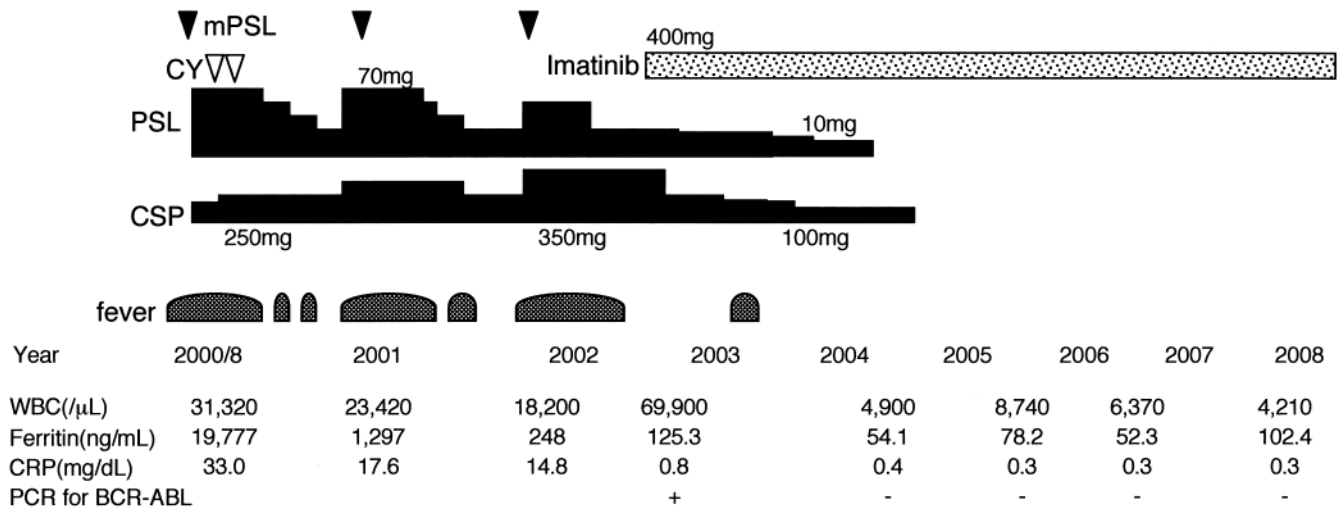


Figure 1. Clinical course of AOSD before and after treatment with imatinib mesylate. mPSL: methylprednisolone; CY: cyclophosphamide; CSP: cyclosporine; CRP: C-reactive protein; WBC: white blood cell count.

and anti-IL-1 have been successfully used in cases of refractory AOSD<sup>6</sup>. Therefore, as in our case, imatinib could prove beneficial in patients with AOSD, an inflammatory disorder involved with various cytokines and multiple signaling pathways; the precise etiology of AOSD remains unclear<sup>1,9</sup>.

Imatinib shows promise for treatment of AOSD and other autoimmune and inflammatory diseases. However, to clarify the efficacy of imatinib as well as other tyrosine kinase inhibitors, it is necessary to define which kinases and cellular responses mediate the disease pathogenesis. Moreover, since the effect of imatinib on autoimmune disorders has been observed in patients with CML treated with 400 mg imatinib per day, it is critical to define the therapeutic dosages suitable for treatment of these disorders<sup>2,3,5</sup>.

CML arises from primary mutations in Bcr-Abl, and relatively high doses of imatinib are required to inhibit proliferation of the leukemic cells<sup>1</sup>. In contrast, autoimmune diseases are not associated with mutations in kinases, and wild-type kinases participate in the dysregulated cellular responses that mediate tissue injury. Therefore, lower doses of imatinib may prove beneficial in autoimmune diseases<sup>1</sup>. Further studies are needed to define the course of therapy required for imatinib treatment, and the influence of treatment, in autoimmune and inflammatory diseases.

YOJI NAGASAKI, MD, Medicine and Biosystemic Science;  
TOSHIHIRO MIYAMOTO, MD, PhD, Medicine and Biosystemic Science,  
and Center for Cellular and Molecular Medicine; HIDEHO HENZAN,  
MD, PhD; KOJI NAGAFUJI, MD, PhD; MINE HARADA, MD, PhD; KOICHI  
AKASHI, MD, PhD, Medicine and Biosystemic Science, Kyushu University  
Graduate School of Medical Sciences, Fukuoka, Japan. Address reprint  
requests to Dr. T. Miyamoto, Center for Cellular and Molecular Medicine,  
Kyushu University Hospital, 3-1-1 Maidashi, Higashi-ku, Fukuoka, Japan  
812-8582. E-mail: toshmiya@intmed1.med.kyushu-u.ac.jp

## REFERENCES

1. Paniagua RT, Robinson WH. Imatinib for the treatment of rheumatic diseases. *Nat Clin Pract Rheumatol* 2007;3:190-1.
2. Miyachi K, Ihara A, Hankins RW, Murai R, Maehiro S, Miyashita H. Efficacy of imatinib mesylate (STI571) treatment for a patient with rheumatoid arthritis developing chronic myelogenous leukemia. *Clin Rheumatol* 2003;22:329-32.
3. Eklund KK, Joensuu H. Treatment of rheumatoid arthritis with imatinib mesylate: clinical improvement in three refractory cases. *Ann Med* 2003;35:362-7.
4. Baroni SS, Santillo M, Bevilacqua F, et al. Stimulatory autoantibodies to the PDGF receptor in systemic sclerosis. *N Engl J Med* 2006;354:2667-76.
5. Ames PR, Aye WW, Beatty C, O'Reilly D. Imatinib treatment of seropositive arthritis in a young woman with chronic myeloid leukemia. *J Rheumatol* 2008;35:1682.
6. Pouchot J. How can we improve the management of adult-onset Still's disease? *Joint Bone Spine* 2007;74:117-9.
7. Dietz AB, Souan L, Knutson GJ, Bulur PA, Litzow MR, Vuk-Pavlovic S. Imatinib mesylate inhibits T-cell proliferation in vitro and delayed-type hypersensitivity in vivo. *Blood* 2004;104:1094-9.
8. Sandler C, Joutsiniemi S, Lindstedt KA, Juutilainen T, Kovanen PT, Eklund KK. Imatinib mesylate inhibits platelet derived growth factor stimulated proliferation of rheumatoid synovial fibroblasts. *Biochem Biophys Res Commun* 2006;347:31-5.
9. Paniagua RT, Sharpe O, Ho PP, et al. Selective tyrosine kinase inhibition by imatinib mesylate for the treatment of autoimmune arthritis. *J Clin Invest* 2006;116:2633-42.
10. Koyama K, Hatsushika K, Ando T, et al. Imatinib mesylate both prevents and treats the arthritis induced by type II collagen antibody in mice. *Mod Rheumatol* 2007;17:306-10.

*J Rheumatol* 2009;36:6; doi:10.3899/jrheum.081159