

Churg-Strauss Syndrome in Childhood: A Clinical Review

To the Editor:

The Chapel Hill Consensus Conference on the Nomenclature of Systemic Vasculitis defines Churg-Strauss Syndrome (CSS) as an eosinophil-rich and granulomatous inflammation involving the respiratory tract, and necrotizing vasculitis affecting small to medium-size vessels, and associated with asthma and eosinophilia. The nomenclature describes CSS as strongly associated with antineutrophil cytoplasmic antibodies (ANCA). We describe a 10-year-old Japanese girl who had CSS without accompanying ANCA. We previously reported 10 patients with CSS, but none were children. The present case was our first encounter with CSS in a child.

A 10-year-old Japanese girl first visited our hospital with a 2-month history of intensely painful erythematous rashes on the extensor surfaces of her legs. Additionally, she began to experience pain and paresthesias in her lower extremities in conjunction with her cutaneous lesions. Her history was significant for asthma, which had been diagnosed 8 years earlier. Physical examination revealed erythematous rashes with ill defined borders resembling erythema multiforme, which had appeared progressively on her lower extremities. Skin biopsy specimens obtained from the erythema on her left lower extremity revealed a dermal perivascularity with neutrophils, red blood cells, and numerous eosinophils, consistent with leukocytoclastic vasculitis and extravascular granuloma (Figure 1). There was a predominance of eosinophils infiltrating the dermis around the vascular walls (Figure 2). Laboratory tests revealed a white blood cell count of 7600/ μ l (normal 4000–9000/ μ l), an eosinophil level of 1292/ μ l (17.0%; normal 0%–8%), and immunoglobulin E (IgE) elevated to 2000 IU/ml (normal < 170 IU/ml). ANCA with antibodies to myeloperoxidase (MPO-ANCA) and proteinase-3 (PR3-ANCA) were negative. No significant laboratory abnormalities were found, including rheumatoid factor, antinuclear antibodies, hepatitis A and B serologic test results, or cryoglobulins.

She was given 30 mg prednisone daily (1 mg/kg/day), which led to improvement in symptoms. Two months after the beginning of treatment, her condition stabilized and the peripheral eosinophilia and IgE levels normalized. The corticosteroids were tapered without any recurrence. She did not develop any systemic vasculitis during the 5-year followup.

Since Churg and Strauss¹ first described childhood CSS, 29 such cases have been published in the English literature, including our present case. The patients' ages ranged from 2 to 17 years (13 males, 16 females; mean age 11.7 ± 4.1 years). The majority of reports have emerged since 2000 (20 of the 29 cases; 69%), suggesting either an increasing incidence or, more likely, a higher awareness of this entity in the pediatric community. The reports came from all over the world, including 3 from Japan^{2,3}. Cutaneous

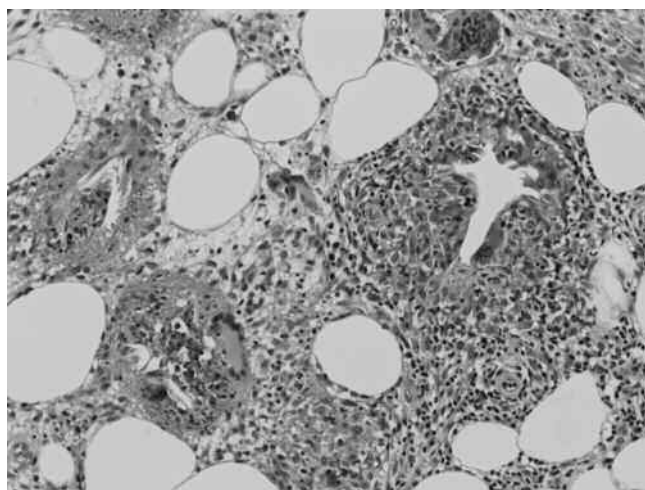


Figure 1. Microscopic examination showing vasculitis consisting of an endothelialitis rich in eosinophils and abundant giant cells in the subcutaneous fat (hematoxylin-eosin stain; original magnification $\times 200$).

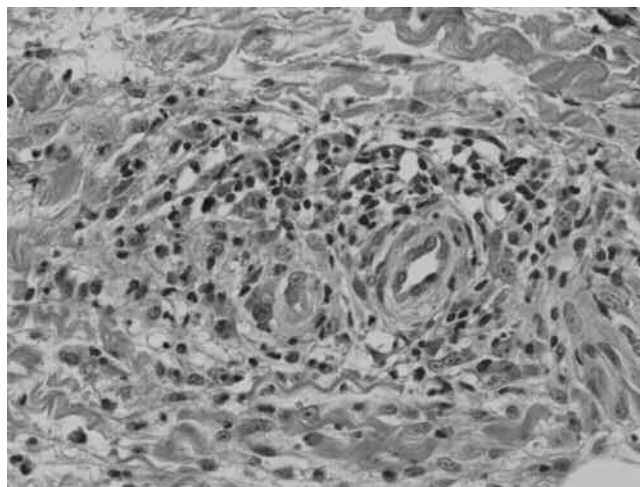


Figure 2. Micrograph showing the predominance of eosinophil infiltration into the dermis around the vascular walls (hematoxylin-eosin stain; original magnification $\times 400$).

manifestations were reported in 15 of the 29 cases (52%), and the main findings included purpura, nodules, and livedo reticularis. Among the cases reviewed, mononeuritis multiplexes were reported in 13 of 29 (45%) children with CSS. We previously reported the presence of mononeuropathy multiplexes in the lower extremities of all 9 adult CSS patients with initial cutaneous manifestations on the legs. We further noted erythematous rashes with mononeuritis multiplexes on the lower extremities of our patient as a concomitant initial manifestation. In our review of CSS in children, 9 of the 15 cases with cutaneous manifestations had both cutaneous manifestations and mononeuritis multiplexes on their lower extremities. Pneumonia was the most common disorder (21 cases; 72%) followed by paranasal sinus abnormalities (10 cases). There was also an incidence of renal (6 cases; 21%), heart ($n = 7$; 24%), and abdominal ($n = 11$; 38%) involvement. The 7 cases of CSS in children with the worst prognosis had renal insufficiency, cardiomyopathy, or gastrointestinal tract involvement^{1,4–9}.

The cornerstone of treatment for CSS remains corticosteroid therapy. In patients with a severe condition, additional therapy with cyclophosphamide and/or azathioprine is required. The use of these various immunosuppressive medications was effective to treat symptoms of refractory CSS and to minimize the development of relapses.

Almost all cases of CSS in children showed a marked peripheral blood eosinophilia and a high IgE level. The term “ANCA-associated vasculitis” has been applied to the small-vessel vasculitis including CSS. Our patient was not positive for ANCA, and we observed only one patient with ANCA in the 14 young patients with CSS in our review. In contrast, more than half the adults with CSS were positive for ANCA. Our data show a low incidence of nephritis in children with CSS. Some reports have suggested that ANCA-positive adult CSS patients are significantly correlated with nephritis compared to the ANCA-negative patients¹⁰. Among the laboratory data, ANCA seems to be the factor that is the most significantly different between children and adults with CSS. ANCA has been hypothesized to participate in the pathogenesis of leukocytoclastic vasculitis based on its association with small-vessel vasculitides and the ability of these antibodies to activate neutrophils, monocytes, and endothelial cells *in vitro*. We propose that ANCA might not be related to the pathogenesis of childhood CSS, and suggest that the pediatric form of CSS differs from the disorder in adults.

TAMIHIRO KAWAKAMI, MD, PhD; YOSHINAO SOMA, MD, PhD,
Department of Dermatology, St. Marianna University School of
Medicine, 2-16-1 Sugao, Miyamae-ku, Kawasaki, Kanagawa 216-8511,
Japan. Address correspondence to Dr. Kawakami;
E-mail: tami@marianna-u.ac.jp

REFERENCES

1. Churg J, Strauss L. Allergic granulomatosis, allergic angiitis, and periarteritis nodosa. *Am J Pathol* 1951;27:277-301.
2. Ikemoto Y, Kohdera U, Uraoka M, Teraguchi M, Okamura A, Kobayashi Y. Pulmonary infarction and deep venous thrombosis in a 13-year-old boy with Churg-Strauss syndrome. *Pediatr Int* 2001;43:441-3.
3. Kobayashi S, Ishizuka S, Tamura N, Takaya M, Kaneda K, Hashimoto H. Churg-Strauss syndrome (CSS) in a patient receiving pranlukast. *Clin Rheumatol* 2003;22:491-2.
4. Farooki ZQ, Brough AJ, Green EW. Necrotizing arteritis. *Am J Dis Child* 1974;128:837-40.
5. Frayha RA. Churg-Strauss syndrome in a child. *J Rheumatol* 1982;9:807-9.
6. Treitman P, Herskowitz JL, Bass HN. Churg-Strauss syndrome in a 14-year-old boy diagnosed by transbronchial lung biopsy. *Clin Pediatr (Phila)* 1991;30:502-5.
7. Louthrenoo W, Norasetthada A, Khunamornpong S, Sreshthaputra A, Sukitawut W. Childhood Churg-Strauss syndrome. *J Rheumatol* 1999;26:1387-93.
8. Lin TL, Wang CR, Liu MF, Chen PC, Shan YS, Jin YT, et al. Multiple colonic ulcers caused by Churg-Strauss syndrome in a 15-year-old girl. *Clin Rheumatol* 2001;20:362-4.
9. Hamdan MA, Al-Rumaihi S, Tolaymat N, Ionescu G, Al-Ashari M, El-Teraifi H. Churg-Strauss syndrome presenting as an abdominal mass in a non-asthmatic child. *Ann Trop Paediatr* 2007;27:311-4.
10. Sinico RA, Tosoni C, Bottero P, Sabadini E, Giammarresi G, Tumiatì B, et al. Renal involvement in Churg-Strauss syndrome. *Am J Kidney Dis* 2006;47:770-9.

J Rheumatol 2009;36:11; doi:10.3899/jrheum.090324