Severe Back Pain in a 56-year-old Woman

SOUMYA CHATTERJEE, MD, MS, MRCP, FACP, Assistant Professor, Lerner College of Medicine, Case Western Reserve University, Department of Rheumatic and Immunologic Diseases, Cleveland Clinic; JEAN P. SCHILS, MD, Head, Section of Musculoskeletal Imaging, Department of Diagnostic Radiology, Cleveland Clinic, Cleveland, Ohio, USA. Address reprint requests to Dr. S. Chatterjee, Department of Rheumatic and Immunologic Diseases, Cleveland Clinic, 9500 Euclid Avenue, A50, Cleveland, OH 44195. E-mail: chattes@ccf.org

A 56-year-old woman with a long history of dermatomyositis (DM), diabetes mellitus, and osteoporosis presented with severe low back pain. She had had severe pain in the tailbone area, across the back, for about 2 weeks. There was no history of trauma. The pain reached a peak in 1–2 days and was constant, but got worse on standing or walking. Her DM had been treated with daily oral steroids for over 2 years, and intravenous immunoglobulin therapy every 2 months, which controlled her disease well. Her diabetes was also well controlled. She was taking daily calcium and vitamin D, and weekly oral alendronate for osteoporosis. On examination she had significant tenderness over the sacral area, but no visible swelling or any sign of inflammation. Range of motion of the lumbar spine was normal, and there was no clinical evidence of lumbar radiculopathy. Laboratory studies were all normal. Conventional radiography of lumbar spine and pelvis only showed mild narrowing of the hip joints, suggestive of early osteoarthritis. Magnetic resonance imaging (MRI) of the pelvis revealed infiltration of the bone marrow in the sacral alae, more prominent on the left side [in the coronal plane, on both T1-weighted images (Figure 1A) and T2-weighted images with fat suppression (Figure 1B)]. On T2-weighted images in the axial plane (Figure 1C) there was evidence of a discrete fracture on the left side. Findings were consistent with bilateral sacral insufficiency fractures[1].

Studies suggest that teriparatide is superior to placebo, hormone replacement therapy, or alendronate in alleviating back pain in vertebral compression fractures[2]. Based on these studies she was started on teriparatide 20 μg subcutaneous injections daily. Alendronate was discontinued and she was advised to avoid weight-bearing activity[2]. Her pain improved significantly within 7–10 days, and she was able to stand and walk again.

First described in 1982[3], sacral insufficiency fractures are often bilateral and occur mostly in the sacral alae parallel to the sacroiliac joints[4]. These fractures result from axial stresses transmitted from the spine to the sacral alae with inadequate elastic resistance. Although not rare, they are often not considered in the differential diagnosis of persistent low back pain. Pain usually starts insidiously, often with no history of trauma, and tends to be aggravated by weight-bearing. Rest, especially in a supine position, usually relieves the pain. Conventional radiography often fails to detect these fractures, but MRI may provide early and specific findings, although the fracture line itself may be rather subtle. Computed tomography scan may also be helpful in this clinical setting. Postmenopausal osteoporosis, corticosteroid use, and prior radiation therapy are known predisposing factors. Morbidity can be significant, and a high index of suspicion is necessary to establish the diagnosis.

REFERENCES

1. Grangier C, Garcia J, Howarth NR, May M, Rossier P. Role of MRI in the diagnosis of insufficiency fractures of the sacrum and acetabular roof. Skeletal Radiol 1997;26:517-24.
2. Nevitt MC, Chen P, Dore RK, et al. Reduced risk of back pain following teriparatide treatment: a meta-analysis. Osteoporos Int 2006;17:273-80.
3. Lourie H. Spontaneous osteoporotic fracture of the sacrum. An unrecognized syndrome of the elderly. JAMA 1982;248:715-17.
4. Tsiridis E, Upadhyay N, Giannoudis PV. Sacral insufficiency fractures: current concepts of management. Osteoporos Int 2006;17:1716-25.

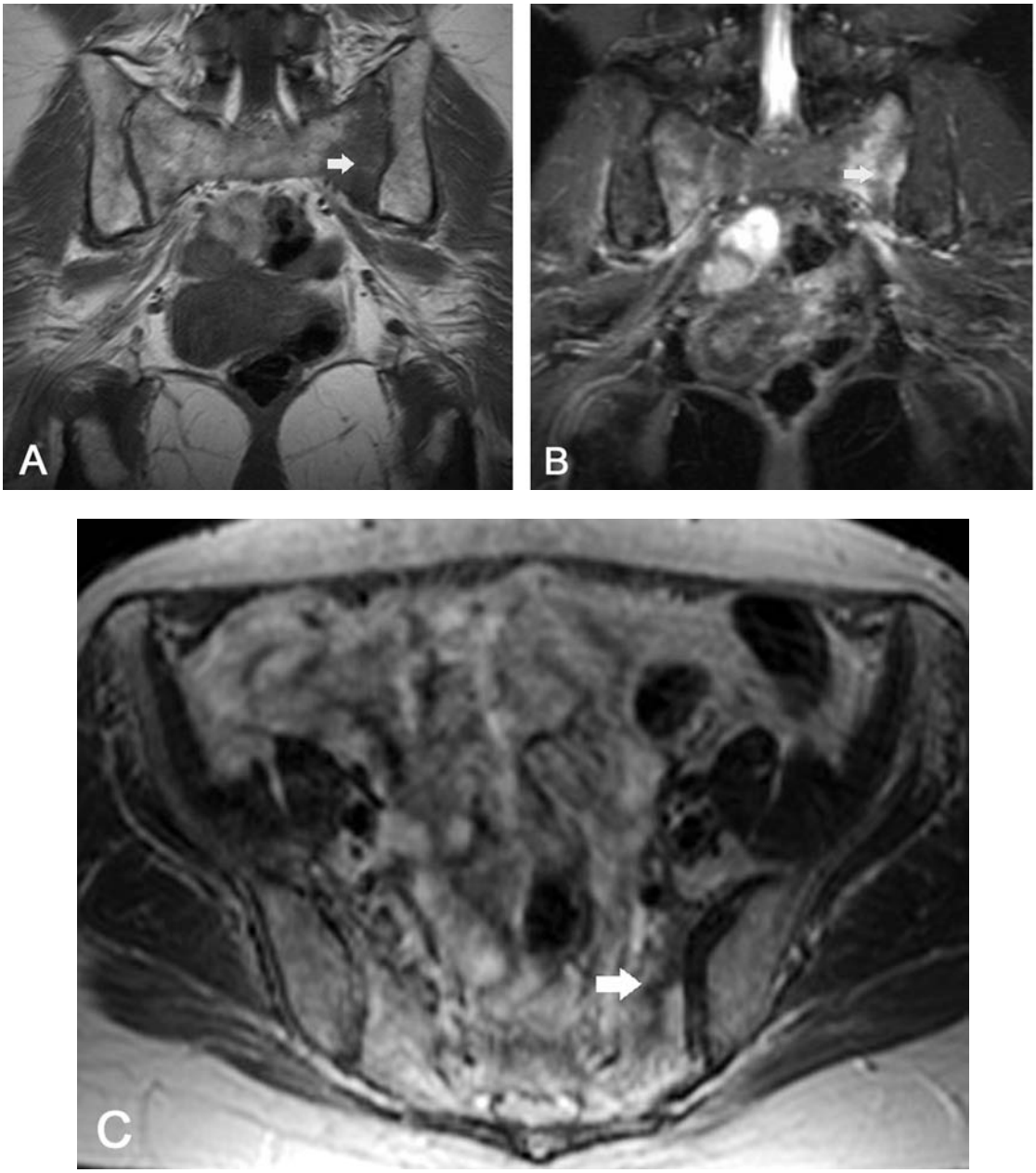

Figure 1. A. Coronal T1-weighted image of the sacrum showing nonspecific loss of normal fatty signal intensity on the left side of the sacrum (arrow). B. Coronal T2-weighted image of the sacrum with fat suppression, same plane as panel A, shows high signal intensity in the same area of the sacrum (arrow), but similar finding on the right side as well, consistent with edema. C. Axial T2-weighted image of the sacrum showing linear area of low signal intensity (arrow) on the left edematous reaction of the sacrum, consistent with a discrete fracture.