

## Dactylitis or “Sausage-Shaped” Digit

In the early 1980s, when our interest for the spondyloarthritides was born, we were impressed by a poorly defined and studied clinical manifestation of spondyloarthritis (SpA): dactylitis or “sausage-like” digit (Figures 1 and 2).

In the most popular classic rheumatologic books in Europe there was next to nothing on this manifestation. In the chapter dealing with psoriatic arthritis (PsA) in the 1978 edition of *Copeman’s Textbook of the Rheumatic Diseases*, Verna Wright wrote: “Involvement of the distal and proximal interphalangeal joints, together with tendon sheath involvement, may give the digit a sausage shape”<sup>1</sup>. In the chapter written by Robert M. Bennett in the 1979 edition of *Arthritis and Allied Conditions* no mention was made of dactylitis<sup>2</sup>. Only in the following edition, in 1985, a sentence on the topic appeared: “In some instances, involvement of a metacarpophalangeal or proximal interphalangeal joint is associated with a flexor tenosynovitis, giving the sausage-digit appearance”<sup>3</sup>.

In the 25 years that followed, important advances were made in the knowledge of this hallmark and highly specific manifestation of SpA. It is completely different from other digit diseases called dactylitis<sup>4</sup>. Although SpA dactylitis is more frequent in PsA<sup>5</sup>, it has been observed in all forms of SpA, including the undifferentiated ones<sup>6</sup>. Dactylitis is so specific for SpA that it was included among the clinical criteria suggested by Amor, *et al* for classification and diagnosis of the whole disease group<sup>7</sup>. In the European Spondylarthropathy Study Group (ESSG) study on classification criteria for the SpA group as a whole, the sensitivity and specificity of dactylitis were 17.9% and 96.4%, respectively<sup>6</sup>. In spite of this high specificity, dactylitis failed to be included in the best set of variables able to differentiate patients with SpA from controls. Recently, dactylitis has been included, due to its high specificity and sufficient sensitivity, in the classification criteria generated by the CASPAR (CIASSification criteria for Psoriatic ARthritis) Study Group for PsA<sup>8</sup>. In this study 50% of controls had rheumatoid arthritis. In undifferentiated SpA (uSpA), dactylitis usually occurs with the other manifestations of the HLA-B27-associated disease process: peripheral enthesitis, peripheral arthritis, inflammatory spinal pain, buttock pain, chest wall pain, acute anterior uveitis, and aortic regurgitation together

with conduction disturbances<sup>9</sup>. Like these, dactylitis may sometimes occur for a long time in isolation as the only clinically apparent manifestation of the HLA-B27-associated disease process<sup>10-13</sup>. This has been observed in children<sup>10,11</sup>, in young and middle-aged adults<sup>12</sup>, and in the elderly<sup>13</sup>. In addition, it should be remembered that there are patients with psoriasis who exhibit only dactylitis and/or enthesitis for months or years<sup>14</sup>.

Usually dactylitis involves few fingers and/or toes asymmetrically<sup>15-17</sup>. Sometimes it may simultaneously involve most of the fingers<sup>18</sup>. Like other peripheral manifestations of SpA, i.e., enthesitis and arthritis, the onset of dactylitis may be triggered by a physical injury<sup>19</sup>.

Physical examination of the dactylitic finger or toe always shows swelling and pain along the flexor tendons. In finger dactylitis, the swelling of the synovial sheaths is often so marked that the patients cannot flex the finger. So it was thought that the sausage-like appearance was due to concomitant flexor tenosynovitis and arthritis of the metacarpophalangeal (MCP) or metatarsophalangeal (MTP) and interphalangeal joints. In 1996 we used ultrasonography (US) and magnetic resonance imaging (MRI) to establish the role of tenosynovitis and arthritis in producing the sausage-like feature<sup>15</sup>. Twelve dactylitic fingers and their corresponding normal contralateral fingers were studied. The diameter of the flexor tendons and their sheaths was measured at the midpoint of the proximal phalanx on both examinations. The MCP and interphalangeal joints were examined for capsule distension and synovial proliferation. In all “sausage-like” fingers both MRI and US showed fluid collection in the flexor synovial sheaths. Of the 36 joints of the 12 dactylitic fingers, only one showed capsule distension. We concluded that dactylitis is due to flexor tenosynovitis and that the enlargement of the joint capsule is not an indispensable condition for the “sausage-like” feature. Another important conclusion was that clinical examination is a sufficient method for the diagnosis of tenosynovitis, since it showed 100% sensitivity and specificity compared with MRI. Subsequently, we showed that the same conclusions are valid for toe dactylitis<sup>16</sup>. Twelve sausage-like toes and the corresponding contralateral toes of 7 consecutive patients with SpA were studied by MRI.

---

See Measuring dactylitis in clinical trials: which is the best instrument to use?, page 1302

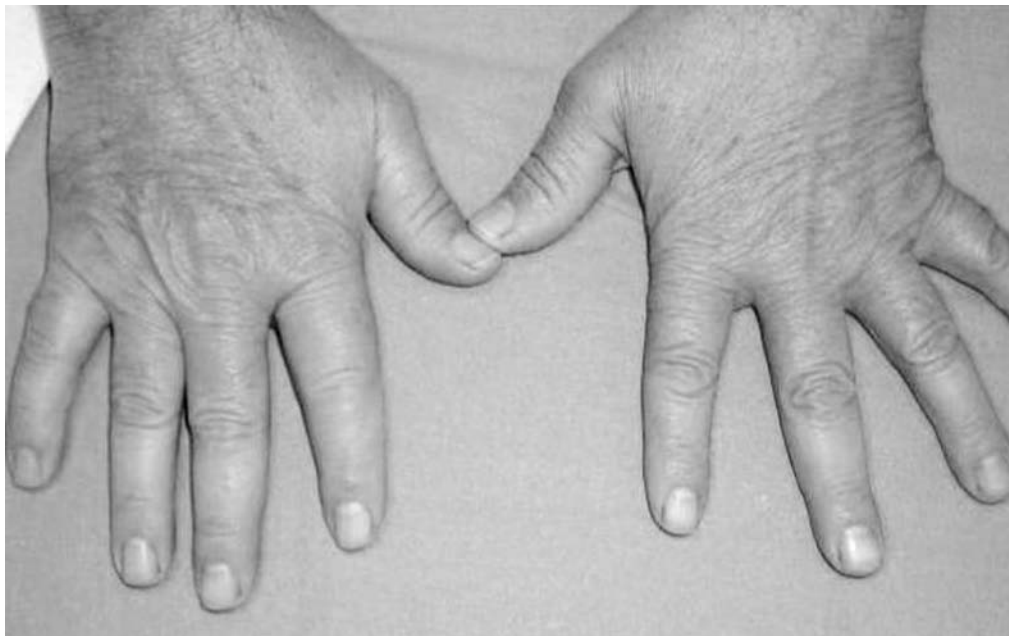


Figure 1. Dactylitis involving the second finger of the right hand.

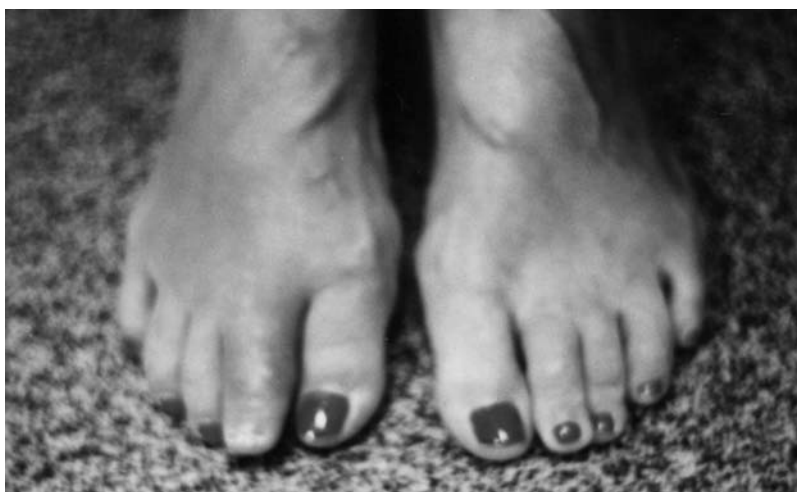

Figure 2. Dactylitis of the second toe of the right foot.

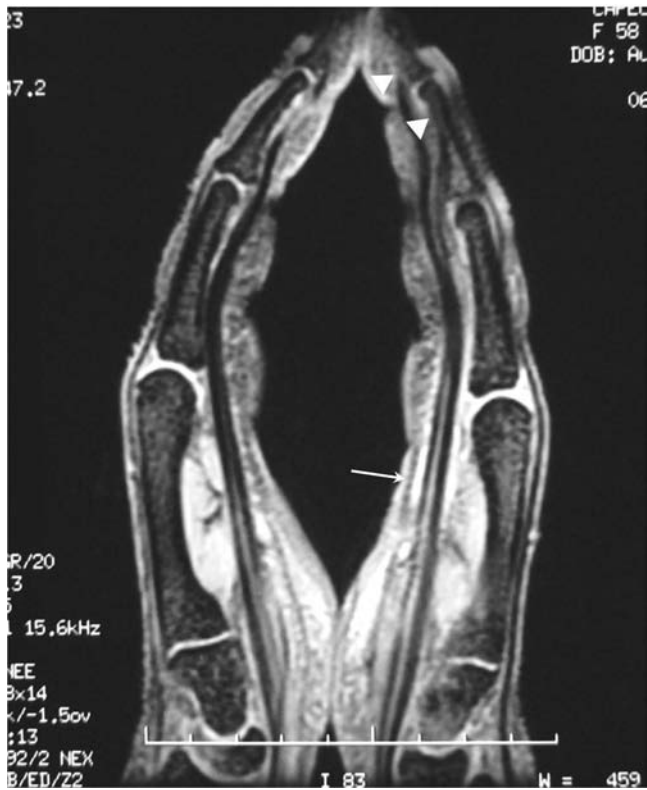All dactylitic toes showed fluid collection in the flexor synovial sheaths. Of the 36 joints of the 12 dactylitic toes only 2 MTP joints showed capsule distension. The only differences from the study on finger dactylitis were the presence of peritendinous soft tissue in 2 dactylitic toes and the involvement of extensor synovial sheaths in 4.

The results of our studies were confirmed by 2 other ultrasonographic studies on dactylitis<sup>20,21</sup>. Both found flexor tenosynovitis in all dactylitic digits. The only difference from our studies was in the frequency of joint synovitis. Kane, *et al* found a frequency of 52%<sup>20</sup> and Wakefield, *et al* 62.5%<sup>21</sup>. In our 3 MRI studies on 36 dactylitic digits, we have observed a frequency of 16.6%<sup>15-17</sup>.

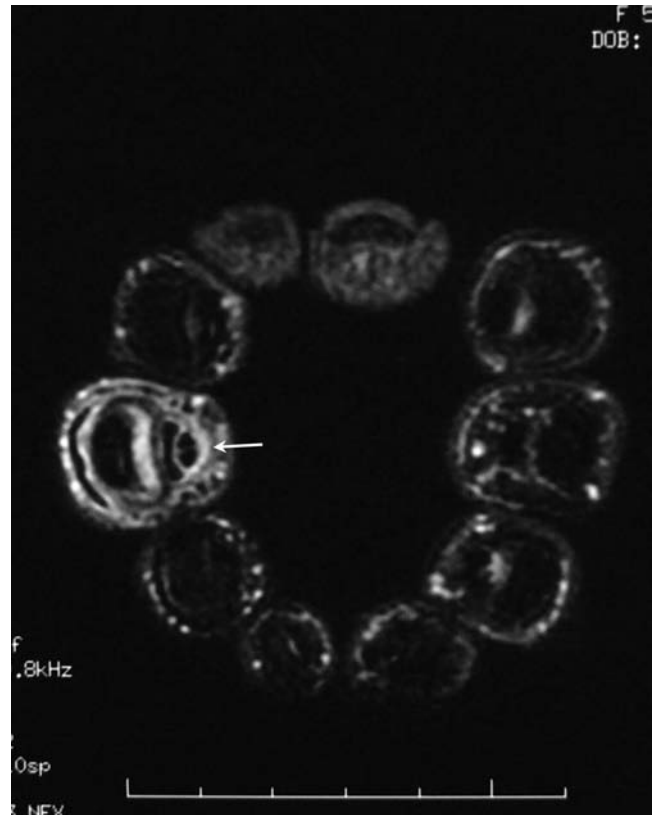
The involvement of the tenosynovial sheaths in finger

dactylitis may extend beyond the digit<sup>22-25</sup>. The most frequent pattern of digital and palmocarpal synovial sheaths is as follows. The index, middle, and ring fingers have synovial sheaths separate from those of the radial and ulnar bursae, which communicate, respectively, with the synovial sheaths of the thumb and the little finger. However, variants showing communication of the sheaths of index, middle, and ring fingers with the ulnar bursa are frequent. When dactylitis involves a finger with synovial sheaths communicating with the ulnar bursa, the painful swelling also extends into the palm of the hand<sup>22,23</sup>. In addition, in dactylitis of the first and fifth fingers, synovial inflammation may spread to the radial and ulnar bursa, respectively<sup>24,25</sup>.

Recently, McGonagle and colleagues hypothesized that

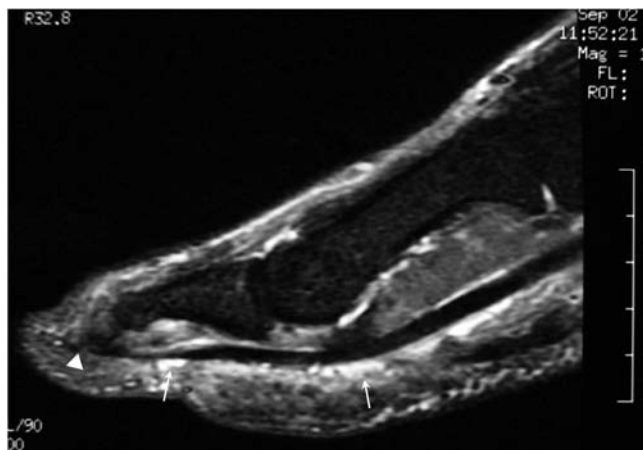


**A**

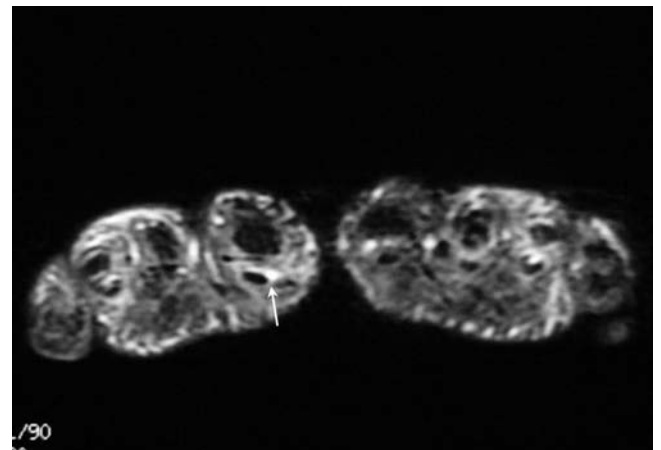


**B**

Figure 3. Finger dactylitis. Sagittal gradient-echo T2-weighted (A) and axial fast spin-echo T2-weighted image with fat saturation (B) showing fluid/synovitis in the flexor synovial sheaths (arrows), subcutaneous edema extending all around the circumference, and normal flexor and adjacent bone (arrowheads).



**A**



**B**

Figure 4. Toe dactylitis. Sagittal (A) and axial (B) FSPGR (fast spoiled gradient-echo) T1-weighted image with fat saturation obtained after contrast administration showing fluid/synovitis together with vascularization in the flexor synovial sheaths (arrows) and normal flexor entheses and adjacent bones (arrowhead).

enthesitis is the primary lesion in SpA, while synovitis of the various structures (joint, tendon, and bursa) represents a secondary phenomenon due to release of proinflammatory cytokines from the inflamed entheses<sup>26,27</sup>. In their opinion,

flexor tenosynovitis of dactylitis is due to enthesitis caused by diffusion of cytokines along the tenosynovial sheaths<sup>28</sup>. In a recent study we demonstrated, using fast spin-echo (FSE) T2-weighted sequences with fat saturation, that in

SpA dactylitis there is no evidence of enthesitis of the flexor digitorum tendons and joint capsule (Figure 3)<sup>17</sup>. The same seems to occur in toe dactylitis (Figure 4). McGonagle, *et al* have replied that in the digit there are also numerous “functional entheses” that are associated with the presence of fibrocartilage and that these may be the site of the primary inflammation in dactylitis<sup>29</sup>. This could be true, because at the 2006 EULAR meeting the Leeds group reported signs of enthesitis together with joint synovitis, adipose tissue edema, and tenosynovitis<sup>30</sup>. Future MRI studies on dactylitis should examine the enthesal insertions along the digit by using high resolution sequences. These studies should also examine the nail, since MRI nail findings have been shown to exist also in patients without onychopathy<sup>31</sup>.

Lately, Brockbank, *et al* have suggested that dactylitis can be a marker of disease progression in PsA<sup>32</sup>. They have observed increased radiological progression in digits showing dactylitis compared with those without the sausage-like aspect. The Group for Research and Assessment of Psoriasis and Psoriatic arthritis (GRAPPA) has proposed evidence based guidelines for PsA categorized by disease characteristics and disease organ involvement including dactylitis<sup>33</sup>. Therapy for dactylitis usually begins with nonsteroidal anti-inflammatory drugs and local corticosteroid injections<sup>34</sup>. Conventional disease modifying antirheumatic drugs (DMARD) and anti-tumor necrosis factor- $\alpha$  blocking agents such as infliximab can be used. So far, a valid, reliable, and responsive clinical outcome measure for dactylitis has not been used in clinical trial on PsA.

In this issue of *The Journal*<sup>35</sup> Healy and Helliwell test the responsiveness of the Leeds Dactylitis Index (LDI)<sup>36</sup> and its modified version (LDI-basic) in 28 patients with PsA receiving conventional DMARD or etanercept. They demonstrate that these measures meet the requirements for truth, discrimination, and feasibility of the OMERACT filter and could be used in future randomized trials on PsA.

Today we know more about dactylitis than 25 years ago. We hope that even more knowledge may soon be acquired on this interesting manifestation of SpA.

**IGNAZIO OLIVIERI, MD,**

Consultant, Director;

**ANGELA PADULA, MD,**

Senior Registrar,  
Rheumatology Department of Lucania,  
San Carlo Hospital,  
Madonna delle Grazie Hospital of Matera, Potenza;

**ENRICO SCARANO, MD,**

Senior Registrar,  
Radiology Department,  
San Carlo Hospital, Potenza;

**RAFFAELE SCARPA, MD,**

Associate Professor of Rheumatology,  
Rheumatology Research Unit,  
University Federico II,  
Naples, Italy

Address reprint requests to Dr. I. Olivieri, Rheumatology Department of Lucania, San Carlo Hospital, Contrada Macchia Romana, 85100 Potenza, Italy. E-mail: ignazioolivieri@tiscalinet.it; i.olivieri@ospedalesancarlot.it

**REFERENCES**

1. Wright V. Psoriatic arthritis. In: Scott JT, editor. Copeman's textbook of the rheumatic diseases. 5th ed. Edinburgh: Churchill Livingstone; 1978:537-48.
2. Bennett RM. Psoriatic arthritis. In: McCarty DJ, editor. Arthritis and allied conditions. 9th ed. Philadelphia: Lea and Febiger; 1979:642-55.
3. Bennett RM. Psoriatic arthritis. In: McCarty DJ, editor. Arthritis and allied conditions. 10th ed. Philadelphia: Lea and Febiger; 1985:850-66.
4. Olivieri I, Scarano E, Padula A, Giasi V, Priolo F. Dactylitis, a term for different digit diseases. *Scand J Rheumatol* 2006;35:33-40.
5. Gladman DD. Psoriatic arthritis. In: Khan MA, editor. Ankylosing spondylitis and related spondyloarthropathies. Spine: state of the art review. Philadelphia: Hanley and Belfus; 1990:637-56.
6. Dougados M, van der Linden S, Juhlin R, et al. The European Spondylarthropathy Study Group preliminary criteria for the classification of spondylarthropathy. *Arthritis Rheum* 1991;34:1218-27.
7. Amor B, Dougados M, Mijiyawa M. Criteria of the classification of spondylarthropathies [French]. *Rev Rhum Mal Osteoartic* 1990;57:85-9.
8. Taylor W, Gladman D, Helliwell P, et al. Classification criteria for psoriatic arthritis: Development of new criteria from a large international study. *Arthritis Rheum* 2006;54:2665-73.
9. Olivieri I, Padula A, Pierro A, Favaro L, Oranges GS, Ferri S. Late onset undifferentiated seronegative spondyloarthropathy. *J Rheumatol* 1995;22:899-903.
10. Siegel DM, Baum J. HLA-B27 associated dactylitis in children. *J Rheumatol* 1988;15:976-7.
11. Padula A, Scarano E, Giasi V, Olivieri I. Juvenile onset isolated B27 associated dactylitis. *Semin Arthritis Rheum* 2003;32:341-2.
12. De Ceulaer K, van der Linden JM, Cats A. “Sausage-like” toes (dactylitis) and HLA B27. *J Rheumatol* 1977;4 Suppl 3:66-9.
13. Padula A, Giasi V, Olivieri I. Elderly onset isolated B27 associated dactylitis. *Ann Rheum Dis* 2002;61:759-60.
14. Salvarani C, Cantini F, Olivieri I, et al. Isolated peripheral enthesitis and/or dactylitis: a subset of psoriatic arthritis. *J Rheumatol* 1997;24:1106-10.
15. Olivieri I, Barozzi L, Favaro L, et al. Dactylitis in patients with seronegative spondylarthropathy: assessment by ultrasonography and magnetic resonance imaging. *Arthritis Rheum* 1996;39:1524-8.
16. Olivieri I, Barozzi L, Pierro A, De Matteis M, Padula A, Pavlica P. Toe dactylitis in patients with spondyloarthropathy: assessment by magnetic resonance imaging. *J Rheumatol* 1997;24:926-30.
17. Olivieri I, Salvarani C, Cantini F, et al. Fast spin echo (FSE)-T2-sequences with fat saturation in dactylitis of spondyloarthritis: no evidence of enthesal involvement of flexor digitorum tendons. *Arthritis Rheum* 2002;46:2964-7.
18. Olivieri I, Scarano E, Padula A, Giasi V. Dactylitis involving most of the fingers (letter). *Clin Exp Rheumatol* 2003;21:406.
19. Padula A, Belsito F, Barozzi L, Cantini F, Salvarani C, Pavlica P, Olivieri I. Isolated tenosynovitis associated with psoriasis triggered by physical injury. *Clin Exp Rheumatol* 1999;17:103-4.
20. Kane D, Greaney T, Bresnihan B, Gibney R, FitzGerald O. Ultrasonography in the diagnosis and management of psoriatic dactylitis. *J Rheumatol* 1999;26:1746-51.
21. Wakefield RJ, Emery P, Veale D. Ultrasonography and psoriatic arthritis. *J Rheumatol* 2000;27:1564-5.

22. Olivieri I, Favaro L, Pierro A, et al. Dactylitis also involving the synovial sheaths in the palm of the hand. *Ann Rheum Dis* 1994;53:783-4.
23. Padula A, Olivieri I, Barozzi L, et al. Dactylitis also involving the synovial sheaths in the palm of the hand: two more cases studied by magnetic resonance imaging. *Ann Rheum Dis* 1998;57:61-2.
24. Olivieri I, Scarano E, Padula A, Giasi V. Dactylitis of the thumb extending to the radial bursa. *J Rheumatol* 2003;30:1626-7.
25. Olivieri I, Scarano E, Padula A, Giasi V. Dactylitis of the thumb and little finger extending to the carpal tunnel. *J Rheumatol* 2007;34:1155-6.
26. McGonagle D, Gibbon W, O'Connor P, Green M, Pease C, Emery P. Characteristic magnetic resonance imaging enthesal changes of knee synovitis in spondylarthropathy. *Arthritis Rheum* 1998;41:694-700.
27. McGonagle D, Gibbon W, Emery P. Classification of inflammatory arthritis by enthesitis. *Lancet* 1998;352:1137-40.
28. McGonagle D, Pease C, Marzo-Ortega H, O'Connor P, Emery P. The case for classification of polymyalgia rheumatica and remitting seronegative symmetrical synovitis with pitting edema as primarily capsular/enthesal based pathologies. *J Rheumatol* 2000;27:837-40.
29. McGonagle D, Marzo-Ortega H, Benjamin M, Emery P. Report on the Second International Enthesitis Workshop. *Arthritis Rheum* 2003;48:896-905.
30. Healy PJ, Groves C, Chandramohan R, Helliwell P. Magnetic resonance imaging in dactylitis — What is the site of inflammation? [abstract] *Ann Rheum Dis* 2006;65 Suppl 2:68.
31. Scarpa R, Soscia E, Peluso R, et al. Nail and distal interphalangeal joint in psoriatic arthritis. *J Rheumatol* 2006;33:1315-9.
32. Brockbank JE, Stein M, Schentag CT, Gladman DD. Dactylitis in psoriatic arthritis: a marker for disease severity? *Ann Rheum Dis* 2005;64:188-90.
33. Kavanaugh AF, Ritchlin CT. Systematic review of treatments for psoriatic arthritis: evidence based approach and basis for treatment guidelines. *J Rheumatol* 2006;33:1417-21.
34. Helliwell PS. Therapies for dactylitis in psoriatic arthritis. A systematic review. *J Rheumatol* 2006;33:1439-41.
35. Healy PJ, Helliwell PS. Measuring dactylitis in clinical trials: which is the best instrument to use? *J Rheumatol* 2007;34:1302-5.
36. Helliwell PS, Firth J, Ibrahim GH, Melson RD, Shah I, Turner DE. Development of an assessment tool for dactylitis in patients with psoriatic arthritis. *J Rheumatol* 2005;32:1745-50.