

Letters



INSTRUCTIONS FOR LETTERS TO THE EDITOR

Editorial comment in the form of a Letter to the Editor is invited. The length of a letter should not exceed 800 words, with a maximum of 10 references and no more than 2 figures or tables; and no subdivision for an abstract, methods, or results. Letters should have no more than 4 authors. Financial associations or other possible conflicts of interest should be disclosed.

Letters should be submitted via our online submission system, available at the Manuscript Central website: <http://mc.manuscriptcentral.com/jrheum> For additional information, contact the Managing Editor, The Journal of Rheumatology, E-mail: jrheum@jrheum.com

First Release Oct 15 2007

“Pseudospondylitis” Caused by Rupture of an Aortic Aneurysm

To the Editor:

Abdominal aortic aneurysm (AAA) has several origins including atherosclerosis, infection, inflammation, trauma, autoimmune disease, and Marfan's syndrome¹. Its prevalence is broad, representing 15% of patients with peripheral artery disease and increasing with aging, but up to 85% of these patients will actually die of other causes². Although rupture is usually a fatal event, it can be contained, leading to a chronic AAA dissection. We describe a rare case of such a chronic AAA dissection in a patient with low back pain, crural neuralgia, and imaging that revealed a lumbar spondylitis suggesting a chronic infectious bony lesion.

A 68-year-old man was hospitalized for progressive weight loss and severe asthenia. He had moderate low back pain and reported a fall on his buttocks 6 weeks earlier. He had several medical problems including smoking-induced chronic obstructive broncho-pneumopathy, mellitus diabetes type II, alcoholism addiction stopped 5 years ago, lower limb arteriopathy treated by stent, and myocardopathy with complete arrhythmia treated by anticoagulant therapy.

Both C-reactive protein (CRP) and erythrocyte sedimentation rate were increased. Plain radiographs showed vertebral deformities of T12 and L4. Both total-body computed tomographic (CT) and magnetic resonance imaging (MRI) scans (Figure 1) gave evidence of recent benign crush vertebral fractures. A soft tissue lesion was observed close to T4 vertebral body, and was considered a hematoma in this context of a vertebral fracture. However, the suspected alcoholism-induced osteoporosis was not supported by normal densitometry values.

He did not attend followup visits and was rehospitalized one year later only because of chronic back pain and weight loss of 9 kg. CRP levels were still high (20 to 70 mg/l). A new MRI showed more severe lesions of L4 vertebra, suggesting spondylitis with resorption of vertebral body front wall. The lesion expanded in the venous-aortic space together with inflam-

matory aspect of psoas muscles. Histological analysis of a first percutaneous vertebral biopsy revealed no specific lesion. The tuberculin intradermal test was positive despite no known history of tuberculosis and sterile culture of both bone sample and lung secretions. A thoracic CT was normal. Thus the bone lesion was considered as potential Pott's disease. Shortly after introduction of triple antibiotic therapy, an isolated right L4 crural neuralgia occurred with moderate quadriceps motor deficit. Because of the lack of a definitive diagnosis and clinical worsening, a second surgical biopsy was performed. Again, no sign of a malignant lesion or caseous necrosis was observed. However, macrophages containing hemosiderin were present within bone, suggesting a vascular origin. A second abdominal-thoracic CT (Figure 2) showed enlargement of the infiltrative tissue surrounding the abdominal aorta (17 × 22 mm in the axial plan), suggesting a potential false AAA. An aortic-femoral bridging combined with reimplantation of the lower mesenteric artery was performed. Histology revealed a very dystrophic aortic wall with a mix of ossified lesions, signs of discontinuity, and an extensive inflammatory reaction with lymphoplasmocytic and macrophagic cells within the lesion. Macrophages were located close to hemosiderin deposit stained blue with Perls coloration.

Cruralgia and chronic fever resolved rapidly. Four months after surgery, the patient had gained 7 kg and was able to walk with no pain. The inflammatory status resolved as well, and lumbar spine radiographs were stable, with no sign of secondary necrosis.

The incidence of vertebral destruction, usually erosion in contact with an AAA, ranges from 7%³ to 25%⁴, with nonspecific episodes of low back pain and sometimes the addition of neuralgia in lower limbs, as we and others^{3,5} have reported. Erosion of the anterior part of the vertebra in contact with the aneurysm can contribute to a delayed diagnosis⁵⁻⁸ and misleading hypotheses of bony metastasis or infection. The regression of all symptoms after AAA surgery, as described here, unequivocally confirms the pathogenesis of the vascular lesion^{5,7,9}.

The association of a contained rupture of AAA with a true pyogenic spondylitis is rare⁶. Indeed, in this case the aneurysm was discovered accidentally when a vertebral biopsy was performed under CT control, and the relationship between the 2 lesions was probably fortuitous.

According to Katz, *et al*¹⁰, the vertebral erosion is secondary to mechanical loading induced by the aortic pulse within the aneurysmal portion. We believe this mechanism cannot explain in our case the inflammatory aspect of the adjacent vertebra, revealed by MRI and histologically confirmed by the presence of a granuloma with macrophages containing hemosiderin. Therefore we suggest that this represents the formation of a chronic inflammatory granuloma surrounding the aortic aneurysm, which subsequently infiltrated the vertebral body, leading to secondary erosion.

Our case is an example of a rare, misleading presentation of chronic, contained aneurysm rupture mimicking infectious spondylitis. This has to be kept in mind when facing such a situation, since invasive diagnosis procedures might be dangerous and the need for surgical treatment urgent.

ADAMAH AMOUZOGAN, MD, Department of Rheumatology, University Hospital, Saint Etienne; THIERRY ZÉNONE, MD; MARIE COURET, MD, Department of Medicine, General Hospital, Valence; MICHEL PEOC'H, MD, Department of Anatomopathology; XAVIER BARRAL, MD, Department of Cardiovascular Surgery; FABRICE GUY BARRAL, MD, Department of Radiology; THIERRY THOMAS, MD, PhD, Department of Rheumatology, University Hospital, Saint Etienne, France. Address reprint requests to Prof. T. Thomas, INSERM U890, Rheumatology Department, University Hospital, Boulevard Pasteur, 42055 Saint-Etienne Cedex 2, France. E-mail: thierry.thomas@chu-st-etienne.fr

REFERENCES

1. Stites J, Canterbury R. Aneurysm of the abdominal aorta. *Acad J Chiropractic* 1989;9:65-7.
2. Berqvist D. Management of small abdominal aortic aneurysms. *Br J Surg* 1999;86:433-4.

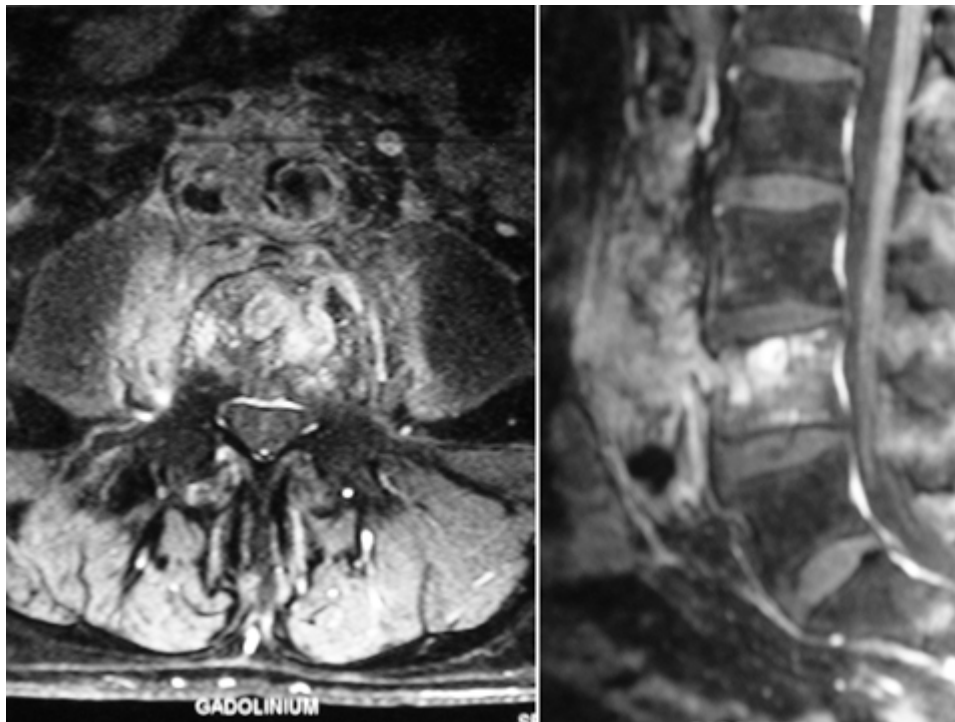

Figure 1. T1 MRI sequence with gadolinium injection shows high signal alteration in the L4 vertebral body and psoas muscles, suggesting a diagnosis of spondylitis, on both coronal (left) and sagittal (right) views.

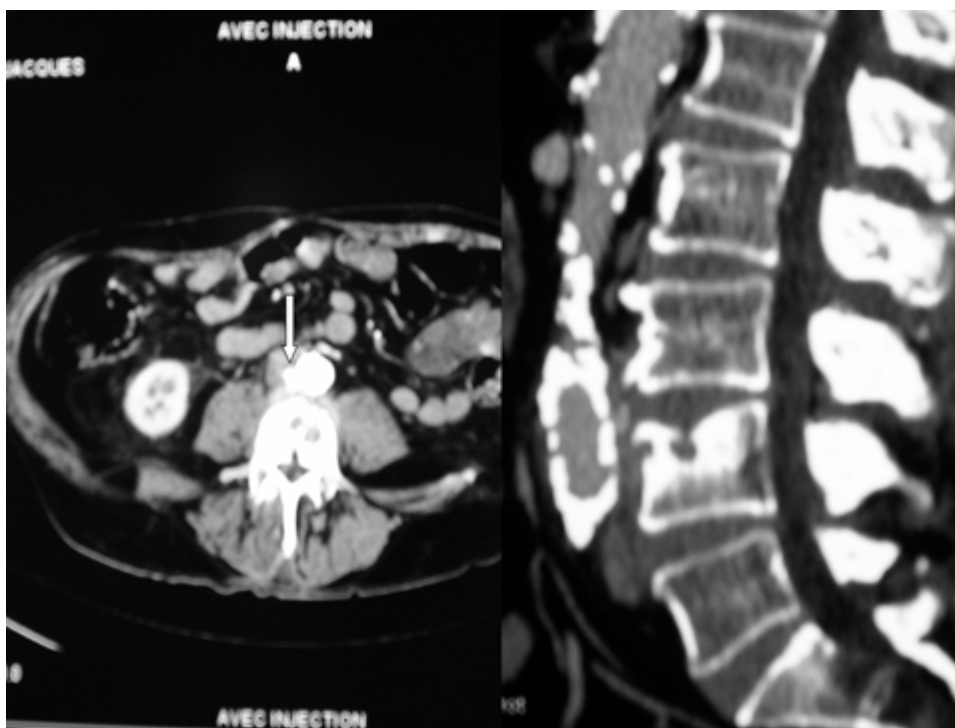


Figure 2. CT with intravenous injection shows erosion of the upper plate of L4 vertebra body and rupture of the abdominal aortic aneurysm (arrow).

3. Husson JL, Polard JL, Mehdi M, Roy-Camille R. Extensive pseudotumoral lumbar spine lesions of vascular origin [French]. *Chirurgie* 1996;121:223-4.

4. Rothschild M, Cohn L, Aviza A, Yoon BH. Aortic aneurysm producing back pain, bone destruction, and paraplegia. *Clin Orthop Relat Res* 1982;164:123-5.

5. Seckin H, Bavbek M, Dogan S, Keyik B, Yigitkanli K. Is every chronic low back pain benign? Case report. *Surg Neurol* 2006;66:357-60.
6. Doita M, Marui T, Kurosaka M, et al. Contained rupture of the aneurysm of common iliac artery associated with pyogenic vertebra spondylitis. *Spine* 2001;26:E303-7.
7. Saiki M, Urata Y, Katoh I, Hamasaki T. Chronic contained rupture of an abdominal aortic aneurysm with vertebral erosion: report of a case. *Ann Thorac Cardiovasc Surg* 2006;12:300-2.
8. Nagi S, Taright N, Meder JF, Vanel D, Fredy D. What is your diagnosis? Aneurysm of the abdominal aorta destroying the lumbar spine. *Neuroradiol* 1999;26:3-6.
9. Galesiere PF, Downs AR, Greenberg HM. Chronic, contained rupture of aortic aneurysms associated with vertebral erosion. *Can J Surg* 1994;37:23-8.
10. Katz SH, Harrison AW, Key JA. Vertebral erosion by an atherosclerotic lumbar aortic aneurysm: an unusual case. *Can Med Assoc J* 1962;87:187-9.

Systemic Lupus Erythematosus in a Patient Treated with Etanercept for Polyarticular Juvenile Rheumatoid Arthritis

To the Editor:

We describe the first case of a patient treated with etanercept for juvenile rheumatoid arthritis (JRA) who developed systemic lupus erythematosus (SLE) with irreversible type IV glomerulonephritis and severe obstructive and restrictive pulmonary disease. Adverse events reported include the development of positive antinuclear antibodies (ANA), anti-dsDNA antibodies, anticardiolipin antibodies, and reversible lupus-like syndromes, occurring between 2 and 18 months after starting etanercept (Enbrel®)¹.

Generally the development of antibodies has no clinical implication, antibodies are not monitored, and symptoms disappear after tumor necrosis factor inhibitor is stopped².

Our patient, a 16-year-old Hispanic female, presented with arthritis, right facial cellulitis, and elevated ANA (1:1280). Her erythrocyte sedimentation rate (ESR) was high and chest radiograph showed borderline cardiomegaly. She had negative rheumatoid factors (RF), dsDNA, anticardiolipin antibodies, lupus anticoagulant, and C3, C4; echocardiogram and radiographs of her hands were normal. She was diagnosed with JRA and treated with multiple disease modifying antirheumatic drugs, nonsteroidal antiinflammatory drugs, and systemic corticosteroids. Periodically anti-dsDNA antibodies were abnormal (28 IU/ml; normal < 5 IU/ml), but no other criteria for SLE were met. Clinically, she developed erosive disease requiring replacement of the metacarpophalangeal and proximal interphalangeal joints.

Nine years later, her arthritis was active and she started taking etanercept. Before treatment, autoimmune markers, chemistry investigations, urinalysis, and complement were negative. Within 2 months of beginning Enbrel® her anti-dsDNA antibodies were 930 (normal < 30) and her arthritis was in remission. Within 1 year she had hair loss and fatigue. In the second year, her arthritis flared, anti-dsDNA were elevated, RF, SSA, and direct Coombs' test were positive, complements were low, and urinalysis showed 2+ blood and 3+ protein; Enbrel was discontinued. A kidney biopsy revealed type IV glomerulonephritis and pulmonary function tests showed obstructive and restrictive disease with decreased diffusion capacity.

Many cases in the literature document reversible SLE developing in patients receiving etanercept. In initial trials 11% of patients had elevated ANA compared to placebo controls (5%), and 15% of Enbrel patients had elevated anti-dsDNA compared to 4% in the placebo controls; however, no patient developed clinical disease³. Other markers, such as anti-histone antibodies, anticardiolipin antibodies, and anti-U1-RNP, are documented in the literature along with lupus-like syndromes⁴. However, in most cases the

clinical signs resolved, and antibody titers became negative when etanercept was discontinued⁵. One patient developed lupus with multiorgan involvement, but improved within 12 months of stopping etanercept, although serological markers remained high⁶. Our patient is unique, as her disease manifestations were irreversible.

The question arises whether our patient has the "rhumus syndrome" or has primary JRA and developed SLE taking Enbrel⁷. As with our patient, others with JRA or RA have elevated ANA and positive anti-dsDNA with no other criteria for SLE⁴. Multiple reports and series discuss patients initially diagnosed with RA who developed SLE within 2 to 8 years; the majority had non-erosive arthritis and were RF-positive early in the disease course⁷. Our patient's destructive arthritis and autoimmune markers are less consistent with those of the rhupus patients.

Our patient's transformation is similar to reports describing drug-induced lupus, with the abrupt development of anti-dsDNA and other autoantibodies.

Currently, SLE is understood as a breakdown of tolerance, an activation of B cells with autoantibody production and inflammatory changes that leads to organ damage. However, the mechanism of action of cytokines in the pathogenesis of SLE is elusive, making it hard to propose a mechanism for induction of lupus by TNF- α inhibitors.

One suggestion is that TNF suppression induces autoreactivity by shifting the balance of cytokines to propagate the humoral response, as seen in SLE⁸. Another is that the chronic high levels of TNF- α seen in RA down-regulate B cell hyperactivity. Thus when TNF- α is blocked, regulation of B cells is lifted and a massive production of antibodies proliferates⁹.

Cairns, *et al*¹⁰ propose that TNF blockade leads to less CD44 expression, which impedes the clearance of apoptotic neutrophils, making nuclear-derived antigens available for tolerance breakdown and changes of SLE¹⁰.

Although TNF inhibitors play a role in dysregulation of the immune balance (explaining the increased autoantibodies), most patients do not develop clinical disease, suggesting possible alternative pathogenic pathways or genetic susceptibility.

It may be prudent to consider that some patients with drug-induced lupus-like syndromes related to the use of TNF inhibitors may be at risk for developing SLE. Further, it may be of interest to define the characteristics of patients taking TNF blockers who develop lupus-like syndromes and SLE.

SHARON BOUT-TABAKU, MSc, MD, Fellow; RAFAEL RIVAS-CHACON, MD, Associate Clinical Professor, Department of Rheumatology, University of Miami, School of Medicine; RICARDO RESTREPO, MD, Attending Physician, Department of Radiology, Miami Children's Hospital, Miami, Florida, USA. Address reprints requests to Dr. Bout-Tabaku; e-mail: bouttabaku@email.chop.edu.

REFERENCES

1. Moreland LW, Schiff MH, Baumgartner SW, et al. Etanercept therapy in rheumatoid arthritis. A randomized, controlled trial. *Ann Intern Med* 1999;130:478-86.
2. Mohan AK, Edwards ET, Cote TR, Siegel JN, Braun MM. Drug-induced systemic lupus erythematosus and TNF-alpha blockers. *Lancet* 2002;360:646.
3. Amgen. Enbrel and Autoantibodies/SLE Data.
4. Debandt M, Vittecoq O, Descamps V, Le Loet X, Meyer O. Anti-TNF-alpha-induced systemic lupus syndrome. *Clin Rheumatol* 2003;22:56-61.
5. Shakoob N, Michalska M, Harris CA, Block JA. Drug-induced systemic lupus erythematosus associated with etanercept therapy. *Lancet* 2002;359:579-80.
6. Kang MJ, Lee YH, Lee J. Etanercept-induced systemic lupus erythematosus in a patient with rheumatoid arthritis. *J Korean Med Sci* 2006;21:946-9.
7. Fernandez A, Quintana G, Rondon F, et al. Lupus arthropathy: a

- case series of patients with rhus. *Clin Rheumatol* 2006;25:164-7.
8. Fleischmann RM, Iqbal I, Stern RL. Considerations with the use of biological therapy in the treatment of rheumatoid arthritis. *Expert Opin Drug Saf* 2004;3:391-403.
 9. Aringer M, Feierl E, Steiner G, et al. Increased bioactive TNF in human systemic lupus erythematosus: associations with cell death. *Lupus* 2002;11:102-8.
 10. Cairns AP, Duncan MK, Hinder AE, Taggart AJ. New onset systemic lupus erythematosus in a patient receiving etanercept for rheumatoid arthritis. *Ann Rheum Dis* 2002;61:1031-2.

Central Nervous System Involvement in Blau Syndrome: A New Feature of the Syndrome?

To the Editor:

Blau syndrome is an autosomal dominant syndrome characterized by the triad of joint, skin, and eye involvement. It is a disease of early childhood, which usually begins with spontaneously resolving rash. Eye involvement may lead to blindness without prompt treatment. Patients are generally negative for antinuclear antibodies, rheumatoid factors, and HLA-B27. Pathologic investigation of organs reveals granulomatous inflammation. We describe 3 members of a family with typical manifestations of Blau syndrome. In addition, seizure occurred in one case; this may be a new feature of the syndrome. The first case was a 10-year-old boy, referred to the pediatric rheumatology clinic with severe joint deformities (Figure 1A).

The disease began when he was 1.5 years old, with spontaneously resolving maculopapular rash and synovitis of the wrists and ankles. At age 6, blurring of vision occurred, which led to blindness in his right eye despite the use of topical corticosteroids. Later he experienced 2 episodes of generalized tonic seizures in a 48-hour interval. No aura was noted, and each lasted for nearly 20 minutes. Neurological examination was within normal limits, with no lateralizing signs. No neurological deficits remained as sequelae. Laboratory data were all within normal ranges. Brain magnetic resonance imaging was normal and electroencephalogram showed insignificant nonspecific sharp waves. The seizure was controlled by phenobarbital administered after the second episode.

The proband's sister was a 12-year-old girl with similar age of onset and course of progression. Articular manifestations began at an early age, with less severity. Asymptomatic synovial boggiess of both wrists and ankles was also noted (Figure 1B). Pathologic examination of the cyst revealed noncaseating granulomatous inflammation. The third case was a 42-year-old man, the father of patients 1 and 2, with the same onset and pattern of joint involvement. Decreased visual acuity and blurring of vision occurred at the age of 18 years, which led to complete visual loss of the right eye.

Blau syndrome or familial granulomatous arthropathy with uveitis, consisting of early onset arthritis, noncaseating granulomatous dermal infiltrations, synovial cysts, and uveitis¹, is a rare granulomatous disease; Blau syndrome can be "typical" or "atypical." The typical form involves skin, joints and eyes; in the atypical syndrome, other organs such as the kidneys², liver³, and peripheral nerves⁴ are involved. The leading manifestation is rash, which has been reported as early as 4 months of age¹.

The arthritis starts in the first decade of life as moderately painful cys-

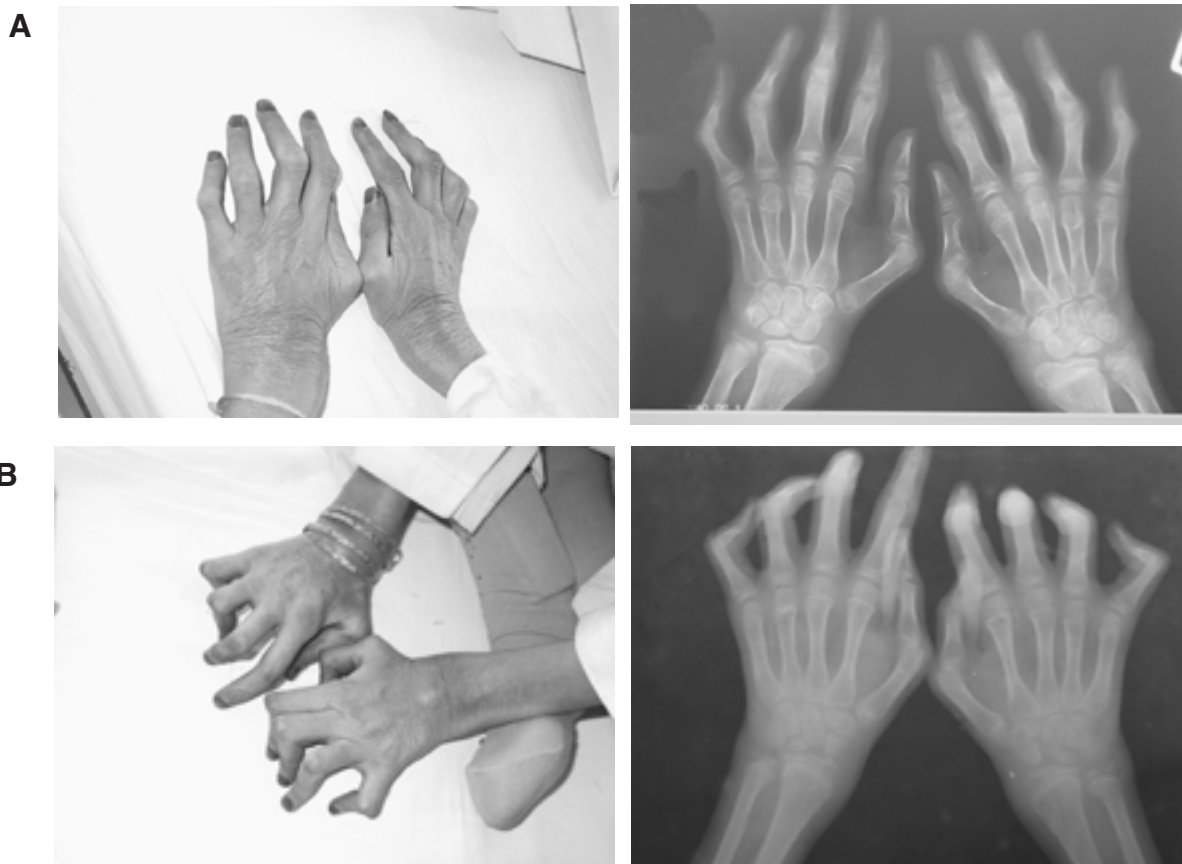


Figure 1. A. Case 1, with Boutonniere's deformity of most digits. Radiograph shows decreased joint space is mostly in proximal interphalangeal joints. B. Case 2 shows a synovial cyst on the left wrist. Radiograph shows bilateral first metacarpophalangeal subluxation.

tic swellings of the wrists, fingers, ankles, and elbows with erythema and mild tenderness. Eye involvement represents the most severe aspect of the syndrome and can appear early in childhood or in adulthood. Involvement of the nervous system was first described by Jabs and colleagues in 1985⁴ as corticosteroid-responsive bilateral neurosensory hearing loss in one case, and transient sixth nerve palsy in another. To our knowledge, this is the first report of central nervous system involvement as a manifestation of Blau syndrome.

ABBAS EMAMI NIA, MD; MOHAMMAD NABAVI, MD; MAHSA MOUSAVI NASAB, MD, Department of Pediatrics, Division of Pediatric Rheumatology, Shiraz University of Medical Sciences; SARA KASHEF, MD, Associate Professor, Division of Pediatric Immunology and Rheumatology, Namazi Hospital, Shiraz, Iran. Address reprint requests to Dr. Emami Nia; E-mail: emaminia@gmail.com

REFERENCES

1. Blau EB. Familial granulomatous arthritis, iritis and rash. *J Pediatr* 1985;107:689-93.
2. Ting SS, Ziegler J, Fischer E. Familial granulomatous arthritis (Blau syndrome) with granulomatous renal lesion. *J Pediatr* 1998;133:450-2.
3. Saini SK, Rose CD. Liver involvement in familial granulomatous arthritis (Blau syndrome). *J Rheumatol* 1996;23:396-9.
4. Jabs DA, Houk JL, Bids WB, Arnett FC. Familial granulomatous synovitis, uveitis, and cranial neuropathies. *Am J Med* 1985;78:801-4.

Diagnosis of Muckle-Wells Syndrome — 33 Years Later

To the Editor:

As medical information is rapidly expanding, it is incumbent on the clinician to continually reevaluate every patient, looking for new diagnostic and therapeutic opportunities. We describe our experience with a woman who developed her disease at 4 months of age but in whom the diagnosis and appropriate therapy were delayed until she was 33 years old. The diagnosis was originally missed, because 30 years ago the syndrome was not widely recognized, the tools necessary for diagnosis had not yet been developed, and effective therapy had not yet been devised. Three decades of accumulating medical experience, creation of new diagnostic techniques, and development of new effective therapies resulted in diagnosis and successful treatment of her disorder.

The patient was a 33-year-old Caucasian woman referred to the University of California, San Francisco, with a chronic syndrome characterized by recurrent urticaria, migratory polyarthritis, progressive hearing loss, intermittent anterior eye disease (episcleritis, scleritis, uveitis, and iridocyclitis), headaches, intermittent fevers, lymphadenopathy, and episodic diarrhea. Her disease had begun when she was 4 months of age, and over 30 years she had been evaluated by an army of pediatricians, internists, rheumatologists, otolaryngologists, and ophthalmologists, with no definitive diagnosis. Therapeutic interventions included various nonsteroidal antiinflammatory agents, antihistamines, prednisone, and colchicine, all of which were of limited benefit or associated with unacceptable side effects.

At presentation her therapeutic regimen included diclofenac, 75 mg bid, and colchicine, 0.6 mg tid. Physical examination revealed bilateral conjunctivitis, hearing loss requiring the use of hearing aids in both ears, synovitis of the left wrist, and urticaria of the shoulders, trunk and thighs. Laboratory evaluation revealed a hematocrit of 30.4%, white blood cell count $8.8 \times 10^9/l$, and platelet count $333 \times 10^9/l$. Erythrocyte sedimentation rate was 45 mm/h and C-reactive protein was 28.1 mg/l (normal < 6.3). Liver function studies, electrolytes, creatinine, blood urea nitrogen, antinuclear antibody, rheumatoid factor, antineutrophil cytoplasm antibodies, complement levels (C3 and C4), quantitative immunoglobulins, hepatitis C

antibody, thyroid function studies, antithyroid antibodies, cryoglobulins, creatine phosphokinase, and urinalysis were all normal. Chest radiograph and magnetic resonance imaging of the brain were unremarkable. A previous biopsy of one of the skin lesions revealed urticarial vasculitis.

Because the constellation of signs and symptoms was consistent with a diagnosis of Muckle-Wells syndrome, a buccal swab was sent for genetic testing. Gene sequencing revealed a heterozygous cytosine to thiamine substitution in exon 3 of the *CIAS1* gene, leading to a methionine for threonine substitution at amino acid position 348 in the cryopyrin protein. This mutation is seen in patients with the Muckle-Wells syndrome or with familial cold urticaria. After the diagnosis was confirmed, treatment with the interleukin 1 (IL-1) receptor antagonist anakinra (100 mg subcutaneously per day) was begun. Within 24 hours of the first injection she noted a dramatic improvement. Since initiation of therapy 1 year ago, ocular inflammation and arthritis have recurred only once, when she went on a 3 day vacation and forgot her anakinra.

Muckle-Wells syndrome is a heritable autoinflammatory disorder characterized by progressive deafness, inflammatory eye disease, recurrent urticaria, cutaneous vasculitis, arthritis, lymphadenopathy, abdominal pain and bloating, and recurrent fevers¹. Some patients will eventually develop AA amyloidosis. The disease begins during infancy, so generally patients are diagnosed and treated by pediatricians. The disorder is due to some of over 20 defects in the *CIAS1* gene (also termed *NALP3* or *PYPAF1*) that codes for the production of cryopyrin, a protein that modulates a platform of proinflammatory cytokines important in the innate immune system². Related disorders with defects at the same locus include familial cold-induced urticaria, neonatal-onset multisystem inflammatory disease (NOMID), and the CINCA (chronic infantile neurologic, cutaneous, articular) syndrome. Specific gene sequencing, available commercially and done with a simple cheek swab, now offers clinicians the capability of a definitive diagnosis.

Prednisone, antihistamines, dapsone, minocycline, azathioprine, chlorambucil, mycophenolate mofetil, and infliximab have all been used to treat the inflammatory components of the disorder, and colchicine has been prescribed in hope of preventing the development of amyloidosis. None of these therapies has been particularly helpful in the long term. The defect at *CIAS1* results in unregulated activation of a number of humoral inflammatory mediators, including IL-1 α , IL-1 β , tumor necrosis factor- α , IL-3, IL-5, IL-6, and IL-18^{3,4}.

The proinflammatory cytokine IL-1 β is felt to be the major mediator of the clinical manifestations of Muckle-Wells syndrome. Therefore, development of the IL-1 receptor antagonist anakinra that could block the ability of IL-1 β to mediate the inflammatory process offered patients a potentially valuable therapeutic modality. Anakinra has proven to be dramatically effective in short-term treatment of Muckle-Wells syndrome². There is even evidence that anakinra can normalize serum amyloid A protein⁵, suggesting that it could prevent the development of AA amyloidosis in these patients. Certainly, our patient's dramatic response to anakinra appears to be typical of patients with this disorder.

This case is an example of just how much our diagnostic and therapeutic capability has improved in the last 30 years. It is a reminder that physicians should try to view every new patient interaction as if it were the patient's first experience with a medical professional. Without an open, unbiased assessment of even longstanding chronic problems there is always the risk that incorrect diagnoses or inadequate therapies will be perpetuated for decades, and that new diagnostic and therapeutic modalities will be wasted for lack of consideration.

KENNETH H. FYE, MD, Professor of Clinical Medicine, Division of Rheumatology, Department of Medicine, University of California, San Francisco; DAWN H. SIEGEL, MD, Resident in Dermatology, Department of Dermatology, University of California, San Francisco; M. KARI CONNOLLY, MD, Professor of Dermatology and Medicine, Departments of Dermatology and Medicine, University of California, San Francisco. Address reprint requests to Dr. Fye; E-mail: Ken.Fye@ucsf.edu.

REFERENCES

1. Hawkins PN, Lachman HJ, Aganna E, McDermott MF. Spectrum of clinical features in Muckle-Wells syndrome and response to anakinra. *Arthritis Rheum* 2004;50:607-12.
 2. Aksentijevich I, Nowak M, Mallah M, et al. De novo mutations, cytokine activation, and evidence for genetic heterogeneity in patients with neonatal-onset multisystem inflammatory disease (NOMID): a new member of the expanding family of pyrin-associated autoinflammatory diseases. *Arthritis Rheum* 2002;46:3340-8.
 3. Sutterwala FS, Ogura Y, Szczepanik M, et al. Critical role for NALP3/CIAS1/cryopyrin in innate and adaptive immunity through its regulation of caspase-1. *Immunity* 2006;24:241-3.
 4. Mariathasan S, Weiss DS, Newton K, et al. Cryopyrin activates the inflammasome in response to toxins and ATP. *Nature* 2006;440:228-32.
 5. Hawkins PN, Lachman HJ. Interleukin-1 receptor antagonist in the Muckle-Wells syndrome. *N Engl J Med* 2003;348:2583-4.
-

Corrections

Roux CH, Brocq O, Leccia N, et al. New-onset psoriatic palmoplantar pustulosis following infliximab therapy: A class effect? *J Rheumatol* 2007;34:434-7. The last author's name should correctly be spelled Lianna Euler-Ziegler. We regret the error.

Maksymowych WP, Landewé R, Boers M, et al. Development of draft validation criteria for a soluble biomarker to be regarded as a valid biomarker reflecting structural damage endpoints in rheumatoid arthritis and spondyloarthritis clinical trials. *J Rheumatol* 2007;34:634-40. The eighth author's name should correctly be spelled Virginia B. Kraus. We regret the error.

Durai M, Kim HR, Bala K, Moudgil KD. T cells against the pathogenic and protective epitopes of heat-shock protein 65 are crossreactive and display functional similarity: novel aspect of regulation of autoimmune arthritis. *J Rheumatol* 2007;34:2134-43. The name of the third author should be Kamalesh K. Bala. We regret the error.