

## Rheumatoid Nodule of the Extensor Tendons of the Lower Extremity

DEREK J. DONEGAN, MD, Orthopedic Resident, University of Pennsylvania; JOSEPH N. DANIEL, DO, Attending Orthopedic Surgeon, Albert Einstein Medical Center, Philadelphia, Pennsylvania, USA. Address reprint requests to Dr. D. Donegan, Department of Orthopaedic Surgery, Hospital of the University of Pennsylvania, 2 Silverstein Bldg., 3400 Spruce Street, Philadelphia, PA 19104. E-mail: derek.donegan@uphs.upenn.edu

A 40-year-old woman with a significant history of rheumatoid arthritis (RA) presented with the atraumatic onset of a painless enlarging mass lesion to the left leg, ankle, and foot complex over the past several months. She denied weakness or instability. She had a surgical history of excision of similar masses involving the upper extremities that were determined to be rheumatoid nodules. Examination of the left lower extremity revealed normal neurologic and vascular features, with full motor function from the level of L2 to S1. There was a soft, mobile mass lesion along the anterior aspect of the distal third of the left leg, the anterior aspect of the left ankle, and the dorsal medial and dorsal lateral aspect of the left foot. The location of the mass across the anterior aspect of the ankle joint resulted in limitation in dorsiflexion to less than 5°, making

ground clearance challenging during the swing phase of gait. Plain radiographs of the left ankle revealed evidence of a soft tissue shadow about the anterior aspect of the distal third of the left leg, ankle, and dorsum of the foot. There was no evidence of any bony pathology. Magnetic resonance imaging revealed a multiloculated fluid collection measuring 28 cm at its greatest length (Figures 1–3). The structure appeared to wrap around the medial anterior and lateral aspects of the ankle and to involve the extensor tendons. There was no evidence of tendon or ligament attenuation.

The decision was made to surgically resect the mass due to the limitations imposed on the patient's daily activity. The mass was resected and found to contain a viscous, brown fluid. The underlying extensor tendons across the ankle joint

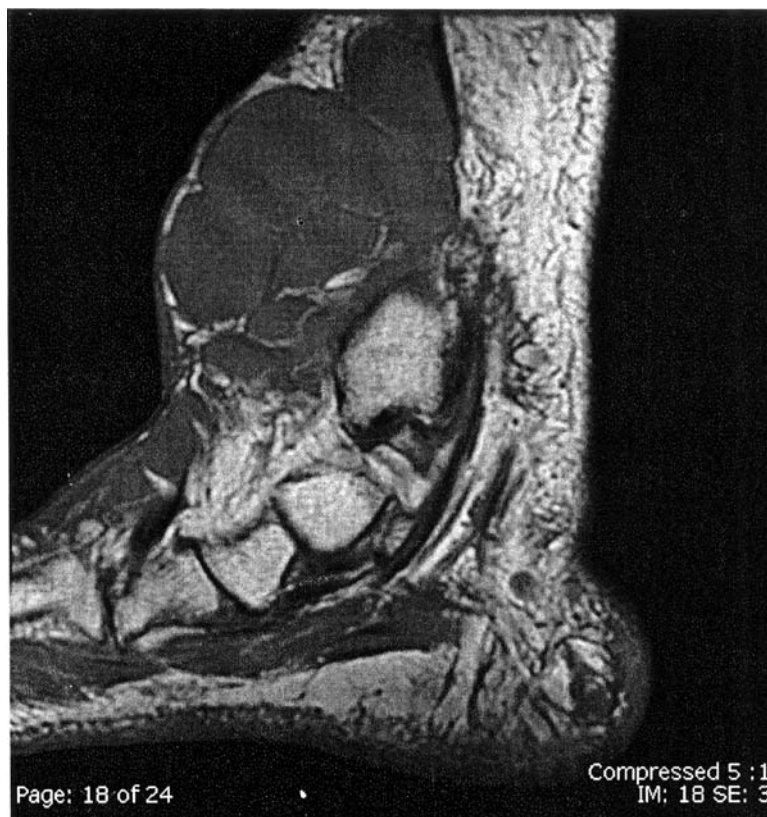


Figure 1. Sagittal T1 weighted MRI of left lower extremity showing a hypointense lobulated mass.

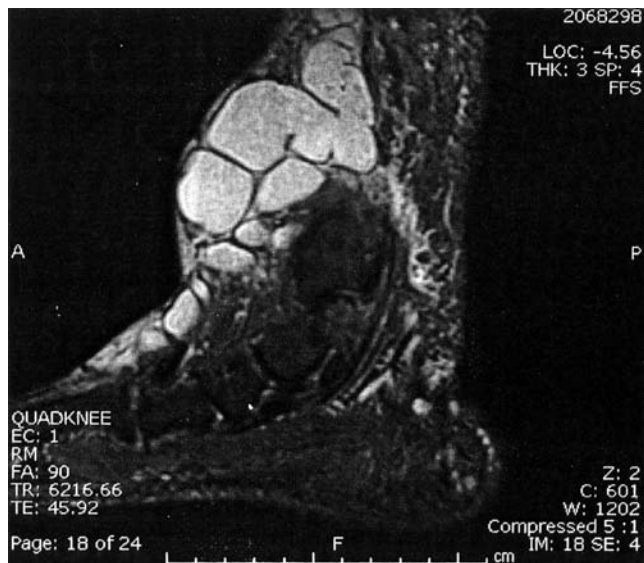


Figure 2. Sagittal T2 weighted MRI of left lower extremity showing a hyperintense enhancing lobulated mass.

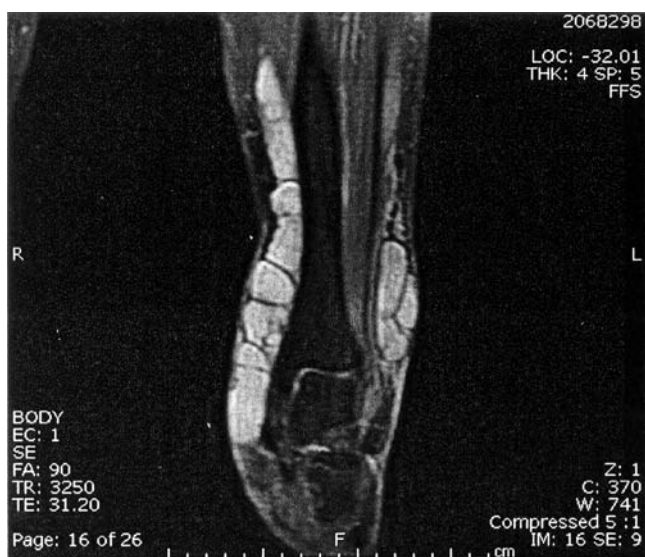

Figure 3. Coronal proton density fat saturation MRI of left lower extremity showing the enhancing lobulated mass.

were all intact. The specimen was sent to pathology and was found to be consistent with a rheumatoid nodule. The patient had routine postoperative care and has now resumed full weight-bearing activities without limitation and regained full range of motion of her left ankle joint.

Management of rheumatoid nodules varies. Typically, treatment is not necessary since they are often asymptomatic. It has been recommended that nodules should not be drained, injected, or excised due to the high risk of infection or recurrence with such intervention<sup>1</sup>. Local corticosteroid injections may be used to reduce large nodules, but this is not widely recommended due to the risk of persistent drainage or infection<sup>2</sup>. Surgical removal may be considered if nodules are debilitating, ulcerated, infected, compressing a nerve, or causing a limited range of joint motion<sup>3,4</sup>. Nodules tend to shrink as the arthritic component is managed with therapy; however, some nodules may persist or even worsen with treatment<sup>5,6</sup>.

Rheumatoid nodules tend to reflect the activity of the underlying RA. Treatment options for these nodules are limited due to their highly variable structure. Current methods of treatment include observation, the use of antirheumatic agents, and surgical excision. As shown in our case, surgery was the desired treatment option due to the size and physical limitations caused by the nodule.

## REFERENCES

1. Calin A. Diagnosis and management of rheumatoid arthritis. Menlo Park, CA: Addison-Wesley Publishing; 1983.
2. Rothermich NO, Whisler RL. Rheumatoid arthritis. Orlando: Grune & Stratton, Inc.; 1985.
3. Arnold C. The management of rheumatoid nodules [comment]. Am J Orthop 1996;25:706-8.
4. Kaye BR, Kaye RL, Bobrove A. Rheumatoid nodules. Review of the spectrum of associated conditions and proposal of a new classification, with a report of four seronegative cases. Am J Med 1984;76:279-92.
5. O'Gradaugh D, Watts RA, Scott DG. Extra-articular features of rheumatoid arthritis. In: Firestein GS, Panayi GS, Wollheim FA, editors. Rheumatoid arthritis: frontiers in pathogenesis and treatment. New York: Oxford University Press; 2000:229-32.
6. Ruddy S, Harris ED, Sledge CB. Kelley's textbook of rheumatology. 6th ed. Philadelphia: WB Saunders Co.; 2001.