Case Report

Laser Induced Chrysiasis: Disfiguring Hyperpigmentation Following Q-Switched Laser Therapy in a Woman Previously Treated with Gold

HANI ALMOALLIM, ALICE V. KLINKHOFF, ANNE B. ARTHUR, JASON K. RIVERS, and ANDREW CHALMERS

ABSTRACT. We describe a 40-year-old woman with rheumatoid arthritis and a history of 2 previous courses of intramuscular gold who developed disfiguring hyperpigmentation immediately after Q-switched laser therapy. This is the third case report of localized chrysiasis induced by laser therapy. (J Rheumatol 2006;33:620–1)

Key Indexing Terms:
LASER INDUCED CHRYSIASIS LASER GOLD CHRYSIASIS RHEUMATOID ARTHRITIS

Chrysiasis is a permanent slate-gray skin pigmentation that may occur in individuals receiving longterm gold therapy. Laser induced chrysiasis has been reported previously in 2 patients with a history of gold treatment for inflammatory arthritis[1,2]. We describe a third patient in whom disfiguring hyperpigmentation of the skin developed after treatment with a Q-switched laser.

CASE REPORT

A 20-year-old Caucasian woman developed seropositive rheumatoid arthritis (RA) in 1980. Over a 20-year period she was treated with standard disease modifying regimens including 2 courses of intramuscular gold. The first course was discontinued in 1986 after a cumulative dose of 5020 mg. The second course between 1997 and 1998 consisted of 3325 mg. Between February 1999 and January 2001 she received a combination of methotrexate and adalimumab in the setting of a clinical trial. In January 2001 she underwent laser hair removal with a Q-switched Nd:YAG laser. Immediately she developed a dense blue-gray skin discoloration involving 2.5 × 5 cm confined to the treatment area of the cheek (Figure 1). The lesion was diagnosed as chrysiasis likely induced by Q-switched laser treatment.

DISCUSSION

Chrysiasis was first described by Hansborg, *et al* in 1928 in a woman who received 12 g of gold sodium thiosulfate for pulmonary tuberculosis[3]. Chrysiasis develops gradually in patients on longterm gold therapy, and is typically noted after a cumulative dose of 8 g. Dermal pigmentation appears blue or gray because of pigment dispersion in the dermis that results in depression of diffuse reflectance in the longer red

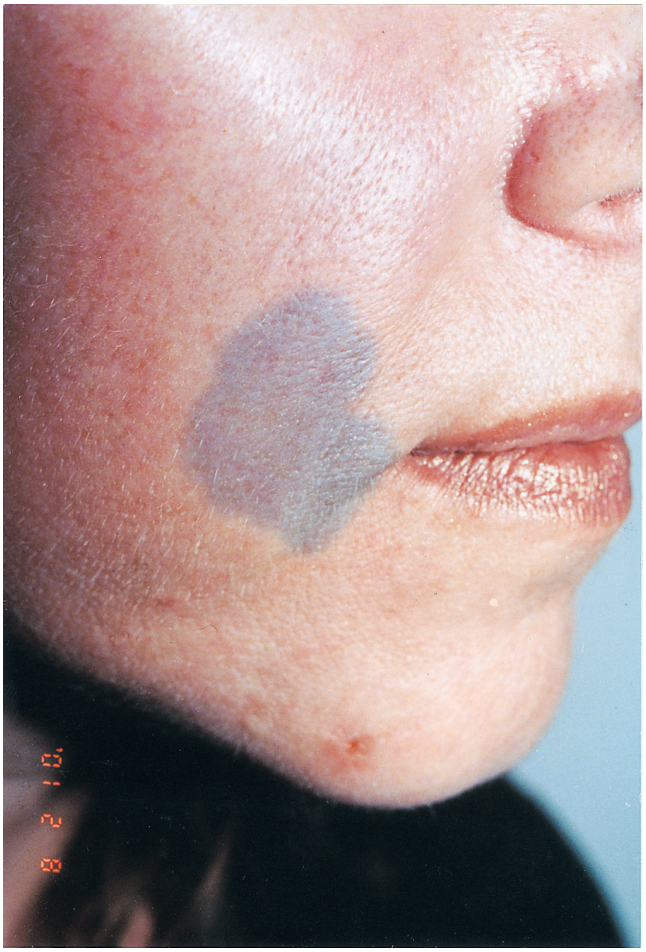

Figure 1. Immediately after Q-switched laser treatment, blue-gray hyperpigmentation developed involving 2.5 × 5 cm confined to the treated area of the cheek.

From the Divisions of Rheumatology and Dermatology, Department of Medicine, University of British Columbia, Vancouver, British Columbia, Canada.

H. Almoallim, MBBS, FRCP, Assistant Professor, Internal Medicine Department, University of Umm Alqura, Former Clinical Rheumatology Fellow, Division of Rheumatology; A.V. Klinkhoff, MD, FRCPC, Clinical Associate Professor, Division of Rheumatology; J.K. Rivers, MD, FRCPC, Professor of Medicine, Division of Dermatology; A.B. Arthur, RN, MSN, Research Nurse, Arthritis Research Centre of Canada; A. Chalmers, MD, FRCPC, Professor of Medicine, Division of Rheumatology, University of British Columbia.

Address reprint requests to Dr. A. Klinkhoff, 895 West 10th Avenue, Vancouver, BC V5Z 1L7.

Accepted for publication October 28, 2005.

wavelengths[4]. In patients receiving gold therapy, semiquantitative assessment of dermal gold concentration correlates with degree of visible skin pigmentation[5]. In one study, chrysiasis developed in 29/29 patients who had received more than 45 mg/kg and in 2/11 who had received smaller cumulative amounts[5].

In chrysiasis, dermatopathologists have described aggregates of gold seen on light microscopy in the reticular and papillary dermis in a predominantly perivascular distribution. On light microscopy gold deposits appear as black particulate matter within macrophages, which are clustered around dermal blood vessels in the papillary-reticular dermal plexus and around sweat glands. These black particles do not stain for iron, do not bleach after melanin stains, and have very weak red birefringence in polarized light[5]. Electron microscopy reveals that these particles are electron-dense and localized in lysosomes; electron probe microanalysis, a technique able to identify elements by their specific patterns of emitted frequencies, is used to confirm the presence of gold[6]. Leonard, *et al* have proposed 2 possible explanations for the localization of chrysiasis to sun exposed skin[7]. One theory proposes that hyperpigmentation results from a combination of gold deposition and an increase in melanogenesis caused by gold in sun exposed areas. A second proposal is that the exposure to ultraviolet light promotes deposition of gold in the skin[7].

Highly selective pulsed lasers have become available since the late 1980s and are successfully employed for the treatment of vascular lesions, benign pigmented lesions, and tattoos. Lasers target microscopic sites of selective light absorption in the skin, such as blood vessels and pigmented cells, with minimal damage to adjacent tissue. To achieve this selective effect lasers must fulfill 3 requirements: they emit at a wavelength that is highly absorbed by the targeted structure; they produce high energy to inflict thermal damage; the time of tissue exposure is short so that there is no heat diffusion that can damage surrounding tissue. The primary site of laser induced damage is most likely the melanosome. Q-switched lasers are characterized by very short pulse duration, less than 1 microsecond, which selectively targets subcellular organelles such as melanosomes and tattoo particles. Other pulsed lasers are distinguished by wavelength and pulse duration or width. The short wavelengths target superficial pigmented lesions leaving deeper structures intact, while longer wavelengths can target deeper dermal lesions[8].

The first report of laser induced chrysiasis was published in 1995[1]. The subject of that report had psoriatic arthritis and had received an estimated 11.5 g of gold. Immediately after Q-switched laser treatment for granuloma faciale, there developed a blue-gray hyperpigmentation that persisted despite treatment with topical agents. Transmission electron microscopy showed electron-dense deposits, and these were confirmed to contain gold by energy-dispersive radiograph microanalysis. The biopsy from the laser induced skin change was compared with his normal appearing skin. Both biopsies showed dermal gold deposits, but the size of the deposits was dramatically reduced in the lesion that had been treated with the laser and the faceted appearance of the gold was lost[1].

A second report of this phenomenon was reported in 2002[2]. The patient had received a 3-year course of oral gold 20 years previously. She underwent Q-switched alexandrite laser treatment for facial lentigines. A blue-black discoloration developed and persisted for 4 months. A biopsy revealed numerous black particles within dermal macrophages. Although the subject's history of gold therapy was remote and the amount of gold ingested in auranofin may have been small, this report again emphasizes that gold may remain in dermal macrophages indefinitely[3].

The authors of the second report proposed that the power delivered per unit area determines the risk of laser induced chrysiasis, and suggested that Q-switched versions of alexandrite, ruby Nd:YAG laser, short pulsed dye lasers, quasi-continuous KTP lasers, and xanon excimer lasers may be prone to cause laser induced chrysiasis in patients who have received prior gold therapy.

Although other arthritis medications, including methotrexate, can cause photosensitive reactions, they do not cause this type of localized hyperpigmention.

Rheumatologists, dermatologists, and patients must be aware of the risk of inducing permanent localized chrysiasis from Q-switched and other short pulsed laser devices in individuals who have ever received gold therapy.

REFERENCES

1. Trotter MJ, Tron VA, Hollingdale J, Rivers JK. Localized chrysiasis induced by laser therapy. Arch Dermatol 1995;131:1411-4.
2. Yun PL, Arndt KA, Anderson RR. Q-switched laser-induced chrysiasis treated with long-pulsed laser. Arch Dermatol 2002;138:1012-4.
3. Hansborg H. Chrysiasis ablagerung von gold in vivo. Acta Tuberc Scand 1928;4:124.
4. Mosher D, Fitzpatrick T, Hori Y, et al. Disorders of pigmentation: pathogenesis of dermal hyperpigmentation. In: Fitzpatrick TB, Eisen AZ, Wolff K, et al, editors. Dermatology in general medicine. 4th ed. New York: McGraw-Hill; 1993.
5. Smith RW, Leppard B, Barnett NL, et al. Chrysiasis revisited: a clinical and pathological study. Br J Dermatol 1995;133:671-8.
6. Benn HP, von Gaudecker B, Czank M, Loeffler H. Crystalline and amorphous gold in chrysiasis. Arch Dermatol Res 1990;282:172-8.
7. Leonard PA, Moatamed F, Ward JR, et al. Chrysiasis: the role of sun exposure in dermal hyperpigmentation secondary to gold therapy. J Rheumatol 1986;13:58-64.
8. Stratigos AJ, Dover JS, Arndt KA. Laser treatment of pigmented lesions — 2000. How far have we gone? Arch Dermatol 2000;136:915-21.