

# Does the Nature of Deposited Basic Calcium Phosphate Crystals Determine Clinical Course in Calcific Periarthritis of the Shoulder?

JUN'ICHIRO HAMADA, KAZUYA TAMAI, WATARU ONO, and KOICHI SAOTOME

**ABSTRACT. Objective.** Two typical clinical courses of calcific periarthritis in the shoulder are known: acute, with severe inflammation, and chronic, in the form of impingement syndrome with secondary subacromial bursitis. It remains unclear what factors determine these clinical courses. Our objectives were to clarify whether the calcified deposits that occur in both acute and chronic cases are composed of carbonate apatite; and to compare the Ca:P molar ratio in the 2 forms and to determine if there was any correlation in this respect with the intensity of inflammation induced by basic calcium phosphate crystals.

**Methods.** Ten samples were aspirated from 10 women (ages 42–65 yrs) with acute inflammation. The average time from first attack to aspiration was 2.3 days. A further 10 samples were operatively removed from 10 women (ages 35–58 yrs) with refractory chronic subacromial bursitis, among whom an average of 7.8 months had passed since the onset of symptoms. All samples were analyzed by x-ray diffraction, Fourier transform infrared spectroscopy, and Raman spectroscopy, and Ca:P molar ratios were measured by x-ray fluorescence spectrometry.

**Results.** Calcified deposits from both acute and chronic cases were identified as carbonate apatite, and not hydroxyapatite, octacalcium phosphate, tricalcium phosphate, or dicalcium phosphate dihydrate. The average Ca:P molar ratio of calcified deposits was calculated as  $1.71 \pm 0.16$  in acute cases and  $1.71 \pm 0.16$  in chronic cases (statistically nonsignificant).

**Conclusion.** Deposits around the shoulder in both acute and chronic calcific periarthritis are composed of carbonate apatite, Ca:P molar ratios being almost identical in the 2 forms. The results suggest that some factor other than the composition of the crystalline deposits may determine clinical course in calcific periarthritis of the shoulder. (J Rheumatol 2006;33:326–32)

*Key Indexing Terms:*

CALCIFIC PERIARTHROSIS  
SHOULDER JOINT

CLINICAL COURSE  
CARBONATE APATITE

Basic calcium phosphate (BCP) crystals induce acute or chronic inflammation in the soft tissues around the joint, and calcific periarthritis of the shoulder is particularly common. However, the pathogenesis, diverse clinical courses of the disease, and the phases of crystal formation and enlargement and disruption or resorption of calcific deposits remain undefined. Some investigators have tried to explain the clinical courses or phases of the disease. DePalma and Kruper<sup>1</sup> divided clinical symptoms into 3 groups on the basis of time and acuteness of symptoms as: (1) acute, in which symptoms persist one to 4 weeks; (2) subacute, in which symptoms persist one to 6 months; and (3) chronic, in which

symptoms persist more than 6 months. They also reported that calcific deposits in acute cases were liquid and presented a fluffy, fleecy appearance on radiographs, whereas deposits in subacute or chronic cases were chalk-like and appeared more or less discrete and homogeneous. Uthoff, *et al*<sup>2</sup> proposed classifying the calcification process into 3 stages: (1) a precalcific stage; (2) a calcific stage, subdivided into formative, resting, and resorptive phases; and (3) a postcalcific stage. On the basis of experience of more than 300 cases, Moseley<sup>3</sup> subdivided the calcific stage into 4 phases: (1) a silent phase, in which the deposit is localized within the tendon with no clinical signs or symptoms; (2) a mechanical phase, in which the deposit enlarges in size and produces an elevation under the floor of the bursa with symptoms of bursitis; (3) a phase of sub-bursal rupture, in which the liquid deposit bursts out of the tendon under the floor of the bursa with recurrent rheumatic pains; and (4) a phase of intrabursal rupture in which the whole deposit evacuates into the bursa, with severe symptoms. As noted, clinical courses of calcific periarthritis are complicated and are still the subject of considerable dispute.

Reports have identified that hydroxyapatite (HAP), octa-

*From the Department of Orthopaedic Surgery, Dokkyo University School of Medicine, Tochigi, Japan.*

*J. Hamada, MD, PhD, Director, Department of Orthopedic Surgery, Kuwano Kyoritsu Hospital; K. Tamai, MD, PhD, Professor; W. Ono, MD, PhD, Assistant Professor; K. Saotome, MD, PhD, Professor, Chair, Department of Orthopaedic Surgery, Dokkyo University School of Medicine.*

*Address reprint requests to Dr. J. Hamada, Department of Orthopedic Surgery, Kuwano Kyoritsu Hospital, 2-9-18 Shima Koriyama-shi, Fukushima 963-8034, Japan. E-mail: i\_hamada@koriyama-h-coop.or.jp*

*Accepted for publication September 19, 2005.*

calcium phosphate (OCP), tricalcium phosphate (TCP), dicalcium phosphate dihydrate (DCPD), and carbonate apatite as BCP crystals are responsible for calcific peri-arthritis (Table 1)<sup>4,5</sup>. It has also been reported that the inflammatory potential of BCP crystals appears to vary according to crystal type, and that the Ca:P ratio influences the inflammatory properties of apatite crystals<sup>6,7</sup>. Therefore, the different clinical courses of the disease may be explained by the composition of the BCP crystals, conversion of the crystal type in the calcification process, or differences in Ca:P molar ratios between crystals.

We used x-ray diffraction (XRD), Fourier transform infrared spectroscopy (FTIR), Raman spectroscopy, and x-ray fluorescence spectrometry (XRF) to qualitatively analyze calcific deposits from patients with acute and chronic calcific peri-arthritis, and to measure the Ca:P molar ratio in each.

## MATERIALS AND METHODS

**Patients.** We recruited 10 patients with acute and 10 patients with chronic symptoms of calcific peri-arthritis in the shoulder joint according to the clinical classification of DePalma and Kruper<sup>1</sup>. Patients with calcium pyrophosphate dihydrate crystal deposition disease, connective tissue disease, chronic renal failure, or metabolic disorders were excluded.

The 10 patients with acute symptoms had experienced sudden onset of severe pain around the shoulder without trauma. All were female, and their ages ranged from 42 to 65 years (average 48.3 yrs). They visited our clinic within 3 days of the onset of symptoms and presented radiographically recognizable calcification in the rotator cuff tendon and/or subacromial bursa. The shoulder joints of all patients showed swelling and tenderness to varying degrees. Laboratory investigations showed elevated C-reactive protein (CRP) and white cell counts in peripheral blood in all patients. Fluid calcific deposits were aspirated by syringe, and the patients were injected with corticosteroid at sites of calcification and given nonsteroidal antiinflammatory drugs (NSAID). The aspirated fluid specimens could be seen by light microscopy to contain large numbers of polymorphonuclear leukocytes. The acute inflammation subsided by the tenth day of treatment on average (range 2–18 days).

The 10 patients with chronic symptoms had had mild or moderate shoulder pain for more than 1 month. Again, all were female, with ages ranging from 35 to 58 years (average 44.6 yrs). Physical examination showed positive impingement signs and slightly restricted motion of the affected shoulder joint. Calcification in the rotator cuff tendon was confirmed by radiographs in all. Laboratory investigations were negative for CRP and showed normal white cell counts. All patients took NSAID and underwent physiotherapy, and 7 of 10 were given corticosteroid injections in the subacromial bursa. As their symptoms had persisted for more than 6 months with our conservative treatment, we removed solid calcific deposits surgically. Durations between symptom onset and surgery ranged from 7 to

13 months (average 8.4 mo). Histological findings indicated no inflammatory reaction around calcific deposits in rotator cuff tendon, but significant cell proliferation in the bursal wall (data not shown).

**Preparation of calcific deposits.** Samples of calcific deposits from patients with acute or chronic symptoms were washed with distilled water and dried at room temperature. We also prepared heated samples, which were heated to 1000°C for 1 h<sup>5</sup>. Synthetic HAP to serve as a control was provided by Sumitomo Cement (Tokyo, Japan).

**X-ray diffraction.** The powder XRD patterns of all samples were recorded with a diffractometer (Ru 200B; Rigakudenki, Akishima, Japan) using CuK $\alpha$  radiation generated at 30 kV and 30 mA from a graphite monochromator. The detector was scanned between 3° and 90°. A data processor (RAD-B; Rigakudenki) was used to record radiation counts. Specimen components were defined according to the database of the Joint Committee on Powder Diffraction Standards (JCPDS)<sup>8</sup>.

**Raman spectroscopy.** Laser Raman spectra were collected from powdered samples with a spectrometer (Ramanor U-1000; Jobin Yvon, Longjumeau, France) using argon ion laser excitation at 5145 Å with an NEC GLG3300 exciter. Laser power determined at the samples ranged from 100 to 150 mW. The spectrum scan speed was 120 cm<sup>-1</sup>/min and scans were repeated 30 times. Spectral ranges<sup>5</sup> were from 3800 to 120 cm<sup>-1</sup>.

**Fourier transform infrared spectroscopy.** We obtained FTIR spectra between 4000 and 480 cm<sup>-1</sup> using a spectrometer (FTS-60; Bio-Rad, Waltham, MA, USA) in conjunction with a microscope (IR-Plan; Spectra Tech USA). The collected specimens were placed on a KRS-5 plate and direct measurements were performed without the use of any dispersion material such as KBr. Spectra were obtained at 8 cm<sup>-1</sup> resolution and averaged 256 scans<sup>5</sup>.

**X-ray fluorescence spectrometry.** XRF was performed using an x-ray analytical microscope (XGT-2000V; Horiba, Kyoto, Japan). Measurement conditions used of an acceleration voltage of 15.0 kV, an irradiation current of 1.0 mA, an analyzing beam diameter of 100 μm, and a measurement time of 600 s. Synthetic HAP (Ca:P molar ratio 1.67) and synthetic calcium pyrophosphate dihydrate (Ca:P molar ratio 1.00) were used as controls. The characteristic intensities of calcium and phosphorus were measured at 3 points on each sample<sup>8</sup>.

## RESULTS

**X-ray diffraction.** Figure 1 shows the powder XRD patterns of the acute case samples, the chronic case samples, and synthetic HAP. The XRD patterns of the acute and chronic case samples appearing in the vicinity of 25.9°, 31.8°, and 32.9° of 2 θ were similar to those of HAP and carbonated hydroxyapatite. Phases characteristic of OCP, TCP, and DCPD were not evident. The broader peaks displayed by all 20 samples indicated that calcific deposits in both acute and chronic cases possessed a lower degree of crystallinity than the synthetic HAP. Using XRD alone, HAP and carbonate apatite could not be differentiated. The XRD patterns of

Table 1. Calcium phosphate crystals involved in calcific peri-arthritis.

Chemical Name	Formula
Hydroxyapatite	Ca <sub>10</sub> (PO <sub>4</sub> ) <sub>6</sub> (OH) <sub>2</sub>
Octacalcium phosphate	Ca <sub>8</sub> H <sub>2</sub> (PO <sub>4</sub> ) <sub>6</sub> •5H <sub>2</sub> O
Tricalcium phosphate	Ca <sub>3</sub> (PO <sub>4</sub> ) <sub>2</sub>
Dicalcium phosphate dihydrate	CaHPO <sub>4</sub> •2H <sub>2</sub> O
Calcium phosphate dydrate	Ca <sub>3</sub> (PO <sub>4</sub> ) <sub>2</sub> •nH <sub>2</sub> O
Carbonate apatite	Ca <sub>10-x-y/2</sub> (PO <sub>4</sub> ) <sub>6-x</sub> (CO <sub>3</sub> ) <sub>y</sub> (OH) <sub>2-y</sub> (CO <sub>3</sub> ) <sub>y/2</sub> •nH <sub>2</sub> O

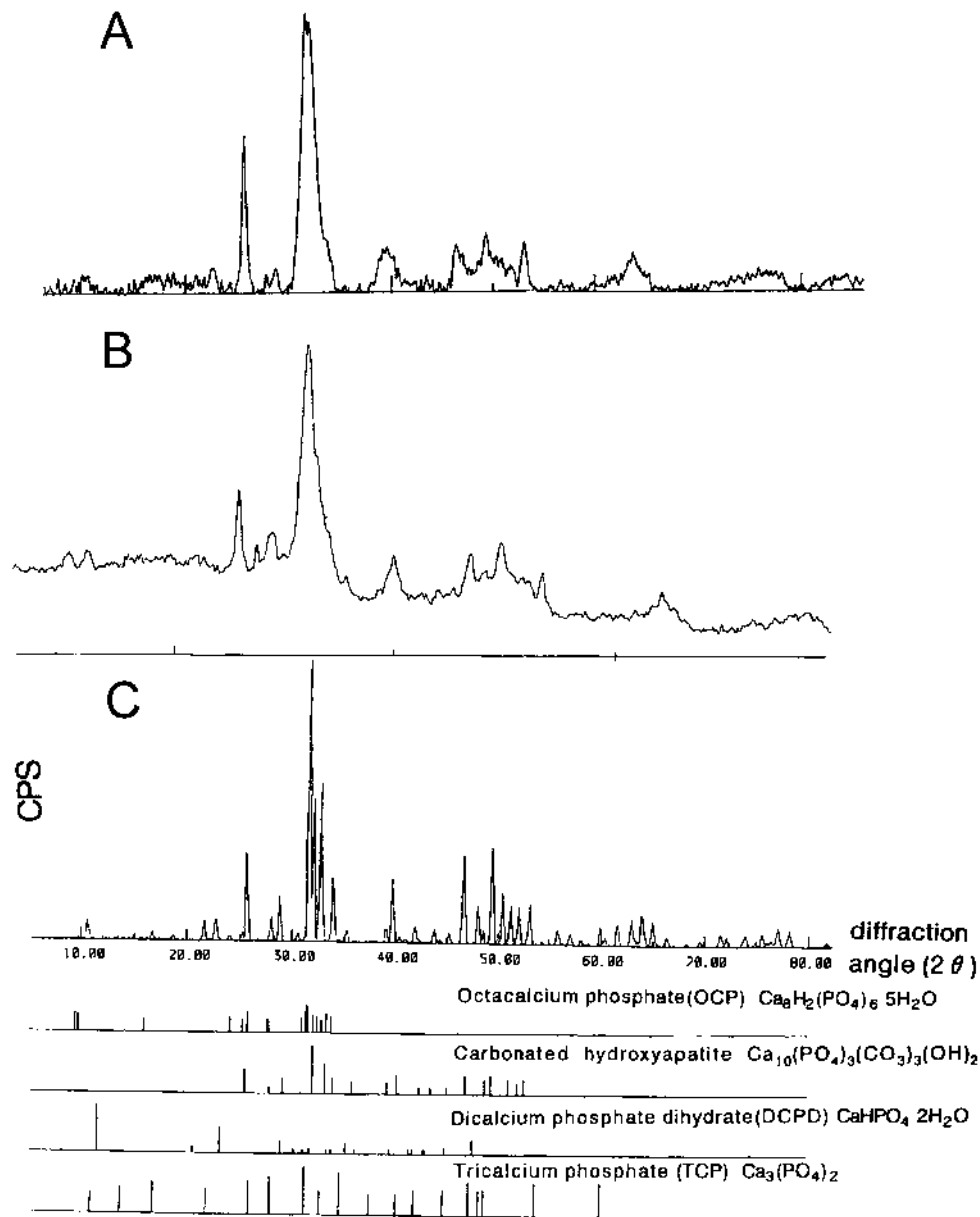


Figure 1. X-ray diffraction patterns of samples from an acute case (A), a chronic case (B), and from synthetic hydroxyapatite (C). XRD spectra of octacalcium phosphate, carbonated hydroxyapatite, dicalcium phosphate, and tricalcium phosphate from the Joint Committee on Powder Diffraction Standards database are shown at the bottom.

heated samples were consistent with that of HAP, as we have reported<sup>5</sup>.

**Raman spectroscopy.** Raman spectra of acute and chronic case samples and the synthetic HAP are shown in Figure 2. The spectra of all samples were characterized by a strong band at  $960\text{ cm}^{-1}$  derived from the symmetric stretching mode of the  $\text{PO}_4$  group. Other Raman-active modes were seen at  $1075$ ,  $590$ , and  $435\text{ cm}^{-1}$ . The weak bands at  $1447$ ,  $1580$ , and  $1650\text{ cm}^{-1}$  were derived from protein. Since water is a weak Raman scatterer, absorbed water, which can sometimes obscure parts of the infrared spectrum of calcium

phosphate minerals, affects the Raman spectrum minimally. The band positioned at  $3570\text{ cm}^{-1}$  attributable to the OH group was clearly observed in the synthetic HAP. In contrast, this band was absent from the acute and chronic case samples, indicating that neither possessed the OH base or contained HAP. The spectra of heated samples were completely compatible with that of HAP, as reported<sup>5</sup>.

**Fourier transform infrared spectroscopy.** Figure 3 shows the infrared spectra of the same 3 samples used for XRD and Raman spectroscopy. The OH band at  $3570\text{ cm}^{-1}$  was evident only in the synthetic HAP, and was unclear in both the

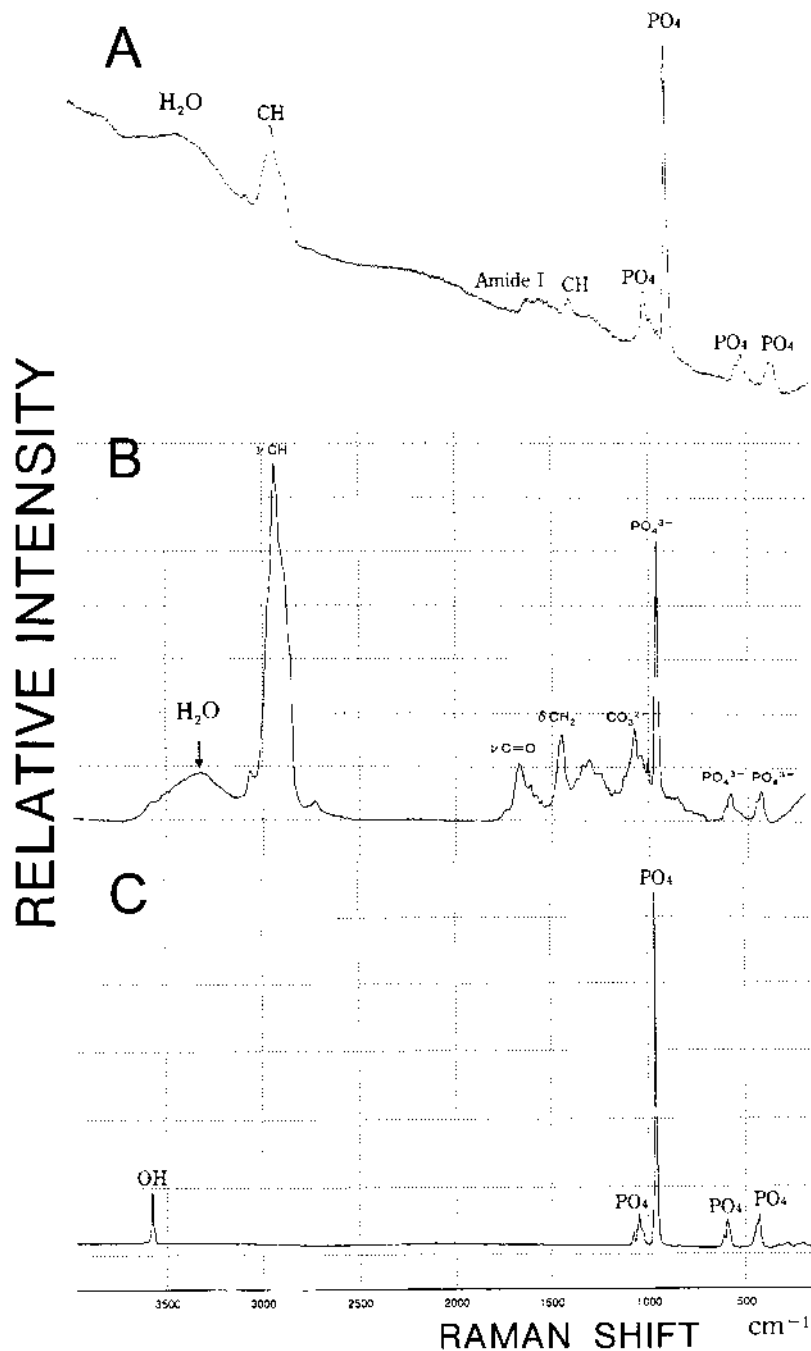


Figure 2. Raman spectra of samples from an acute case (A), a chronic case (B), and synthetic hydroxyapatite (C).

acute and chronic case samples due to the broad water band between 3100 and 3700  $\text{cm}^{-1}$ . Broad doublet-like bands in the 1600 to 1400  $\text{cm}^{-1}$  range and at 870  $\text{cm}^{-1}$  characteristic of carbonate ions were clearly observed in both acute and chronic case samples. The bands at 1230, 1650, and 2920  $\text{cm}^{-1}$  in the acute and chronic case samples are attributable to proteins bound to the samples, i.e., amide I, and  $\text{CH}_3$ . The intensity of carbonate bands did not change after depro-

teination by treatment with hydrazine. This indicates that carbonate replaces hydroxyl or phosphate ions in the calcium phosphate structure. The spectra of heated samples were completely compatible with that of HAP, as reported<sup>5</sup>.

*X-ray fluorescence spectrometry.* The presence of calcium and phosphorus in both acute and chronic case samples was confirmed by energy-dispersive spectra. Ca:P molar ratios are shown in Table 2. The mean Ca:P molar ratios in acute

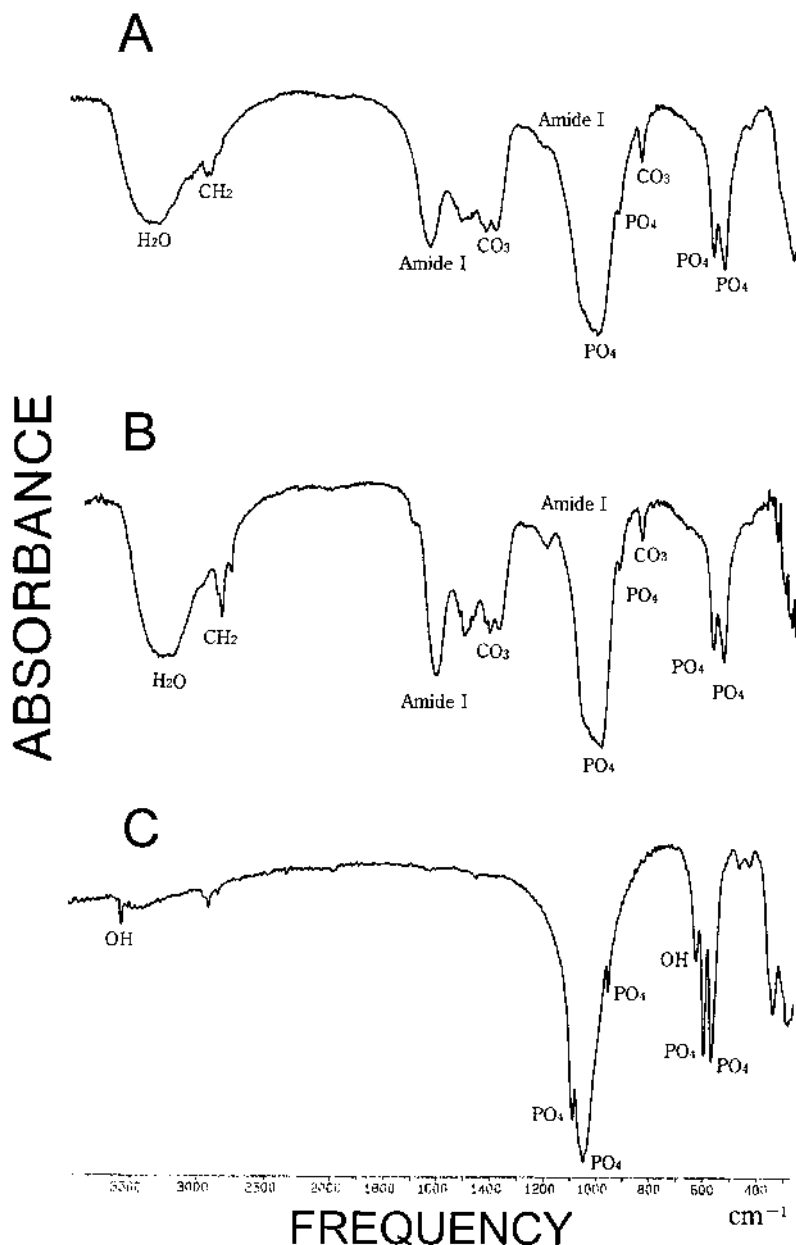


Figure 3. FTIR spectra of samples from an acute case (A), a chronic case (B), and synthetic hydroxyapatite (C).

case samples, chronic case samples, and synthetic HAP were 1.71, 1.71, and 1.67, respectively. The difference between the acute and chronic case samples was not statistically significant. The Ca:P molar ratio in heated samples was 1.67, as described<sup>5</sup>.

## DISCUSSION

XRD is an analytical method used to characterize and identify crystals based on their diffraction patterns. As shown in Figure 1, dried acute and chronic case samples had broad peaks compared to the synthetic HAP, indicating that they had a much lower degree of crystallinity (crystal size, crys-

tal imperfection, or both)<sup>9</sup>. The 3 strong peaks appearing in the vicinity of 25.8°, 31.7°, and 32.9° of 2θ in the dried samples could have resulted from HAP, carbonate apatite, or calcium phosphate hydrate (Table 1). These 3 substances are poorly differentiated by XRD<sup>5,10</sup>.

If the dried samples had been composed of calcium phosphate hydrate, this would have been converted to β-tricalcium phosphate by heating to 900°C<sup>11</sup>. We therefore heated dried samples to 900°C for 1 h, but they converted to HAP and not β-tricalcium phosphate (data not shown). This showed that dried samples were composed of HAP or carbonate apatite. The OH<sup>-</sup> band at 3570 cm<sup>-1</sup> was not present

Table 2. Ca:P molar ratios.

Case	Sex	Acute Cases		Sex	Chronic Cases	
		Age, yrs	Ca:P		Age, yrs	Ca:P
1	F	52	1.55	F	35	1.53
2	F	43	1.91	F	49	1.84
3	F	42	1.53	F	38	1.81
4	F	50	1.78	F	43	1.70
5	F	47	1.82	F	39	1.81
6	F	51	1.58	F	42	1.95
7	F	65	1.66	F	36	1.69
8	F	44	1.80	F	58	1.77
9	F	48	1.71	F	51	1.53
10	F	45	1.75	F	54	1.56
Average		48.3	1.71 ± 0.158		44.6	1.71 ± 0.158

in the Raman spectrum of any dried samples (Figure 2), showing that they did not consist of HAP. Moreover, the FTIR spectra of the dried samples had CO<sub>3</sub> group bands around 870, 1410, and 1450 cm<sup>-1</sup>. These data confirm that the dried samples from both acute and chronic cases were composed of carbonate apatite.

HAP, OCP, TCP, DCPD, and carbonate apatite have been identified as BCP crystals responsible for calcific periarthritis (Table 1)<sup>4,5</sup>. Our evidence that calcium deposits in both acute and chronic cases consist of carbonate apatite means that the different clinical courses of calcific periarthritis cannot be explained by differences in the composition of the BCP crystals.

It has been reported that the specific surface area (SSA), calculated as total surface area (m<sup>2</sup>) divided by weight (g)<sup>12</sup>, and Ca:P ratio of crystals influence the magnitude of BCP-induced inflammatory responses *in vivo*<sup>7</sup>. The greater the SSA, the more intense the inflammation, as indicated by the numbers of polymorphonuclear leukocytes. The SSA of BCP crystals is known to be proportional to the Ca:P ratio<sup>7,13</sup>, but whereas the BCP crystals produced from aqueous solution by Prudhommeaux, *et al*<sup>7</sup> consisted of single pure crystals (high crystallinity and similar sizes, identical chemical composition, and similar SSA), biological calcific deposits are composed of bulk-type crystals, varying in size, CO<sub>3</sub> content, and Ca:P ratio. It is not appropriate to use SSA to estimate the inflammatory potency of such crystals, because their surfaces are so irregular that it cannot accurately be determined. Therefore, we prefer to use Ca:P molar ratio as a marker of inflammatory potential of BCP crystals. We found no statistically significant difference in the Ca:P molar ratios of calcific deposits from acute and chronic cases, and thus the various clinical manifestations of inflammation in calcific periarthritis cannot be explained by either the composition of the BCP crystals present or their Ca:P molar ratios. Some other factor must therefore be postulated to explain the complexity of the clinical courses.

One possibility is that clinical course may depend on the

precise location of the calcific deposit, as suggested by Moseley<sup>3</sup> and DePalma<sup>14</sup>. Liquid calcific deposits in the acute cases in our study were located in the bursa, because they could be aspirated by syringe. On the other hand, we obtained solid intratendinous calcific deposits from chronic cases by surgery. Any increase in size of carbonate apatite crystals deposited in tendon will produce an elevation under the floor of the bursa, with subsequent clinical symptoms of bursitis with impingement against bone and ligament. Such symptoms are not due, therefore, to inflammation directly induced by crystals, but to mechanical stress. The carbonate apatite crystals finally rupture the tendon, are shed into the bursa, and eventually evoke acute inflammatory response.

We postulate another possibility, namely that serum plasma proteins, especially alpha 2-HS glycoprotein, inhibit the inflammatory response through their suppression of neutrophil stimulation<sup>15</sup>. This may modulate the inflammatory potential of carbonate apatite crystals, particularly intratendinous crystals in the silent phase.

There are 2 limitations to our study: first, sampling was restricted to the shoulder joint; and second, BCP crystals in synovial fluid were not examined. Using radiographic calcification as a marker of calcific periarthritis, most calcification occurs in the soft tissue of the shoulder, hip, elbow joint, and other joints. Calcifications around the shoulder joint constitute 79% of all such cases of soft tissue calcification<sup>16</sup>. On the basis of our experience, we speculate that calcific periarthritis in other joints may take the same clinical courses as in the shoulder joint. Apatite, OCP, and TCP have been identified in synovial fluid by FTIR<sup>17</sup>. We did not characterize BCP crystals in synovial fluid, and therefore further studies will be necessary to clarify the clinical course of the arthritis induced by BCP crystals.

Finally, our study showed that BCP crystals in calcific periarthritis of the shoulder joint are composed of carbonate apatite in both acute and chronic cases, and that the composition of BCP crystals and their Ca:P molar ratios do not determine the clinical course, even though the Ca:P molar ratios ranged from 1.53 to 1.95.

## REFERENCES

1. DePalma AF, Kruper JS. Long-term study of shoulder joints afflicted with and treated for calcific tendinitis. *Clin Orthop* 1961;20:61-72.
2. Uhthoff HK, Dervin GF, Loehr JF. Calcifying tendinitis. In: Rockwood CA Jr, Matsen FA, editors. *The shoulder*. 3rd ed. Philadelphia: Saunders; 2004:1033-58.
3. Moseley HF. Calcified deposits in the rotator cuff. In: Moseley HF, editor. *Shoulder lesions*. 3rd ed. London: E&S Livingstone Ltd.; 1969:99-118.
4. Halverson PB. Basic calcium phosphate (apatite, octacalcium phosphate, tricalcium phosphate) crystal deposition diseases and calcinosis. In: Koopman BC, Moreland LW, editors. *Arthritis and allied conditions*. 14th ed. Philadelphia: Lea and Febiger; 2004:2397-416.
5. Hamada J, Ono W, Tamai K, et al. Analysis of calcium deposits in calcific periarthritis. *J Rheumatol* 2001;28:809-13.
6. Maugars Y, Peru L, Berthelot JM, Delecrin J, Prost A, Daculsi G. Air pouch model in the rat for evaluating articular phlogogenic capacity of ceramics. *Chirurgie* 1994-95;120:88-93.
7. Prudhommeaux F, Schiltz C, Lioté F, et al. Variation in the inflammatory properties of basic calcium phosphate crystals according to crystal type. *Arthritis Rheum* 1996;39:1319-26.
8. Hamada J. Analysis of deposits in calcific periarthritis. *J Jpn Orthop Assoc* 1995;69:1158-69.
9. Doi Y, Moriwaki T, Aoba T, et al. ESR and IR studies of carbonate-containing hydroxyapatites. *Calcif Tissue Int* 1982;34:178-81.
10. Doi Y, Shibutani Y, Moriwaki Y, Kajimoto T, Iwayama Y. Sintered carbonate apatites as bioresorbable bone substitutes. *J Biomet Mater Res* 1998;39:603-10.
11. Posner AS, Stephenson AS. Crystallographic investigation of tricalcium phosphate hydrate. *J Dent Res* 1952;31:371-82.
12. Brunauer S, Emmett PH, Teller E. Absorption of gases in multimolecular layers. *Am Chem Soc* 1938;60:309-19.
13. Shimoda S, Aoba T, Moreno EC, et al. Effect of solution composition on morphological and structural features of carbonated calcium apatites. *J Dent Res* 1990;69:1731-40.
14. DePalma AF. Calcareous tendinitis. In: DePalma AF, editor. *Surgery of the shoulder*. 3rd ed. Philadelphia: J.B. Lippincott Co; 1983:277-85.
15. Terkeltaub RA, Santoro DA, Mandel G, et al. Serum and plasma inhibit neutrophil stimulation by hydroxyapatite crystals. Evidence that serum alpha 2-HS glycoprotein is a potent and specific crystal-bound inhibitor. *Arthritis Rheum* 1988;31:1081-9.
16. Sandstrom C. Peritendinitis calcarea: Common disease of middle life: Its diagnosis, pathology and treatment. *AJR Am J Roentogenol* 1938;40:1-21.
17. McCarty DJ, Lehr JR, Halverson PB. Crystal populations in human synovial fluid. Identification of apatite, octacalcium phosphate, tricalcium phosphate. *Arthritis Rheum* 1983;26:1220-4.