



INSTRUCTIONS FOR LETTERS TO THE EDITOR

Editorial comment in the form of a Letter to the Editor is invited. The length of a letter should not exceed 800 words, with a maximum of 10 references and no more than 2 figures or tables; and no subdivision for an abstract, methods, or results. Letters should have no more than 4 authors. Financial associations or other possible conflicts of interest should be disclosed.

Letters should be submitted via our online submission system, available at the Manuscript Central website: <http://mc.manuscriptcentral.com/jrheum> For additional information, contact the Managing Editor, The Journal of Rheumatology, E-mail: jrheum@jrheum.com

Bullous Pemphigoid in a Patient with Systemic Sclerosis (Scleroderma)

To the Editor:

A 65-year-old Caucasian man with scleroderma presented for evaluation of 6 months of intense pruritus and recurrent cutaneous ulcerations. He began to develop ulcerated lesions on both the upper and lower extremities thought to be secondary to self-inflicted trauma from scratching areas of dry thickened scleroderma skin. Several times, these lesions became secondarily infected and required topical and systemic antibiotic therapy. It was noted that the ulcers seemed to respond to topical application of triamcinolone 0.1% cream.

Examination on presentation revealed diffuse cutaneous sclerosis with taut scaly skin over the dorsum of the hands, face, arms, trunk, and legs. Superimposed on areas of scleroderma skin were multiple papules, becoming confluent in some areas. The papules were erythematous with fine overlying scale and areas of lichenification. Well demarcated punched-out ulcerations were also present, particularly over the lower extremities (Figure 1). Mucous membranes and conjunctivae were normal. No bullae were present on examination, but he reported previously noting thin blisters on his legs.

H&E staining of the biopsy specimen from the right shoulder revealed acute spongiotic dermatitis with focal substitutive collagenosis, consistent with nonspecific eczematous change superimposed on scleroderma. Direct immunofluorescence performed on the biopsy specimen showed heavy linear deposition of IgG and C3 along the basement membrane zone (Figure 2), a finding that is diagnostic for bullous pemphigoid. He was given mycophenolate mofetil 1 g PO bid, and the prednisone was increased to 50 mg PO qam for 4 weeks before being reduced back to 40 mg PO qd. He responded to this therapy with improved pruritus, healed ulcerations, and resolution of papules. He currently is doing well with inactive pemphigoid skin disease, taking mycophenolate mofetil 1 g PO bid and prednisone 5 mg PO qod.

Although a case of a 73-year-old woman with generalized morphea who developed bullous pemphigoid after receiving whole-body UVA-1 phototherapy is reported¹, the coexistent systemic sclerosis (scleroderma) with bullous pemphigoid is not described in the literature.

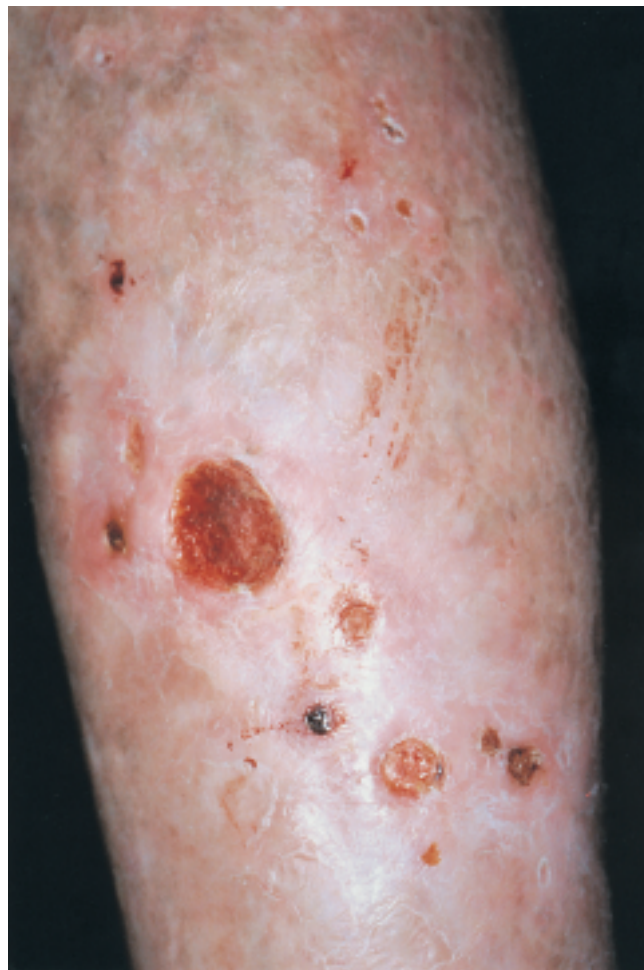

Figure 1. Bullous pemphigoid causing multiple ulcerations in the sclerotic skin on the extremity of a patient with scleroderma.

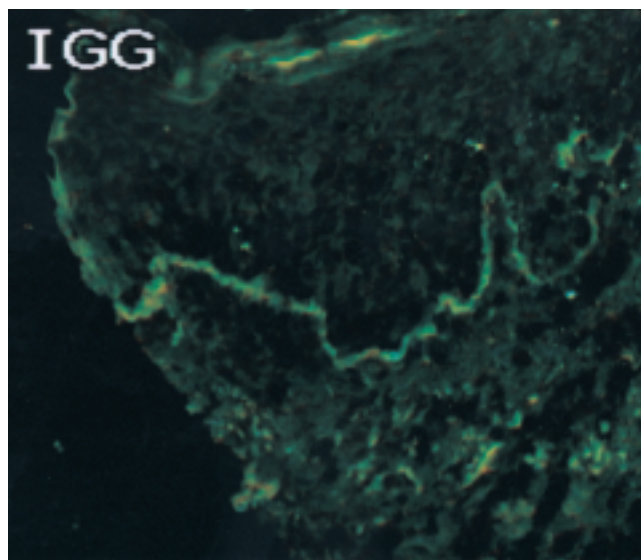


Figure 2. Direct immunofluorescence performed on the biopsy specimen showing heavy linear deposition of IgG and C3 along the basement membrane zone, a finding that is diagnostic for bullous pemphigoid.

Bullous pemphigoid is an autoimmune bullous skin disease affecting keratinocytes' adherence to each other and to the basement membrane. Autoimmune bullous diseases with blistering at the intraepidermal level are in the pemphigus group (pemphigus vulgaris, pemphigus foliaceus, and paraneoplastic pemphigus), while blistering occurring at the subepidermal level is classified as pemphigoid disease (bullous pemphigoid, gestational pemphigoid, and cicatricial pemphigoid). Bullous pemphigoid has primary cutaneous involvement, gestational pemphigoid (also known as herpes gestationis) has primary cutaneous involvement in pregnant women, while cicatricial pemphigoid has primary mucosal involvement².

Clinically, bullous pemphigoid presents with cutaneous lesions, with only rare mucosal involvement. Disease progression typically begins with urticarial plaques or papules, erythematous macules, or, as in our case, eczematous lesions, all of which are usually intensely pruritic³. Tense clear blisters then develop over an erythematous base, which may manifest as an extensive bullous eruption².

Direct immunofluorescence findings are diagnostic for bullous pemphigoid. On biopsy of normal-appearing skin adjacent to a lesion, direct immunofluorescence reveals deposition of IgG and C3 along the epidermal basement membrane zone. Deposition of C3 is characteristically more intense than that of IgG³. While direct immunofluorescence is 100% sensitive, indirect immunofluorescence is approximately 90% sensitive when salt-split human skin is used as a substrate for circulating bullous pemphigoid autoantibodies. These antibodies bind to the epidermal roof³. Biopsy histology shows epidermal blistering with prominent polymorphonuclear and eosinophilic infiltrates². Bullous pemphigoid is triggered by autoantibody formation against the BP180 antigen, also known as Type XVII collagen. BP180 antigen is a key component of epidermal hemidesmosomes, and is a transmembrane protein composed of a short non-collagenous ectodomain adjacent to the plasma membrane as well as a long collagenous endodomain that interacts with the basement membrane's anchoring proteins. Pathogenic autoantibodies in bullous pemphigoid recognize an immunodominant epitope in the ectodomain of BP180 antigen². Antibody activation against BP180 antigen leads to complement activation, resulting in neutrophil and eosinophil infiltration. Protease release from neutrophils is likely the critical step in subepidermal blister formation².

Prednisone has been a mainstay of treatment, with rapid effects seen at 0.5–1 mg/kg PO qd⁴. Antibiotic therapy can also have effective anti-inflammatory effects as part of a steroid-sparing strategy³. Newer data suggest that mycophenolate mofetil 1 g PO bid may be exceedingly useful in limiting steroid usage while inducing prompt and persistent remission of bullous pemphigoid⁵.

Diagnosis of blistering skin disease like bullous pemphigoid can be overlooked in patients with scleroderma because significant pruritus and ulcerations are commonly part of the scleroderma skin process. Our case demonstrates that bullous pemphigoid should be considered when evaluating scleroderma patients with diffuse papules, lichenified lesions, blistering, or ulcerations. It also illustrates the unique concurrence of 2 rare autoimmune diseases.

We describe a case of bullous pemphigoid in a man with systemic sclerosis (scleroderma) skin disease, who when diagnosed correctly responded to appropriate therapy.

NOELLE S. SHERBER, MD, Johns Hopkins University School of Medicine; FREDRICK M. WIGLEY, MD, Departments of Rheumatology and Medicine; GRANT J. ANHALT, MD, Departments of Dermatology and Pathology, Johns Hopkins Medical Institutions, Baltimore, Maryland, USA.

Address reprint requests to Dr. F. Wigley. E-mail: fwig@jhmi.edu

REFERENCES

1. Sacher C, König C, Scharffetter-Kochanek K, Krieg T, Hunzelmann N. Bullous pemphigoid in a patient treated with UVA-1 phototherapy for disseminated morphea. *Dermatology* 2001;202:54-7.

2. Nousari HC, Anhalt GJ. Pemphigus and bullous pemphigoid. *Lancet* 1999;354:667-72.
3. Mutasim DF, Anhalt GJ. Bullous diseases in the elderly. *Clin Geriatr Med* 2002;18:43-58.
4. Nousari HC, Griffin WA, Anhalt GJ. Successful therapy for bullous pemphigoid with mycophenolate mofetil. *J Am Acad Dermatol* 1998;39:497-8.
5. Nousari HC, Sragovich A, Kimyai-Asadi A, Orlinsky D, Anhalt GJ. Mycophenolate mofetil in autoimmune and inflammatory skin disorders. *J Am Acad Dermatol* 1999;40:265-8.

Intestinal Flora and Psoriatic Arthritis

To the Editor:

The editorial comment on "Psoriatic Disease"¹ and the importance of the gut reminded us of a noteworthy patient. A 52-year-old white woman had no psoriasis or psoriatic arthritis. She was hit by another car from the left while driving. In the emergency room computed tomography of the abdomen raised concern over splenic rupture. She was admitted and observed.

On the second hospital day our patient developed a *Streptococcus faecalis* positive bladder infection. By the fourth hospital day she had developed psoriasis and psoriatic arthritis.

Our observations support Dr. Scarpa's suggestion that the bowel is important² possibly as a site for streptococcal immune activation. In the same issue of *The Journal*, Madland, *et al*³ reported improved global assessment after patients with psoriatic arthritis ingested seal oil³. Could Madland, *et al* speculate on the influence of seal or fish oil on the bacterial content of the stool? They refer to a report showing the benefit of fish oil in patients with inflammatory bowel disease. Data suggest that fish oil can alter intestinal microflora in mice⁴. Could this explain the positive effect of seal oil in their patients?

FRANK B. VASEY, MD, Professor; JOHN D. CARTER, MD, Assistant Professor; Department of Internal Medicine, Division of Rheumatology, University of South Florida, Tampa, FL, USA.
Email: jdcarter@hsc.usf.edu

REFERENCES

1. Scarpa R, Ayala F, Caporaso N, Olivieri I. Psoriasis, psoriatic arthritis, or psoriatic disease? [editorial]. *J Rheumatol* 2006; 33:210-2.
2. Scarpa R, Manguso F, D'Arienzo A, et al. Microscopic inflammatory changes in colon of patients with both active psoriasis and psoriatic arthritis without bowel symptoms. *J Rheumatol* 2000;27:1241-6.
3. Madland TM, Bjorkkjaer T, Brunborg LA, et al. Subjective improvement in patients with psoriatic arthritis after short-term oral treatment with seal oil. A pilot study with double blind comparison to soy oil. *J Rheumatol* 2006;33:307-10.
4. Kuda T, Enomoto T, Yano T, Fujii T. Cecal environment and TBARS level in mice fed corn oil, beef tallow and menhaden fish oil. *J Nutr Sci Vitaminol Tokyo* 2000;46:65-70.

Hypothyroidism and Antithyroglobulin and Antithyroperoxidase Antibodies in the Pathogenesis of Autoimmune Associated Congenital Heart Block

To the Editor:

Neonatal lupus (NL) is a model of passively acquired autoimmunity, in which disease in an offspring likely represents insult to fetal tissue follow-

ing transplacental passage of maternal autoantibodies. The 2 most common manifestations of NL are congenital heart block (CHB), which is rarely if ever reversible, and rash, which disappears coincident with the clearance of maternal antibodies from the neonatal circulation. While antibodies reactive with components of the Ro/SSA-La/SSB system are highly associated with NL, only a fraction of all fetuses exposed to these maternal antibodies develop disease¹. This observation strongly suggests that additional factors, such as another maternal autoantibody or a fetal component, are required.

It has recently been reported that hypothyroidism in mothers with anti-Ro/SSA and/or anti-La/SSB antibodies increases by 9-fold the risk for delivering a child with CHB compared to women with these same antibodies who have normal thyroid function². Hypothyroidism is often the result of chronic autoimmune (Hashimoto's) thyroiditis, and is characterized by high serum concentrations of antibodies to thyroglobulin (TG; 80%–90%) and thyroperoxidase (TPO; 90%–100%). These antibodies are also found, in lower concentration, in patients with other thyroid diseases and in healthy persons. In otherwise healthy individuals, anti-TPO and anti-TG antibodies are detected in roughly 11% and 10% of the population, respectively. The percentage of positive individuals increases with age, and females are more likely than males to synthesize these antibodies³. Since many mothers of children with NL have or eventually develop symptoms of Sjögren's syndrome (SS), it is relevant that the reported prevalence of these antithyroid antibodies in patients with SS is 17.5% for anti-TG and 25.5% for anti-TPO⁴.

These observations provided the rationale to evaluate the role of hypothyroidism and/or associated autoantibodies in the pathogenesis of NL. Accordingly, we examined the prevalence of hypothyroidism (by review of medical records) and anti-TG and anti-TPO antibodies in mothers enrolled in the Research Registry for Neonatal Lupus (established at our institution in 1994⁵). Sixty-nine sera were available from the Registry specimen bank. Of these 69 patients, 18 were asymptomatic and 51 had a variety of autoimmune diseases including undifferentiated autoimmune syndrome, systemic lupus erythematosus, and/or primary or secondary SS.

Following approval by the Registry external review/advisory committee, these sera were tested for the presence of anti-TG and anti-TPO antibodies using a commercial ELISA (Kronus Kalibre ELISA; Kronus, Boise, ID, USA) following the manufacturer's instructions. Positivity for anti-Tg antibodies was defined as > 3 Kronus Units/ml, corresponding to an optical density (OD) of 0.175 (negative control OD = 0.006, positive control OD = 1.30). Positivity for anti-TPO antibodies was defined as > 2 Kronus Units/ml, corresponding to an OD of 0.340 (negative control OD = 0.101, positive control OD = 1.268).

In total, 23 (33.3%) mothers of children with NL had anti-TG antibodies, and 15 (21.7%) had anti-TPO antibodies. These numbers are higher than in the general population, and slightly higher than expected in an autoimmune population for anti-TG antibodies (Table 1).

A search of maternal questionnaires for the key words hypothyroidism,

thyroiditis, and Synthroid identified 6 mothers of children with NL who had a history of hypothyroidism. Subsequently, we reviewed medical records of another 61 mothers for evidence of thyroid abnormalities. The total number of maternal cases of thyroid disease in the Registry population is 11 (9 hypothyroidism, likely due to Hashimoto's thyroiditis, and 2 hyperthyroidism). In the Registry population there are 2 children with hypothyroidism diagnosed at an early age (6–7 years), both born to mothers with high-titer antithyroid antibodies.

These data suggest that mothers of children with NL (who by definition have anti-Ro/SSA and/or anti-La/SSB antibodies) are more likely to have anti-TG antibodies than women with primary SS and historical healthy controls, anti-TG antibodies being present in one-third of the mothers tested. In the search for other factors responsible for NL, anti-TG antibodies, while not present in 100% of these sera, might be another contributing factor, the pathologic mechanism of which is not evident. Although the prevalence of anti-TG antibodies was higher in the Registry mothers, a history of clinical hypothyroidism was not increased in these women, as compared to a cohort of patients with primary SS⁴.

ANCA DINU ASKANASE, MD, MPH; IJEOMA ILOH, MS; JILL P. BUYON, MD, Department of Medicine, Division of Rheumatology, Hospital for Joint Diseases, New York University School of Medicine, New York, NY 10016, USA. E-mail: jill.buyon@nyumc.org

Patients and serum samples were obtained through the Research Registry for Neonatal Lupus, funded by US National Institutes of Health contract no. AR4-2271 to J.P. Buyon.

REFERENCES

1. Brucato A, Frassi M, Franceschini F, et al. Risk of congenital complete heart block in newborns of mothers with anti-Ro/SSA antibodies detected by counterimmunoelectrophoresis: a prospective study of 100 women. *Arthritis Rheum* 2001;44:1832-5.
2. Spence D, Hornberger L, Hamilton R, Silverman ED. Increased risk of complete congenital heart block in infants born to women with hypothyroidism and anti-Ro and/or anti-La antibodies. *J Rheumatol* 2006;33:167-70. E-pub ahead of print.
3. Hollowell JG, Staehling NW, Flanders WD, et al. Serum TSH, T4, and thyroid antibodies in the United States population (1988 to 1994): National Health and Nutrition Examination Survey (NHANES III). *J Clin Endocrinol Metab* 2002;87:489-99.
4. D'Arbonneau F, Ansart S, Le Berre R, Dueymes M, Youinou P, Pennec Y-L. Thyroid dysfunction in primary Sjögren's syndrome: A long-term followup study. *Arthritis Rheum* 2003;49:804-9.
5. Buyon JP, Hiebert R, Copel J, et al. Autoimmune-associated congenital heart block: demographics, mortality, morbidity and recurrence rates obtained from a national neonatal lupus registry. *J Am Coll Cardiol* 1998;31:1658-66.

Table 1. Antithyroid antibodies in patients with primary SS (Sjögren's syndrome), mothers of children with NL (neonatal lupus), and mothers of children with CHB (congenital heart block).

Patients	Anti-TPO Antibodies, No. Positive (%)	Anti-TG Antibodies, No. Positive (%)	Hypothyroidism, No. Positive (%)
Primary SS, N = 137*	35 (25.5)*	24 (17.5)*	20 (14.6)*
NL mothers, N = 69	15 (21.7)	23 (33.3)	9 (13.0)
CHB mothers, N = 54	14 (25.9)	20 (37.0)	5 (9.3)
p values (NL/CHB mothers vs primary SS patients)	NS	<0.05	NS

* Cohort of patients with primary SS⁴. TPO: thyroperoxidase, TG: thyroglobulin.

Book review

Fibromyalgia and Other Central Pain Syndromes

Daniel J. Wallace and Daniel J. Clauw. Philadelphia: Lippincott Williams & Wilkins, 2005. 432 pages, price \$79.95 US.

This is an excellent and comprehensive outline of current knowledge and understanding of fibromyalgia and other central pain syndromes. There are 43 contributors, most of them leading experts and investigators in this area.

The discussions deal with various features of fibromyalgia including myofascial pain, sleep abnormalities, and psychological factors. Other related syndromes such as chronic fatigue syndrome, functional bowel disease, and genitourinary associations are discussed. A number of chapters deal with underlying biological disturbances. Other topics include approaches to management as well as disability.

Overall, this is an outstanding up to date outline of current knowledge and understanding of fibromyalgia and other central pain syndromes that we commonly encounter in rheumatological practice.

W.J. Reynolds, MD, FRCPC, Rheumatologist, University Health Network, Associate Professor of Medicine, University of Toronto, Toronto, Ontario, Canada.

Correction

Yamamoto T, Schneider R, Iwamoto Y, Bullough PG. Rapid destruction of the femoral head after a single intraarticular injection of corticosteroid into the hip joint. *J Rheumatol* 2006;33:1701-4.

Table 1, which summarizes the present and previously described cases, was omitted from the report; it is presented below. We regret the error.

Table 1. Summary of cases of osteonecrosis after intraarticular injection of corticosteroids.

Reference	Patient Age & Gender	Drug	Dose, mg × No. (total)	Injection Site	Period*, mo	ON	Histology	Outcome
6	42 F	Triamcinolone	40 × 2 (80)	Bilateral shoulder	6	Bilateral hips	Biopsy (ON)	NA
	78 F (RA**)	Triamcinolone	40 × 8 (740)***	Shoulder, knee, ankle	5	Bilateral hips & shoulders	Done (L FH:ON)	L THA
7	67 F	Triamcinolone	40 × 6 (408)****	Bilateral knee	13	Bilateral femoral condyles & tibial plateau	NA	NA
Present report	50 F	Methylprednisolone	80 × 1 (80)	L hip	3	L hip	Done (ON)	Rapid collapse & THA

* From the first corticosteroid injection until the radiographic confirmation of osteonecrosis. ** History of seronegative rheumatoid arthritis. *** Oral prednisone (420 mg) was also taken. **** Oral prednisone (168 mg) was also taken. No.: Number of injections; ON: osteonecrosis; L: left; THA: total hip arthroplasty; FH: femoral head; NA: not available.