

Correspondence



INSTRUCTIONS FOR LETTERS TO THE EDITOR

Editorial comment in the form of a Letter to the Editor is invited. The length of a letter should not exceed 800 words, with a maximum of 10 references and no more than 2 figures or tables; and no subdivision for an abstract, methods, or results. Letters should have no more than 4 authors. Financial associations or other possible conflicts of interest should be disclosed.

Letters should be submitted via our online submission system, available at the Manuscript Central website: <http://mc.manuscriptcentral.com/jrheum> For additional information, contact the Managing Editor, The Journal of Rheumatology, E-mail: jrheum@jrheum.com

Prasterone and Bone Mineral Density in Women with Systemic Lupus Erythematosus

To the Editor:

We read with interest the report by Mease, *et al* describing improved bone mineral density (BMD) in glucocorticoid-treated women with systemic lupus erythematosus, after prasterone (DHEA) therapy at 200 mg/day for one year¹. Readers should be aware that DHEA doses of 200 mg/day are clearly supraphysiological. Based on our own clinical and laboratory experience with DHEA therapy, and the scientific literature, doses of DHEA greater than 50 mg/day almost always result in urinary DHEA and DHEA metabolite (androsterone and etiocholanolone) concentrations that are higher than those measured in healthy young adults.

Callies, *et al* reported that when DHEA 50 mg/day was given to elderly men and women, urinary excretions of DHEA and metabolites were slightly higher than in healthy young adults, while DHEA 100 mg/day resulted in clearly supraphysiological values². A study of the effects of DHEA on prednisone pharmacokinetics and cortisol suppression in healthy women reported that serum DHEA and DHEA-S were significantly greater than endogenous levels at a dose of 200 mg/day³. The risk of adverse effects increases with increasing DHEA dose⁴.

In our experience, women receiving DHEA doses of 100 mg/day or higher often have elevated testosterone concentrations in serum and urine, and prominent androgenic side effects.

Some patients may need supraphysiological doses of DHEA. In these cases, monitoring of DHEA and its metabolites would be prudent. Improved BMD in older women after DHEA 50 mg/day has been reported in one study⁵. Followup studies comparing 50 mg doses of DHEA to the 200 mg dose should be undertaken to evaluate effects on bone density. In any case, based on our experience with thousands of patients receiving DHEA therapy, we recommend laboratory testing for any patient taking 25 mg/day or more. Twenty-four hour urinary steroid hormone profiling may be especially helpful, because it allows determination of DHEA and several downstream metabolites, including androsterone, etiocholanolone, estradiol, estrone, and testosterone.

THOMAS ALEXANDER, MD; PATRICK N. FRIEL, BS; JONATHAN V. WRIGHT, MD, The Tahoma Clinic and Meridian Valley Laboratory, 801 SW 16th Street, Suite 121, Renton, Washington 98055, USA. E-mail: steroids@meridianvalleylab.com

REFERENCES

1. Mease PJ, Ginzler EM, Gluck OS, et al. Effects of prasterone on bone mineral density in women with systemic lupus erythematosus receiving chronic glucocorticoid therapy. *J Rheumatol* 2005;32:616-21.
2. Callies F, Arlt W, Siekmann L, Hubler D, Bidlingmaier F, Allolio B. Influence of oral dehydroepiandrosterone (DHEA) on urinary steroid metabolites in males and females. *Steroids* 2000;65:98-102.
3. Meno-Tetang GM, Blum RA, Schwartz KE, Jusko WJ. Effects of oral prasterone (dehydroepiandrosterone) on single-dose pharmacokinetics of oral prednisone and cortisol suppression in normal women. *J Clin Pharmacol* 2001;41:1195-205.
4. Dhataria KK, Nair KS. Dehydroepiandrosterone: is there a role for replacement? *Mayo Clin Proc* 2003;78:1257-73.
5. Baulieu EE, Thomas G, Legrain S, et al. Dehydroepiandrosterone (DHEA), DHEA sulfate, and aging: contribution of the DHEAge Study to a sociobiomedical issue. *Proc Natl Acad Sci USA* 2000;97:4279-84.

Dr. Mease and Dr. Schwartz reply

To the Editor:

Alexander and colleagues have inquired about the rationale for the 200 mg/day dose of prasterone used in our recent study¹. Our study assessing bone mineral density (BMD) was nested within a larger 381 patient study designed to assess effects of prasterone on overall lupus disease². Women with active systemic lupus erythematosus have low circulating levels of DHEA-S, which are suppressed even further by treatment with exogenous glucocorticoids^{3,4}. The dose of prasterone, 200 mg/day, was intended to be a pharmacologic rather than a replacement dose and was based partly on earlier Stanford reports^{5,6} as well as our own experience with 100 mg/day in a steroid-sparing study, in which a dose response was observed between placebo and 100 and 200 mg prasterone per day⁷.

Acne and hirsutism have been the principal androgenic side effects observed; most reported side effects have been mild and have not led to withdrawal from treatment².

Alexander, *et al* cite a French study that assessed changes in bone mineral density (BMD) in normal, healthy men and women aged 60–79 years who received 50 mg/day prasterone or placebo for up to one year⁸. No effects on BMD were observed in men; in women, a positive effect on BMD was observed, mostly in trabecular bone zones. However, few of the multiple comparisons reported were statistically significant, and none of the comparisons for change in BMD at the total hip was significant. Further, they did not report BMD in the lumbar spine and, importantly, these were not patients receiving glucocorticoids.

The metabolism of prasterone is complex, with both downstream androgenic and estrogenic metabolites. Additionally, prasterone may also have direct actions that do not require conversion to downstream androgens or estrogenic metabolites^{9–11}. While measurement of various downstream metabolites is of interest, we believe the most important measurements remain those of serum testosterone, estradiol, and DHEA/DHEA-S.

Finally, it should be noted that prasterone is an investigational agent, currently in testing as a treatment for lupus. There are currently no US Food and Drug Administration-approved indications for its use.

PHILIP J. MEASE, MD; KENNETH E. SCHWARTZ, MD, Seattle Rheumatology Associates, 10th floor, 1101 Madison Street, Seattle, Washington 98104, USA. E-mail: pmease@nwlink.com

REFERENCES

1. Mease PJ, Ginzler EM, Gluck OS, et al. Effects of prasterone on bone mineral density in women with systemic lupus erythematosus receiving chronic glucocorticoid therapy. *J Rheumatol* 2005;32:616-21.
2. Petri MA, Mease PJ, Merrill JT, et al. Effects of prasterone on disease activity and symptoms in women with active systemic lupus erythematosus. *Arthritis Rheum* 2004;50:2858-68.
3. Lahita RG, Bradlow HL, Ginzler E, Pang S, New M. Low plasma androgens in women with systemic lupus erythematosus. *Arthritis Rheum* 1987;30:241-8.
4. Hedman M, Nilsson E, de la Torre B. Low sulpho-conjugated steroid hormone levels in systemic lupus erythematosus (SLE). *Clin Exp Rheumatol* 1989;7:583-8.
5. van Vollenhoven RF, Engleman EG, McGuire JL. Dehydroepiandrosterone in systemic lupus erythematosus. Results of a double-blind, placebo-controlled, randomized clinical trial. *Arthritis Rheum* 1995;38:1826-31.
6. Barry NN, McGuire JL, van Vollenhoven RF. Dehydroepiandrosterone in systemic lupus erythematosus: relationship between dosage, serum levels, and clinical response. *J Rheumatol* 1998;25:2352-6.
7. Petri MA, Lahita RG, Van Vollenhoven RF, et al. Effects of prasterone on corticosteroid requirements of women with systemic lupus erythematosus: a double-blind, randomized, placebo-controlled trial. *Arthritis Rheum* 2002;46:1820-9.
8. Baulieu EE, Thomas G, Legrain S, et al. Dehydroepiandrosterone (DHEA), DHEA sulfate, and aging: contribution of the DHEAge Study to a sociobiomedical issue. *Proc Natl Acad Sci USA* 2000;97:4279-84.
9. Liu D, Dillon JS. Dehydroepiandrosterone activates endothelial cell nitric-oxide synthase by a specific plasma membrane receptor coupled to G alpha (i2,3). *J Biol Chem* 2002;277:21379-88.
10. Simoncini T, Mannella P, Fornari L, Varone G, Caruso A, Genazzani AR. Dehydroepiandrosterone modulates endothelial nitric oxide synthesis via direct genomic and nongenomic mechanisms. *Endocrinology* 2003;144:3449-55.
11. Williams MR, Dawood T, Ling S, et al. Dehydroepiandrosterone increases endothelial cell proliferation in vitro and improves endothelial function in vivo by mechanisms independent of androgen and estrogen receptors. *J Clin Endocrinol Metab* 2004;89:4708-15.

Bilateral Ocular Myositis as a Late Complication of Dermatomyositis

To the Editor:

It was with great interest that I read the article by Kokotis, *et al* describing a patient with bilateral ocular myositis that was, according to the authors, a late complication of dermatomyositis (DM)¹. The article is of interest because extraocular muscles are considered to be spared in idiopathic inflammatory myopathies². The occurrence of diplopia or ophthalmoplegia in a patient diagnosed with an idiopathic inflammatory myopathy is therefore seen as being indicative of another coincidental disease, usually myasthenia gravis or Graves' disease. There are several items of concern with regard to their case presentation that need to be addressed.

First, the authors do not provide evidence that the patient has suffered from DM. The non-itching erythema for 7 years prior to occurrence of ophthalmologic symptoms is by no means typical for DM. Further, a history of "symmetrical weakness of limb-girdle muscles..., which had resolved with brief oral prednisone" is not evidence of an inflammatory myopathy without providing information on levels of serum creatine kinase, electromyographic studies performed at that time, and histological evidence of an

inflammatory myopathy. The authors state that the diagnosis of definite DM was established based on the information referred to above. They support their statement by referring to 2 book chapters instead of referring to established diagnostic criteria^{3,4}.

Second, the authors do not provide solid evidence that the patient had orbital myositis. Their patient had eyelid edema, erythema, and orbital pain. Physical examination revealed proptosis and exophthalmus. Orbital myositis almost always leads to diplopia and/or ophthalmoplegia⁵. Their patient had neither. Other causes of the ophthalmologic signs and symptoms were excluded, with the exception of the main differential diagnosis: Graves' disease. No information is provided on thyroid function. The fact that magnetic resonance imaging showed enlargement of several eye muscles is not discriminative between orbital myositis and Graves' disease⁶. The MR images accompanying the article reveal smooth, enlarged muscles. It has been shown that smooth enlargement of eye muscles is more suggestive of Graves' disease, whereas irregular enlargement is more indicative of ocular myositis⁶. It would also be of interest to know whether the tendons were involved or just the muscle bellies (the latter being more indicative of Graves' disease)⁶.

Based on the information that the authors provide of their case, it cannot be concluded that the patient suffered from DM and ocular myositis. It can therefore be stated that the general rule mentioned earlier (that the occurrence of diplopia or ophthalmoplegia in a patient diagnosed with an idiopathic inflammatory myopathy is indicative of another coincidental disease) is still valid.

GERALD J.D. HENGSTMAN, MD, Neuromuscular Centre Nijmegen, Department of Neurology, Radboud University Nijmegen Medical Centre, PO Box 9101, 6500 HB Nijmegen, The Netherlands.
E-mail: g.hengstman@neuro.umcn.nl

REFERENCES

1. Kokotis P, Theodossiadis P, Bouros C, Sfikakis PP. Bilateral ocular myositis as a late complication of dermatomyositis. *J Rheumatol* 2005;32:379-81.
2. Dalakas MC. Polymyositis, dermatomyositis, and inclusion-body myositis. *N Engl J Med* 1991;325:1487-98.
3. Olsen JN, Wortmann LR. Inflammatory and metabolic disease of muscle. In: Klippel HJ, editor. *Primer on the rheumatic diseases*. Atlanta: The Arthritis Foundation; 1998:276-82.
4. Medsger TA, Oddis VC. Inflammatory muscle disease: clinical features. In: Klippel HJ, Dieppe AP, editors. *Rheumatology*. New York: Mosby; 1998:345-57.
5. Mannor GE, Rose GE, Moseley IF, Wright JE. Outcome of orbital myositis: clinical features associated with recurrence. *Ophthalmology* 1997;104:409-14.
6. Lacey B, Chang W, Rootman J. Nonthyroid causes of extraocular muscle disease. *Surv Ophthalmol* 1999;44:187-213.

To the Editor:

The recent report by Kokotis, *et al*¹, who describe bilateral ocular myositis occurring in a patient several years after dermatomyositis (DM), prompted us to report the following case.

A 71-year-old woman presented in December 1999 with a 3-month history of proptosis, initially unilateral but rapidly involving both eyes. Ten years earlier she developed muscular fatigue and weakness of upper and lower limbs, and an inflammatory myopathy was diagnosed by muscle biopsy. She was started on steroids, which were withdrawn after several months for severe osteoporosis; a subsequent course of cyclophosphamide was spontaneously discontinued because of well being. In June 1999, she was found to have atrial fibrillation and systemic arterial hypertension and was given digoxin, diuretics, and angiotensin-converting enzyme inhibitors. On admission, physical examination was unremarkable, except for bilateral proptosis and exophthalmus; blood pressure was normal, atrial

fibrillation was present with heart rate of 80/min. Laboratory evaluation showed antinuclear antibodies (ANA, 1:640, homogeneous pattern), but no other autoantibodies (anti-DNA, antiextractable nuclear antigen, antineutrophil cytoplasmic antibodies, anticardiolipin, and rheumatoid factor). The other laboratory data were normal, including creatine phosphokinase, C-reactive protein, complement, and thyroid function tests.

Orbital magnetic resonance imaging (MRI) was consistent with inflammatory myopathy of extrinsic ocular muscles. Electromyography (EMG) of arm and leg muscles showed mild involvement confined to deltoid. She refused azathioprine and began methotrexate (MTX), 7.5 mg once a week, with a slow but significant improvement. Orbital MRI was unchanged in June 2000, but by December 2000 did not show any myopathy, even though a mild exophthalmus persisted. MTX was progressively reduced and discontinued. When last seen (March 2004), she was in good health.

As far as we know, this is the second case of bilateral orbital myositis in patients with systemic inflammatory myopathy. Interestingly, our patient, like the patient described by Kokotis, *et al*¹, developed orbital myositis several years after systemic muscle involvement, with no other symptoms than proptosis and exophthalmus, and with normal circulating muscle enzymes (Kokotis's patient reported erythema on the back and eyelid). Several cases of orbital myositis have been reported in association with autoimmune rheumatic diseases²⁻⁴, however, although our patient had antinuclear antibodies, since there were no symptoms/signs suggesting other rheumatic diseases, since mild signs of myopathy were indeed recorded on EMG, and because of the previous biopsy-based diagnosis of inflammatory polymyositis, we conclude that our patient had bilateral ocular myositis as a late complication of polymyositis.

Another interesting feature that seemed to emerge in both patients was good response to low dose MTX. Our patient was started on MTX, having refused azathioprine and because steroids were contraindicated for severe osteoporosis. Kokotis's patient did not benefit from azathioprine or intravenous immunoglobulin, but did improve with MTX. Poor response to steroids has been recently reported in a child with idiopathic orbital myositis⁵.

In accord with Kokotis, *et al*¹, we conclude that ocular myositis is probably less rare than previously thought and suggest the usefulness of low dose MTX.

BIANCA MARASINI, MD, Department of Medicine, Surgery and Dentistry, Rheumatology Unit, Istituto Clinico Humanitas, University of Milan; ROBERTA COSSUTTA, MD, Rheumatology Unit, Istituto Clinico Humanitas; MARCO MASSAROTTI, MD, Rheumatology Unit, Istituto Clinico Humanitas, Milan, Italy.

Address reprint requests to Dr. B. Marasini, Istituto Clinico Humanitas, Via Manzoni 56, 20089 Rozzano, Milan, Italy

REFERENCES

1. Kokotis P, Theodossiadis P, Kouros C, Sfikakis PP. Bilateral ocular myositis as a late complication of dermatomyositis. *J Rheumatol* 2005;32:379-81.
2. Billing K, Malhotra R, Selva D, Dodd T. Orbital myositis in Churg-Strauss syndrome. *Acta Ophthalmol* 2004;122:393-6.
3. Younes M, Bejia I, Moussa A, et al. Oculomotor muscle involvement revealing dermatomyositis in a patient with rheumatoid arthritis. *Rev Med Interne* 2004;25:829-32.
4. Tsironi E, Eftaxias B, Karabatsas CH, Ioachim E, Kalogeropoulos C, Psilas K. An unusually longstanding, strictly ocular, limited form of Wegener's granulomatosis. *Acta Ophthalmol* 2005; 83:123-5.
5. Hattori H, Ohnishi S, Nakagawa Y, et al. An infant with idiopathic orbital myositis poorly responsive to steroid therapy: a case report. *Brain Dev* 2005;27:160-2.

Dr. Kokotis replies

To the Editor:

We thank Dr. Hengstman for his comments on our article. Our patient pre-

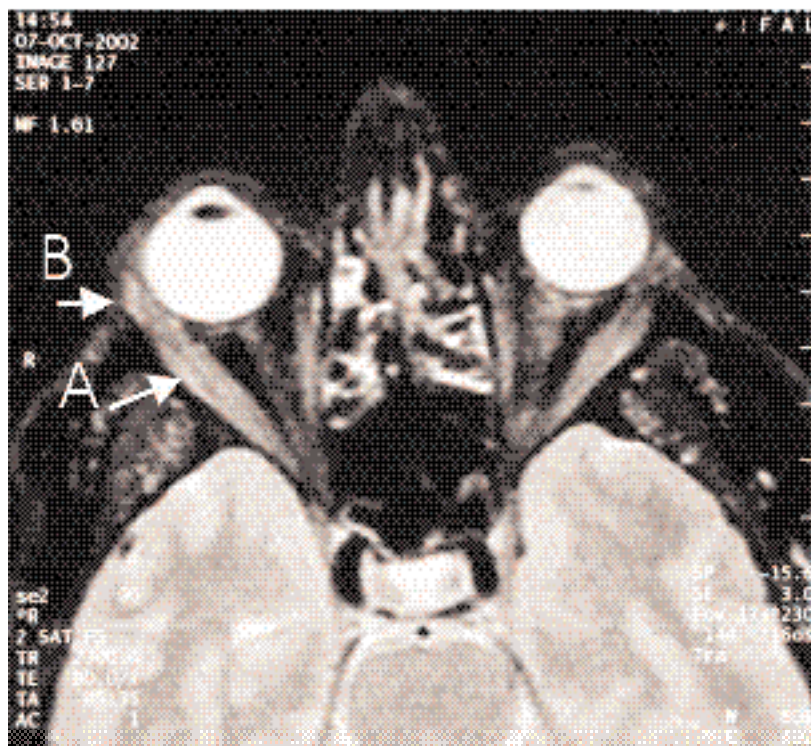


Figure 1. Orbital MRI (T1 sequence) showing enlargement of the muscle bellies (arrow A), as well of the tendons of the orbital muscles (arrow B) in a patient who developed bilateral ocular myositis as a late complication of dermatomyositis.

sented with typical red-purple edematous erythema on the upper palpebra (skin lesion), he had myopathic-like changes on electromyography and pathologic findings compatible with inflammatory myositis in muscle biopsy, and had experienced proximal muscle weakness in the past that resolved with prednisone treatment. Therefore, he met the classification criteria for dermatomyositis (DM) according to Tanimoto, *et al*¹, as well as the proposed revised classification criteria for idiopathic inflammatory myopathies by Targoff, *et al*². Serum creatine kinase or aldolase levels were not measured at the time when proximal muscle weakness was clinically evident. Clearly this is not a case of severe DM, but, as we have stated, represents a mild disease form that was untreated for years. Further, the presence of orbital myositis is fully supported by his clinical condition, i.e., the presence of erythema, eyelid edema, and orbital pain, as well as by magnetic resonance image (MRI) findings. The absence of diplopia or ophthalmoplegia, which were also not present in 15% of the 52 patients with orbital myositis reviewed by Berkhoff, *et al*³, does not exclude this diagnosis. Indeed, Siatkowski, *et al*⁴ observed normal function of the affected muscles in 34 of 74 patients (45%) with idiopathic orbital myositis.

Unintentionally, we failed to mention that ophthalmopathy associated with Graves' disease was excluded on the basis of normal thyroid function and thyroid autoantibody profile, including thyrotropin receptor antibodies⁵. Further, the MRI findings (Figure 1) disclosed not only involvement of the muscle bellies, but also enlargement of the tendons of the orbital muscles. MRI measurements of orbital tissues in thyroid-associated ophthalmopathy have shown that tendons are not affected in patients with Graves' disease⁶.

Dr. Marasini and her colleagues report a second case of bilateral ocular myositis that developed 10 years after initial diagnosis of inflammatory myopathy. Their case has striking similarities to our patient, including normal levels of serum muscle enzymes and thyroid function, no diplopia or ophthalmoplegia, and a beneficial response to treatment with methotrexate.

To conclude, although we agree that the occurrence of diplopia or ophthalmoplegia in a patient diagnosed with polymyositis or DM requires a thorough differential diagnosis to exclude coincidental disease, we feel that our case report as well as the second patient described by Marasini, *et al* indicate that ocular myositis should not be overlooked in patients with DM.

PANAGIOTIS KOKOTIS, MD, Department of Neurology; PETROS P. SFIKAKIS, MD, First Department of Propedeutic Medicine, Athens University Medical School, Athens, Greece.

REFERENCES

1. Tanimoto K, Nakano K, Kano S, et al. Classification criteria for polymyositis and dermatomyositis. *J Rheumatol* 1995;22:668-74.
2. Targoff NI, Miller WF, Medsger AT, Oddis VC. Classification criteria for the idiopathic inflammatory myopathies. *Curr Opin Rheumatol* 1997;9:527-35.
3. Berkhoff M, Sturzenegger M, Schroth G, Hess WC. Ocular myositis. *Nervenarzt* 1997;68:792-800.
4. Siatkowski RM, Capo H, Byrne SF, et al. Clinical and echographic findings in idiopathic orbital myositis. *Am J Ophthalmol* 1994;118:343-50.
5. Khoo DH, Eng PH, Ho SC, et al. Graves' ophthalmopathy in the absence of elevated free thyroxine and triiodothyronine levels: prevalence, natural history, and thyrotropin receptor antibody levels. *Thyroid* 2000;10:1093-100.
6. Nishida Y, Tian S, Isberg B, Tallstedt L, Lennerstrand G. MRI measurements of orbital tissues in dysthyroid ophthalmopathy. *Graefes Arch Clin Exp Ophthalmol* 2001;239:824-31.



Bacillus Calmette-Guérin Vaccination in a Patient Treated with Infliximab

To the Editor:

Anti-tumor necrosis factor- α (TNF- α) agents have come into widespread use, and adverse events such as infections are well described complications¹. The infection of greatest concern is tuberculosis (TB)^{2,3}. Patients receiving TNF- α blockers should not be given a live attenuated vaccine such as bacillus Calmette-Guérin (BCG). The risk of developing BCG related adverse reactions among anti-TNF- α treated patients is not known. We describe a case of BCG vaccination in a patient with rheumatoid arthritis (RA) treated with infliximab.

For 5 years, a 24-year-old woman suffered from symmetrical polyarthritis diagnosed as rheumatoid factor-positive RA. She had no other pertinent medical history. She had had BCG vaccination in her infancy. Since the polyarthritis was not controlled by methotrexate 10 mg weekly and prednisolone 10 mg daily, and she rapidly developed hand joint erosions with significant functional disability, therapy with infliximab (3 mg/kg) was introduced in March 2001, producing a prompt and dramatic improvement. The Disease Activity Score (DAS28) decreased from 4.69 to 2.45 after 3 infliximab infusions. A chest radiograph at that time was normal. No tuberculin skin test was performed. Infliximab was maintained while corticosteroids were progressively tapered to 4 mg prednisolone. Between 2001 and 2004, she received infliximab every 8 weeks, with no adverse events.

A tuberculin skin test was performed by her general practitioner (GP) as a requirement for entrance into nursing school. The skin test was negative. The GP decided to revaccinate the patient with BCG without informing our department. The vaccine (Monovax, Aventis Pasteur, Lyon, France) was administered intradermally in the deltoid region of the left arm August 9, 2004, a few days after her last infliximab infusion. Infliximab treatment was withdrawn and she was seen 3 weeks after vaccination, at which time she had not developed any local reaction and had no fever, asthenia, or cough. On examination, there was no axillary lymphadenitis and the lungs showed no abnormalities. The chest radiograph was still normal and sputum cultures were negative. An anti-tuberculosis treatment (isoniazid 4 mg/kg) was given for 2 months. Nine months after vaccination, she was still asymptomatic with no local reaction, axillary adenitis, fever, or pulmonary symptoms.

BCG is a live attenuated vaccine derived from multiple passages of the wild-type *Mycobacterium bovis*. It is used worldwide for TB prevention and is considered to have an excellent safety profile. Adverse events are rare and include local reactions, lymphadenitis, and disseminated disease^{4,5}. The frequency of adverse reactions after BCG vaccination ranges from 0.1% to 19%⁵. In an Australian study, the adverse event frequency in 918 immunocompetent subjects was 5%, including injection site abscesses, severe local reactions, and lymphadenitis⁵. Serious disseminated BCG reaction occurs in 2 cases per 1 million vaccinated children, and has been reported mainly in immunocompromised hosts, particularly in persons positive for human immunodeficiency virus (HIV)⁶. The factors influencing the occurrence of these BCG adverse reactions are the dose and strain

of BCG vaccine, the injection technique, and the age and immune status of the vaccinated person^{4,5}. Disseminated BCG disease causes fever, weight loss, lymphadenopathy, severe illness, and pulmonary symptoms. Talbot, *et al* reported one case of disseminated BCG disease in an HIV-negative infant and reviewed another 27 cases, mostly associated with immunodeficiency, including 9 patients with acquired immunodeficiency syndrome⁶.

In BCG infected mice, TNF- α is required for granuloma formation and mycobacterial elimination, and TNF- α messenger RNA has been detected in granulomas⁸. Thus, BCG vaccine must be considered a potent active mycobacterium in anti-TNF- α treated patients. However, several substrains of BCG exist that may have different virulence and reactivity. Our patient did not develop any reaction to BCG vaccination. This might indicate that the BCG substrain used for inoculation had low virulence or a good safety profile. An alternative explanation might be the efficacy of the isoniazid treatment, since the BCG substrains used in France are highly sensitive to this drug. The duration of isoniazid treatment in our patient was empirical. Although BCG disseminated disease usually occurs a few months after vaccination, rarely later⁴, caution is required before reintroducing anti-TNF- α therapy, and it is difficult to decide when the anti-TNF- α agent should be reintroduced in this situation.

In light of these observations, BCG vaccination should be avoided in patients taking TNF- α blockers. In case of accidental BCG administration, anti-tuberculosis prophylaxis is strongly recommended, the choice of anti-tuberculosis drug depending on the BCG substrain. This case also highlights the importance of education, in particular regarding vaccinations, in patients receiving anti-TNF- α therapy.

ÉRIC TOUSSIROT, MD, PhD; DANIEL WENDLING, MD, PhD, Department of Rheumatology, University Hospital Jean Minjoz, Bvd Fleming, 25030 Besançon Cédex, France. Address reprint requests to Dr. É. Toussiro. E-mail: eric.toussiro@ufc-chu.univ-fcomte.fr

The authors are indebted to Yves-Dominique Henry, Schering-Plough, France, for his helpful remarks.

REFERENCES

1. Hyrich KL, Silman AJ, Watson KD, Symmons DPM. Anti-tumour necrosis factor alpha therapy in rheumatoid arthritis: an update on safety. *Ann Rheum Dis* 2004;63:1538-43.
2. Keane J, Gershon S, Wise R, et al. Tuberculosis associated with infliximab, a tumor necrosis factor alpha- neutralizing agent. *N Engl J Med* 2001;345:1098-104.
3. Gardam MA, Keystone EC, Menzies R, et al. Anti-tumour necrosis factor agents and tuberculosis risk: mechanisms of action and clinical management. *Lancet Infect Dis* 2003;3:148-55.
4. Adverse effects of BCG vaccination; mainly BCG infection. *Prescrire Int* 2003;12:220-4.
5. Turnbull FM, McIntyre PB, Achat HM, et al. National study of adverse reactions after vaccination with bacille Calmette-Guérin. *Clin Infect Dis* 2002;34:447-53.
6. Talbot EA, Perkins MD, Silva SF, Frothingham R. Disseminated bacille Calmette-Guérin disease after vaccination: case report and review. *Clin Infect Dis* 1997;24:1139-46.
7. Hesselting AC, Schaaf HS, Hanekom WA, et al. Danish bacille Calmette-Guérin vaccine-induced disease in human immunodeficiency virus-infected children. *Clin Infect Dis* 2003;37:1226-33.
8. Kindler V, Sappino AP, Grau GE, Piguet PF, Vassalli P. The inducing role of tumor necrosis factor in the development of bactericidal granulomas during BCG infection. *Cell* 1989;56:731-40.

Simultaneous Presentation of Cryptococcal Meningitis and Lupus Nephritis

To the Editor:

Infection is a significant cause of morbidity and mortality in systemic lupus erythematosus (SLE)¹. Patients with lupus are known to be at heightened risk for common pathogens as well as opportunistic organisms¹. Susceptibility to infection may be attributed to underlying immune dysregulation and to immunosuppressive therapy. Clinicians caring for these patients need to be familiar with the range of potential pathogens and maintain a high index of suspicion for infection whenever new symptoms or fevers occur. Indeed, severe life-threatening infection can not only mimic but can present simultaneously with new-onset lupus, based on our recent experience.

A 30-year-old woman originally from Guatemala presented to the Johns Hopkins Hospital with acute renal failure. She was well until 2 months prior to admission, when she developed gradual onset of fatigue with intermittent diffuse abdominal discomfort and nausea. One week prior to admission, she developed diffuse myalgias and arthralgias involving the knees, hands, and wrists and pleuritic chest pain. Several days prior to admission she complained of a bitemporal headache without photophobia. Upon hospitalization, she was afebrile. She had no rash, oropharyngeal ulcers, or synovitis. Meningismus was absent; mental status and peripheral neurologic examination were unremarkable. Admission examinations included serum creatinine of 4.4 mg/dl and white blood cell (WBC) count of 2300 cells/mm³. Erythrocyte sedimentation rate was elevated at 102 mm/h. Profound hypocomplementemia was present, with C3 24 mg/dl and C4 3 mg/dl. Antinuclear antibody titer was 1:640. Anti-double-stranded DNA titer was markedly elevated at 1:640. Chest computer tomography scan revealed pleural and pericardial effusions. Renal histopathology showed WHO class IV glomerulonephritis with numerous crescents.

Based on these findings she was diagnosed with SLE. The headache was initially attributed to lupus disease activity. Intravenous methylprednisolone was initiated at 1 gm/day for 3 consecutive days, followed by oral prednisone 60 mg/day. Given the severity of renal disease, intravenous cyclophosphamide was administered at 750 mg/m². The day after cyclophosphamide infusion, she developed fever. She continued to have a mild intermittent headache and no abnormalities detected by neurologic or funduscopic examination. Lumbar puncture revealed normal cerebrospinal fluid (CSF) protein and glucose concentrations and only 1–2 WBC/mm³, but both CSF and blood cultures grew *Cryptococcus neoformans*.

She was treated with a 14 day course of liposomal amphotericin, followed by a 42 day course of fluconazole, with prompt resolution of the fever and headache. Corticosteroids were gradually tapered. Subsequent blood and CSF cultures one month after diagnosis were negative for fungal growth. She did require hemodialysis at the time of discharge, but was not given additional cyclophosphamide during the hospitalization.

A large variety of organisms have been reported in association with SLE including bacteria, mycobacteria, viruses, fungi, and protozoa². Moreover, infections are reported to account for 14% of hospital admissions in affected persons³. Whether susceptibility to infection is due to immunosuppressive treatment only or to the underlying disease is uncertain.

Glucocorticoid and cytotoxic drugs may suppress the immune system and heighten susceptibility to infection. Infection rates are reported to be 2–4 times higher in patients treated with compared to those treated without steroids⁴.

Interestingly, there may be inherent immunologic abnormalities associated with lupus that also predispose to infection. Studies conducted prior to the widespread use of immunosuppressive therapies indicated an elevated

risk of infection in lupus⁴. Further, deficiencies of complement components, which are known to predispose to development of lupus⁵, may also lead to impaired clearance of immune complexes and microbial pathogens^{6,7}. Specifically, patients with lupus who possess deficient mannose-binding lectin are at higher risk for serious infection⁸.

Cryptococcal meningitis is an uncommon complication of SLE. Most reports of cryptococcal disease in lupus describe patients who have been maintained on high levels and sustained durations of immunosuppressive therapy. Zimmermann, *et al* reported 2 new cases and reviewed the literature regarding 24 previous cases⁹. Mean duration of lupus at development of cryptococcal meningitis was 3.3 years. Twenty-four of these patients were treated with corticosteroids and 10 with azathioprine. The outcome without antifungal therapy was uniformly poor, and all 5 untreated patients died. In contrast, there were 8 deaths in the 20 patients treated with amphotericin. Further, there has been one previous report of a patient who developed cryptococcal meningitis concurrent with the diagnosis of SLE and prior to initiation of immunosuppressive therapy¹⁰.

Our case represents the second report of a patient diagnosed with cryptococcal meningitis simultaneously with onset of SLE. We believe the unusual presentation suggests that underlying immune defects associated with lupus contributed to their infection, since both cases became clinically apparent before receipt of prolonged immunosuppression.

K. KWASIND HUSTON, MD; ALLAN C. GELBER, MD, Department of Medicine, Johns Hopkins University School of Medicine, Baltimore, Maryland, USA. Address reprint requests to Dr. A.C. Gelber, Johns Hopkins University School of Medicine, 5200 Eastern Avenue, Mason F. Lord Bldg. Center Tower, Suite 4100, Baltimore, MD 21224. E-mail: agelber@jhmi.edu

REFERENCES

1. Hellmann DB, Petri M, Whiting-O'Keefe Q. Fatal infections in systemic lupus erythematosus: the role of opportunistic organisms. *Medicine* 1987;66:341-8.
2. Kang I, Park SH. Infectious complications in SLE after immunosuppressive therapies. *Curr Opin Rheumatol* 2003;15:528-34.
3. Petri M, Genovese M. Incidence of and risk factors for hospitalizations in systemic lupus erythematosus: a prospective study of the Hopkins lupus cohort. *J Rheumatol* 1992;19:1559-65.
4. Staples PJ, Gerding DN, Decker JL, Gordon RS. Incidence of infection in systemic lupus erythematosus. *Arthritis Rheum* 1974;17:1-10.
5. Walport MJ. Complement. Second of two parts. *N Engl J Med* 2001;344:1140-4.
6. Walport MJ. Complement. First of two parts. *N Engl J Med* 2001;344:1058-66.
7. Ross SC, Densen P. Complement deficiency states and infection: epidemiology, pathogenesis and consequences of neisserial and other infections in an immune deficiency. *Medicine* 1984;63:243-73.
8. Garred P, Madsen HO, Halberg P, et al. Mannose-binding lectin polymorphisms and susceptibility to infection in systemic lupus erythematosus. *Arthritis Rheum* 1999;42:2145-52.
9. Zimmermann B, Spiegel M, Lally EV. Cryptococcal meningitis in systemic lupus erythematosus. *Semin Arthritis Rheum* 1992;22:18-24.
10. Mok CC, Lau CS, Yuen KY. Cryptococcal meningitis presenting concurrently with systemic lupus erythematosus. *Clin Exp Rheumatol* 1998;16:169-71.

Book Review

Bone Disease in Rheumatology

Michael Maricic, MD, and Oscar Gluck, MD, editors. Philadelphia: Lippincott Williams and Wilkins, 2004. 211 Pages, price \$ 99.95 US.

Bone Disease in Rheumatology is a unique offering that focuses on major topics in osteoporosis as seen from a rheumatology perspective. The 27 chapters in this book are organized into 6 major sections, which include anatomy and physiology of bone, measurement tools used in osteoporosis assessment and followup, disease-specific bone loss, rheumatologic drug related bone loss, management strategies for osteoporosis, and lastly a short review of common, non-osteoporotic bone disorders that may be seen in a rheumatology clinical setting. Chapters are by internationally recognized experts in the field. Basic concepts are discussed, and the published literature reflecting the osteoporosis/rheumatology interface is reviewed and well referenced. Additionally, the nuances of osteoporosis medicine are highlighted, giving the text a breadth and depth appealing to a wide readership. The writing styles are varied but uniformly clear and understandable.

Depending on the reader's prior level of expertise in this area, this new text can be seen as either an excellent primer or a compact amalgamation of key topics in osteoporosis through the eyes of the rheumatologist.

Heather McDonald Blumer, MD, FRCPC, Mt. Sinai Hospital/University Health Network, Suite 2-002 Lebovic Building, 600 University Avenue, Toronto, Canada.

Correction

Andriamanalijaona R, Baugé C, Renard E, et al. Comparative effects of 2 antioxidants, selenomethionine and epigallocatechin-gallate, on catabolic and anabolic gene expression of articular chondrocytes. *J Rheumatol* 2005;32:1958-67. The correct order of authors' names should be Rina Andriamanalijaona, Madeleine Kypriotou, Catherine Baugé, Emmanuelle Renard, Florence Legendre, Maha Raoudi, Karim Boumediene, Hugues Gatto, Patricia Monginoux, and Jean-Pierre Pujol. We regret the error.