



#### INSTRUCTIONS FOR LETTERS TO THE EDITOR

Editorial comment in the form of a Letter to the Editor is invited; however, it should not exceed 800 words, with a maximum of 10 references and no more than 2 figures (submitted as camera ready hard copy per Journal Guidelines) or tables and no subdivision for an Abstract, Methods, or Results. Letters should have no more than 4 authors. Full name(s) and address of the author(s) should accompany the letter as well as the telephone number, fax number, or E-mail address.

**Contact.** The Managing Editor, The Journal of Rheumatology, 365 Bloor Street East, Suite 901, Toronto, ON CANADA M4W 3L4. Tel: 416-967-5155; Fax: 416-967-7556; E-mail: jrheum@jrheum.com Financial associations or other possible conflicts of interest should always be disclosed.

### Erosions Rare Without Clinically Detectable Inflammation

To the Editor:

The recent article by Sokka, *et al*<sup>1</sup> highlighting the close correlation of wrist inflammation with wrist erosion development presents opportunities, as well as challenges. While they utilized either tenderness or swelling as measures of inflammation (and while many rheumatologists would consider tenderness separate from inflammation), swelling appeared to account for the majority of what they listed as inflammation. This limited (wrist-only) study<sup>1</sup> confirms previous analysis of the relationship of inflammation to erosive disease<sup>2-5</sup>.

Sokka, *et al* note that their data do not explain "why 23–50% of joints do not develop erosions while... suggests persistent inflammation." As 30–50% of bone must be lost before an erosion can be visualized by routine radiographic techniques<sup>6,7</sup>, radiographic underestimation of the presence or extent of erosive disease is well documented.

Analysis of skeletons of individuals with rheumatoid arthritis (RA) provided a similar perspective of relationship of erosions to synovitis, one not limited to the wrist. Fifty-nine individuals with RA in the Hamman-Todd human skeleton collection<sup>8</sup> were examined both grossly and radiologically for evidence of erosions<sup>2</sup>. The frequency of radiologically detectable erosions in a given joint (Table 1) in that population was indis-

Table 1. Radiologic distribution (%) of rheumatoid erosive disease.

Joint	Contemporary*	Hamman-Todd
Metacarpophalangeal	26–75	51
Proximal interphalangeal	18–51	33
Distal interphalangeal	8–10	3
Wrist	36–65	41
Elbow	14–39	7
Shoulder	7–26	14
Hip	2–15	4
Ankle	2–22	2
Metatarsophalangeal	35–49	41

\* Derived from references 9–13.

Table 2. Gross distribution (%) of rheumatoid erosions in defleshed skeletons compared with contemporary clinical synovitis.

Joint	Contemporary*	Hamman-Todd
Metacarpophalangeal	39–70	72
Proximal interphalangeal	44–64	70
Distal interphalangeal	8–45	41
Wrist	44–92	64
Elbow	15–66	26
Shoulder	6–26	29
Hip	2–12	7
Ankle	4–54	3
Metatarsophalangeal	36–74	72

\* Derived from references 9–13.

tinguishable from that noted ( $\chi^2 = 12.46$ , 8 df) in contemporary clinical populations<sup>9-13</sup>. As previously described, frequency of involvement (radiologic) of a given joint proved an excellent criterion for demonstrating comparability of populations<sup>8,14-16</sup>.

As anticipated, the frequency of visibly detectable erosions in defleshed skeletons exceeded that detectable radiologically. That frequency was, however, indistinguishable from the frequency of clinically recognized synovitis (e.g., swelling) in clinical populations (Table 2)<sup>9,12,15</sup>. Excellent correlation of gross and clinical distribution of disease suggests that some degree of erosive disease is integral to all joint involvement in RA and that only the relative insensitivity of radiologic techniques<sup>6,7,17</sup> precludes universal recognition of those erosions.

BRUCE M. ROTHSCHILD, MD, Northeastern Ohio Universities College of Medicine, Youngstown, Ohio 44512, USA.

#### REFERENCES

1. Sokka T, Kautiainen H, Mottonen T, Hannonen P. Erosions develop rarely in joints without clinically detectable inflammation in patients with early rheumatoid arthritis. *J Rheumatol* 2003;30:2580-4.
2. Rothschild BM, Woods RJ. Synovitis equivalent to erosions in rheumatoid arthritis: implications of skeletal analysis for clinical management of contemporary rheumatoid arthritis. *Clin Exp Rheumatol* 1992;10:117-22.
3. Mottonen TT. Prediction of erosiveness and rate of development of new erosions in early rheumatoid arthritis. *Ann Rheumatic Dis* 1988;47:648-53.
4. Ingeman-Nielsen M, Halskov O, Hansen TM, Halberg P, Lorenzen I. Clinical synovitis and radiological lesions in rheumatoid arthritis: A prospective study of 25 patients during treatment with remission-inducing drugs. *Scand J Rheumatol* 1983;12:237-40.
5. Sharp JT. Radiologic assessment as an outcome measure in rheumatoid arthritis. *Arthritis Rheum* 1989;32:221-9.
6. Rothschild BM. *Rheumatology: a primary care approach*. New York: Yorke Medical Press; 1982.
7. Resnick D. *Diagnosis of bone and joint disorders*. Philadelphia: Saunders; 2002.
8. Rothschild BM, Woods RJ. Rheumatoid arthritis 'in the buff': erosive arthritis in representative defleshed bones. *Am J Phys Anthropol* 1990;82:441-9.
9. Weissberg DL, Resnick D, Taylor A, Becker M, Alazraki N. Rheumatoid arthritis and its variants: Analysis of scintiphographic, radiographic, and clinical examinations. *AJR Am J Roentgenol* 1988;131:665-73.
10. Woods RJ, Rothschild BM. Population analysis of symmetrical erosive arthritis in Ohio Woodland Indians (1200 years before the present time). *J Rheumatol* 1988;15:1258-63.

11. Fletcher DE, Rowley KA. The radiologic features of rheumatoid arthritis. *Br J Radiol* 1952;25:282-95.
12. Martio J, Kiviniemi P, von Essen R. Early rheumatoid arthritis in the USSR and in Finland. *Scand J Rheumatol* 1980;9:39-43.
13. Martel W. Radiologic signs of rheumatoid arthritis with particular reference to the hand, wrist, and foot. *Med Clin North Am* 1968;52:655-65.
14. Rothschild BM, Turner KR, DeLuca MA. Symmetrical erosive peripheral polyarthritis in the Late Archaic Period of Alabama. *Science* 1988;241:1498-502.
15. Young A, Brook AS, Corbett M. The clinical assessment of joint inflammatory activity in rheumatoid arthritis related to radiologic progression. *Rheumatol Rehabil* 1980;19:14-9.
16. Rothschild BM, Woods RJ. Spondyloarthropathy in gorillas. *Semin Arthritis Rheum* 1989;18:267-76.
17. Rothschild BM, Sebes JJ, DeSmet AA. Radiologic assessment of bone and joint disease. I. Magnification radiology. *Semin Arthritis Rheum* 1985;14:274-9.

### Drs. Sokka and Hannonen reply

To the Editor:

We appreciate Dr. Rothschild's letter concerning our study. We are delighted that he cites additional papers we did not include in the references. It is important that the existing data are not forgotten but shared with the readers of the *Journal of Rheumatology*.

TUULIKKI SOKKA, MD, PhD; PEKKA HANNONEN, MD, PhD, Jyväskylä Central Hospital, Jyväskylä, Finland.

### Pollen Allergies in Patients with Systemic Lupus Erythematosus

To the Editor:

There is a controversy in the medical literature about whether patients with systemic lupus erythematosus (SLE) present a higher incidence of allergic reactions than the general population<sup>1,2</sup>, including reactions to drugs. This issue is raised in a recent article by Pope, *et al*<sup>3</sup>. In our geographic area (Mediterranean area, southern Spain) there is a high prevalence of olive, Graminaceae, Parietaria, and cypress pollen allergies. Since this aspect has not been previously studied in lupus patients, we designed a descriptive study to determine the prevalence of these types of allergies in our cohort of patients with SLE.

We studied 101 patients who fulfilled at least 4 criteria for SLE (90 women and 11 men), with a mean age of  $41.0 \pm 15.6$  years (range 12–73). All the patients were recruited from the Systemic Autoimmune Diseases Unit of our hospital. The group was compared with a control group consisting of 130 healthy subjects (103 women and 27 men, mean age  $39.2 \pm 15.2$  yrs) recruited from among researchers.

Patients and control subjects were interviewed in the outpatient department or by telephone asking the following questions: (1) presence or absence of pollen allergy; (2) if yes, type of allergen (olive, Parietaria, Graminaceae, cypress, others); (3) how diagnosis was made (clinically or by tests); (4) allergic symptoms (rhinitis, conjunctivitis, rhinoconjunctivitis, asthma); (5) treatment received; (6) in patients, relation (subjective impression) between allergic crisis and lupus course (worsening or not worsening). Demographic and clinical data of patients were obtained from our clinical database. Demographic data of healthy subjects were included in the questionnaire. A statistical study consisting of a chi-square test and Fisher's exact test, as appropriate, for the comparison of categorical variables was performed (significance was considered when  $p < 0.05$ ).

Continuous variables were expressed as mean  $\pm$  SD, and categorical data as percentages.

Patients with SLE presented more allergic problems (33.7%) than the control group (28%), although without statistical significance ( $p > 0.05$ ). These types of allergens in SLE patients and in controls with allergic problems were similar. Similarly, allergic symptoms were also similar in both groups. Five of 34 (14.7%) SLE patients with pollen allergy experienced a worsening of the disease, coinciding with allergic crisis. Because corticosteroid use could improve and mask allergic symptoms in lupus patients, we compared SLE patients with and without corticosteroid treatment for lupus (68 and 33 patients, respectively), and we found that the 2 groups presented a similar frequency of allergic problems (32% and 36%, respectively).

Therefore we found that, in our geographic area, the prevalence of allergy to olive, Parietaria, Graminaceae, and cypress pollen in patients with SLE was similar to that of the general healthy population.

JUAN JIMÉNEZ-ALONSO, MD; J. JIMÉNEZ-JÁIMEZ, MD; M.V. ALMAZÁN, MD, Grupo Lupus Virgen De Las Nieves, Systemic Autoimmune Diseases Unit, Service of Internal Medicine, Virgen de las Nieves University Hospital, Granada, Spain.

**ACKNOWLEDGMENT:** Other members of the Grupo Lupus Virgen De Las Nieves: José Mario Sabio, MD; Laura Jáimez, MD; José Manuel Osorio, MD; Juan Pasquau, MD; Manuel López-Gómez, MD; Juan Diego Mediavilla, MD; Encarnación Milla, MD; Julián Muñoz-Alonso, MD; Manuel Guzmán-Úbeda, MD; Rafael Cáliz, MD; Antonio García-Sánchez, MD; Miguel Angel Ferrer, MD; Valentín García-Mellado, MD; Jesús Tercedor, MD; Elena García-Lora, MD; Jorge Espelt, MD; Dolores López-Segarra, MD; Jesús Prieto, MD; Santiago Medialdea, MD; Teresa Muros, MD; Gonzalo Piédrola, MD; David Esteva, MD; Carmen Vera, MD; Nuria Navarrete, MD; Pilar Macias, MD; Concepción García, MD; Fernando Jaén, MD; M. José Pérez, MD; Francisco Jarilla, MD; and Mónica Zamora, MD.

### REFERENCES

1. Sekigawa I, Yoshiike T, Iida N, Hashimoto H, Ogawa H. Allergic disorders in systemic lupus erythematosus: prevalence and family history. *Lupus* 2002;11:426-9.
2. Sekigawa I, Yoshiike T, Iida N, Hashimoto H, Ogawa H. Allergic diseases in systemic lupus erythematosus: prevalence and immunological considerations. *Clin Exp Rheumatol* 2003;21:117-21.
3. Wozniacka A, Sysa-Jedrzejowska A, Robak E, Samochocki Z, Zak-Prelich M. Allergic diseases, drug adverse reactions and total immunoglobulin E levels in lupus erythematosus patients. *Mediators Inflamm* 2003;12:95-9.
4. Pope J, Jerome D, Fenlon D, Krizova A, Ouimet J. Frequency of adverse drug reactions in patients with systemic lupus erythematosus. *J Rheumatol* 2003;30:480-4.

### Dr. Pope replies

To the Editor:

I read with interest the letter submitted by Jimenez-Alonso, *et al* describing their study on the commonly found pollen allergies in Spain in 101 patients with SLE and 130 healthy controls. The prevalence of pollen allergies was not different between the groups.

This is an interesting study with case-control methodology similar to our study of adverse drug reactions in patients with SLE<sup>1</sup>, where we studied the prevalence of drug allergies in SLE and age and sex matched subjects with rheumatoid arthritis. We found no increase in reports of allergic drug reactions except with sulfa based drugs. One would wonder if our findings of increased sulfa allergies (and not other common drug exposures), and now their study showing no increase in pollen allergies, are related to the pharmacogenetics in the SLE patients and not an overall

increase in nonspecific allergies. This current report would support this hypothesis, and more work is needed to determine if the metabolism of sulfa drugs is different in SLE, or if in fact an extended haplotype is more common in patients with SLE and in those who are allergic to sulfa.

JANET POPE, MD, Rheumatology Centre, 268 Grosvenor Street,  
PO Box 5777, London, Ontario N6A 4V2, Canada.  
E-mail: janet.pope@sjhc.london.on.ca

## REFERENCE

1. Pope J, Jerome D, Fenlon D, Krizova A, Ouimet J. Frequency of adverse drug reactions in patients with systemic lupus erythematosus. *J Rheumatol* 2003;30:480-4.



## Synovial Density of Frizzled 5-Positive Cells Does Not Differ Between Patients with Rheumatoid Arthritis and Osteoarthritis and Is Independent of Inflammation

To the Editor:

Synovial inflammation leads to remodeling of affected tissue, which normally leads to fast repair. This healing process may be largely disturbed in inflamed synovial tissue of patients with rheumatoid arthritis (RA). Investigation of "embryonic factors" and their signaling pathways may add important new information about RA pathogenesis and may yield new targets for therapeutic intervention.

Recently, new embryonic growth factors from the wingless (wnt) and frizzled (fz) families were found to play a role in embryogenesis of *Drosophila melanogaster*<sup>1</sup>. Fz and wnt play an important role in the signaling cascade of cell-cell interactions where wnt proteins are ligands of fz proteins. Sen, *et al* recently found that the synovial tissue of patients with osteoarthritis (OA) expressed much less frizzled 5 (fz5) mRNA compared to synovium of patients with RA<sup>2</sup>. The same investigators demonstrated that anti-fz5 antibody reduced expression of proinflammatory cytokines<sup>3</sup>, and that this new "embryonic pathway" can regulate important wound healing in RA fibroblast-like synoviocytes<sup>4</sup>.

We investigated the protein fz5 in synovial tissue of patients with RA and OA, to relate the density of fz5-positive synoviocytes to typical histological markers of inflammation.

From a total group of 150 patients with OA and 150 with RA who underwent knee joint replacement surgery, we randomly selected 9 RA and 11 OA patients with similar signs of inflammation in order to detect a possible disease-specific expression of fz5 that is independent of inflammation. RA patients fulfilled the American College of Rheumatology criteria for RA<sup>5</sup>. The study was approved by the Ethical Committee of the University of Regensburg.

The preparation and histology of the tissue was as described<sup>6</sup>. For each parameter, 8 cryosections were prepared of 3 different pieces of synovial tissue marked with antibodies against T cells (CD3, clone UCHT1; Dako, Hamburg, Germany), macrophages (CD163, clone BerMAC; Dako), vessels (collagen IV, clone CIV22; Dako), and fz5 (Upstate Biotechnology,

Lake Placid, NY, USA). Staining was achieved by the alkaline phosphatase anti-alkaline phosphatase (APAAP) method or by BCIP/NBT (fz5). As well, 45 cryosections were stained with hematoxylin-eosin (H&E) for the quantification of lining-layer thickness and cell density.

Histological evaluation was as described<sup>6</sup> according to Bresnihan, *et al*<sup>7</sup>. The number of identified structures was averaged from 17 randomly selected high power fields (400×) and expressed per mm<sup>2</sup>.

All data are given as mean ± SEM. Group medians were compared by the nonparametric Mann-Whitney test (SPSS/PC, Advanced Statistics, V10.0.1; SPSS Inc., Chicago, IL, USA). The significance level was  $p < 0.05$ .

As shown in Table 1, histological signs of inflammation were comparable in RA and OA patients. Figure 1 illustrates typical staining of fz5-positive cells in the synovial tissue of 3 different OA and RA patients. Counting fz5-positive synovial cells did not reveal a significant difference between OA and RA patients. Cell density of fz5-positive cells was similar to density of CD3-positive T cells (compare Table 1 and Figure 1). Spearman correlation analysis did not reveal any interrelation between density of fz5-positive synovial cells and other histological markers of inflammation, in disease subgroups or in the entire group.

Since the density of fz5-positive cells did not differ between RA and OA patients, we combined the 2 disease groups in order to detect any influence of prior medication with nonsteroidal antiinflammatory drugs. In the combined RA and OA data, no interrelation was found between any type of drug and density of fz5-positive synoviocytes.

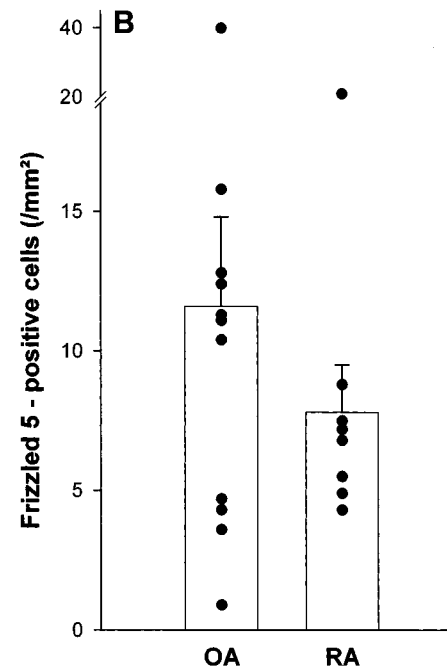
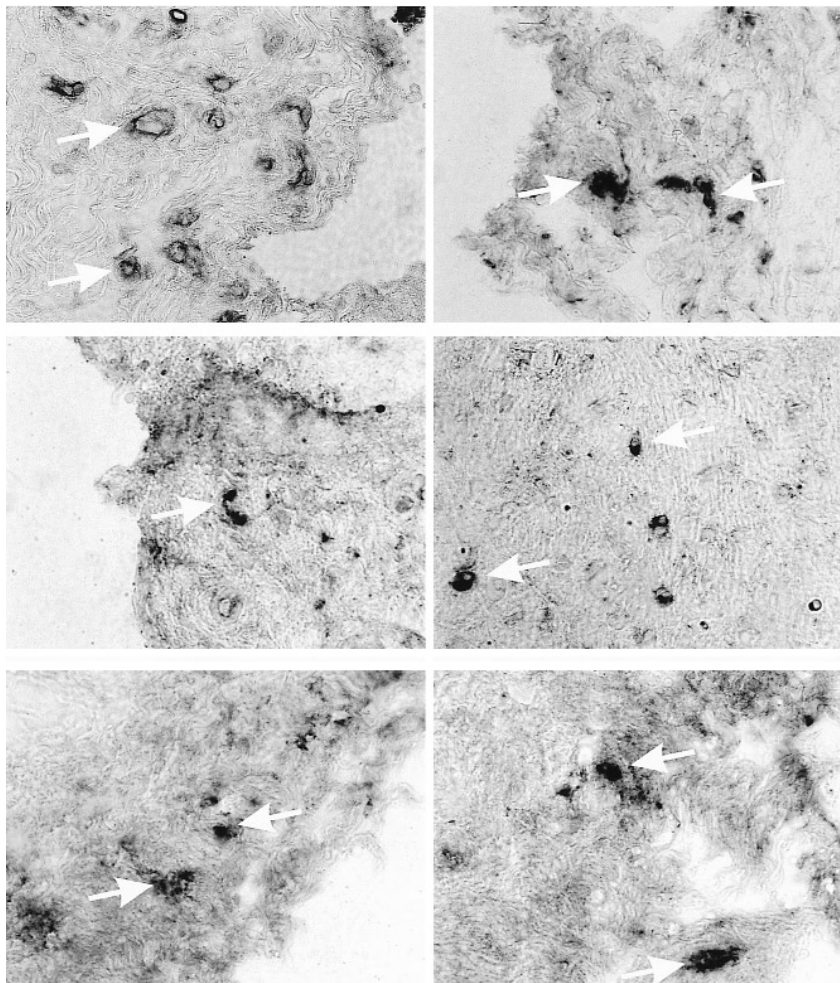
Thus we were not able to detect a significant difference of fz5-positive synovial cells in patients with RA compared to those with OA. Our study does not corroborate recent findings of a marked difference in fz5 mRNA expression in RA patients compared to OA patients<sup>2</sup>. That study investigated only mRNA expression by means of reverse transcription-polymerase chain reaction and Northern blotting<sup>2</sup>. Since the authors did not investigate the presence of fz5 by means of semiquantitative immunohistochemistry, a comparison of RA and OA patients with respect to fz5 protein was not possible. Although the signs of inflammation of the 2 disease groups were similar, it may be possible that our contrasting findings may be attributed to the types of patients, of medications, and of biopsies. From our point of view,

**Table 1.** Basic characteristics and markers of inflammation in patients with OA and RA. Data are given as means ± SEM.

	OA	RA
Number	11	9
Age, yrs (range)	69.4 ± 2.4 (54–82)	61.3 ± 3.1 (47–76)
F/M (%)	9/2 (86/18)	5/4 (57/44)
ESR, mm/h	15.0 ± 2.9	23.0 ± 7.7
CRP, mg/l	6.2 ± 1.7	22.4 ± 7.4
Medication (%)		
Prednisolone	0 (0)	7 (78)
Methotrexate	0 (0)	1 (11)
Sulfasalazine	0 (0)	2 (22)
Azathioprine	0 (0)	1 (11)
Cyclosporin A	0 (0)	1 (11)
Leflunomide	0 (0)	2 (22)
Gold compounds	0 (0)	0 (0)
NSAID	6 (55)	7 (78)
Histology		
Lining-layer thickness, no. cells	4.5 ± 1.9	6.8 ± 0.7
CD3+ T lymphocytes, per mm <sup>2</sup>	29.1 ± 7.5	23.6 ± 5.6
CD163+ macrophages, per mm <sup>2</sup>	84.0 ± 21.6	77.4 ± 13.0
Overall cellularity, cells/mm <sup>2</sup>	948.5 ± 96.2	1193.2 ± 231.9
Overall vascularity, vessels/mm <sup>2</sup>	26.7 ± 2.6	25.6 ± 2.9

ESR: erythrocyte sedimentation rate, CRP: C-reactive protein, NSAID: nonsteroidal antiinflammatory drug.

## A osteoarthritis rheumatoid arthritis



**Figure 1.** Frizzled 5-positive cells in RA and OA synovial membrane. A. Immunohistochemistry observations from 3 patients with RA and 3 with OA. These are randomly selected fields of the sublining and lining area. A polyclonal rabbit antibody directed against a synthetic peptide derived from amino acids 564–585 of human fz5 was used (400 $\times$ ). B. Density of frizzled 5-positive cells in synovial membrane in patients with RA compared to OA. In 17 randomly selected high power fields (400 $\times$ ), the number of fz5-positive cells was counted, and the average is expressed in cells/mm<sup>2</sup>. The mean density is given  $\pm$  SEM.

fz5 protein may not be a suitable histological marker to discriminate RA and OA patients. As Sen, *et al* point out, the ligand of fz5, the soluble protein wingless 5a (wnt5a), may be a more important factor in this embryonic pathway. Using a commercially available antibody (polyclonal goat antibody; R&D Systems, Wiesbaden, Germany), we were not able to detect wnt5a protein by immunohistochemistry in synovium of patients with RA or OA. However, this protein has been reported to be very unstable<sup>8</sup>, and thus is probably undetectable. The question remains why mRNA of these 2 embryonic factors are largely different in the 2 disease groups, but immunohistochemical staining does not detect a significant difference in density of fz5-positive cells. This discrepancy may be due to differences in translation or posttranslational processing. Another explanation for the different findings may be that fz5-positive cells in RA contain more fz5 protein than those in OA, which cannot be detected by quantitative immunohistochemistry.

Nevertheless, we agree with the general idea that embryonic factors may be interesting targets in RA and possibly OA. Remodeling of the inflamed tissue is probably a very important issue in understanding the pathogenesis of these quite different diseases.

CLAUDIA WEIDLER, PhD Student, Department of Internal Medicine I;  
JENS SCHAUMBURGER, MD, Orthopedic Surgeon, Department of  
Orthopedic Surgery; LUITPOLD E. MILLER, PhD, Fellow in

Experimental Rheumatology, Department of Internal Medicine I;  
JÜRGEN SCHÖLMERICH, MD, Professor of Medicine, Head,  
Department of Internal Medicine I; RAINER H. STRAUB, MD, Professor  
of Experimental Medicine, Department of Internal Medicine I, University  
Medical Center Regensburg, D-93042 Regensburg, Germany.  
E-mail: rainer.straub@klinik.uni-regensburg.de

*Supported by the Deutsche Forschungsgemeinschaft (STR 511/10-1).*

## REFERENCES

1. Vinson CR, Conover S, Adler PN. A Drosophila tissue polarity locus encodes a protein containing seven potential transmembrane domains. *Nature* 1989;338:263-4.
2. Sen M, Chamorro M, Reifert J, Corr M, Carson DA. Blockade of Wnt-5A/frizzled 5 signaling inhibits rheumatoid synoviocyte activation. *Arthritis Rheum* 2001;44:772-81.
3. Sen M, Lauterbach K, El Gabalawy H, Firestein GS, Corr M, Carson DA. Expression and function of wingless and frizzled homologs in rheumatoid arthritis. *Proc Natl Acad Sci USA* 2000;97:2791-6.
4. Sen M, Reifert J, Lauterbach K, et al. Regulation of fibronectin and metalloproteinase expression by Wnt signaling in rheumatoid arthritis synoviocytes. *Arthritis Rheum* 2002;46:2867-77.

5. Arnett FC, Edworthy SM, Bloch DA, et al. The American Rheumatism Association 1987 revised criteria for the classification of rheumatoid arthritis. *Arthritis Rheum* 1988;31:315-24.
6. Miller LE, Jüsten HP, Schölmerich J, Straub RH. The loss of sympathetic nerve fibers in the synovial tissue of patients with rheumatoid arthritis is accompanied by increased norepinephrine release from synovial macrophages. *FASEB J* 2000;14:2097-107.
7. Bresnihan B, Cunnane G, Youssef P, Yanni G, Fitzgerald O, Mulherin D. Microscopic measurement of synovial membrane inflammation in rheumatoid arthritis: proposals for the evaluation of tissue samples by quantitative analysis. *Br J Rheumatol* 1998;37:636-42.
8. Yoshikawa S, MacKinnon RD, Kokel M, Thomas JB. Wnt-mediated axon guidance via the Drosophila derailed receptor. *Nature* 2003;422:583-8.

### Septicemia with *Staphylococcus aureus*, $\beta$ -Hemolytic Streptococci Group B and G, and *Escherichia coli* in a Patient with Rheumatoid Arthritis Treated with a Recombinant Human Interleukin 1 Receptor Antagonist (Anakinra)

To the Editor:

The endogenous interleukin 1 receptor antagonist (IL-1Ra) belongs to the acute phase proteins and is induced during sepsis. Recognition of the importance of IL-1 in the pathogenesis of inflammatory arthritis<sup>1,2</sup> paved the way for treatment of RA patients with the recombinant human IL-1Ra anakinra<sup>3</sup>. However, the longterm effects of blocking IL-1 and other cytokines in patients with RA are not sufficiently defined, and adequate concern has been raised about their safety, including susceptibility to infections.

Our patient was a 66-year-old Caucasian woman with an 11-year history of seropositive and erosive RA. She had required bilateral hip arthroplasty and posterior atlantoaxial arthrodesis due to cervical spine involvement. Rheumatoid nodules had been present, but she had no other extra-articular manifestations. Her history included mild chronic obstructive pulmonary disease and obesity, but no serious infection requiring hospitalization or prolonged treatment with antibiotics. She had previously been unable to tolerate methotrexate, sulfasalazine, hydroxychloroquine, and leflunomide, and cyclosporine and low dose corticosteroids did not control disease activity. Two months before presentation, 100 mg anakinra subcutaneously was added to baseline 5 mg prednisolone daily. One month later, she was admitted to the local hospital due to a minor stroke, at which time warfarin was started for atrial fibrillation. She was also found to have erysipelas, which was treated with penicillin V for 10 days. Anakinra was discontinued, but because of rapidly increasing disease activity, the IL-1Ra treatment was reinstituted after one week. Three weeks later, she developed fever, rigors, and lightheadedness, and was brought to the emergency room the following day. On admission, she had a temperature of 38.5°C, atrial fibrillation with a frequency of 155 per minute, and blood pressure 110/60. Widespread eczema and suspected cutaneous mycosis were noted. These lesions had been present before penicillin V was started, and they had only partly resolved during treatment. A chest radiograph was normal, and laboratory tests revealed an increased leukocyte count ( $30 \times 10^9/l$ ) and elevated C-reactive protein (215 mg/l). A diagnosis of infection of unknown origin was made, and intravenous cefotaxime therapy (1 g three times daily) was started. The patient recovered within 4 days. Fortunately, there were no clinical signs of prosthesis infection or other septic arthritis.

*Staphylococcus aureus* and  $\beta$ -hemolytic group B and G streptococci were isolated in each of 2 sets of blood drawn on 2 separate occasions with a 30 minute interval. In addition, *Escherichia coli* was isolated in blood on one occasion. Throat and urine specimens revealed growth of group G streptococci and *E. coli* ( $> 10^6/l$ ), respectively. The *S. aureus* was suscepti-

ble to isoxazolyl penicillins, cefuroxime, cefotaxime, ceftazidime, erythromycin, clindamycin, tetracycline, linezolid, vancomycin, rifampicin, trimethoprim-sulfamethoxazole, tobramycin, and imipenem. The  $\beta$ -hemolytic group B and G streptococci were susceptible to the antibacterial agents tested, with the exception of trimethoprim-sulfamethoxazole (intermediate susceptible) and tobramycin (resistant). The streptococci were susceptible to penicillin V, and the *E. coli* isolate was susceptible to all tested antibiotics that are active against gram-negative bacteria.

RA is associated with an increased susceptibility to severe infections<sup>4</sup>, and patients with severe disease and chronic corticosteroid treatment are at a greater risk than others<sup>5</sup>. Immunosuppressive anticytokine treatment may further increase the risk of infection complications<sup>6</sup>. Based on experience from clinical trials, treatment with anakinra has been considered generally safe, but a slightly increased frequency of pneumonia and cellulitis caused by *Streptococcus pneumoniae* and *S. aureus*, respectively, has been reported<sup>3</sup>. It has been suggested that patients with obstructive pulmonary disease may be at a particularly increased risk of respiratory infections if treated with IL-1Ra<sup>3</sup>. Our case, with relatively mild symptoms considering the presumptive virulence of the 4 different bacterial species, is unusual. Patients with variant IL-1Ra gene polymorphisms have an increased risk of mortality when affected by severe sepsis<sup>7</sup>. It is possible that our patient was protected from the harmful effects of IL-1 due to the anakinra treatment, and therefore only developed moderate symptoms of infection that in combination with efficient antibacterial therapy did not lead to septic shock.

Patients treated with anakinra and other cytokine-blocking interventions should be carefully monitored. Suppression of signs and symptoms of infections in such patients could delay recognition of complications and their treatment. Early intervention to treat potentially serious adverse events is of major importance in the management of patients with severe RA. Future research should explore the effects of cytokines and specific anti-cytokine therapy on susceptibility to infections and on the clinical course in affected patients.

CARL TURESSON, MD, PhD; KRISTIAN RIESBECK, MD, PhD,  
Departments of Rheumatology and Microbiology, Malmö University  
Hospital, Malmö, Sweden. E-mail: turesson.carl@mayo.edu

### REFERENCES

1. Arend WP, Malyak M, Guthridge CJ, Gabay C. Interleukin-1 receptor antagonist: role in biology. *Annu Rev Immunol* 1998;16:27-55.
2. Horai R, Saijo S, Tanioka H, et al. Development of chronic inflammatory arthropathy resembling rheumatoid arthritis in interleukin 1 receptor antagonist-deficient mice. *J Exp Med* 2000;191:313-20.
3. Fleischmann RM, Schechtman J, Bennett R, et al. Anakinra, a recombinant human interleukin-1 receptor antagonist (r-metHuIL-1ra), in patients with rheumatoid arthritis: A large, international, multicenter, placebo-controlled trial. *Arthritis Rheum* 2003;48:927-34.
4. Doran MF, Crowson CS, Pond GR, O'Fallon WM, Gabriel SE. Frequency of infection in patients with rheumatoid arthritis compared with controls: a population-based study. *Arthritis Rheum* 2002;46:2287-93.
5. Doran MF, Crowson CS, Pond GR, O'Fallon WM, Gabriel SE. Predictors of infection in rheumatoid arthritis. *Arthritis Rheum* 2002;46:2294-300.
6. Bresnihan B, Cunnane G. Infection complications associated with the use of biologic agents. *Rheum Dis Clin North Am* 2003;29:185-202.
7. Arnalich F, Lopez-Maderuelo D, Codoceo R, et al. Interleukin-1 receptor antagonist gene polymorphism and mortality in patients with severe sepsis. *Clin Exp Immunol* 2002;127:331-6.