Posterior Tibial Tendon and Subtalar Joint Complex in Rheumatoid Arthritis: Magnetic Resonance Imaging Study

MAURICE BOUYSSET, JACQUES TEBIB, THIERRY TAVERNIER, ERIC NOEL, CHANTAL NEMOZ, MICHEL BONNIN, KARL TILLMANN, and JOCELYNE JALBY

ABSTRACT. ***Objective.*** To observe by magnetic resonance imaging (MRI) the pathologic changes in the posterior tibial tendon (PTT), subtalar joint complex (STJC), and sinus tarsi in patients with rheumatoid arthritis (RA), and if possible to determine their involvement in the course of the disease.

Methods. Sixty-seven rheumatoid feet with mid and hindfoot pain underwent MRI with gadolinium injection. Localized enhancement and anatomic lesions were assessed in the 3 sites.

Results. On MRI, PTT involvement was seen to be more frequent than STJC or sinus tarsi. When there was gadolinium enhancement of the PTT there was no sinus tarsi enhancement ($p = 0.014$). Interosseous talocalcaneal ligament rupture was correlated with disability ($p = 0.031$).

Conclusion. In RA patients with hindfoot pain, PTT synovitis is observed when there is no sinus tarsi synovitis. (J Rheumatol 2003;30:1951–4)

Key Indexing Terms:
POSTERIOR TIBIAL TENDON
SUBTALAR JOINT COMPLEX
SINUS TARSI
RHEUMATOID ARTHRITIS

Flattening of the longitudinal arch is the most common mid-tarsal deformity of patients with rheumatoid arthritis (RA) and there is an associated valgus deformity[1]. In RA, there is controversy whether the planovalgus deformity is due to posterior tibial tendon (PTT) pathology or subtalar joint instability[2]. This study cannot answer this question, since no reliable clinical assessment and no radiographic measurements were considered.

Synovitis is the primum movens of local inflammatory pathology and is observed by gadolinium enhancement on magnetic resonance imaging (MRI). The degree of synovitis and comparison of anatomic lesions seen on MRI make it possible to monitor the progression of the local inflammatory process.

MATERIALS AND METHODS

Thirty-five patients with RA defined according to the American College of Rheumatology criteria were studied[3]. These patients were referred by the Department of Rheumatology (CHLS) for foot discomfort possibly requiring complementary local treatment (foot orthoses, made-to-measure shoes, or surgery). All patients had marked mid and hindfoot pain apparently due to RA, and were consecutively recruited in a foot clinic specializing in inflammatory pathology. Three feet had had surgery on the mid-hindfoot and were excluded from the study, so 67 rheumatoid feet were included: female feet 88.1%, male feet 11.9%, patients' mean age 54.67 years (range 26–75) and mean disease duration 9.93 years (range 1–20). Functional capacity was assessed according to Steinbrocker[4]: stage I, 11.9%; stage II, 68.7%; stage III, 19.4%.

MRI with gadolinium injection was carried out in each patient. The earliest images were obtained according to the following protocol: T2 spin-echo in the transverse plane, T1 in the coronal plane before and after intravenous (IV) gadolinium injection, transverse T1 after gadolinium, and supplementary sagittal T1 images after gadolinium. More recently, the following sequences were obtained: transverse fat-saturation T2, coronal T1, and fat-saturation T1 in the transverse, coronal and sagittal planes after gadolinium. A single experienced radiologist (TT), blind to patient symptoms and physical assessment, examined the MRI images twice at an interval of 6 months, and a final decision based on the opinion of this single radiologist was reached by reviewing any doubtful films.

We carried out observations of the following: PTT enhancement (tenosynovitis): mild, moderate, or marked depending on the degree of gadolinium enhancement of the synovial sheath; PTT lesions[5]: stage I = tendon thickening with longitudinal splitting, stage II = hourglass tendon at the level of the lesion, stage III = complete rupture; subtalar joint complex (STJC) enhancement (between the surfaces of the talonavicular or subtalar joints); STJC lesions (degenerative changes between the surfaces of the talonavicular or subtalar joints); and sinus tarsi enhancement (sinus tarsi synovial pannus): 0 = no pannus, 1 = minimal pannus, 2 = moderate pannus, 3 = marked pannus (Figure 1).

The term "involvement" indicates the presence of every possible lesion: enhancement alone, lesion alone, or enhancement associated with an anatomic lesion of the PTT, STJC, or sinus tarsi.

We also noted destruction of the interosseous talocalcaneal ligament (ITCL): 0 = no lesion, or 1 = ITCL lesion (ligament deleted) (Figure 1).

Statistical analysis. SPSS software was used for analysis. For comparison

From the Department of Rheumatology, Hôpital Edouard-Herriot, Lyon, and Department of Rheumatology, Centre Hospitalier Lyon Sud, Pierre Bénite, France.

M. Bouysset, MD, Villefranche sur Saône; J. Tébib, MD, Professor of Medicine, Service de Rhumatologie, Centre Hospitalier Lyon Sud (CHLS); T. Tavernier, MD, Service de Radiologie, Clinique de la Sauvegarde, Lyon; E. Noël, MD, Hôpital Edouard Herriot; C. Némoz, PhD, Service de Biostatistique et d'Informatique Médicale des Hospices Civils de Lyon, Lyon; M. Bonnin, MD, Orthopaedic Surgeon, Clinique Sainte Anne Lumière, Lyon; K. Tillmann, MD, Rheumaklinik Bad Bramstedt, Gmbh, Bad Bramstedt, Germany; J. Jalby, MD, Villefranche sur Saône.

Address reprint requests to Dr. M. Bouysset, 126 rue Philippe Héron, 69400 Villefranche sur Saône, France. E-mail: scm.rhumatologie-caladoise@wanadoo.fr

Submitted April 18, 2002; revision accepted February 21, 2003.

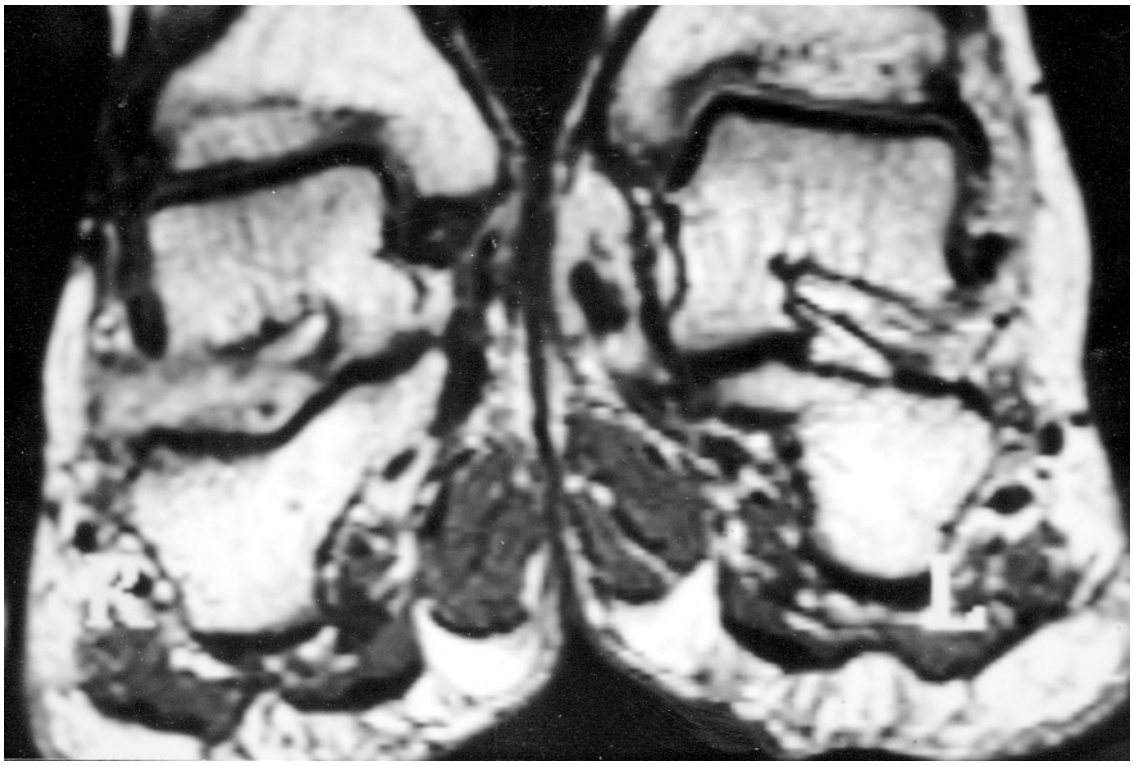

Figure 1. MRI after gadolinium injection. Right foot: enhancement of pannus in sinus tarsi and ruptured interosseous ligament.

of the qualitative data, we used Fisher's exact test for 2 × 2 tables and the chi-squared likelihood ratio. For comparison of disease duration we used Student's t test and the nonparametric Wilcoxon test.

RESULTS

The MRI findings are summarized in Table 1. PTT pathology was more frequent than STJC or sinus tarsi pathology (Table 2). The incidence of PTT involvement was always higher (10 to 20%) than that of STJC involvement (Figure 2). The results were the same if enhancement alone or lesion alone was considered. On MRI, the search for PTT pathology without STJC pathology or ITCL pathology showed a correlation only between PTT enhancement with no sinus tarsi enhancement (Table 3).

STJC enhancement was correlated with sinus tarsi enhancement ($p = 0.0005$). STJC involvement was correlated with sinus tarsi enhancement ($p = 0.005$). The PTT and STJC showed no significant difference concerning disease duration for enhancement, lesions, or involvement. ITCL rupture was correlated with disability ($p = 0.031$).

Table 1. MRI findings in rheumatoid feet.

Rheumatoid Feet (n = 67)	n (%)
PTT enhancement	
Mild	22 (32.8)
Moderate	13 (19.4)
Marked	18 (26.9)
PTT lesions	
Stage 1	20 (29.9)
Stage 2	26 (38.8)
Stage 3	7 (10.4)
STJC enhancement	30 (44.8)
Degenerative STJC lesion	34 (50.7)
Sinus tarsi enhancement	
Mild	13 (19.4)
Moderate	9 (13.4)
Marked	8 (11.9)
ITCL poorly visualized or not seen	11 (16.4)

DISCUSSION

Some authors consider that all hindfoot deformity seen in RA is a consequence of rheumatoid related joint laxity[6,7], with no significant PTT dysfunction. Electromyographic and gait studies do not show deficient PTT function secondary to weakness, nor is the deformity due to impaired function of the tendon because of tenosynovitis[8]. By contrast, a clinical study observed that planovalgus deformity in RA can be due to clinically evident dysfunction of the posterior tibial muscle-tendon unit[2].

On MRI, PTT involvement in RA was frequent if tarsal inflammation was present[9]. PTT tears were common in RA flat feet, but PTT did not appear to be solely responsible for the flat foot deformity[10].

The PTT is an important stabilizer of the medial arch of the foot[11]. When significant PTT force across the talonavic-

Table 2. PTT enhancement was more frequent than STJC enhancement. Involvement (enhancement or lesion) was more frequent in the PTT than in the STJC. Enhancement of sinus tarsi alone was the most frequent observation. The groups cannot be compared because they are not independent.

MRI Signs (total 67 feet)	PTT Pathology 53 feet, 79.1% n (%)	STJC Pathology 34 feet, 50.7% n (%)	Sinus Tarsi Pathology 11 feet, 16.4% n (%)
Localized Gd enhancement without lesions	8 (11.9)	9 (13.4)	23 (34.3)
Lesions without Gd enhancement	8 (11.9)	13 (19.4)	4 (6.0)
Localized Gd enhancement with lesions	45 (67.2)	21 (31.3)	7 (10.4)
Involvement	61 (91.0)	43 (64.2)	34 (50.7)
No enhancement + no lesions	6 (9.0)	24 (35.8)	33 (49.3)

Gd: gadolinium.

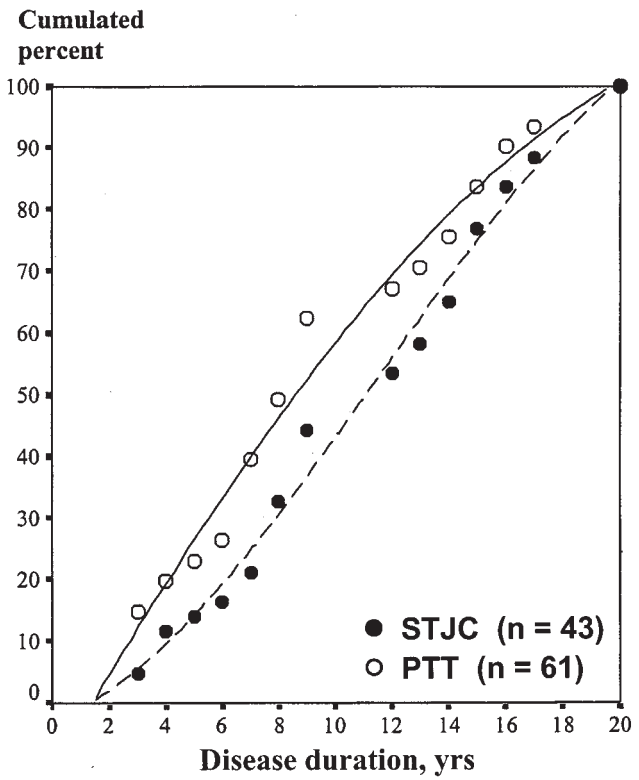

Figure 2. Curve of cumulative frequency in percentage involvement. Involvement of PTT and STJC increased in frequency with disease duration. PTT involvement was observed before STJC involvement and was always more frequent. The results are the same if lesions alone or enhancement alone are considered.

ular joint is lost, this can result in flat foot deformity, and when PTT action is absent the initial stages of deformity can be observed in a cadaveric model[12]. This leads to the hypothesis that PTT inflammatory pathology could provoke PTT dysfunction followed by flat foot deformity, which may cause increased stress on the ITCL, resulting in sinus tarsi synovitis. Such a hypothesis could corroborate the observation that many patients with RA experience medial hindfoot pain followed by a period of relatively mild symptoms; the next stage involves increasing flat foot deformity and lateral pain due to impingement in the sinus tarsi area. However, from our study we cannot determine whether earlier PTT inflammatory involvement is correlated with altered hindfoot stability and alignment. However, it is generally considered that progression of the deformity is related to slow destruction of all the supporting tissues around the subtalar joints with stretching of the ligaments[1] and tendons, among them the PTT.

Treatment of PTT insufficiency due to synovitis or primary hindfoot instability in patients with RA, is similar[2], and the distinction does not appear to be clinically important. However, it must be stressed that during foot assessment, PTT synovitis must be systematically investigated, since it is more frequently detected on MRI than STJC involvement, and it is also observed when there is no inflammatory lesion of the sinus tarsi.

In summary, MRI shows that in patients with RA having hindfoot pain PTT involvement is more frequent than STJC involvement. PTT synovitis is observed when there is no sinus tarsi synovitis. ITCL rupture is correlated with disability.

Table 3. PTT pathology without other pathology. Only one correlation was observed: when there is PTT enhancement there is no sinus tarsi enhancement (p = 0.014).

	No STJC Lesion, n = 33 (%)	No STJC Enhancement, n = 37 (%)	No STJC Involvement, n = 24 (%)	No ITCL Leison, n = 56 (%)	No Sinus Tarsi Enhancement, n = 37 (%)
PTT enhancement, n = 53	26 (78.8)	27 (33.0)	18 (75.0)	43 (76.8)	25 (67.6) p = 0.014
PTT lesion, n = 53		27 (33.0)	17 (70.8)	43 (76.8)	28 (75.7)
PTT involvement (lesion or enhancement), n = 61	29 (87.9)	32 (86.5)	20 (83.3)	50 (89.3)	32 (86.5)

REFERENCES

1. Vainio K. The rheumatoid foot. A clinical study with pathological and roentgenological comments. Ann Chir Gynaecol 1956;45 Suppl 1:39.
2. Michelson J, Easley M, Wigley FM, Hellmann D. Posterior tibial tendon dysfunction in rheumatoid arthritis. Foot Ankle Int 1995;16:156-61.
3. Arnett FC, Edworthy SM, Bloch DA, et al. The American Rheumatism Association 1987 revised criteria for the classification of rheumatoid arthritis. Arthritis Rheum 1988;31:315-24.
4. Steinbrocker O, Traeger CH, Batterman RC. Therapeutic criteria in rheumatoid arthritis. JAMA 1949;140:659-62.
5. Rosenberg ZS, Cheung Y, Jahss MH, Noto AM, Norman A, Leeds NE. Rupture of posterior tibial tendon: CT and MRI imaging with surgical correlation. Radiology 1988;169:229-35.
6. Jahss MH. Tendon disorders of the foot and ankle. In: Jahss MH, editor. Disorders of the foot and ankle: medical and surgical management. 2nd ed. Philadelphia: WB Saunders; 1991:1461-513.
7. Kirkham BW, Gibson T. Comment on the article by Downey, et al [letter]. Arthritis Rheum 1989;32:359.
8. Keenan MAE, Peabody TD, Gronley JK, Perry J. Valgus deformities of the feet and characteristics of gait in patients who have rheumatoid arthritis. J Bone Joint Surg Am 1991;73:237-47.
9. Bouysset M, Tavernier T, Tebib J, et al. CT and MRI evaluation of tenosynovitis of the rheumatoid hindfoot. Clin Rheumatol 1995;14:303-7.
10. Jernberg ET, Simkin P, Kravette M, Lowe P, Gardner G. The posterior tibial tendon and the tarsal sinus in rheumatoid flat foot: magnetic resonance imaging of 40 feet. J Rheumatol 1999; 26:289-93.
11. Kitaoka HB, Luo ZP, An KN. Effect of the posterior tibial tendon on the arch of the foot during simulated weightbearing: biomechanical analysis. Foot Ankle Int 1997;18:143-6.
12. Otis JC. Clinical and applied biomechanics. In: Myerson MS, editor. Foot and ankle disorders. Philadelphia: WB Saunders Company; 2000:181-94.