

Case Report

Polyarteritis Nodosa Presenting as Acute Leg Ischemia

EMMANUEL HÉRON, JEAN-NOËL FIESSINGER, and LOÏC GUILLEVIN

ABSTRACT. We describe a 33-year-old hypertensive woman with otherwise apparently good health, in whom acute leg ischemia by acute occlusion of the 3 infrapopliteal arteries led to the diagnosis of polyarteritis nodosa (PAN). Angiography and ultrasound imaging showed multiple microaneurysmal and thrombotic lesions, notably in the kidneys and the 4 extremities. Cutaneous biopsy showed necrotizing angitis. She was treated with corticosteroids. Ischemia improved progressively, with normal walking after several months. Three points were remarkable in this case of PAN: (1) its unusual presentation; (2) the absence of constitutional symptoms despite the diffuse distribution of vascular lesions; (3) the good visualization of peripheral microaneurysms by ultrasonography (US), suggesting a potential diagnostic interest for US examination of the limbs in PAN. (*J Rheumatol* 2003;30:1344–6)

Key Indexing Terms:

POLYARTERITIS NODOSA

ACUTE ISCHEMIA

ULTRASONOGRAPHY

Polyarteritis nodosa (PAN) is a systemic vasculitis involving exclusively small and medium size arteries¹, which causes vessel stenoses, thromboses, and microaneurysms². Despite the systemic distribution of arterial lesions, reports of limb ischemia have been exceptional in this vasculitis. We describe an unusual case of PAN with diffuse visceral and peripheral arterial lesions presenting as acute leg ischemia in a patient who was otherwise in good health.

CASE REPORT

A 33-year-old Afro-Caribbean woman presented to the emergency department of our hospital in June 1998 with sudden coldness and paresthesia of the right foot. She had a history of arterial hypertension discovered in 1988, complicated by malignant hypertension in 1992 (headache and convulsions) shortly after a treatment interruption. The maximum systolic blood pressure recorded was 240 mm Hg. Renal ultrasound (US) scans in 1992 and 1994 and abdominal tomodensitometry in 1996 revealed segmental areas of renal atrophy, and a renal biopsy in 1997 showed tubulointerstitial lesions with no glomerular abnormality. A diagnosis of interstitial nephropathy secondary to vesico-ureteral reflux was suggested. She did not undergo renal angiography at this time because she felt well and her hypertension was well controlled with 5 mg/day amlodipine, 50 mg/day losartan, and 1 cp/day Moduretic® (5 mg amiloride plus 50 mg hydrochlorothiazide per cp), a treatment that she took regularly until leg ischemia occurred. Examination in the emergency room showed abolition of the right pedal

and posterior tibial pulses and of the left radial pulse; the other peripheral pulses were present. She was otherwise in good condition, with a temperature of 37°C, arterial blood pressure of 120/80 mm Hg, normal electrocardiogram, and no other abnormal clinical sign or symptom. Arterial thromboembolism was clinically suspected and intravenous heparin was given. Standard laboratory test results were normal apart from a slightly elevated erythrocyte sedimentation rate of 40 mm/h. Creatinemia was 90 µmol/l. No proteinuria or hematuria was found. Aorto-arteriography showed diffuse vascular abnormalities sparing the large arteries: the right and left renal arterial beds showed microaneurysms, thromboses of division branches, and renal infarcts (Figure 1); numerous microaneurysms were observed in the medium size and small arteries of the lower limbs, and distal occlusion of the peroneal and tibial arteries of the right leg was also observed (Figure 2). Thrombolytic therapy was considered to be contraindicated because of the thrombotic (not embolic) appearance of these lesions, and fear of aneurysmal rupture. The trunks of the aorta, iliac, femoral, and popliteal arteries were angiographically normal. No angiography of the upper limbs was performed, but US examination showed aneurysmal lesions on both radial arteries, and occlusion of the left one at the level of the wrist. The mean diameter of peripheral microaneurysms was roughly 5 mm on US scan (Figure 3). Histological examination of a biopsy sample from the left radial artery showed only fibrosis, but biopsy of a small cutaneous nodular lesion of the right leg revealed necrotizing angitis. The diagnosis of PAN was strongly suggested on imaging studies because of the size of involved arteries and the presence of multiple aneurysms¹, confirmed by the pathological findings of the skin biopsy. No antibodies against hepatitis B and C viruses, human immunodeficiency virus, or parvovirus B19 were detected. Antineutrophil cytoplasmic antibody testing was negative. She was treated with corticosteroids for 1 year, starting at a dose of 1 mg/kg/day prednisone. Leg ischemia gradually improved following the development of collaterals (tibial and peroneal arteries did not recanalize) and after 6 months, she was able to walk 1 km without plantar claudication. After 1 year, walking distance was not limited at normal speed. The appearance and size of the tibial microaneurysms on US scans remained unchanged.

DISCUSSION

PAN is a well known form of systemic inflammatory angitis, with a low prevalence of about 6 in 100,000 people³. Histologically, the disease is characterized by necrotizing

From the Service de Médecine Interne, C.H.N.O. des Quinze-Vingts, Paris; Service de Médecine Vasculaire, Hôpital Européen Georges Pompidou, Paris; and Service de Médecine Interne, Hôpital Avicenne, Bobigny, France.

E. Héron, MD, Service de Médecine Interne, C.H.N.O. des Quinze-Vingts; J.N. Fiessinger, MD, Service de Médecine Vasculaire, Hôpital Européen Georges Pompidou; L. Guillevin, MD, Service de Médecine Interne, Hôpital Avicenne.

Address reprint requests to Dr. E. Heron, Service de Médecine Interne, Centre Hospitalier National d'Ophthalmologie des Quinze-Vingts, 28 rue de Charenton, 75571 Paris Cedex 12, France.

E-mail: heron@quinze-vingts.fr

Submitted June 28, 2002; revision accepted November 21, 2002.

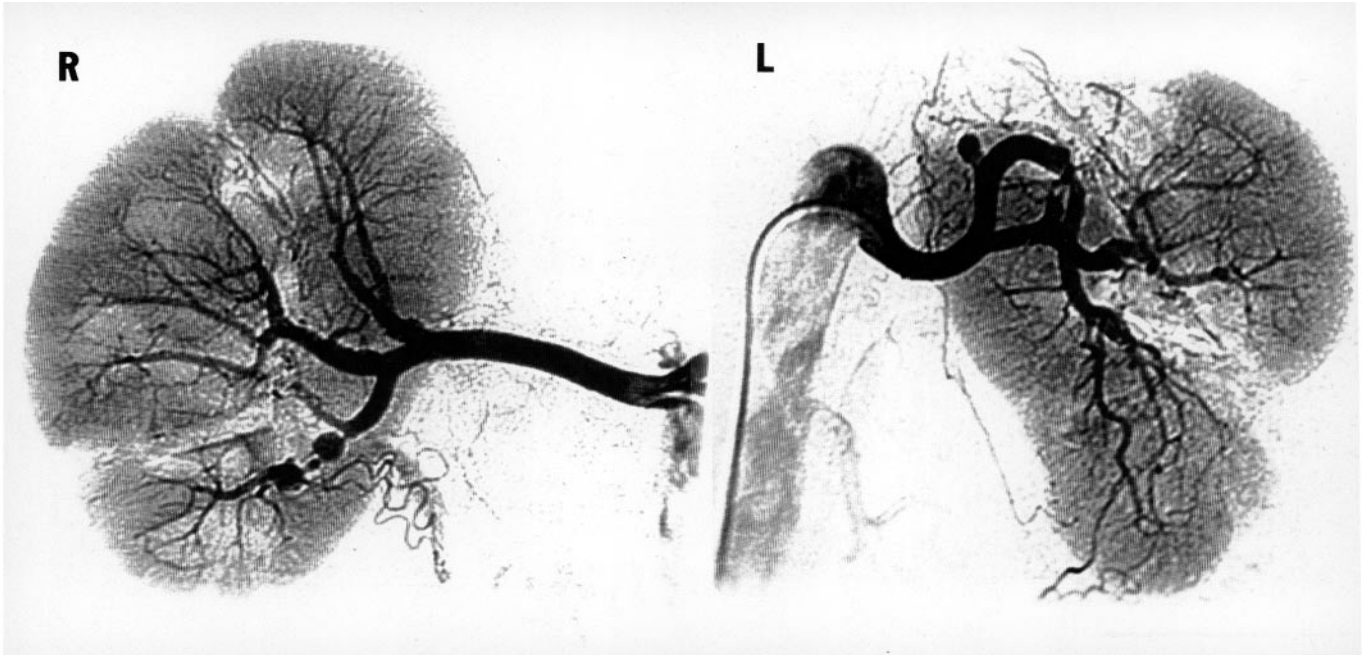


Figure 1. Renal arteriography showing microaneurysms, stenoses, and segmental branch occlusions involving the right and left renal artery beds, with hypoperfused parenchymal areas (mainly right kidney) and renal infarcts (mainly left kidney).

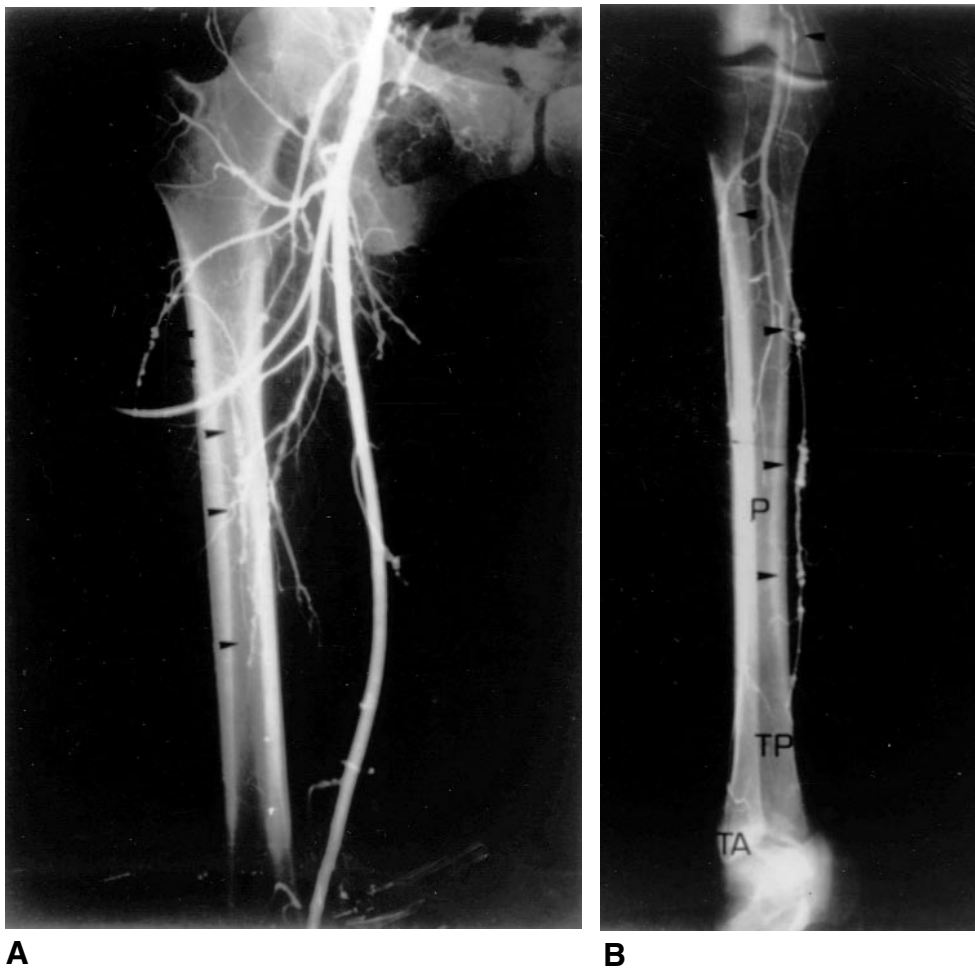


Figure 2. Arteriography of the right lower limb showing multiple microaneurysms involving small and medium size arteries (arrows), i.e., the division branches of the femoral profundis and femoral superficialis arteries, the leg arteries and distal occlusion of the 3 main leg arteries: anterior tibial artery (TA), posterior tibial artery (TP), peroneal artery (P). Labels are placed at the areas of occlusion.

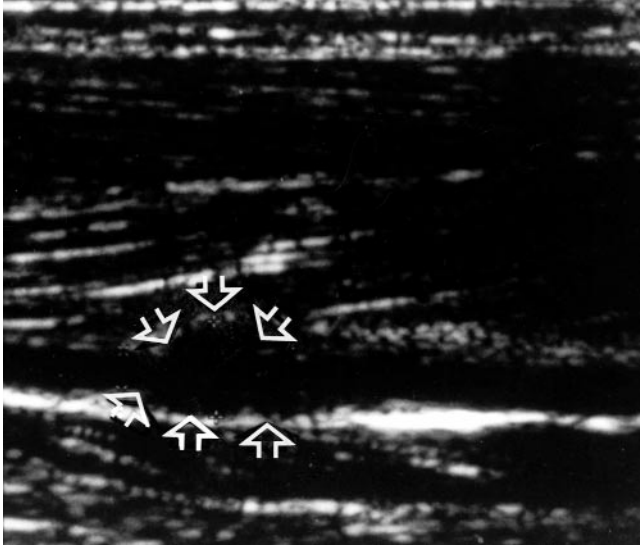


Figure 3. Ultrasound scanning showing a 5.2 mm diameter aneurysm (arrows) on a 2.2 mm tibial artery.

fibrinoid panarteritis, with a segmental distribution on small and medium size arteries, leading to microaneurysm formation and organ infarction. Its clinical expression mainly depends on the location of affected vessels and the degree of damage. Fever, weight loss, mononeuritis multiplex, and visceral manifestations dominate the clinical features of PAN⁴. Aneurysmal rupture is relatively rare and mainly causes visceral hemorrhages from complicated mesenteric or renal arterial lesions⁵⁻⁷. We found in the literature only 2 case reports of sudden limb ischemia complicating PAN. Hasaniya, *et al*⁸ described a case of PAN revealed by bilateral rupture of tibial artery microaneurysms with acute compartment syndrome of the legs. Brochot, *et al*⁹ reported a case of PAN with hand ischemia in which arteriography of the upper limbs revealed numerous microaneurysms and occlusions of the hand arteries. Our case is thus exceptional by its mode of revelation, and also by the disease history. Indeed, angiography findings explain the kidney abnormalities discovered in 1992, and indicate that the patient's hypertension was secondary to renal ischemia. Thus, severe systemic artery lesions developed over a period of at least 10 years (diagnosis of hypertension) in a paucisymptomatic clinical context that is unusual in this disease.

Autopsy studies have shown specific changes in the visceral arteries (renal, hepatic, gastrointestinal) in almost 80% of cases and in the peripheral arteries in 20 to 27% of cases⁸. Visceral angiography is now the reference imaging test¹⁰ for the diagnosis of PAN, and shows renal and/or celiomesenteric microaneurysms in about 50% of cases in

patients with abdominal symptoms¹¹. Aneurysmal lesions are present in 61% of abnormal angiograms in patients with this condition², and the presence of an aneurysm has a specificity of 90% for the diagnosis of PAN¹². Because the presence of peripheral aneurysms has *a priori* the same high specificity of visceral aneurysms for PAN, we suggest that US examination of the extremities could be worthwhile in the diagnostic strategy of this disease. Indeed, a positive noninvasive US examination for peripheral microaneurysms could make an invasive visceral arteriogram unnecessary in patients suspected of systemic vasculitis. The sensitivity of this diagnostic approach should be tested prospectively, as there are no data on the frequency of peripheral aneurysms revealed by modern imaging in this condition.

REFERENCES

- Jennette C, Falk R, Andrassy K, et al. Nomenclature of systemic vasculitides. Proposal of an international consensus conference. *Arthritis Rheum* 1994;37:187-92.
- Stanson AW, Friese JL, Johnson CM, et al. Polyarteritis nodosa: spectrum of angiographic findings. *Radiographics* 2001;21:151-9.
- Conn DL, Hunder GG. Necrotizing vasculitis. In: Kelley WN, Harris ED, Ruddy S, Sledge CB, editors. *Textbook of rheumatology*. 2nd ed. Philadelphia: WB Saunders; 1985:1137-66.
- Guillevin L, Lhote F, Gayraud M, et al. Prognostic factors in polyarteritis nodosa and Churg-Strauss syndrome. A prospective study in 342 patients. *Medicine* 1996;75:17-28.
- Dave SP, Reis ED, Hossain A, Taub PJ, Kerstein MD, Hollier LH. Splenic artery aneurysm in the 1990s. *Ann Vasc Surg* 2000; 14:223-9.
- Sautter T, Trinkler FB, Sulser T, Schopke W, Hauri D. Spontaneous perirenal hemorrhage after rupture of an aneurysm in case of polyarteritis nodosa along with anuric renal failure. Case report and review of the literature. *Urol Int* 1997;59:188-90.
- Choy CW, Smith PA, Frazer C, Jeffrey GP. Ruptured hepatic artery aneurysm in polyarteritis nodosa: a case report and literature review. *Aust NZ J Surg* 1997;67:904-6.
- Hasaniya N, Katzen JT. Acute compartment syndrome of both lower legs caused by ruptured tibial artery aneurysm in a patient with polyarteritis nodosa: a case report and review of the literature. *J Vasc Surg* 1993;18:295-8.
- Brochot P, Ban R, Eschard JP, Pennaforte JL, Etienne JC. Apport de l'artériographie des mains dans le diagnostic d'une périartérite noueuse: à propos d'une observation [abstract]. *Rev Med Int* 1991;12 Suppl 3:S186.
- Lightfoot RW, Michel BA, Bloch DA, et al. The American College of Rheumatology 1990 criteria for the classification of polyarteritis nodosa. *Arthritis Rheum* 1990;33:1088-93.
- Guillevin L, Lhote F. Polyarteritis nodosa related to hepatitis B virus. A prospective study with long-term observation of 41 patients. *Medicine* 1995;74:238-53.
- Hekali P, Kajander H, Pajari R, Stenman S, Somer T. Diagnostic significance of angiographically observed visceral aneurysms with regard to polyarteritis nodosa. *Acta Radiol* 1991;32:143-8.