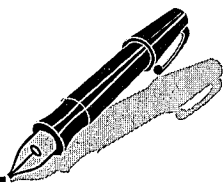


# Correspondence



## INSTRUCTIONS FOR LETTERS TO THE EDITOR

Editorial comment in the form of a Letter to the Editor is invited; however, it should not exceed 800 words, with a maximum of 10 references and no more than 2 figures (submitted as camera ready hard copy per Journal Guidelines) or tables and no subdivision for an Abstract, Methods, or Results. Letters should have no more than 3 authors. Full name(s) and address of the author(s) should accompany the letter as well as the telephone number, fax number, or E-mail address.

Contact. The Managing Editor, The Journal of Rheumatology, 920 Yonge Street, Suite 115, Toronto, Ontario M6J 3G7, CANADA. Tel: 416-967-5155; Fax: 416-967-7556; E-mail: jrheum@jrheum.com Financial associations or other possible conflicts of interest should always be disclosed.

## Arthroscopy and Psoriatic Knee Joint Synovitis

To the Editor:

Hoping to find the key to the "histologic signature" of psoriatic arthritis I started to read with great interest the work by Fiocco, *et al*<sup>1</sup>. Soon, my enthusiasm gave way to concern. That disturbing feeling of "calm passionate disapproval" so well put by the Scottish philosopher David Hume (1711–1776) to describe how we feel when we encounter human behavior that could be rendered wrong.

According to the authors' description, 20 adults with psoriatic and 19 with rheumatoid arthritis underwent arthroscopic examination and synovial biopsy of the knee joint. The sole purpose of the procedure, as it stands in the Methods section, was to compare the visual appearance and histologic morphology of the synovium in these 2 rheumatic diseases. Patients received spinal anesthesia and the procedure lasted an average of 45 minutes. The authors reported no complications.

There are several disquieting elements in this scenario. The first has to do with straightforward risk/benefit analysis. These human research participants draw no direct benefit from the operation (as described), leaving the substantial (certainly more than minor) increase over minimal risk to plain altruism. Such dose of altruism, when viewed under the utilitarian "social justice" umbrella, could have only been justified by the prospect of a monumental contribution to the advancement of generalizable knowledge. With that standard in mind this work in my view did not fulfill criteria<sup>2,3</sup>.

The phrase "all patients gave written informed consent" is the only reference devoted to human subject protection in this manuscript. There is no allusion to institutional review board (IRB) approval or any specific details or safeguards in the consent process, a fact that is remarkable in a study involving such an invasive intervention. Of course, what lurks behind the question is how much did the subjects really know about the purpose of the surgical procedure before they consented. Furthermore, how much undue pressure (coercion) they suffered by being both patient and subject at the same time, that is the issue of vulnerability, a problem expected to surface always in clinical settings but which acquires unusual relevance in the context of an invasive research procedure. In fact, the International Conference on Harmonisation (Brussels, 1996) defines vulnerable subjects very strin-

gently and includes individuals with incurable disease in that category<sup>4</sup>. A vulnerable subject should be given special protection including the requirement of either minor increase over minimal risk or direct benefit commensurate with the entailed risk before the research is approved. For this protocol, a non-therapeutic trial by ICH definition<sup>4</sup>, at least a mechanism of consent involving an impartial party (unrelated to the investigators) should have been in place.

In summary, we feel the work would be enhanced if the authors can expand on the following issues:

1. Which were the direct benefits (if any) to the subjects.
2. What were the considerations by the Institution's IRB leading to the approval of this study, and confirm that such approval process took place.
3. Which were the safeguards in place during the consent process to assure compliance with the principle of "respect for persons".

This report will benefit from this addition, which in turn will enhance the ethical acceptability of the data presented.

CARLOS D. ROSÉ, MD, Pediatric Rheumatologist, Professor of Pediatrics, Thomas Jefferson University, Chair, Institutional Review Board, duPont Children's Hospital, 1600 Rockland Road, PO Box 269, Wilmington, Delaware 19899, USA.

## REFERENCES

1. Fiocco U, Cozzi L, Chieco Bianchi F, et al. Vascular changes in psoriatic knee joint synovitis. *J Rheumatol* 2001;28:2480-6.
2. National Commission for the Protection of Human Subjects of Biomedical Research. The Belmont Report: Ethical principles and guidelines for the protection of human subjects of research. Washington, DC. DHEW Publication No. (OS) 78-0013 and (OS) n78-0014, 1979. World wide web: <http://ohsr.od.nih.gov/mpa/belmont>
3. World Medical Association. Declaration of Helsinki, 18th WMA General Assembly, Helsinki, Finland, June 1964. Amended 52nd WMA General Assembly, Edinburgh, Scotland, October 2000. <http://www.wma.net>
4. International Conference on Harmonisation. ICH harmonized tripartite guidelines: E6. Guideline for good clinical practice 1996. <http://www.ifpma.org.pdfifpma/e6.pdf>

## Dr. Fiocco, *et al*, reply

To the Editor:

Dr. Rosé raises some important issues in view of the increasingly extensive use of invasive diagnostic and therapeutic procedures in rheumatology.

As regards his points 1 and 2 ("Which were the direct benefits to the subjects"; "What were the considerations by the institution's IRB leading to the approval of this study..."): The aim of our study was to evaluate the diagnostic utility of standard arthroscopy equipped with an image analysis system, to examine the macroscopic appearance of synovial blood vessels in knees of patients with rheumatoid arthritis (RA) and psoriatic arthritis (PsA) who submitted to arthroscopic synovectomy for refractory knee joint synovitis (KJS). Therefore, video-recording of a standardized exploration of the joint, obtained before starting to remove synovium, was processed by dedicated software and used for blind examination<sup>1</sup>.

Everything that occurred after video-recording did not come within the scope of our report<sup>1</sup>. That these patients were arthroscopied for synovectomy rather than solely for research purposes makes a difference from the subject protection viewpoint. Unfortunately, that information was not highlighted in our manuscript.

Refractory KJS, defined as the persistence of active synovitis after at least 6 months of aggressive local and systemic medical management, is considered a proper indication for arthroscopic synovectomy, within early anatomic stages<sup>2</sup>. The serious longterm outcome of persistent KJS in RA clearly emerges from the recently reported incidence of knee joint arthroplasty, representing 68% of all disease related procedures, in a large series

of patients<sup>1</sup>. In the last decade, arthroscopic synovectomy has increasingly been extended to earlier disease phases<sup>4</sup>. Unfortunately, blind controlled studies are lacking and not easy to perform, for ethical reasons. Longterm longitudinal followup of the response to arthroscopic synovectomy using objective clinical<sup>3</sup>, ultrasound<sup>6</sup>, and magnetic resonance (MR)<sup>7</sup> outcomes have highlighted the importance of optimal diagnostic and therapeutic approaches, to slow down the intensity of synovitis before intervention and to prevent KJS relapses.

The introduction of new technologies including arthroscopy, high frequency and power Doppler ultrasound, and MRI can provide fundamental information for new management strategies and early surgical procedures<sup>8</sup>. Diagnostic arthroscopy is indicated when knee symptoms persist in a patient with an established diagnosis of inflammatory arthropathy, despite conventional local therapy for the knee and adequate control of the systemic process<sup>9</sup>. "Prearthroscopic" complications arise when diagnoses that cannot be established or treated by arthroscopy are neglected<sup>10</sup>.

As regards Dr. Rosé's point 3 ("Which were the safeguards in place during the consent process to ensure compliance with the principle of 'respect for persons'"), in the last 5 years, patients with persistent active KJS attending the Rheumatology Clinic at Padova General Hospital were entered into a protocol for management and followup of KJS supported by the Veneto Region Health authorities (670/01/96)<sup>1</sup>. Each time, separate written forms for informed consent for each specific therapeutic and diagnostic procedure are submitted to patients. Great importance is placed on patient empowerment<sup>11</sup>: to provide advice in such a way as to enable "prime" patients to ask for information they need<sup>12</sup>, to enable decisions to be made and to anticipate possible complications through provision of clear, specific information<sup>13</sup>. The *General Guidelines for Therapy* are followed with the aim to achieve remission, followed by timely strengthening exercises, and the identification of nonresponses<sup>8</sup>. Conventional radiology, ultrasound, and MRI are performed at entry and repeated according to the clinical picture and response to treatment during followup.

Suggested indications for arthroscopy in patients with inflammatory arthritis are, for example: symptoms unresponsive to medical treatment; symptoms disproportionate to clinical findings; and uncertain diagnosis<sup>9</sup>. Arthroscopic synovectomy is always done by consultant orthopedic surgeons in an operating room (OR) of a knee surgery department, in the presence of the rheumatologist who is aware of the patient's clinical condition. Diagnostic arthroscopy is now also performed by rheumatologists, in multidisciplinary day surgery (OR), under monitored anesthetic care, combined with local anesthesia if deemed appropriate<sup>14</sup>. Monitored anesthetic care allows possible coupling of diagnostic and therapeutic phases of arthroscopy, after recognition of specific intraarticular lesions requiring operative procedures, thus reinforcing the collaboration with orthopedic surgeons<sup>15,16</sup>.

Also considered are guidelines for practising arthroscopy by rheumatologists (to obtain data to support patient diagnosis; to document all elements of comprehensive management; to explain procedures; to select therapeutic arthroscopic procedures with due consideration; to prepare reports of procedures, and to ensure continuity of management)<sup>2,10</sup>.

We agree that ongoing discussion on this subject would certainly be useful, to enhance the principle of respect for persons.

UGO FIOCCO, MD; LUISELLA COZZI; SILVANO TODESCO, MD, Division of Rheumatology, Department of Medical and Surgical Sciences, University of Padova, Padova; ROBERTO NARDACCHIONE, MD, Knee Joint Surgery Unit, Abano Terme Hospital, Abano Terme; CRISTINA BOETTO, Nurse in Charge, Multidisciplinary Day Surgery, Padova General Hospital; PAOLO MORENI, MD, Department of Forensic Medicine, University of Padova; ANTONELLA ACCHETTI, MD; GABRIELE ARMELLIN, MD, Department of Anesthesia and Intensive Care, University of Padova, Padova, Italy.

## REFERENCES

1. Fiocco U, Cozzi L, Chieco Bianchi F, et al. Vascular changes in

psoriatic knee joint synovitis. *J Rheumatol* 2001;28:2480-6.

2. Arnold WJ, Kalunian K. Arthroscopic synovectomy by rheumatologists: time for a new look. *Arthritis Rheum* 1989;32:108-11.
3. Massardo L, Gabriel SE, Crowson CS, O'Fallon WM, Matteson EL. A population based assessment of the use of orthopedic surgery in patients with rheumatoid arthritis. *J Rheumatol* 2002;29:52-6.
4. Klug S, Wittmann G, Weseloh G. Arthroscopic synovectomy of the knee joint in early cases of rheumatoid arthritis: follow-up results of a multicenter study. *Arthroscopy* 2000;16:262-7.
5. Fiocco U, Cozzi L, Rigon C, et al. Arthroscopic synovectomy in rheumatoid and psoriatic knee synovitis: long-term outcome. *Br J Rheumatol* 1996;35:463-70.
6. Fiocco U, Cozzi L, Rubaltelli L, et al. Long term sonographic follow-up of rheumatoid and psoriatic proliferative knee joint synovitis. *Br J Rheumatol* 1996;35:155-63.
7. Ostegaard M. Quantitative magnetic resonance imaging as marker of synovial membrane regeneration and recurrence of synovitis after arthroscopic knee joint synovectomy: a one year follow up study. *Ann Rheum Dis* 2001;60:233-6.
8. Emery P. The optimal management of early rheumatoid disease: the key to preventing disability. *Br J Rheumatol* 1994;33:765-8.
9. Ike RW. Diagnostic arthroscopy. *Baillieres Clin Rheumatol* 1996;10:495-517.
10. Kalunian K, Moreland LW, Ike RW. Arthroscopy. In: Koopman WJ, editor. *Arthritis and allied conditions. A textbook of rheumatology*. 13th ed. Baltimore: William and Wilkins; 1997:103-15.
11. Malin N, Teasdale K. Caring versus empowerment: considerations for nursing practice. *J Adv Nursing* 1991;16:657-62.
12. Mitchell M. Constructing information booklets for day-case patients. *Ambulatory Surgery* 2001;9:37-45.
13. Redman BK. Patient education at 25 years: where we have been and where we are going. *J Adv Nursing* 1993;18:725-30.
14. Sa Rego MM, Watcha MF, White PF. The changing role of monitored anesthesia care in the ambulatory setting. *Anesth Analg* 1997;85:1020-36.
15. Ayril X, Dougados M. Rheumatological arthroscopy or research arthroscopy in rheumatology? *Br J Rheumatol* 1998;37:1039-41.
16. Committee on Ethics and Standards, Board of Directors of the Arthroscopy Association of North America. Suggested guidelines for the practice of arthroscopic surgery. *Arthroscopy* 2002;18:1.

---

## In Quest of the Holy Grail: Efficacy versus Effectiveness in Rheumatoid Arthritis

To the Editor:

In her intriguing editorial<sup>1</sup>, Dr. Maria E. Suarez-Almazor asked, "Are clinical trials enough for health care decision making?" She asserts that observational studies and surveys are helpful in determining the community effectiveness of drugs, while clinical trials can only determine a drug's efficacy. I agree that efficacy is necessary but not sufficient to ensure a drug's effectiveness in community practice.

The model of community effectiveness (community effectiveness = efficacy × access × diagnosis × recommendation × adherence) is useful because it emphasizes that multiple variables, in addition to clinical efficacy, influence effectiveness. However, with this model, poor community effectiveness scores are more reflective of current practice of medicine than the effectiveness of the treatments. For example, under Dr. Suarez-Almazor's base scenario (1.0 × 0.80 × 0.85 × 0.85 × 0.70) even a treatment that is 100% effective will be given to less than 50% of patients, and under the more optimistic scenario (1.0 × 0.90 × 0.90 × 0.90 × 0.80) this increases to only 58%. I believe that disease prevalence should also be considered in the evaluation of com-

munity effectiveness. Since about 2.1 million people in the US have rheumatoid arthritis, a community effectiveness value of 24% would still benefit a half million patients.

Dr. Suarez-Almazor compares the efficacy and effectiveness of 4 disease modifying antirheumatic drugs (DMARD), methotrexate, leflunomide, etanercept, and anakinra, reported in 3 studies<sup>2-4</sup>. However, comparison of these studies is questionable, because the studies are widely different in their objectives, methods, and patient populations; therefore, their results cannot be directly compared. Both the leflunomide and etanercept trials were placebo controlled (that is, patients were prohibited from receiving any DMARD<sup>2,3</sup>). The anakinra trial included an active control of methotrexate<sup>4</sup>. The anakinra trial tested the hypothesis that anakinra in combination with methotrexate is better than methotrexate alone. The other 2 trials test the hypothesis that leflunomide or etanercept is better than no DMARD. It is inappropriate to compare the treatment effects across clinical trials with such divergent objectives. The methods used in the studies also differ. In the leflunomide trial, response rates were calculated after 12 months of therapy, while in the etanercept and anakinra studies response rates were calculated after 6 months. The leflunomide and etanercept trials used a last-observation-carried-forward (LOCF) imputation technique for dropouts and missing data, while the anakinra trial used a nonresponder imputation technique. The LOCF method can result in higher response rates. All these differences confound the comparison of these studies.

Dr. Suarez-Almazor acknowledges that her example is overly simplistic since it is based only on efficacy data and does not consider other important factors, such as toxicity, joint damage, or quality of life. I believe that it is very important to consider the safety profile of an agent when calculating community effectiveness, since a safer product may be more likely to be adopted, increasing the community effectiveness.

In conclusion, I agree with Dr. Suarez-Almazor's hypothesis, that results from a clinical trial may not predict how effective a therapy will be in the clinical setting. However, comparison of clinical effectiveness and efficacy must be done among similar studies. We need to determine how we can increase the adoption of new therapies with good efficacy and safety profiles to maximize the benefit to patients.

ROY FLEISCHMANN, MD, Clinical Professor of Medicine, University of Texas Southwestern Medical Center; Radiant Research, 5939 Harry Hines Blvd., Dallas, Texas 75235, USA.

Dr. Fleischmann is an advisor/consultant and has performed clinical studies for Aventis, Immunex, Wyeth Ayerst, and Amgen Pharmaceuticals.

## REFERENCES

1. Suarez-Almazor M. In quest of the holy grail: efficacy versus effectiveness in rheumatoid arthritis. *J Rheumatol* 2002;29:209-11.
2. Strand V, Cohen S, Schiff M, et al. Treatment of active rheumatoid arthritis with leflunomide compared with placebo and methotrexate. Leflunomide Rheumatoid Arthritis Investigators Group. *Arch Intern Med* 1999;159:2542-50.
3. Moreland LW, Schiff MH, Baumgartner SW, et al. Etanercept in rheumatoid arthritis. A randomized controlled trial. *Ann Intern Med* 1999;130:478-86.
4. Cohen SB, Moreland LW, Cush JJ, et al. Anakinra (recombinant interleukin-1 receptor antagonist): a large, placebo controlled efficacy trial of anakinra in patients with erosive rheumatoid arthritis disease [abstract]. *Arthritis Rheum* 2001; Suppl 44.

## Dr. Suarez-Almazor replies

*To the Editor:*

I appreciate Dr. Fleischmann's comments, and for the most part agree with him. The objective of the editorial was not to compare the efficacy or the effectiveness of disease-modifying drugs in rheumatoid arthritis (RA), which would require a thorough, systematic review of the trials with regard to

patient populations, benefits, and risks. Rather, I wanted to demonstrate with simple numerical examples the potential importance of health system and patient variables on the overall effectiveness of therapies in the community. These factors are often overlooked by clinical researchers, and are seldom mentioned in textbooks or reviews regarding the treatment of RA. It has been my experience that clinicians, researchers, and policy makers recognize the importance of access to health care or adherence to treatment. However, the extent to which these issues may influence overall effectiveness is often underestimated.

MARIA E. SUAREZ-ALMAZOR, MD, PhD, Associate Professor of Medicine, Baylor College of Medicine, Veterans Affairs Medical Center, 2002 Holcombe Blvd., Houston, Texas 77030, USA.

## SAPHO Syndrome and Transient Hemiparesis in a Child: Coincidence or New Association?

*To the Editor:*

The case report of SAPHO syndrome with transient hemiparesis in a child with clavicular osteitis<sup>1</sup> prompted us to briefly describe the opinion of German rheumatologists about the SAPHO syndrome and also to comment on the case. We regret that the German literature is no longer read or cited, thus being lost to international experience and knowledge, especially as far as clinical, radiologic, and histopathologic findings are concerned.

Our experience is based on this 3 dimensional analysis of a patient collective with the SAPHO syndrome, which we first published 2 years ago with 86 cases<sup>2</sup> and which presently includes 140 patients<sup>3</sup>. Our results, which could correct and enhance precision of the opinion of the last 15 years, proceed from the clinically decisive experience that this syndrome is not a nosologic entity and therefore cannot represent a diagnosis, but rather offers a heterogeneous picture of diseases with various symptom combinations, which are mainly kept together by the potential of pustular-psoriatic dermato-arthroskeletal associations<sup>4</sup>.

The 2 entities that predominantly present the SAPHO syndrome are as follows.

1. With 40% of all cases: "chronic recurrent multifocal osteomyelitis" (CRMO), which we have newly defined and characterized as "primary chronic poly-osteomyelitis" with "sympathetic arthritis"<sup>5</sup>, and which was expanded with the adult form<sup>6</sup>. Its histopathogenesis, starting as reactive osteomyelitis, equals a plasma cell-sclerotic process, which comprises 3 stages, mainly lympho-plasmacellular with ossifying periostitis, and which ends as "sclerotic osteomyelitis" (Garrè)<sup>7</sup>. Important for clinical evaluation is the early magnetic resonance imaging (MRI) finding of a partly extended, "cloudy," soft tissue edema surrounding the involved tubular, flat, and spinal bones: the parosseous inflammatory edema with infiltration and inflammatory affection of neighboring neural and vascular structures.
2. In 24% of our cases: the disease we described as "spondylarthritis hyperostotica pustulo-psoriatica"<sup>8</sup>. It appears in adults as a triad of sternocostoclavicular hyperostoses (SCCH), hyperostotic shaped spondylopathy, and pustulosis palmo-plantaris (psoriatica) (Ppp), and it corresponds pathogenetically to HLA-B27 negative enthesopathy.

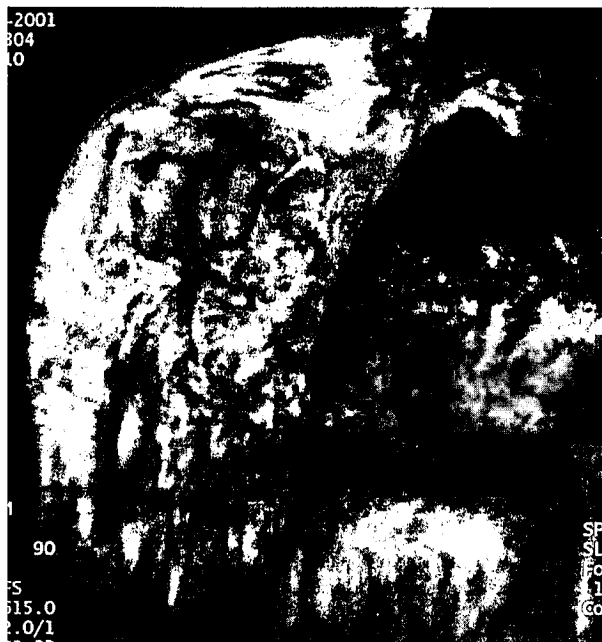Three additional smaller groups are dominated by the disease presentations of:

3. inflammatory syndrome of the anterior chest wall (ACW syndrome);
4. sternocostoclavicular hyperostoses (which are not found in childhood); and
5. arthroskeletal association with pustular acne.

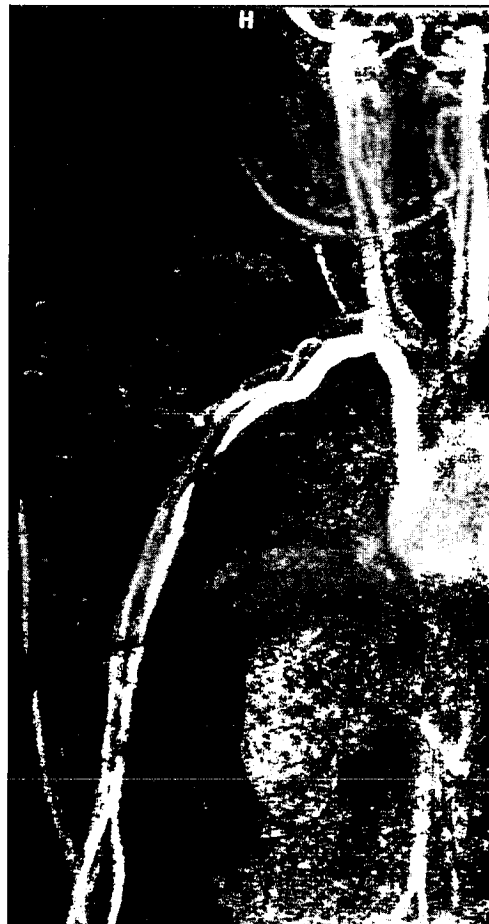The quality of CRMO-osteomyelitis, which remained unnoticed until recently, is its sometimes widely extended paraphlogistic inflammatory edema, which up to now has only been acknowledged in SCCH of the adult as a fibrotic mass stenosing the subclavian vein mediastinally or supra-

clavicularly. The early stage, which is already clinically complicated, can only be recognized by MRI. We have observed the following as clinically striking synovial, vascular, neurologic, or visceral neighboring complications close to metaphyseal, pelvic, vertebral, clavicular, or mandibular bony areas, which are affected by osteomyelitis<sup>2,3,5,6,9,10</sup>: retroperitoneal fibrosis in iliac osteitis, painful neuritis of the plexus, exudative pleuritis and pericarditis, as well as pneumonitis of the upper lobe and intercostal neuralgias in spondylitis of the lower cervical or the middle thoracic spine, an aortitis between sternal and vertebral osteomyelitis, and finally stenosis not only of the subclavian vein (as in SCCH) but also of the subclavian artery in a 9-year-old boy with primary chronic osteomyelitis of the right clavicle. This subacute osteomyelitis, lympho-plasmacellular in biopsy and negative in culture, had to be considered as a monostotic form of juvenile CRMO. The MRI showed a vast soft tissue swelling extending wide into the axillary area (Figure 1) and in this circumstance the MRI angiography revealed stenosis of the subclavian vein and artery (Figure 2), in the course of which the venous stenosis manifested the typical visible subcutaneous collateral circulation. Localization of the arterial stenosis did prevent a subclavian-steele syndrome. Our regimen with the effective longterm combination therapy of azithromycin and calcitonin resulted in prompt healing of the initially voluminous, hyperostotic, periosteally ossifying and edematous surrounding process. This case is documented together with another 11 cases of the clavicular type, i.e., with 21% of our CRMO patient collective<sup>10</sup>. It resembles the case presentation of Vanin, *et al*<sup>9</sup> but without neurologic deficits.

The authors of the case report from Padua are searching for a cause of the transient hemiparesis of their patient. They assume a reversible ischemic neurologic deficit syndrome as the likely cerebral cause, yet could not detect the pathogenetic correlation with the clavicular osteomyelitis. According to our experience, we can postulate that an inflammatory process in the neighborhood of the clavicular osteomyelitis could cause thrombosis or stenosis of an artery, as a possible explanation for an ischemic event of the cerebrum. Moreover, in our opinion, we would classify this patient among the SAPHO syndrome as a juvenile CRMO with primary chronic osteomyelitis of the clavicle.



**Figure 1.** Chronic recurrent multifocal osteomyelitis of the right clavicle. Note the vast soft tissue swelling around the bone extending wide into the axillary area (spin echo T1 weighted, fat suppression MRI, after intravenous gadolinium-DTPA).



**Figure 2.** Contrast enhanced MRI angiography shows a stenosis of the subclavian artery and vein.

FRITZ SCHILLING, Prof. Dr. med., Klinische und radiologische Rheumatologie, Klinikum der Johannes Gutenberg-Universität Mainz, Heibelstrasse 20, D-55127 Mainz, Germany; MARKUS UHL, Priv.-Doz. Dr. med., Kinderradiologie, Radiologische Universitätsklinik, Sektion Kinderradiologie, Mathildenstrasse 1, D-79106 Freiburg, Germany.

#### REFERENCES

1. Vanin E, Drigo P, Martini G, et al. SAPHO syndrome and transient hemiparesis in a child: Coincidence or new association? *J Rheumatol* 2002;29:384-7.
2. Schilling F, Kessler S. Das SAPHO-Syndrom: Klinisch-rheumatologische und radiologische Differenzierung und Klassifizierung eines Krankengutes von 86 Fällen. *Z Rheumatol* 2000;59:1-28.
3. Schilling F. SAPHO, CRMO und Spondylarthritiden. *Akt Rheumatol* 2001;26:297-302.
4. Schilling F. Das SAPHO-Syndrom — Nosologische Heterogenität und diagnostische Differenzierung. *Akt Rheumatol* 1998;23 Suppl 1:1-64.
5. Schilling F, Kessler S, Eckardt A, Stofft E. Die „sympathische Arthritis“ — ein Symptom der Chronischen rekurrenden multifokalen Osteomyelitis (CRMO). *Akt Rheumatol* 2001; 26:61-74.
6. Schilling F, Schweden F. Die chronische rekurrende multifokale Osteomyelitis im Erwachsenenalter: Adulte CRMO — Darstellung des osteosklerosierenden Prozesses anhand von vier eigenen Fällen

mit Pustulosis palmo-plantaris (Ppp.). *Osteologie* 1997;6:171-91.

- Schilling F. Die chronische rekurrende multifokale Osteomyelitis (CRMO). *Fortschr Röntgenstr* 1998;168:115-27.
- Schilling F, Kessler S. Die Spondylarthritis hyperostotica pustuloprosiatica: Nosologische Studie mit klinischer und radiologischer Darstellung innerhalb des SAPHO-Syndroms. *Fortschr Röntgenstr* 1998;169:576-84.
- Schilling F, Fedlmeier M, Eckardt A, Kessler S. Wirbelsäulenmanifestationen der chronischen rekurrenden multifokalen Osteomyelitis (CRMO). *Fortschr Röntgenstr* 2002; (in press).
- Schilling F, Kessler S, Eckardt A, et al. Die primär chronische Osteomyelitis der Clavicula: Eine Manifestation der chronischen rekurrenden multifokalen Osteomyelitis (CRMO) — Kasuistik. *Osteologie* 2002;11:96-123.

### Drs. Vanin and Zulian reply

To the Editor:

We appreciate the interesting comments by Dr. Schilling and Dr. Uhl about our report of a young boy with SAPHO syndrome and transient hemiparesis<sup>1</sup>.

We agree that SAPHO is probably not a unique nosologic entity, but rather a label for a spectrum of diseases with various symptom combinations. According to recent studies<sup>2,3</sup> and to the close similarity of the histologic picture, we think it is correct to include CRMO under the acronym SAPHO, at least until the pathogenetic underlying mechanisms are better understood.

The proposed classification of SAPHO syndrome<sup>4</sup> is quite interesting from many viewpoints. It is based on a multi-patient sample, includes both pediatric and adult forms, concerns not only clinical but also radiologic and histopathologic findings, and, finally, underlines the possibility of overlap conditions.

Up to now, many treatments have been tried both in adult and in pediatric patients with SAPHO syndrome and some seem to be effective<sup>2,5,6</sup>. Unfortunately, the heterogeneity of the patient population and the variety of drugs, dosages, and treatment durations make it difficult to draw definitive conclusions. Multi-center randomized controlled studies therefore, would be recommended.

Considering these issues on SAPHO syndrome, it would be important to standardize the diagnostic criteria and to establish common therapeutic approaches. An international consensus conference, in which specialists including pediatricians, rheumatologists, radiologists, and pathologists take part, giving their specialized contributions, could be the appropriate way to face this problem.

In terms of the pathogenetic link between the sternoclavicular joint (SCJ) lesion and the right transient hemiparesis suggested by Schilling and Uhl, we had considered the hypothesis of a thrombosis or stenosis of the subclavian artery as cause of an ischemic cerebral event and subsequent hemiparesis. Indeed, the right subclavian artery arises from the brachiocephalic artery behind the SCJ, runs behind the scalenus muscle, and then over the first rib. An important inflammatory process of the SCJ, involving the surrounding periarticular tissues, could, therefore, cause either stenosis of the artery, with a subclavian-steel syndrome, or thrombosis, which may cause an ischemic cerebral event. Unfortunately, this hypothesis cannot fully explain our case, since the hemiparesis would be expected on the left and not on the right side of the body and, indeed, would be more persistent.

The relationship between the SCJ lesion and the hemiparesis remains unclear to us and the hypothesis of a reversible ischemic neurologic deficit is still, in our opinion, the more likely one.

ELENA VANIN, MD; FRANCESCO ZULIAN, MD; Dipartimento di Pediatria, Università di Padova, via Giustiniani 3, 35128 Padova, Italy. E-mail: zulian@pediatria.unipd.it

### REFERENCES

- Vanin E, Drigo P, Martini G, et al. SAPHO syndrome and transient hemiparesis in a child: coincidence or new association? *J Rheumatol* 2002;29:384-7.
- Hayem G, Bouchaud-Chabot A, Benali K, et al. SAPHO syndrome: a long-term follow-up study of 120 cases. *Semin Arthritis Rheum* 1999;29:159-71.
- Beretta-Piccoli BC, Sauvain MJ, Gal I, et al. Synovitis, acne, pustulosis, hyperostosis, osteitis (SAPHO) syndrome in childhood: a report of ten cases and review of the literature. *Eur J Pediatr* 2000;159:594-601.
- Schilling F, Kessler S. Das SAPHO-Syndrom: Klinisch-rheumatologische und radiologische Differenzierung und Klassifizierung eines Krankengutes von 86 Fällen. [SAPHO syndrome: clinico-rheumatologic and radiologic differentiation and classification of a patient sample of 86 cases]. *Z Rheumatol* 2000;59:1-28.
- Kahn, MF, Khan MA. The SAPHO syndrome. *Baillieres Clin Rheumatol* 1994;8:333-62.
- Schilling F, Wagner AD. Azithromycin: an anti-inflammatory effect in chronic recurrent multifocal osteomyelitis? A preliminary report. *Z Rheumatol* 2000;59:352-3.

### CA15-3 and Cancer Associated Serum Antigen Assays Are Alternatives to the KL-6 Assay for Measuring Serum MUC-1 Levels in Patients with Interstitial Lung Disease Associated with Polymyositis/Dermatomyositis

To the Editor:

We read with great interest the report by Nakajima, *et al*<sup>1</sup> describing the utility of serum KL-6 antigen levels in the diagnosis and monitoring of interstitial lung disease (ILD) associated with rheumatoid arthritis, systemic sclerosis, and polymyositis/dermatomyositis (PM/DM). However, the KL-6 assay (ED046; Eisai Co. Ltd., Tokyo, Japan) is not readily available outside Japan. The KL-6 antibody recognizes an undefined sialylated carbohydrate side-chain epitope on the high molecular weight mucin MUC-1<sup>2</sup>. There are at least 3 other commercial assays available for measuring MUC-1, namely the tumor marker assays for CA15-3/BR, cancer associated serum antigen (CASA), and CA19-9. The CA19-9 assay (Bayer Diagnostics, Tarrytown, NY, USA) also recognizes sialylated carbohydrate side-chain epitopes (specifically sialyl Le<sup>x</sup>) on MUC-1<sup>2</sup>, while the former 2 assays employ monoclonal antibodies that recognize amino acid sequences on the central protein core of MUC-1, specifically "PDTRP" for the CA15-3/BR assay (Bayer Diagnostics) and "APDTR" for the CASA assay (Medical Innovations, Sydney, Australia)<sup>3</sup>.

We recently saw 2 patients with biopsy proven ILD associated with DM (first case) or PM (second case), with elevated serum CA15-3/BR and CASA levels but no evidence of an underlying malignancy. The first case had a video assisted thoracoscopic biopsy, which showed a predominant pattern of diffuse alveolar damage with a minor component of organizing pneumonitis; the second case had a right lower lobe wedge biopsy, which showed features consistent with usual interstitial pneumonitis (UIP). The peak levels of CA15-3/BR and CASA were 310 kU/l (reference range < 30) and 366 kU/l (reference range < 6) in the first case, and 148 kU/l and 146 kU/l in the second case. In both cases, the levels of CA15-3/BR and CASA normalized after successful immunosuppressive treatment of the lung disease, consistent with the findings of Nakajima, *et al*<sup>1</sup>. Interestingly, CA19-9 levels were not elevated in either case, with peak levels of 16 kU/l and 22 kU/l (reference range < 40), respectively. This is consistent with the findings of Yokoyama, *et al*<sup>4</sup> that the CA19-9 assay had a lower sensitivity (42.9%) than the KL-6 assay (74.3%) in patients with interstitial pneumonia. However, there are no published comparative studies between the KL-6, CA15-3/BR, and CASA assays in this setting.

We therefore suggest that the CA15-3/BR and CASA assays are more

readily available alternatives to the KL-6 assay for the measurement of serum MUC-1 levels in the diagnosis and monitoring of, at least, PM/DM associated ILD. However, it should be emphasized that elevated MUC-1 levels are also found in association with certain malignancies (especially ovarian and breast)<sup>5,6</sup>, which should therefore be considered if levels do not normalize following successful treatment of the lung disease.

RICHARD C.W. WONG, MBChB, MRCP(UK), FRACP, FRCPA, Staff Specialist in Clinical Immunology and Immunopathology, Division of Immunology, Queensland Health Pathology Service, Princess Alexandra and Royal Brisbane Hospitals; SANDRA KLINGBERG, B App Sc, Supervising Scientific Officer, Division of Chemical Pathology, Queensland Health Pathology Service, Royal Brisbane Hospital; ROBERT WILSON, BSc, MSc, Supervising Scientific Officer, Division of Immunology, Queensland Health Pathology Service, Princess Alexandra and Royal Brisbane Hospitals, Woolloongabba, QLD 4102, Australia.

#### REFERENCES

1. Nakajima H, Harigai M, Hara M, et al. KL-6 as a novel serum marker for interstitial pneumonia associated with collagen diseases. *J Rheumatol* 2000;27:1164-70.
2. Kohno N. Serum marker KL-6/MUC1 for the diagnosis and management of interstitial pneumonitis. *J Med Invest* 1999; 46:151-8.
3. McGuckin MA, Ramm LE, Joy GJ, Devine PL, Ward BG. Circulating tumour-associated mucin concentrations, determined by the CASA assay, in healthy women. *Clin Chim Acta* 1993; 241:139-51.
4. Yokoyama A, Kohno N, Kondo K, et al. Comparative evaluation of sialylated carbohydrate antigens, KL-6, CA19-9 and SLX as serum markers for interstitial pneumonia. *Respirology* 1998;3:199-202.
5. Devine PL, McGuckin MA, Ramm LE, Ward BG, Pee D, Long S. Serum mucin antigens CASA and MSA in tumors of the breast, ovary, lung, pancreas, bladder, colon, and prostate. A blind trial with 420 patients. *Cancer* 1993;72:2007-15.
6. Kubo M, Ihn H, Yamane K, et al. Serum KL-6 in adult patients with polymyositis and dermatomyositis. *Rheumatology* 2000;39:632-6.

#### Drs. Harigai and Kamatani reply

To the Editor:

We read with interest the letter by Dr. Wong, *et al* reporting alternative assay systems for serum MUC-1 levels in patients with polymyositis/dermatomyositis (PM/DM).

In our report<sup>1</sup>, we demonstrated that serum KL-6 levels were higher in patients with connective tissue diseases with interstitial pneumonitis (IP) than in those without IP. Our study included 57 patients with rheumatoid arthritis, 47 with systemic sclerosis, 21 with PM/DM, and 18 with systemic lupus erythematosus. Serum KL-6 levels were significantly higher in patients with connective tissue diseases with active IP (n = 43) compared to those with inactive IP (n = 18). Finally, serum KL-6 levels increased or decreased along with the deterioration or amelioration of IP, respectively (n = 13).

Although both CA15-3/BR and CASA decreased after successful treatment of IP in Dr. Wong's 2 cases, further analysis is obviously required to determine whether these methods could really be alternatives to KL-6. Serum levels of CA15-3/BR and CASA should be determined in patients with PM/DM as well as other connective tissue diseases with or without IP. Serum levels of these markers should also be compared between patients with active and inactive IP. After these analyses, one could claim that these methods are alternatives to KL-6.

One of Dr. Wong's cases revealed usual interstitial pneumonitis (UIP) by wedge biopsy. The UIP pattern, which is visible as honeycomb lung on chest computed tomography (CT), usually indicates chronic and inactive IP<sup>2</sup>. We have measured serum KL-6 levels in many PM/DM patients with honeycomb

lung by chest CT, and found that their KL-6 levels did not change during 3 or 4 years of observation. Their arterial blood oxygen levels did not decrease, and their clinical signs and symptoms and chest CT did not deteriorate. Therefore, it should be carefully determined whether the decrease of CA15-3/BR and CASA after immunosuppressive treatment in their UIP case is really associated with amelioration of IP.

Hopefully, the KL-6 assay will soon become available in other countries and its usefulness can be confirmed.

MASAYOSHI HARIGAI, MD, PhD; HIROSHI NAKAJI, MD; NAOYUKI KAMATANI, MD, PhD, Institute of Rheumatology, Tokyo Women's Medical University, 10-22 Kawada-cho, Shinjuku-ku, Tokyo 162-0054, Japan.

#### REFERENCES

1. Nakajima H, Harigai M, Hara M, et al. KL-6 as a novel serum marker for interstitial pneumonia associated with collagen diseases. *J Rheumatol* 2000;27:1164-70.
2. Hirakata M, Nagai S. Interstitial lung disease in polymyositis and dermatomyositis. *Curr Opin Rheumatol* 2000;12:501-8.



#### Cerebral Embolism Complicating Libman-Sacks Endocarditis — Full Recovery Using Recombinant Tissue Plasminogen Activator

To the Editor:

Ischemic stroke occurs in 10–20% of patients with systemic lupus erythematosus (SLE), and emboli from a cardiac source may occur in 70–90% of these patients. We describe a patient with SLE who had a thromboembolic stroke due to Libman-Sacks endocarditis and made a good recovery after early administration of recombinant tissue plasminogen activator (rTPA).

A 28-year-old woman was admitted with sudden complete aphasia and right side weakness that occurred in our lupus clinic waiting room. She had developed SLE 10 years previously, with renal, neuropsychiatric, and skin involvement and was treated with prednisolone, intravenous cyclophosphamide, azathioprine, and hydroxychloroquine. On admission, her SLE was in remission with hydroxychloroquine 200 mg and prednisolone 7.5 mg daily. She had no "traditional" cardiovascular risk factors and was not taking an oral contraceptive.

Clinical examination revealed blood pressure 130/60, pulse 80/min and regular. No cardiac murmur was detected. She had a right upper motor neuron facial weakness, a dense right hemiparesis, right side visual neglect, and right hemi inattention. There was increased tone and exaggerated tendon reflexes on the right and the right plantar was extensor. She was unable to walk. Fundoscopy was normal. Laboratory investigations revealed white blood cells 8200/mm<sup>3</sup>, hemoglobin 13.6 g/dl, platelets 171,000/mm<sup>3</sup>, erythrocyte sedimentation rate 2 mm/h, C-reactive protein < 5 mg/l, glucose 4.9 mmol/l, total cholesterol 5.6 mmol/l, triglycerides 2.08 mmol/l, creatinine 86 μmol/l, creatinine clearance 86 ml/min, total protein excretion 1.69 g/24 h, glomerular filtration rate 111.9 ml/min, antinuclear antibodies weakly positive, anti-DNA negative, extractable nuclear antigens were SSA/Ro positive; RNP, Sm, SSB/La negative; complement C3 1.12 g/l (normal 0.75–1.65) and

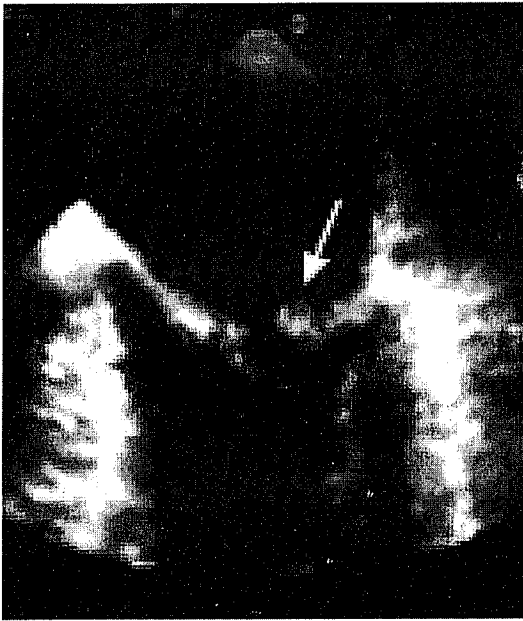

Figure 1. Transesophageal echocardiogram revealed a Libman-Sacks vegetation.

C4 0.45 g/l (normal 0.11–0.43); lupus anticoagulant negative, IgG, IgM and IgA anticardiolipin antibodies negative. Blood cultures yielded 8 bottles sterile. Chest radiograph was normal.

Transesophageal echocardiogram revealed a mass attached to the tip of the posterior mitral leaflet consistent with a Libman-Sacks vegetation (Figure 1). Carotid artery Doppler showed normal flow with no stenosis. An urgent brain magnetic resonance image (MRI) excluded an intracerebral hemorrhage, and showed a large infarct in the left external capsule. A second MRI 4 days later showed that the left external capsule infarcts were smaller, but there were other small infarcts in the posterior part of the claustrum, posterior parietal region, and much of the temporal lobe on this side.

A diagnosis of left middle cerebral artery territory infarction secondary to thromboembolism from the cardiac vegetations was made.

She made a rapid recovery following administration of rTPA intravenously at 0.9 mg/kg within 3 h of onset of the symptoms we had witnessed. Her speech rapidly returned to normal within 24 h. At discharge, she was walking well with only minor weakness of right hip flexion. Warfarin with a maintenance international normalized ratio of 2.0–3.0 was started. At followup 18 months later she has remained well with no residual neurological deficit. She remains negative for antiphospholipid antibodies (aPL).

In 1924, Libman and Sacks reported a unique nonbacterial valvular and mural verrucous endocarditis<sup>1</sup>. The incidence of valvular lesions in patients with SLE is about 40%<sup>2,3</sup>, although with transesophageal echocardiography this can be higher (61%)<sup>4</sup>. Valvular masses and thickening can occur together, can both be associated with valve dysfunction, most commonly regurgitation, and are believed to be characteristic of SLE. The mitral valve is mainly affected, followed by the aortic valve<sup>2,4,7</sup>. Although the majority of valvular lesions are clinically silent, complications include stroke, peripheral embolism, heart failure, and infective endocarditis, and may be the sole manifestation of Libman-Sacks endocarditis. Valve replacement is occasionally required.

Several studies have reported a 10 to 20% incidence of ischemic stroke in patients with SLE, with valvular vegetations, valvulitis, or left-heart thrombus identified as the cardioembolic source in 70 to 90% of those patients<sup>3,8</sup>. However, each patient should be assessed carefully to consider other etiologies. Patients with SLE can have cerebritis and vasculitis, and 30% of patients

with lupus have aPL that are associated with thrombosis. Furthermore, thromboembolism may result from accelerated atheroma.

Several investigators have correlated aPL with a higher prevalence of heart valve disease<sup>2,4,9,10</sup>. However, Roldan, *et al*, using transesophageal echocardiography, found no difference between aPL positive and aPL negative patients with SLE<sup>4</sup>. Vianna, *et al* compared antiphospholipid syndrome (APS) secondary to SLE with primary APS, and reported a higher incidence of valvular heart disease in the APS/SLE group of patients<sup>7</sup>. The significance of aPL in the pathogenesis of the valvular lesions in patients with SLE is not clear.

Our patient received rTPA within 3 h and recovered fully. Thrombolytic therapy with rTPA is approved for acute ischemic stroke from thromboembolic arterial occlusion. The recommendations are for patients over age 18 years, clinical diagnosis of stroke with a meaningful neurologic deficit, clearly defined time of onset of < 180 min before treatment, and a baseline computerized tomography scan showing no evidence of intracranial hemorrhage. rTPA is administered intravenously in a dose of 0.9 mg/kg (maximum 90 mg) with 10% of the total dose given as an initial bolus and the remainder infused over 60 min. rTPA has improved longterm quality of life by reducing disability and should be considered where logistically feasible<sup>12,13</sup>.

BEATRIZ JOVEN, MD; SUSANA MELLOR-PITA, MD; DAVID D'CRUZ, MD, FRCP; MOHAMMED SHARIEF, PhD, FRCP; MUNTHER KHAMASHTA, PhD, FRCP; GRAHAM R.V. HUGHES, MD, FRCP, Lupus Research Unit, The Rayne Institute, St. Thomas' Hospital, Lambeth Palace Road, London SE1 7EH, UK.

#### REFERENCES

1. Libman E, Sacks B. A hitherto undescribed form of valvular and mural endocarditis. *Arch Intern Med* 1924;33:701-37.
2. Khamashta M, Cervera R, Asherson RA, *et al*. Association of antibodies against phospholipids with heart valve disease in systemic lupus erythematosus. *Lancet* 1990;335:1541-4.
3. Roldan CA, Shively BK, Crawford MH. An echocardiographic study of valvular heart disease associated with systemic lupus erythematosus. *N Engl J Med* 1996;335:1424-30.
4. Nihoyannopoulos P, Gómez PM, Jayshree J, Loizou S, Walport MJ, Oakley CM. Cardiac abnormalities in systemic lupus erythematosus: association with raised anticardiolipin antibodies. *Circulation* 1990;82:369-75.
5. Mandell BF. Cardiovascular involvement in systemic lupus erythematosus. *Semin Arthritis Rheum* 1987;17:126-41.
6. Pope JM, Canny CLB, Bell DA. Cerebral ischemic events associated with endocarditis, retinal vascular disease, and lupus anticoagulant. *Am J Med* 1991;90:299-309.
7. Vianna JL, Khamashta MA, Ordi-Ros J, *et al*. Comparison of the primary and secondary antiphospholipid syndrome: a European multicenter study of 114 patients. *Am J Med* 1994;96:3-9.
8. Futrell N, Millikan C. Frequency, etiology, and prevention of stroke in patients with systemic lupus erythematosus. *Stroke* 1989; 20:583-98.
9. Ford PM, Ford SE, Lillcrap DP. Association of lupus anticoagulant with severe valvular heart disease in systemic lupus erythematosus. *J Rheumatol* 1988;15:597-600.
10. Cervera R, Font J, Pare C, *et al*. Cardiac disease in systemic lupus erythematosus: prospective study of 70 patients. *Ann Rheum Dis* 1992;51:156-9.
11. Roldan CA, Shively BK, Lau CC, Gurule FT, Smith EA, Crawford MH. Systemic lupus erythematosus valve disease by transesophageal echocardiography and the role of antiphospholipid antibodies. *J Am Coll Cardiol* 1992;20:1127-34.
12. Hacke W, Brodt T, Caplan L, *et al*. Thrombolysis in acute ischemic stroke: controlled trials and clinical experience. *Neurology* 1999;53 Suppl 4:S3-S14.
13. Albers GW, Amarenco P, Easton JD, Sacco RL, Teal P.

Antithrombotic and thrombolytic therapy for ischemic stroke. *Chest* 2001;119:300S-320S.

14. Adams HP, Brott TG, Furlan AJ, et al. Guidelines for thrombolytic therapy for acute stroke: a supplement to the guidelines for the management of patients with acute ischemic stroke. *Circulation* 1996;94:1167-74.

## Antiinflammatory Effect of Simvastatin in Patients with Rheumatoid Arthritis

To the Editor:

Statins, which inhibit 3-hydroxy-3-methylglutaryl co-enzyme A (HMG-CoA) reductase, are widely used to treat hyperlipidemia. Recent studies have suggested that statins not only lower plasma lipid levels but also reduce coronary events<sup>1,2</sup>, improve outcomes after cardiac transplantation<sup>3</sup>, and prevent osteoporosis or Alzheimer disease<sup>4,5</sup>. In particular, the immunosuppressive effect of statins has been highlighted. *In vitro* studies have revealed possible mechanisms of immunosuppression by statins, including suppression of natural killer cells<sup>6,7</sup>, regulation of DNA synthesis in cycling cells<sup>8</sup>, and an inhibition of monocyte chemotaxis<sup>9</sup>. These lines of evidence suggest a new clinical application of statins as an immunomodulator in autoimmune diseases such as multiple sclerosis and rheumatoid arthritis (RA). To address this issue, we serially evaluated immunological, inflammatory, and clinical variables in patients with RA taking simvastatin for coexisting hypercholesterolemia.

From March to July 2001, 8 patients with RA who also had hypercholesterolemia (> 232 mg/dl) requiring lipid-lowering treatment were enrolled in this study after giving written informed consent. They were 6 women and 2 men with a median age of 57 years (range 49–73). The median duration after the diagnosis of RA was 12 years (range 5–28). All patients except one were stage III or IV by Steinbrocker classification and class III or IV by RA classification. All patients took simvastatin 10 mg per day for 12 weeks. Other treatments, such as disease modifying antirheumatic drugs, glucocorticoids, and nonsteroidal antiinflammatory drugs for RA, had not been changed from 3 months before beginning simvastatin administration through the study peri-

od. Clinical and immunological variables were evaluated before simvastatin therapy and at the end of the administration of simvastatin (Table 1).

Simvastatin significantly reduced the number of tender joints ( $p = 0.02$ ) (Figure 1f) and patient self-assessment of disease activity on visual analog scale (VAS;  $p = 0.03$ ) (Figure 1b). However, the numbers of swollen joints (Figure 1e), patient self-assessment of pain on VAS (Figure 1a), physician global assessment of disease activity on VAS (Figure 1d), and Health Assessment Questionnaire (HAQ; Figure 1c) did not change significantly. Of interest was that erythrocyte sedimentation rate (ESR) and rheumatoid factor (RF) were significantly reduced (ESR,  $p = 0.01$ ; RF,  $p = 0.02$ ), and that C-reactive protein (CRP) showed a tendency to decrease ( $p = 0.12$ ) after simvastatin, especially during the first 4 weeks (Figure 2). Simvastatin was discontinued in 2 patients after 4 weeks and in one after 8 weeks because of their refusal. The reduction in the levels of ESR and CRP was attenuated after the discontinuation of simvastatin in these patients (Figure 2a, b, c). In addition, according to the American College of Rheumatology ACR20 response criteria<sup>10</sup>, 7 of 8 patients (88%) at 4 weeks, 5 of 6 patients (83%) at 8 weeks, and 4 of 5 patients (80%) at 12 weeks were defined as responders. On the other hand, addition of simvastatin did not significantly alter the immunological responses including the number of T cells, B cells and natural killer (NK) cells, the ratio between Th1 and Th2, and major histocompatibility complex class II (MHC-II) expression on T cells, B cells, and monocytes among patients.

The mechanism of immunosuppressive effect of statins is not fully understood; however, 2 distinct molecular mechanisms have been proposed recently. One is a repression of the induction of MHC-II expression induced by interferon- $\gamma$  on human endothelial cells and macrophages<sup>11,12</sup>. Another is a selective inhibition of the molecular association between leukocyte function antigen-1 (LFA-1) and intercellular adhesion molecule-1 by competitive binding to the L-site of LFA-1<sup>13</sup>. We analyzed the expression levels of MHC-II on T cells, B cells, and monocytes in peripheral blood from 8 patients to clarify the molecular mechanism of our results. However, we could not find significant changes of the MHC-II expression levels on these cells by simvastatin. The analysis of numbers of T cells, B cells, and NK cells showed no consistent changes at the end of the treatment.

This is the first clinical study evaluating the effect of statins on RA. The number of patients in our study was relatively small because we enrolled only

Table 1. Summary of changes in clinical and laboratory variables before versus at the end of simvastatin therapy. Indicated values are the median (range).

	Before	End	p
Tender joint count	8 (4–29)	6 (0–20)	0.02*
Swollen joint count	7 (2–19)	5 (0–15)	0.07
Patient assessment of pain (VAS)	4.5 (1.5–7.5)	4.4 (1.3–7)	0.29
Patient assessment of disease activity (VAS)	5.3 (2–7.5)	4.6 (1.5–7)	0.03*
HAQ	10 (1–18)	11.5 (0–18)	0.11
Physician assessment of disease activity (VAS)	4.1 (2.0–9.0)	3.5 (0.8–7.5)	0.18
RF, IU/ml	76 (20–525)	65 (20–370)	0.03* (4w 0.02*)†
ESR, mm/h	51 (27–96)	43.5 (23–107)	0.33 (4w 0.01*)†
CRP, mg/dl	2.2 (0.5–6.9)	1.6 (0.4–4.7)	0.18 (4w 0.12)†
CD3, $\mu$ l	1077 (471–1658)	1227 (400–1535)	0.89
CD19, $\mu$ l	104 (32–140)	95 (28–171)	0.89
CD56, $\mu$ l	202 (109–897)	167 (153–874)	0.5
HLA-DR+ CD3+/CD3+, %	11.3 (8.6–19.0)	13.3 (6.8–27.9)	0.13
HLA-DR+ CD19+/CD19+, %	97.2 (78.1–100)	98 (87.7–100)	0.69
HLA-DR+ CD14+/CD14+, %	99.7 (98.8–100)	99.8 (99.2–100)	0.8
Th1/Th2	6.8 (3.9–72.7)	5.8 (3.2–9.9)	0.16
Total cholesterol, mg/dl, mean $\pm$ SD	248 $\pm$ 21	189 $\pm$ 9.3	0.01*
HDL-cholesterol, mg/dl, mean $\pm$ SD	65.1 $\pm$ 14.2	70.1 $\pm$ 22.2	0.07

\*  $p < 0.05$ . † 4W: at 4 weeks.

VAS: visual analog scale; HAQ: Health Assessment Questionnaire; RF: rheumatoid factor; ESR: erythrocyte sedimentation rate; CRP: C-reactive protein.



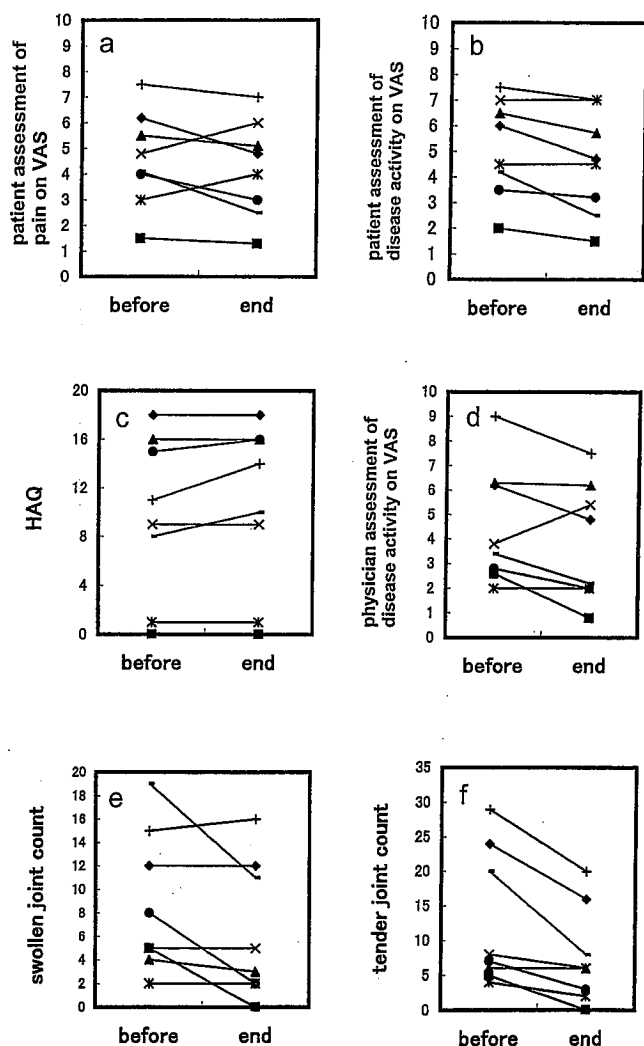


Figure 1. Changes in clinical variables of RA from beginning (“before”) to the end of simvastatin therapy. Y-axes show clinical variables of RA, including (a) patient assessment of pain on VAS, (b) patient assessment of disease activity on VAS, (c) HAQ score, (d) physician assessment of disease activity on VAS, (e) swollen joint count, (f) tender joint count. “Before” represents the data before simvastatin administration and “end” data at 12 weeks or at the end of the study for the dropouts. Patient assessment of pain on VAS (a), HAQ score (c), and physician’s assessment of disease activity on VAS (d) did not change between beginning and end of simvastatin therapy. However, patient assessment of disease activity on VAS (b) and tender joint count (f) improved significantly, in spite of no changes in swollen joint count (e).

those requiring lipid-lowering treatment among RA patients. In addition, most enrolled patients had a long history of RA and had severe joint deformities; therefore, it might not be appropriate to enroll these patients in the study evaluating effects of statins on active manifestations in RA. In spite of these conditions, our data suggest that simvastatin could suppress inflammatory variables as well as clinical symptoms in RA. Based on these findings, we will extend this study to evaluate the benefit of simvastatin in larger numbers of patients with active RA.

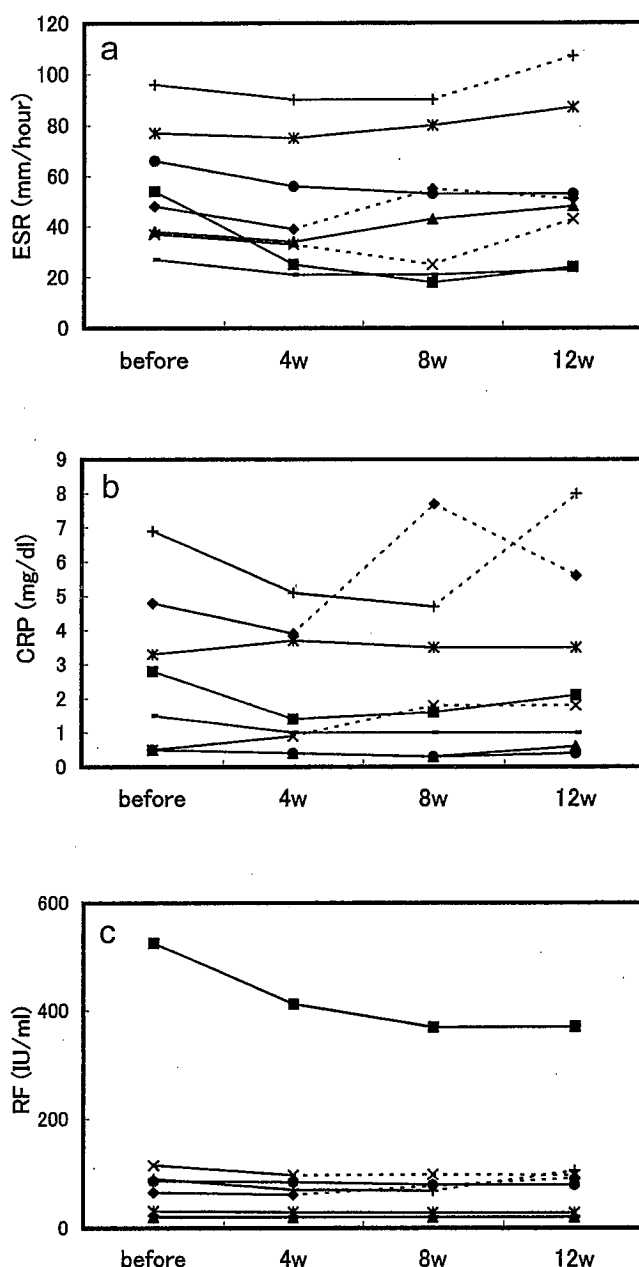


Figure 2. Changes in inflammatory variables of RA between beginning and at the end of simvastatin therapy. Y-axes show inflammatory variables of RA, including (a) ESR, (b) CRP, (c) RF. Solid lines show values during simvastatin therapy and broken lines show values after discontinuation of simvastatin. ESR, CRP, and RF levels showed tendency to decrease at the end of simvastatin therapy. After the discontinuation of simvastatin in 3 patients, the levels of ESR and CRP rose again.

HIROKO KANDA, MD, PhD; KEN HAMASAKI, MD; KANAE KUBO, MD, PhD; SHOKO TATEISHI, MD; AKI YONEZUMI, MD; YOSHINOBU KANDA, MD, PhD; KAZUHIKO YAMAMOTO, MD, PhD; TOSHIHIDE MIMURA, MD, PhD, Department of Allergy and Rheumatology, Department of Cell Therapy and Transplantation Medicine, University of Tokyo, 7-3-1 Hongo, Bunkyo-ku, Tokyo 113-8655, Japan.

## REFERENCES

1. Randomized trial of cholesterol lowering in 4444 patients with coronary heart disease: the Scandinavian Simvastatin Survival Study (4S). *Lancet* 1994;344:1383-9.
2. Ridker PM, Rifai N, Clearfield M, et al. Measurement of C-reactive protein for the targeting of statin therapy in the primary prevention of acute coronary events. *N Engl J Med* 2001;344:1959-65.
3. Kobashigawa JA, Katznelson S, Laks H, et al. Effect of pravastatin on outcomes after cardiac transplantation. *N Engl J Med* 1995;333:621-7.
4. Meier CR, Schlienger RG, Kraenzlin ME, Schlegel B, Jick H. HMG-CoA reductase inhibitors and the risk of fractures. *JAMA* 2000;283:3205-10.
5. Wolozin B, Kellman W, Ruosseau P, Celesia GG, Siegel G. Decreased prevalence of Alzheimer disease associated with 3-hydroxy-3-methylglutaryl coenzyme A reductase inhibitors. *Arch Neurol* 2000;57:1439-43.
6. Cutts JL, Scallen TJ, Watson J, Bankhurst AD. Role of mevalonic acid in the regulation of natural killer cell cytotoxicity. *J Cell Physiol* 1989;139:550-7.
7. Cutts JL, Bankhurst AD. Reversal of lovastatin-mediated inhibition of natural killer cell cytotoxicity by interleukin 2. *J Cell Physiol* 1990;145:244-52.
8. Doyle JW, Kandutsch AA. Requirement for mevalonate in cycling cells: quantitative and temporal aspects. *J Cell Physiol* 1998;137:133-40.
9. Kruezer J, Bader J, Jahn L, Hautmann M, Kubler W, Von Hodenberg E. Chemotaxis of the monocyte cell line U937: dependence on cholesterol and early mevalonate pathway products. *Atherosclerosis* 1991;90:203-9.
10. Felson DT, Anderson JJ, Boers M, et al. American College of Rheumatology preliminary definition of improvement in rheumatoid arthritis. *Arthritis Rheum* 1995;38:727-35.
11. Kwak B, Mulhaupt F, Myit S, Mach F. Statins as newly recognized type of immunomodulator. *Nature Med* 2000;6:1399-402.
12. Sadeghi MM, Tiglio A, Sadigh K, et al. Inhibition of interferon- $\gamma$ -mediated microvascular endothelial cell major histocompatibility complex class II gene activation by HMG-CoA reductase inhibitors. *Transplantation* 2001;71:1262-8.
13. Weitz-Schmidt G, Welzenbach K, Brinkmann V, et al. Statin selectively inhibit leukocyte function antigen-1 by binding to a novel regulatory integrin site. *Nature Med* 2001;7:687-92.