

# Correspondence



## INSTRUCTIONS FOR LETTERS TO THE EDITOR

Editorial comment in the form of a Letter to the Editor is invited; however, it should not exceed 800 words, with a maximum of 10 references and no more than 2 figures (submitted as camera ready hard copy per Journal Guidelines) or tables and no subdivision for an Abstract, Methods, or Results. Letters should have no more than 3 authors. Full name(s) and address of the author(s) should accompany the letter as well as the telephone number, fax number, or E-mail address.

Contact: The Managing Editor, The Journal of Rheumatology, 920 Yonge Street, Suite 115, Toronto, Ontario M6J 3G7, CANADA. Tel: 416-967-5155; Fax: 416-967-7556; E-mail: jrheum@jrheum.com Financial associations or other possible conflicts of interest should always be disclosed.

## Identification of Radiologic Healing Phenomena in Patients with Rheumatoid Arthritis

To the Editor:

The excellent and important paper of Rau, *et al*<sup>1</sup> includes 2 major flaws<sup>1</sup>. First, they state that some authors exclude the possibility of score reduction ("once an erosion, always an erosion"), referring to a personal communication of Dr. Sharp and myself. Second, they do not mention important sources of errors in assessing radiographs.

On several occasions I have discussed the assessment of radiographs with Dr. Sharp. We both prefer reading films without knowing the sequence and we record our observations making no assumptions. Therefore, we will, of course, record improvements if we see them. My appreciation of these "healing" phenomena can be seen at the end of my previous publication<sup>2</sup>.

There are several sources of errors when reading sequential radiographs. All "healings" (an unlucky term) are not real, but only apparent. Many differences in sequential radiographs have technical reasons. Erosions may vary in size due to small differences in projection.

Changes in kilovolts and time of exposure may largely influence the apparent density of bone. Looking at the figures in their article, I would not exclude the possibility of apparent, but not real, "healing."

I agree with the writers that deterioration and improvement should be scored separately and I have suggested it in my previous study<sup>2</sup>, without response.

ARVI LARSEN, MD, Kongsvinger Hospital, 2226 Kongsvinger, Norway.

## REFERENCES

1. Rau R, Wassenberg S, Herborn G, et al. Identification of radiographic healing phenomena in patients with rheumatoid arthritis. *J Rheumatol* 2001;28:2608-15.
2. Larsen A, Kvien TK, Schattenkirchner M, et al. Slowing of disease progression in rheumatoid arthritis patients during long-term treatment with leflunomide or sulfasalazine. *Scand J Rheumatol* 2001;30:135-42.

Dr. Rau, *et al* reply

To the Editor:

We thank Dr. Larsen for his critical comments giving us the opportunity to clarify some important issues.

1. With several exceptions<sup>1</sup>, in the vast majority of studies with x-ray evaluation, radiographs were read knowing the chronological sequence of the films. We are not aware of previous publications demonstrating a reduction of the radiographic score. We believe that the statement of van der Heijde, that a score reduction is impossible because erosions never heal<sup>2</sup>, was shared by all authorities including Drs. Sharp and Larsen. They expressed this opinion at a symposium on scoring methods in 1994<sup>3</sup>. Even in 2002 a negative progression rate is labeled "paradoxical" and explained by the fact that yearly progression rates usually are smaller than the minimal detectable change; the possibility of real improvement is not considered. Thus, RA is still perceived by the scientific community as a steadily progressive disease.

The observation of a score reduction in a certain percentage of patients in clinical trials investigating leflunomide and tumor necrosis factor inhibitors was a great surprise for the rheumatological community. Score reduction was first described when radiographs were read in unknown sequence to avoid the well known bias of steady progression. Today, Dr. Sharp states that while early studies concluded that negative progression rates were errors, today we can no longer assume that no healing will occur<sup>4</sup>. We appreciate that Dr. Larsen found a slight reduction in the mean Larsen score although he scored the films knowing the chronological sequence<sup>5</sup>.

2. We agree that there are several sources of error when reading sequential radiographs. Changes in erosion size due to differences in projection are possible. This source of error can be eliminated when following a lesion over several years: the examples selected for our study were chosen by Dr. Herborn from patients who were followed over several years with radiographs taken yearly. The mean time between 2 radiographs in this study was 4.8 years. Moreover, we took into account the size of the erosion and were able to demonstrate the formation of new bone filling in the gap (Figures 1, 4, and 5<sup>6</sup>). We agree that series of films would be more convincing. Series of healing have been published<sup>6,7</sup>. However, in this particular study only 2 radiographs had to be compared without knowing which was the first and which the second. A very troublesome problem is the difficulty to visualize on photographs what can be seen very clearly on radiographs. We invite everybody to review the original radiographs.

Certainly, the density of bone depends heavily on the exposure. But this holds true for the total bone. We addressed subchondral osteoporosis changing to local sclerosis; this phenomenon can be recognized in a relatively wide range of exposing conditions.

3. In our opinion, "healing" is not an unlucky term. The term is used after bone fractures, for example, where callus formation and deformity may be seen over years, or forever. Healing with scars is known in many organs. If "healing" is too far-reaching we would also accept the term "repair" for improvement of erosions. By the way: Charles Peterfy has described a case of healing seen on magnetic resonance imaging<sup>8</sup>.

Dr. Larsen's proposal to always state if a joint has improved, deteriorated, or is unchanged is very helpful since there are many situations where we see a change that is not sufficient to alter the score. However, very often it is extremely difficult to decide if there is an improvement or not. We agree that healing cannot be observed very frequently within clinical trials and that evaluation of healing is troublesome and time consuming.

ROLF RAU, MD, PHD, SIEGFRIED WASSENBERG, MD, PHD;  
GERTRAUD HERBORN, MD, PHD, Rheumaklinik Evangelisches  
Fachkrankenhaus, Rosenstr. 2, D-40882 Ratingen, Germany.

## REFERENCES

1. Wolfe F, Sharp JT. Radiographic outcome of recent-onset rheumatoid arthritis. *Arthritis Rheum* 1998;41:1571-82.
2. Van der Heijde D, Boonen A, Boers M, Kostense P, van der Linden S. Reading radiographs in chronological order, in pairs or as single

To continue  
please scroll  
to next page

films, has important implications for the discriminative power of rheumatoid arthritis clinical trials. *Rheumatology* 1999;38:1213-20.

3. Symposium on methods of scoring radiographic changes in rheumatoid arthritis. *J Rheumatol* 1995;22:1779-2003.
4. Sharp JT. An overview of radiographic analysis of joint damage in rheumatoid arthritis and its use in metaanalysis. *J Rheumatol* 2000;27:254-60.
5. Larsen A, Kvien TK, Schattenkirchner M, et al. Slowing of disease progression in rheumatoid arthritis patients during long-term treatment with leflunomide or sulfasalazine. *Scand J Rheumatol* 2001;30:135-42.
6. Rau R, Wassenberg S, Herborn G, et al. Identification of radiographic healing phenomena in patients with rheumatoid arthritis. *J Rheumatol* 2001;28:2608-15.
7. Rau R, Herborn G. Healing phenomena of erosive changes in rheumatoid arthritis patients undergoing disease-modifying antirheumatic drug therapy. *Arthritis Rheum* 1996;39:162-8.
8. Peterfy C. Magnetic resonance imaging of the wrist in rheumatoid arthritis. *Semin Musculoskelet Radiol* 2001;5:275-87.

### Cauda Equina Syndrome or a Complication of Total Hip Arthroplasty?

To the Editor:

We read with interest the case report by White and Harth<sup>1</sup>. As the authors note, there are only 4 cases (including their case) of cauda equina syndrome associated with lumbar pannus in the literature. We think, however, there are some drawbacks in their case report. A lumbar pannus at the level of L4-L5 may elucidate the etiology of the low back pain and unilateral lower extremity pain of the patient presented, but can hardly explain the progressive weakness of hip flexors innervated mainly by L2-L3 nerve roots. The cauda equina syndrome manifests itself as a complex of low back pain, sciatica, motor weakness of the lower extremities, saddle anesthesia, and sphincter disturbances. Although its timing is debatable, there is a consensus on surgical intervention in cauda equina syndrome<sup>2</sup>. It is not obvious, however, why the consulting neurosurgeon advised against surgical intervention in this case. We consider that the patient might not have cauda equina syndrome, for he had neither saddle anesthesia nor loss of sphincter control. Although a magnetic resonance image revealed a marked spinal stenosis as a possible cause of cauda equina compression, the acute onset of symptoms and sudden worsened condition of the patient after falling suggest other causative factors. What are the other reasonable causes? Two years ago, the patient had had a total hip arthroplasty (THA), on the same side as the symptoms; hence, the answer may lie in the late complications of THA.

Late infections after THA, manifested more than one year postoperatively, are most common in patients with rheumatoid arthritis (RA). With late infections, passive and active hip motion usually is quite painful; fever may be absent or only mild. Radiographs appear normal in the early stages of infection and later generally show changes that are difficult to distinguish from those seen with aseptic loosening. If a radiograph fails to reveal infection, a bone scan may be an alternative as it has good sensitivity for infection<sup>3</sup>. Hip aspiration should be performed if infection is suspected.

Aseptic loosening usually produces pain on weight bearing, which may be present in the thigh or groin. The anteroposterior and lateral radiographs must include the entire length of the stem and cement mass in the femur and must be inspected carefully and compared with previous films for changes indicating component loosening. However, loosening is complicated to interpret, i.e., whether the component in the radiographs is stable or loose and whether what is seen in the radiographs is producing symptoms. In a few patients there may be no evidence of radiolucency. In general, the diagnosis of loosening is made on the basis of examination, the symptoms, and interpretation of the changes noted in serial radiographs<sup>4</sup>.

Stem failure, especially if it is incomplete, can also easily be overlooked and sometimes is only appreciated in retrospect after the fracture is completed<sup>4</sup>.

The sciatic, femoral, and obturator nerves may be injured after THA. The most common cause of sciatic neuropathy is THA, and it usually becomes apparent perioperatively; however, some patients suffer a delayed onset of neuropathy of several years<sup>5</sup>. The most likely mechanism of injury is a stretching of the nerve by prosthetic dislocation, in which case blunt trauma may be an inciting factor. Therefore, a patient with RA presenting with acute lower extremity pain and weakness should undergo electromyography and nerve conduction studies to reveal whether the lesion is pre-ganglionic or postganglionic.

Although the likelihood of a dislocation or subluxation predisposing to nerve injury can be ruled out by only one hip radiograph, serial radiographs are warranted to confirm infection, aseptic loosening, stem failure, or stress fracture of the shaft of the femur. In some circumstances, bone scans, electromyography, and nerve conduction studies may help as well. A patient with RA who had THA presenting with ipsilateral acute lower extremity pain and weakness should have further investigations concerning the complications of THA before symptoms are attributed to any other cause.

ERDAL GILGIL, MD; TIRAJE TUNCER, MD; MEHMET I. ARMAN, MD, Professor, Division of Rheumatology, Faculty of Medicine, Akdeniz University, Antalya, Turkey.

### REFERENCES

1. White KP, Harth M. Lumbar pannus presenting as cauda equina syndrome in a patient with longstanding rheumatoid arthritis. *J Rheumatol* 2001;28:627-30.
2. Ahn UM, Ahn NU, Buchowski JM, Garrett ES, Sieber AN, Kostuik JP. Cauda equina syndrome secondary to lumbar disc herniation: a meta-analysis of surgical outcomes. *Spine* 2000;25:1515-22.
3. Sledge CB, Ranawat CS. Principles of reconstructive surgery. In: Ruddy S, Harris ED, Sledge CB, editors. *Kelley's textbook of rheumatology*. Philadelphia: WB Saunders; 2001:1699-788.
4. Harkess JW. Arthroplasty of hip. In: Canale ST, editor. *Campbell's operative orthopaedics*. Vol. 4. St. Louis: Mosby; 1998:296-471.
5. Yuen EC, Olney RK, So YT. Sciatic neuropathy: clinical and prognostic features in 73 patients. *Neurology* 1994;44:1669-74.

### Drs. Harth and White reply

To the Editor:

We thank Dr. Gilgil and colleagues for their interest in our article<sup>1</sup>. Their attribution of our patient's clinical course to a late complication of a total hip arthroplasty (THA) is ingenious but unconvincing. Our patient had weakness of hip flexors, abductors, quadriceps, dorsiflexors, and plantar flexors of the right lower limb; in other words, he had weakness of muscles innervated partially or wholly by L3, L4, L5, and S1. The images we obtained showed evidence of disease involving the vertebral body of L2, the interspinous ligaments at L1-L2 and lower levels, and a pannus at L4 on the right. All this suggests widespread involvement in the lumbosacral spine, in keeping with the observed weakness and loss of reflexes. The cauda equina was not completely involved, thus explaining the absence of saddle anesthesia and sphincter involvement.

Gilgil, *et al* discuss the complications of THA at length, but we are not sure which one they suggest fits the case. Infection is highly unlikely to produce the extensive motor weakness we observed. The same applies to a stem failure, which we could not demonstrate, nor could we show prosthetic dislocation. The sciatic, femoral, and obturator nerves may be injured after THA but we would have to postulate that this happened to all of them at once, 2 years after the operation took place. None of these proposed scenarios seems likely.

Finally, Gilgil, *et al* questioned the reluctance of the neurosurgical consultant to proceed with surgery. They cite a consensus on treatment of

cauda equina injury as a result of lumbar disc disease. That, however, is a very different proposition from that of intervening in a chronic granulomatous disease such as rheumatoid arthritis extensively involving the lumbar spine.

MANFRED HARTH, MD, FRCPC; KEVIN P. WHITE, MD, PhD, FRCPC,  
Division of Rheumatology, University of Western Ontario, London,  
Ontario, Canada.

#### REFERENCE

1. White KP, Harth M. Lumbar pannus presenting as cauda equina syndrome in a patient with longstanding rheumatoid arthritis. *J Rheumatol* 2001;28:627-30.

### Coexistent Sickle Cell Disease and Juvenile Rheumatoid Arthritis: 2 Cases with Delayed Diagnosis and Severe Destructive Arthropathy

To the Editor:

I read with interest the article by Murray and Nistala<sup>1</sup> on the challenge of diagnosing and treating chronic inflammatory arthritis accompanied by sickle cell disease (SCD). I was similarly challenged in treating a patient with SCD and arthritis secondary to probable mixed connective tissue disease (MCTD). These patients are unique, as the SCD complicates their treatment options and contributes to their treatment complications, as evidenced in Murray and Nistala's article and the following case report.

The patient was a 16-year-old young woman with SCD complicated by a restrictive cardiomyopathy, alloimmunization, and recurrent acute chest syndromes. She had been taking enalapril, hydroxyurea, ranitidine, and folate for many months when she presented to the rheumatology clinic with a 2 month history of pain in her fingers and a positive antinuclear antibody (ANA) at 1:640, speckled pattern. She had started ibuprofen 600 mg tid with no change in joint symptoms. The only abnormalities on examination were in her joints, where she had tenderness and effusions of the 3rd and 5th proximal interphalangeal (PIP) on the right and 1st and 2nd PIP on the left. Both her wrists were tender and swollen. She was unable to fully extend her elbows and had limitation of rotation of both hips and limited straight leg raise bilaterally. A provisional diagnosis of a ANA positive arthritis was made and she was prescribed indomethacin 25 mg tid and reviewed 2 weeks later, with no change in her joint complaints. At that visit she was noted to be dsDNA negative but strongly RNP positive. Her C3 and C4 were normal. She was therefore given hydroxychloroquine 200 mg daily for her joint complaints and a possible diagnosis of MCTD was entertained.

She was admitted to hospital a few weeks later with sickle cell crisis complicated by pre-renal failure, and both indomethacin and hydroxychloroquine were stopped. She continued to complain of joint symptoms that limited her activities, and was given prednisone 20 mg daily, weaned over a 4 week period. After discontinuation of prednisone, she developed hip and ankle pain. Magnetic resonance imaging (MRI) of her left and right hips revealed evidence of old avascular necrosis (AVN) accompanied by ischemic changes to the entire left femoral head. There was an accompanying small left hip effusion and some thickening of the synovium. As her AVN changes were all felt to be old, she was started on 5 mg prednisone daily to treat her hip and finger pain. However, with continuing use of crutches to ensure mobility, she complained of shoulder pain and on MRI had significant AVN in her right shoulder. Prednisone was discontinued. She was given tramadol 50 mg bid as pain relief and has been pain-free and mobile for the past 18 months, with no recurrence of her AVN and only minimal finger pain, but persistent effusion of the 3rd and 5th PIP on the right and 1st and 2nd PIP on the left. There has been no other sign of evolving MCTD despite rising erythrocyte sedimentation rate, ANA, and RNP titers.

As described in the article by Nistala and Murray<sup>1</sup>, these patients do not tolerate many of the current antiarthritic medications and can develop life threatening complications from their use, as shown by the pre-renal failure in my patient. Interestingly, my patient's SCD was most stable when she was taking small doses of prednisone. Her hemoglobin rose 1 g while she was taking prednisone. However, this rise in hemoglobin may have contributed to her episodes of AVN, and it was decided not to reinstitute prednisone therapy unless required for life threatening complications.

Although tramadol is not recognized treatment for arthritis, given the use of hydroxyurea for her chest crises, other medications such as methotrexate were considered potentially too toxic for use and therefore were not instituted. The article by Nistala and Murray and personal experience confirm that a cautious approach to therapeutic agents in these patients with SCD and inflammatory rheumatologic diseases is indeed warranted.

B. ANNE EBERHARD, MB BS, MSc, FRACP, FRCPC, Division of  
Rheumatology, Schneider Children's Hospital, New Hyde Park, NY,  
USA. E-mail: aeberhar@lij.edu

#### REFERENCE

1. Nistala K, Murray KJ. Co-existent sickle cell disease and JRA. Two cases with delayed diagnosis and severe destructive arthropathy. *J Rheumatol* 2001;28:2125-8.

### Doctors Murray and Nistala reply

To the Editor:

We read with interest the report from Dr. Eberhard, regarding a further case of inflammatory polyarthritis (as part of mixed connective tissue disease, MCTD) complicating the course of sickle cell disease (SCD). I note the similar problems of ongoing sickle crises, possibly related to introduction of new medications. Review of the literature indicates a large number of drugs being implicated in the causation of such crises, although in those with unstable SCD it can be difficult to ascertain a true relationship. The known relationship of crises to infections (such as parvovirus), which are commonplace in childhood, should be considered as well as medications in such situations.

Since our article was published we have diagnosed a further case of juvenile rheumatoid arthritis (JRA) in a patient with SCD. The patient is a 10-year-old girl of African origin (Sierra Leone), diagnosed as having SCD (HbSS) from 2 years of age. She had a relatively stable course requiring only 2 transfusions after malaria. On arrival in the UK at aged 9.5 years she was noted to have shoulder and hip pain thought to be secondary to her SCD. The hip pain was thought to be due to trauma and possible dislocation in the previous year. Shortly after arrival she had cerebrovascular event/crisis (left side weakness) requiring admission and treatment, with full recovery. Clinical examination suggested polyarticular joint problems and radiographs suggested destructive changes in the hips and shoulders, and she was referred to our unit. Clinical examination confirmed a symmetrical inflammatory polyarthritis involving both small and large joints, with marked limitation of hip movement in particular. MRI of her hips confirmed destruction due in part to avascular necrosis but also to florid enhancing synovial hypertrophy consistent with JRA. Serology revealed she was ANA positive but rheumatoid factor negative. She was treated with nonsteroidal antiinflammatory drugs and intensive physiotherapy, and methotrexate was started at 20 mg/m<sup>2</sup> subcutaneously. Over the initial 2 months she has shown encouraging improvement.

Like Dr. Eberhard we remain anxious about medications such as methotrexate, and are continuing to monitor this and the other patients closely. We feel the inflammatory joint disease is as important as, if not more important than, the SCD in causing AVN, and there is evidence that the same mechanism occurs in SCD as inflammatory arthritis mediated by monocytes in causing AVN<sup>1</sup>. Considerable evidence suggests that tumor necrosis factor (TNF) is important in the pathophysiology of vasoocclusive

crises as well<sup>2,3</sup>. We are considering the use of anti-TNF therapy in one of the initial patients we described, and may do so in the others, considering the potential for severe destructive disease and high morbidity in such patients with dual pathology.

KEVIN J. MURRAY, MB BS, FRACP; KIRAN NISTALA, MB BS, MRCP, Paediatric Rheumatology Unit, Great Ormond Street Hospital, London, UK.

#### REFERENCES

1. Belcher JD, Marker PH, Weber JP, Hebbel RP, Vercellotti GM. Activated monocytes in sickle cell disease: potential role in the activation of vascular endothelium and vaso-occlusion. *Blood* 2000;96:2451-9.
2. Kuvibidila S, Gardner R, Ode D, Yu L, Lane G, Warriar RP. Tumor necrosis factor alpha in children with sickle cell disease in stable condition. *J Natl Med Assoc* 1997;89:609-15.
3. Francis RB Jr, Haywood LJ. Elevated immuno-reactive tumor necrosis factor and interleukin-1 in sickle cell disease. *J Natl Med Assoc* 1992;84:611-5.

### Sjögren's Syndrome Associated T Cell Large Granular Lymphocyte Leukemia: A Possible Common Etiopathogenesis

To the Editor:

Molad and colleagues describe 2 cases they consider to have primary Sjögren's syndrome (SS) who also had large granular lymphocyte (LGL) leukemia<sup>1</sup>. If I had been classifying these patients, I would have labelled them Felty's syndrome (FS) with secondary SS and LGL syndrome.

In both cases, they describe patients with symmetrical swelling of the proximal interphalangeal joints and a positive rheumatoid factor. These findings satisfy 4 out of 7 of the 1987 revised American College of Rheumatology criteria for diagnosis of rheumatoid arthritis (RA)<sup>2</sup>, even without knowing the patients' degree of morning stiffness or radiological findings. The diagnosis of RA, together with unexplained neutropenia, satisfies a diagnosis of FS, for which splenomegaly is no longer an essential criterion<sup>3</sup>. Campion's study of 32 patients with FS showed that 53% of cases had secondary SS<sup>3</sup>. In around 30% of patients with FS, there is evidence of LGL expansion<sup>4</sup>. Hence, far from being unique, it is not uncommon (in the arcane world of FS research) for there to be an association between LGL syndrome and SS, because they both commonly complicate FS. In only one of the 2 cases was there a minor (10%) population of LGL within the salivary glands. They do not cite evidence from Loughran that similar infiltrations are seen in the spleen, liver, kidneys, thyroid, and adrenal glands<sup>5</sup>, suggesting that this is a case of "seek and ye shall find." I think the authors go too far in arguing that this one case tells us anything about the etiology of primary SS in general.

GERALD COAKLEY, PhD, MRCP, Consultant Rheumatologist, Queen Elizabeth Hospital, London SE18 4QH, UK.

#### REFERENCES

1. Molad Y, Okon E, Stark P, Prokocimer M. Sjögren's syndrome associated T cell large granular lymphocyte leukemia: a possible common etiopathogenesis. *J Rheumatol* 2001;28:2551-2.
2. Arnett FC, Edworthy SM, Bloch DA, et al. The American Rheumatism Association 1987 revised criteria for the classification of rheumatoid arthritis. *Arthritis Rheum* 1988;31:315-24.
3. Campion G, Maddison PJ, Goulding N, et al. The Felty syndrome: a case-matched study of clinical manifestations and outcome, serologic features, and immunogenetic associations. *Medicine (Baltimore)* 1990;69:69-80.
4. Bowman SJ, Bhavnani M, Geddes GC, et al. Large granular

lymphocyte expansions in patients with Felty's syndrome: analysis using anti-T cell receptor V beta-specific monoclonal antibodies. *Clin Exp Immunol* 1995;101:18-24.

5. Loughran TP Jr. Clonal diseases of large granular lymphocytes. *Blood* 1993;82:1-14.

#### Drs. Molad, et al, reply

To the Editor:

We thank Dr. Coakley for his interest in our article<sup>1</sup>; however, we disagree with his comment with respect of the diagnosis of our patients as having Felty's syndrome (FS) rather than primary Sjögren's syndrome (SS) associated with large granular lymphocytosis (LGL) syndrome. Both described patients presented with non-erosive polyarthritis concomitant with sicca symptoms, with no history of preceding erosive, nodule-forming rheumatoid arthritis (RA), which is characteristic of and a common presentation of FS<sup>2</sup>. Moreover, our patients had serological and histological evidence of SS, only one of them had mild splenomegaly, and they did not have recurrent bacterial infections as described in FS.

We are fully aware of the association of FS with LGL, but the observation of LGL cells in the minor salivary gland biopsy of one of our patients (Case 1) supports a possible etiopathogenic association of primary SS with LGL. The aim of our article was to point out the association between these 2 syndromes.

YAIR MOLAD, MD; ELIMELECH OKON, MD; PINHAS STARK, MD; MIRON PROKOCIMER, MD, Rabin Medical Center, Beilinson Campus, Petah Tikva, Israel.

#### REFERENCES

1. Molad Y, Okon E, Stark P, Prokocimer M. Sjögren's syndrome associated T cell large granular lymphocyte leukemia: a possible common etiopathogenesis. *J Rheumatol* 2001;28:2551-2.
2. Campion G, Maddison PJ, Goulding N, et al. The Felty syndrome: A case-matched study of clinical manifestations and outcome, serologic features, and immunogenetic associations. *Medicine (Baltimore)* 1990;69:69-80.



### Basal Levels of DHEAS as a Marker for Disease Activity in Premenopausal Women with Recent Onset Rheumatoid Arthritis

To the Editor:

Some authors have found low levels of dehydroepiandrosterone sulfate (DHEAS) and cortisol-DHEAS dissociation in premenopausal women with long-lasting rheumatoid arthritis (RA)<sup>1-3</sup>. On the other hand, a recent study<sup>4</sup> noted no significant differences in adrenal steroid levels among patients with short duration RA and controls, as well as a positive (non-significant) cortisol-DHEA correlation, and also showed an inverse (significant) correlation between some indices of inflammation and DHEA.

We analyzed serum levels of cortisol and DHEAS in 15 premenopausal

Table 1. Clinical and laboratory characteristics of women with RA.

Variables	RA, n = 15
Age, yrs*	36.06 ± 2.26
Disease duration, mo†	8 (2–15)
Percentage RF positive, 20 + IU/ml†	73.3; 200 (0–200)
DAS*	3.68 ± 0.14
Steinbrocker anatomic class†	2 (1–3)
Cortisol nmol/l†	480.2 (41.1–1587)
DHEAS, μmol/l†	3.5 (0.5–8.6)

\* mean ± SE; † median (minimum-maximum).

women with short duration RA (up to 15 months from the beginning of the disease) using only nonsteroidal antiinflammatory drugs (NSAID), as well as correlations between cortisol and DHEAS with rheumatoid factor (RF) titer, disease activity represented by the Disease Activity Score (DAS), and Steinbrocker anatomic class<sup>5</sup>. All patients fulfilled the 1987 American College of Rheumatology revised criteria for the diagnosis of RA<sup>6</sup>.

Basal serum concentrations of cortisol and DHEAS were measured as described<sup>7</sup>. DAS was composed of the Ritchie Articular Index, number of swollen joints, and erythrocyte sedimentation rate<sup>8</sup>. RF was determined by latex fixation test (Table 1).

Correlations between cortisol and DHEAS with RF, DAS, and Steinbrocker score were determined using a Spearman rank order method. Multiple correlation of combined steroid levels and DAS were determined by using a multiple regression technique.

Only 2 of 15 (13.33%) patients had abnormally low DHEAS levels, 0.5 nmol/l and 1.2 nmol/l, respectively (most references consider < 1.3 nmol/l to be low for premenopausal women). Regarding cortisol levels, in only one patient was the level of cortisol found to be under the critical limit (the most accepted normal lower limit for cortisol is 140 nmol/l). In 2 patients levels of cortisol were unaccountably much greater than normal basal physiologic level (1313 and 1587 nmol/l). We excluded these 2 patients from further statistical analysis. (Table 1).

We found significantly positive correlation between cortisol and DHEAS ( $r = 0.63$ ,  $p = 0.02$ ) (Figure 1). Cutolo, et al<sup>1</sup> described a significant negative correlation between these steroids, but the duration of disease in their patients was several years. Kanik, et al in patients with short duration RA and controls showed results similar to ours: a positive correlation (although this was nonsignificant in patients and significant in controls) between cortisol and DHEA. One explanation for our positive cortisol–DHEAS correlation could be the short duration disease (median 8 months) in our patients. If chronic disease exhausts the adrenals, we can expect dissociation between these steroids as well as lower adrenal steroid levels later in the disease course.

The correlations between steroids and RF, DAS, and Steinbrocker score revealed one significant inverse correlation (DHEAS–DAS;  $r = -0.74$ ,  $p = 0.003$ ) and one close to significant (cortisol–DAS;  $r = -0.7$ ,  $p = 0.07$ ) (Figure 1). Other authors have found similar results<sup>1–4</sup>. We further calculat-

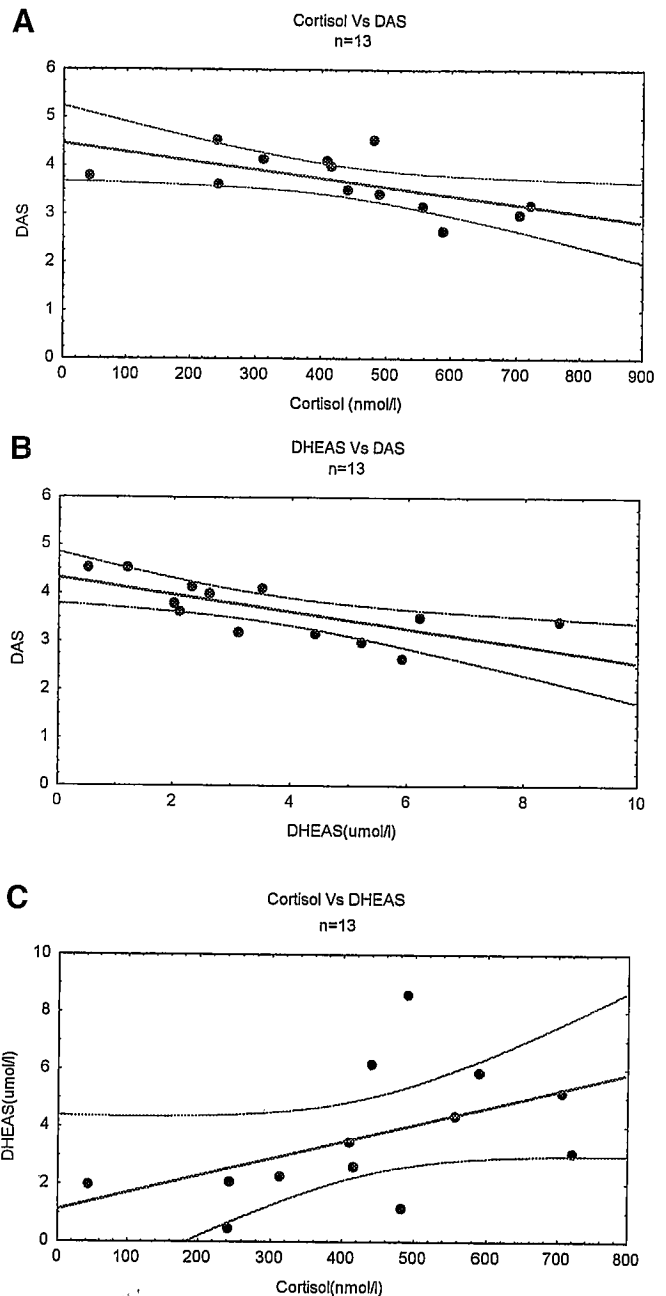


Figure 1. A. Cortisol and DAS: linear regression,  $r = -0.7$ ,  $p = 0.07$ . B. DHEAS and DAS: linear regression,  $r = -0.74$ ,  $p = 0.003$ . C. Cortisol and DHEAS: linear regression,  $r = 0.63$ ,  $p = 0.02$ . Straight lines show linear regression, curved lines show 95% confidence intervals.

Table 2. Correlations of studied hormones and some disease activity variables.

Coefficient of Rank Correlation (Spearman)	Latex RF, n = 13		Steinbrocker Anatomic Class, n = 13		DAS, n = 13		Multiple Regression Coefficient	DAS, n = 13		Partial Correlation Coefficients
	r	p	r	p	r	p		r	p	
Cortisol	0.15	0.62	-0.04	0.89	-0.7	0.07	Cortisol, DHEAS	0.74	0.01	Cortisol beta coefficient -0.33 DHEAS beta coefficient -0.53
DHEAS	-0.02	0.93	0.02	0.93	0.74	0.003				

ed a multiple correlation coefficient between the examined hormones and DAS, which showed that cortisol and DHEAS overall are in significant inverse correlation to DAS ( $r = 0.74$ ,  $p = 0.01$ ). The partial correlation coefficient was stronger for DHEAS than for cortisol; DHEAS beta =  $-0.53$ , cortisol beta =  $-0.33$  (Table 2).

Our results imply that DHEAS might be a marker for increased disease activity in the premenopausal woman with short duration RA. As well, according to the significant inverse multiple correlation we observed between steroids and DAS, as well as a subgroup with lower than normal DHEAS and cortisol levels, we hypothesize that those patients might benefit from chronic DHEA and cortisol replacement therapy. Whether the combination of these steroids should be added to the treatment of patients with RA is speculative<sup>9</sup>, but further research is needed to explore these issues.

BOZA JOSIPOVIC, MD, PhD, Institute for Rheumatology, Resavska 69, 11000 Belgrade, Yugoslavia; ALEKSANDRA JOSIPOVIC, MD, Institute for Endocrinology, Diabetes and Diseases of Metabolism, Dr Subotica 13, 11000 Belgrade, Yugoslavia.

## REFERENCES

- Cutolo M, Foppiani L, Prete C, et al. Hypothalamic-pituitary-adrenocortical axis function in premenopausal women with rheumatoid arthritis not treated with glucocorticoids. *J Rheumatol* 1999;26:282-8.
- Masi AT. Sex hormones and rheumatoid arthritis: cause or effect relationships in a complex pathophysiology? *Clin Exp Rheumatol* 1995;13:227-41.
- Masi AT, Aldag JC, Chatterton RT, Adams RF, Kitabchi AE. Adrenal androgen and glucocorticoid dissociation in premenopausal rheumatoid arthritis: a significant correlate or precursor to onset? *Z Rheumatol* 2000; 59 Suppl 2:54-9.
- Kanik KS, Chrousos GP, Schumacher HR, Crane ML, Yarboro CH, Wilder RL. Adrenocorticotropin, glucocorticoid, and androgen secretion in patients with new onset synovitis/rheumatoid arthritis: Relations with indices of inflammation. *J Clin Endocrinol Metab* 2000;85:1461-6.
- Steinbrocker O, Traeger CH, Batterman RC. Therapeutic criteria in rheumatoid arthritis. *JAMA* 1949;140:659-62.
- Arnett FC, Edworthy SM, Bloch DA, et al. The American Rheumatism Association 1987 revised criteria for the classification of rheumatoid arthritis. *Arthritis Rheum* 1988;31:315-24.
- Cutolo M, Belleardi E, Giusti M, Monachesi M, Accardo S. Sex hormone status of male patients with rheumatoid arthritis: evidence of low serum concentrations of testosterone at baseline and after human chorionic gonadotropin stimulation. *Arthritis Rheum* 1988;31:1314-7.
- van der Heijde D, van't Hof MA, van Riel PL, et al. Judging disease activity in clinical practice in rheumatoid arthritis. *Ann Rheum Dis* 1990;49:916-20.
- Robiznon B, Cutolo M. Should dehydroepiandrosterone replacement therapy be provided with glucocorticoids? *Rheumatology* 1999;38:488-95.

underlying cause(s) remain unclear. Recently, hyperhomocysteinemia has been described as one of the important risk factors of cardiovascular disease<sup>3</sup>. Istok, *et al*, in their recent letter<sup>4</sup>, described increased plasma homocysteine concentrations in patients with gout. However, since the number of subjects was low (28 cases) and the factors affecting plasma homocysteine concentration were not taken into consideration, we investigated plasma homocysteine concentrations in a relatively large number of Japanese patients with gout ( $n = 133$ ) and control subjects ( $n = 72$ ), together with known factors having an effect (alcohol consumption, vitamin B<sub>12</sub>, folic acid<sup>5,6</sup>, and renal function<sup>7</sup>) in 26 patients and 29 control subjects. Blood was drawn into tubes containing EDTA, and plasma was immediately separated to prevent homocysteine leakage from erythrocytes. Plasma homocysteine concentrations were measured by high performance liquid chromatography. Results between gout patients and control subjects were com-

Table 1. Clinical features of the subjects. Data are mean  $\pm$  standard deviation.

	Gout, n = 133	Controls, n = 72	p
Age, yrs	48.9 $\pm$ 11.8	47.4 $\pm$ 11.5	NS
BMI	25.1 $\pm$ 3.2	23.7 $\pm$ 2.5	< 0.001
Alcohol, g/day	34.0 $\pm$ 31.9	21.3 $\pm$ 19.8	< 0.01
SBP, mm Hg	134.8 $\pm$ 18.4	126.2 $\pm$ 15.5	< 0.001
DBP, mm Hg	80.4 $\pm$ 10.3	74.8 $\pm$ 8.8	< 0.001
AST	23.6 $\pm$ 12.5	22.2 $\pm$ 6.7	NS
ALT	25.7 $\pm$ 18.4	24.1 $\pm$ 15.2	NS
$\gamma$ -GTP	69.1 $\pm$ 77.2	42.5 $\pm$ 44.5	< 0.01
SUA, mg/dl	8.5 $\pm$ 1.1	5.4 $\pm$ 1.0	< 0.001
Ccr, ml/min	105.6 $\pm$ 26.2	107.2 $\pm$ 18.1	NS

BMI: body mass index; SBP: systolic blood pressure; DBP: diastolic blood pressure; AST: aspartate aminotransferase; ALT: alanine aminotransferase;  $\gamma$ -GTP:  $\gamma$ -glutamyl transpeptidase; SUA: serum uric acid; Ccr: creatinine clearance.

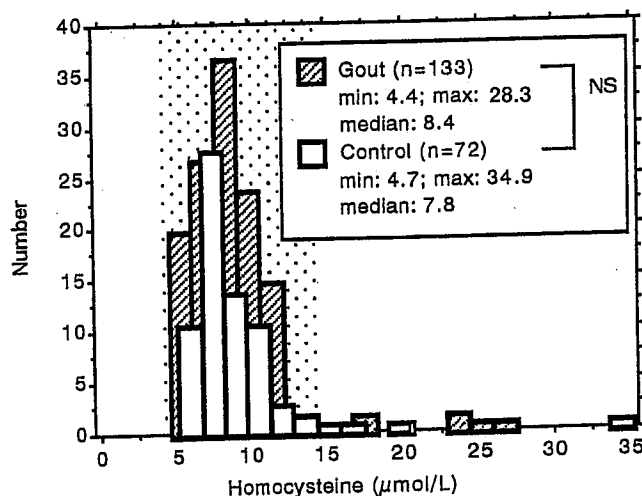


Figure 1. Total plasma homocysteine concentrations in patients with gout and controls. Plasma homocysteine concentration showed a skewed distribution in both gout patients and controls. There was no significant difference in total plasma homocysteine concentration between the 2 groups. Shaded area represents the normal range.

## Total Plasma Homocysteine Is Not Increased in Japanese Patients with Gout

To the Editor:

Gout is frequently complicated with coronary artery disease<sup>1</sup>, and it has been suggested that multiple atherogenic risk factors clustered in patients with gout are responsible for its high prevalence<sup>2</sup>. However, the exact

pared by Mann-Whitney U test. Clinical characteristics of subjects are shown in Table 1.

Although the gout patients showed significant increases in body mass index, alcohol consumption, blood pressure, and  $\gamma$ -glutamyl transpeptidase, there were no significant differences between the 2 groups in terms of age or hepatic and renal function results. Moreover, contrary to the results reported by Istok, *et al*, we found that plasma homocysteine concentrations were not significantly different between gout patients (median 8.4  $\mu\text{mol/l}$ , range 4.4–28.3) and controls (median 7.8  $\mu\text{mol/l}$ , range 4.7–34.9) (Figure 1). In addition, serum vitamin B<sub>12</sub> and folic acid levels were also not different between patients (n = 26) and controls (n = 29) [vitamin B<sub>12</sub> 460  $\pm$  148 vs 561  $\pm$  217 pg/ml (normal range 233–914); folic acid 5.2  $\pm$  2.0 vs 4.7  $\pm$  1.9 ng/ml (normal range 2.4–9.8)].

The discrepancy between our results and those of Istok, *et al* may be ascribable to differences of (1) ethnicity<sup>8</sup>, (2) consumption of alcoholic beverages, (3) concentrations of vitamin B<sub>6</sub>, B<sub>12</sub> or folic acid, or (4) the incidence of impaired renal function, or other factors. In other words, Istok, *et al* described subjects with excessive alcohol consumption (18/28), impaired renal function (6/28), and hepatopathy (18/28), while our study did not. It seems probable that the increased plasma homocysteine concentrations in the results of Istok, *et al* were considerably influenced by these factors, and may not be inherent in patients with gout. Moreover, the incidence of methylenetetrahydrofolate reductase (MTHFR) gene variation<sup>9</sup>, which affects plasma concentration of homocysteine, may also have contributed to the differences. Therefore, we believe further studies that include MTHFR gene polymorphisms in patients with gout are required.

ZENTA TSUTSUMI, MD, PhD; YUJI MORIWAKI, MD, PhD; TETSUYA YAMAMOTO, MD, PhD; SUMIO TAKAHASHI, MD, PhD; TOSHIKAZU HADA, MD, PhD; MINORU FUKUCHI, MD, PhD; Division of Endocrinology and Metabolism, Department of Internal Medicine, Hyogo College of Medicine, Mukogawa-cho 1-1, Nishinomiya, Hyogo 663-8501, Japan.

## REFERENCES

1. Kelley WN, Schumacher HR Jr. Gout. In: Kelley WN, Harris ED Jr, Sledge CB, et al, editors. Textbook of rheumatology. Philadelphia: WB Saunders; 1993:1291-336.
2. Takahashi S, Moriwaki Y, Tsutsumi Z, Yamakita J, Yamamoto T, Hada T. Increased visceral fat accumulation further aggravates the risks for insulin resistance in gout. *Metabolism* 2001;50:393-8.
3. Guba SC, Fink LM, Fonseca V. Hyperhomocysteinemia. An emerging and important risk factor for thromboembolic and cardiovascular disease. *Am J Clin Pathol* 1996;106:709-22.
4. Istok R, Kovalancik M, Rovensky J. Total plasma homocysteine in patients with gout [letter]. *J Rheumatol* 1999;26:2068-9.
5. Stickel F, Choi SW, Kim YI, et al. Effect of chronic alcohol consumption on total plasma homocysteine level in rats. *Alcohol Clin Exp Res* 2000;24:259-64.
6. Cravo ML, Camilo ME. Hyperhomocysteinemia in chronic alcoholism: relations to folic acid and vitamins B(6) and B(12) status. *Nutrition* 2000;16:296-302.
7. Arnadottir M, Hultberg B, Nilsson-Ehle P, Thysel H. The effect of reduced glomerular filtration rate on plasma total homocysteine concentration. *Scand J Clin Lab Invest* 1996;56:41-6.
8. Pollak RD, Friedlander Y, Pollak A, Idelson M, Bejarano-Achache I, Blumenfeld A. Ethnic differences in the frequency of the C677T mutation in the methylenetetrahydrofolate reductase (MTHFR) gene in healthy Israeli populations. *Genet Test* 2000;4:309-11.
9. Rassoul F, Richter VV, Kuntze T, Mohr FW, Geisel J, Herrmann W. Genetic polymorphism of methylenetetrahydro folate reductase (MTHFR) and coronary artery disease. *Int J Angiol* 2000;9:205-7.

## Alopecia Areata in a Patient with Rheumatoid Arthritis Treated with Leflunomide

To the Editor:

Leflunomide is a new and efficient immunomodulatory drug for the treatment of rheumatoid arthritis (RA) that selectively acts on activated autoimmune lymphocytes by inhibiting dihydroorotate dehydrogenase, an enzyme required for de novo pyrimidine synthesis<sup>1,2</sup>. Leflunomide has been associated with diarrhea, nausea, rash, weight loss<sup>3</sup>, elevated liver enzymes, and transient hair loss. We describe a patient with RA who developed alopecia areata associated with leflunomide therapy.

A 46-year-old woman presented with a 2 year history of erosive and refractory RA, despite therapy with methotrexate (MTX) and infliximab. She had no clinical or laboratory measures indicating an underlying autoimmune disease such as systemic lupus erythematosus. Leflunomide was started at a loading dose of 100 mg/day for 3 days, followed by a daily dose of 20 mg. The only other current medication was prednisone, at unchanged dosage of 10mg/day. Three weeks after starting leflunomide, she noticed sudden, focal hair loss (Figure 1), which was not associated with diffuse hair loss. On clinical examination, nonscarring and patchy hair loss could be seen. The patient declined a scalp biopsy. Laboratory tests, including liver enzyme values, were normal. The diagnosis of alopecia areata was made on a clinical basis. The patient continued leflunomide for 2 months. Leflunomide was discontinued because of poor response of RA to 3 months' therapy. The patient's hair was just slowly recovering 3 months after leflunomide had been stopped.

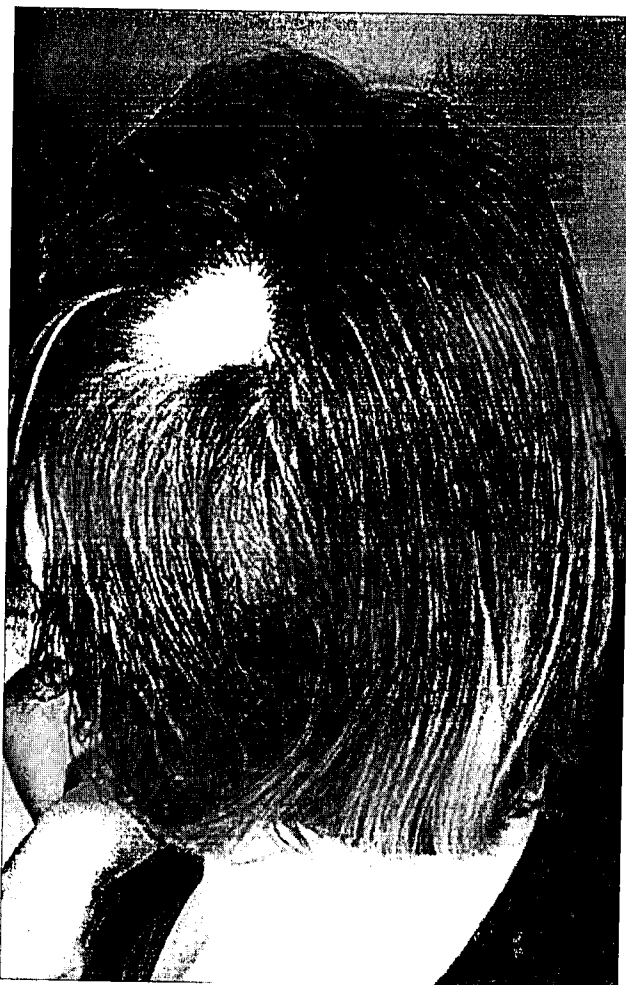


Figure 1. Sudden focal hair loss in a patient with RA 3 weeks after starting leflunomide.



Alopecia areata is a common form of nonscarring hair loss. Patients usually present with sudden and patchy hair loss on the scalp. Hair loss is preceded by a great increase in the number of telogen (resting) follicles compared to the number of anagen (growing) follicles. Peribulbar and intrafollicular inflammatory infiltration of anagen follicles by T lymphocytes and antigen presenting cells (macrophages and Langerhans cells) is a key histological feature of alopecia areata. Pathogenesis of alopecia areata remains unclear. Environmental causes, such as infection, or emotional stress have been suggested to play a role in the disease, but various investigations could not show significant associations. The role of autoimmunity<sup>5</sup> in the pathogenesis of alopecia areata is supported by observation of T lymphocytes and antigen presenting cells in the follicular infiltrate, the increased expression of class I and II HLA antigens in the lower follicle, and the presence of autoantibodies to follicular components. Further, intralesional human T lymphocytes transfer alopecia areata to human skin grafts on SCID mice; removal of T lymphocytes inhibits hair loss, which enhances the hypothesis of a T lymphocyte mediated pathology<sup>6,7</sup>.

Drugs may produce a wide spectrum of hair loss, ranging from barely detectable shedding to irreversible baldness. Drug induced alopecia is usually described as a diffuse nonscarring alopecia reversible upon withdrawal of the drug. Drugs can interfere with every cycle of hair growth, either by direct cytotoxicity (antimitotic agents) or indirectly by shortening of the anagen ("immediate anagen release") or telogene ("immediate telogene release") phase<sup>8</sup>. Whereas many drugs may be the cause of isolated cases of alopecia, only a few drugs (mainly antimitotic agents) constitutionally induce hair loss. A scalp biopsy is usually not enlightening. Diagnosis of drug induced alopecia remains difficult. It can only be confirmed if improvement occurs after cessation of the suspected drug<sup>9</sup>. In the rheumatologic field, azathioprine, cyclosporine, MTX, and various nonsteroidal antiinflammatory drugs can be responsible for alopecia. This side effect must be recognized, since it may be a source of poor compliance.

In our patient, although we cannot exclude the possibility that use of leflunomide, and onset of alopecia areata might have been coincidental, the hair growth improvement after cessation of the drug strongly supports a causative role. As well, some immunomodulators, such as interferon alpha and cyclosporin A, have been associated with alopecia areata<sup>10</sup>.

We suggest that leflunomide, which alters lymphocyte T homeostasis, may have induced alopecia areata. Diffuse hair loss is a classical side effect of leflunomide, but to our knowledge alopecia areata has not been reported.

JACQUES-ERIC GOTTENBERG, MD, Department of Rheumatology;  
PIERRE-YVES VENANCIE, MD, Department of Dermatology; XAVIER  
MARIETTE, MD, PhD, Professor, Department of Rheumatology, Hôpital de  
Bicêtre (Assistance Publique-Hôpitaux de Paris), Université Paris 11, 94275  
Le Kremlin Bicêtre Cedex, France.

## REFERENCES

- Emery P, Breedveld FC, Lemmel EM, et al. A comparison of the efficacy and safety of leflunomide and methotrexate for the treatment of rheumatoid arthritis. *Rheumatology* 2000;39:655-85.
- Smolen JS, Kalden JR, Scott DL, et al. Efficacy and safety of leflunomide compared with placebo and sulphasalazine in active rheumatoid arthritis: a double-blind, randomized, multicentre trial. *Lancet* 1999;353:259-66.
- Coblyn JS, Shadyk N, Helfgott S. Leflunomide-associated weight loss in rheumatoid arthritis. *Arthritis Rheum* 2001;44:1048-51.
- Randall VA. Is alopecia areata an autoimmune disease? *Lancet* 2001;358:1922-3.
- McElwee KJ, Tobin DJ, Bystryn JC, King LE Jr, Sundberg JP. Alopecia areata: an auto-immune disease? *Exp Dermatol* 1999;8:371-9.
- Gilhar A, Shalaginov R, Assay B, Serafimovich S, Kalish RS. Alopecia areata is a T-lymphocyte mediated autoimmune disease: lesional human T-lymphocytes transfer alopecia areata to human skin grafts on SCID mice. *J Invest Dermatol* 1999;4:207-10.
- McElwee KJ, Spiers EM, Oliver RF. In vivo depletion of CD8+ T cells restores hair growth in the DEBR model for alopecia areata. *Br J Dermatol* 1996;135:211-7.
- Liau ME, Viraben R, Montastruc JL. Les alopecies médicamenteuses: revue de la littérature. *Thérapie* 1995;50:145-50.
- Roudier-Pujol C, Jan V. Alopecies médicamenteuses. *Ann Dermatol Venereol* 2000;127:S26-28.
- Kernland KH, Hunziker T. Alopecia areata induced by interferon alpha? *Dermatology* 1999;198:418-9.

## Captopril Induced Lupus

To the Editor:

Captopril can induce the formation of asymptomatic antinuclear antibodies (ANA), but the development of clinical lupus is felt to be quite rare. During the initial clinical investigations of captopril, excessive doses of up to 1 g/day were used and a small number of patients developed ANA<sup>1</sup>. Reidenberg, *et al* documented positive ANA (> 1:40) in 10 of 37 patients taking excessively high doses of captopril (300-1000 mg/day), but found no incidence of clinical lupus syndrome<sup>2</sup>. Conversely, investigations of captopril induced rash and proteinuria have not shown an association with positive ANA<sup>3</sup>. The time course for the development of antibodies is variable, but appears to average 90 days<sup>4</sup>.

To our knowledge there are 4 reported cases of captopril induced lupus<sup>5</sup>. We describe a case of lupus syndrome that developed after one year of treatment with captopril and resolved rapidly after discontinuation of the drug.

A 54-year-old Caucasian man was admitted with a 4 week history of fevers, chills, malaise, and generalized arthralgias. One year previously he had started taking captopril 25 mg tid after an aortic valve replacement. He had no other significant history. His other medications were coumadin and aspirin. He had not undergone any recent dental procedures. He had no history of recent travel, intravenous drug use, or tick bites. He had noticed a discolored pattern on his extremities, which was not pruritic and which he attributed to feeling cold. Otherwise his review of systems was negative. He had no drug allergies. He did not smoke and drank minimal amounts of alcohol.

On admission his temperature was 103°F, blood pressure 130/80, heart rate 80, respiration rate 16. Examination revealed diffuse livedo reticularis on the lower extremities and a grade II/VI hemisystolic murmur, but was otherwise unremarkable. A transesophageal echocardiogram showed no evidence for endocarditis. Blood cultures were negative. Other laboratory results included white blood cell count 2300, hemoglobin 8.3 g/dl, platelets 274,000, erythrocyte sedimentation rate (ESR) 142 mm/h, FANA 1:2560 homogeneous pattern; anti-native DNA was negative; anti-Sm antibody was < 25, anti-RNP < 25, serum complement level 265 mg/dl (normal 101-300), hepatitis screen negative.

Rheumatology consult was requested. Captopril was discontinued and he was treated with a 5 day course of prednisone. Symptoms improved rapidly and the livedo reticularis resolved within 2 days. A followup FANA 6 months later was 1:40. A followup ESR was normal. He remained asymptomatic.

We believe that captopril is implicated as the cause of drug induced systemic lupus erythematosus syndrome in this case. We base this on the following findings: (1) The patient had no clinical signs of lupus prior to captopril therapy. (2) He improved rapidly after discontinuation of the drug. (3) Both the FANA and ESR returned to normal after discontinuation of the drug. (4) Drug induced lupus is associated with high ANA titers and negative anti-native-DNA titers, both noted in this patient.

Although our patient did not meet strict clinical criteria for lupus, the

immunological data and his rapid response to discontinuation of the drug are consistent with the other cases of captopril induced lupus in the literature.

NORMAN B. RATLIFF III, MD, University of Minnesota/Minneapolis Heart Institute Foundation, 920 East 28th St., Suite 300, Minneapolis, MN 55407-1139, USA.

#### REFERENCES

1. Case DB, Atlas SA, Laragh J, Sealey JE, Sullivan PA, McKinsty DN. Clinical experience with the blockade of renin-angiotensin-aldosterone system by an oral converting-enzyme inhibitor (SQ14,225, captopril) in hypertensive patients. *Prog Cardiovasc Dis* 1978;21:195-206.
2. Reidenberg MM, Case DB, Drayer DE, Reis S, Lorenzo B. Development of antinuclear antibody in patients treated with high doses of captopril. *Arthritis Rheum* 1984;27:579-81.
3. Luderer JR, Lookingbill DP, Schneck DW, Demers LM, Cohen C, Hayes AH Jr. Captopril-induced skin eruptions. *J Clin Pharmacol* 1982;5:151-9.
4. Pelayo M, Vargas V, Gonzales A, Vallano A, Esteban R, Guardia J. Drug-induced lupus-like reaction and captopril. *Ann Pharmacother* 1993;27:1541-2.
5. Sieber C, Grimm E, Follath F. Captopril and systemic lupus erythematosus syndrome [letter]. *BMJ* 1990;301:669.
6. Bertin P, Kamden J, Bonnet C, Arnaud M, Treves R. Captopril-induced lupus [letter]. *Clin Exp Rheumatol* 1993;11:695.
7. Samanta A, Burden AC. Fever, myalgia and arthralgia in a patient on captopril and allopurinol. *Lancet* 1984;1:679.

us to reconsider this conclusion. Indeed, in our patient both a genetically determined and an inflammation derived fibrillin-1 defect might coexist.

PIERANNA FIETTA, MD; PAOLO MANGANELLI, MD, Unità Operativa di Reumatologia e Medicina Interna, Azienda Ospedaliera di Parma, Parma, Italy.

#### REFERENCES

1. Simkin PA. Acetabular osteitis in ankylosing spondylitis: does fibrillin figure in its pathogenesis? *J Rheumatol* 2001;28:2663-6.
2. Zhang H, Hu W, Ramirez F. Development expression of fibrillin genes suggests heterogeneity of extracellular microfibrils. *J Cell Biol* 1995;129:1165-76.
3. Plantin PD, Durigon M, Boileau C, Le Parc J. Fibrillin network in normal bone and cartilage. *Ann Pathol* 2000;20:115-8.
4. Edwards JC, Bowness P, Archer JR. Jekyll and Hyde: the transformation of HLA-B27. *Immunol Today* 2000;21:256-60.
5. Dietz HC, Cutting GR, Pyeritz RE, et al. Defects in the fibrillin gene cause the Marfan syndrome: linkage evidence and identification of a missense mutation. *Nature* 1991;352:337-9.
6. van der Linden S, van der Heijde D. Ankylosing spondylitis. In: Ruddy S, Harris ED Jr, Sledge CB, editors. *Kelley's textbook of rheumatology*. 6th ed. Philadelphia: WB Saunders; 2001:1039-53.
7. Yule SR, Hobson EE, Dean JC, Gilbert FJ. Protrusion acetabuli in Marfan's syndrome. *Clin Radiol* 1999;54:95-7.
8. McGonagle D, Stockwin L, Isaacs J, Emery P. An enthesitis based model for the pathogenesis of spondyloarthropathy. Additive effects of microbial adjuvant and biomechanical factors at disease sites. *J Rheumatol* 2001;28:2155-9.
9. Fietta P, Manganelli P. Coexistent Marfan's syndrome and ankylosing spondylitis: a case report. *Clin Rheumatol* 2001; 20:140-2.

### Is Fibrillin-1 the Link Between Ankylosing Spondylitis and Marfan's Syndrome?

To the Editor:

We read with interest the article by Simkin on the pathogenesis of ankylosing spondylitis (AS), suggesting a role for fibrillin-1<sup>1</sup>, a 350 kDa glycoprotein found throughout the extracellular matrix<sup>2</sup>. To confirm this interesting hypothesis, the author reported the following observations. In AS, the fibrocartilage is an important component of most sites of the disease, such as the iliac side of the sacroiliac joints, the acetabulum in the hip, and the periarticular entheses. Since fibrillin-1 is a major component of the microfibrils in fibrocartilage<sup>3</sup>, it may be involved in the pathogenesis of spondylitic inflammation<sup>4</sup>, likely as a target of a cell mediated autoimmune response<sup>5</sup>.

Moreover, the author underlined the parallelism between AS and Marfan's syndrome (MFS), an inherited disorder of the connective tissue caused by the mutation of the gene encoding for fibrillin-1 on the long arm of chromosome 15<sup>6</sup>. The altered structure of fibrillin-1 in MFS leads to major morbidity in the eye and in the base of the aorta, which also are 2 sites of greatest nonarticular morbidity in patients with AS<sup>6</sup>. A further similarity between AS and MFS is the significant risk of protrusion in the acetabula in patients with MFS<sup>7</sup>. Thus, the defective structure of microfibrils in MFS and the inflammation-targeted fibrillin-1 in AS may each lead to comparable structural phenotypes of failure<sup>8</sup>, both involving sites of connective tissue weakening, exposed to repetitive biomechanical stressing<sup>8</sup>.

We recently described a patient in which AS and MFS were found to coexist<sup>9</sup>. Indeed, our patient presented with the typical traits of MFS, along with the clinical and radiological findings of AS. Moreover, the HLA typing was positive for HLA-B27 antigen. To our knowledge, this patient is so far the only reported case of such association. For the rarity of such coexistence, at first we thought that these signs and symptoms were coincidentally and not causally related, but the hypothesis suggested by Simkin leads

### Hemarthrosis and Scurvy

To the Editor:

I read with interest the report of a patient with hemarthrosis as a presentation of scurvy<sup>1</sup>, as 4 patients with similar presentation were described from our unit in 1985<sup>2</sup>. In contrast to the present case, all our patients were women with preexisting joint disease who developed hemarthrosis, which was accompanied by visible bruising in 3 of them. The clinical photograph of one has been published<sup>3</sup>. None of our patients was following a diet as extreme as that described by Pangan and Robinson, but all had poor diets typical of elderly people hampered in food preparation by joint disease. The conclusion at that time was that this condition is probably underdiagnosed because of lack of awareness, and it was interesting that Pangan and Robinson drew the same conclusion 16 years later.

IAN HASLOCK, MD, FRCP, Consultant Rheumatologist, James Cook University Hospital, Middlesbrough, and Visiting Professor of Clinical Bioengineering, University of Durham, Durham, England.

#### REFERENCES

1. Pangan AL, Robinson D. Hemarthrosis as initial presentation of scurvy. *J Rheumatol* 2001;28:1923-5.
2. Dawes P, Haslock I. Haemarthrosis due to ascorbic acid deficiency. *Br J Clin Pract* 1985;39:290-1.
3. Haslock I. Case 31; scurvy. In: Dieppe PA, Bacon PA, Bamji AN, Watt I, editors. *Slide atlas of rheumatology: Vol 23. Miscellaneous conditions*. London: Gower Medical; 1984:23.15.