

Correspondence



INSTRUCTIONS FOR LETTERS TO THE EDITOR

Editorial comment in the form of a Letter to the Editor is invited; however, it should not exceed 800 words, with a maximum of 10 references and no more than 2 figures (submitted as camera ready hard copy per Journal Guidelines) or tables and no subdivision for an Abstract, Methods, or Results. Letters should have no more than 3 authors. Full name(s) and address of the author(s) should accompany the letter as well as the telephone number, fax number, or E-mail address.

Contact. The Managing Editor, The Journal of Rheumatology, 920 Yonge Street, Suite 115, Toronto, Ontario M6J 3G7, CANADA. Tel: 416-967-5155; Fax: 416-967-7556; E-mail: jrheum@jrheum.com Financial associations or other possible conflicts of interest should always be disclosed.

Living with Lupus

To the Editor:

Dobkin, *et al*¹ reported psychosocial functioning of 120 women with systemic lupus erythematosus prospectively assessed during 15 months using a variety of measures. A significant beneficial time effect was found for some of the psychological variables, not necessarily paralleling disease activity. It would be of interest to know if patients' enrollment in lupus support groups was investigated. These organizations (e.g., Lupus Canada) often run a diversity of programs for patients and their relatives and the results may be reflected in the psychosocial assessments.

OSVALDO HUBSCHER, MD, Section of Rheumatology and Immunology, CEMIC, Buenos Aires, Argentina.

REFERENCE

1. Dobkin P, Da Costa D, Fortin P, et al. Living with lupus: a prospective pan-Canadian study. *J Rheumatol* 2001;28:2442-8.

Drs. Dobkin and Clarke reply

To the Editor:

In response to Dr. Hubscher's inquiry with regard to lupus patients' use of support groups we would like to clarify the form of the randomized clinical trial (RCT)¹ in which our subjects participated. At study entry, patients were randomly assigned to either (1) standard medical care or (2) standard medical care plus brief supportive-expressive group psychotherapy. The adjunct intervention (i.e., group psychotherapy) is a professionally led, 15 session program aimed at assisting patients to cope better with their disease. Results of the RCT¹ revealed there were no clinically important between-group differences for the primary outcomes, i.e., psychological distress, quality of life, disease activity, health service utilization, and diminished productivity; and for this reason we combined the 2 groups to describe living with lupus over a 15 month period¹. While group status did not contribute to the primary outcomes, subsequent secondary analyses using a measure of illness intrusiveness as an outcome showed that lupus patients in the brief supportive-expressive psychotherapy group improved

significantly more than the lupus patients in the standard medical care-only group in terms of relationships and personal development and intimacy at 6 and 12 months following the psychological intervention¹. Based on self-report data, 10 and 8 patients in the psychotherapy and control groups, respectively, sought psychological services and 32 and 12 patients in the psychotherapy and control groups, respectively, attended self-help groups during the trial.

PATRICIA L. DOBKIN, PhD; ANN E. CLARKE, MSc, MD, Division of Clinical Epidemiology, Montreal General Hospital Research Institute, 1650 Cedar Avenue, Montreal, Quebec H3G 1A4, Canada.

REFERENCES

1. Dobkin PL, Da Costa D, Joseph L, et al. Counterbalancing patient demands with evidence: results from a pan-Canadian randomized clinical trial of brief supportive-expressive group psychotherapy for women with systemic lupus erythematosus. *Ann Behav Med* 2002;24:88-99.
2. Dobkin P, Da Costa D, Fortin P, et al. Living with lupus: a prospective pan-Canadian study. *J Rheumatol* 2001;28:2442-8.
3. Edworthy S, Dobkin PL, Clarke AE, et al. Group psychotherapy reduces illness intrusiveness in systemic lupus erythematosus. (Submitted for publication.)



Sufficient Evidence to Consider Hydroxychloroquine as an Adjunct Therapy in Antiphospholipid Antibody (Hughes') Syndrome

To the Editor:

Antiphospholipid antibody syndrome (APS), or Hughes' syndrome, is an increasingly recognized acquired autoimmune thrombotic syndrome of importance. Despite our increasing understanding of the syndrome, the cornerstone of therapy remains antiaggregant and anticoagulant agents¹. Data from 2 large retrospective studies suggest that high intensity anticoagulant with an INR of 3.0-3.5 offers the best protection against recurrent thrombosis^{2,3}. Prospective trials are currently under way to ascertain the optimal intensity of oral anticoagulation⁴. But despite antithrombotic therapy, up to 30% of patients have further thrombotic events⁵. Hence other therapeutic modalities need to be explored. Hydroxychloroquine (HCQ), an antimalarial drug widely used for lupus and rheumatoid arthritis since the 1950s, may be a promising drug that warrants further attention in the pharmacotherapy of APS.

Wallace was the first to formally propose that HCQ be used to prevent thromboembolic events in lupus patients with antiphospholipid antibodies (aPL)⁶. However, since then few studies have been published to support or propose this indication. I summarize here the current clinical and experimental evidence supporting the use of HCQ as an adjunct therapy in APS.

Antimalarials have been shown to have many mechanisms of actions in the therapy of rheumatic diseases, including interruption of antigen processing, inhibition of cytokines, and antiinflammatory effects⁷. There is also a mild lipid lowering effect. In terms of antithrombotic effects, HCQ can inhibit, in a dose dependent manner, platelet aggregation induced by adenosine diphosphate, collagen, and rostocetin⁸. Inhibition of arachidonic acid release from thrombin-stimulated platelets and inhibition of

To continue
please scroll
to next page

intravascular aggregation of erythrocytes have also been demonstrated with antimalarials⁸. In a study by Edwards, *et al* using a mouse model of APS, HCQ significantly diminished both thrombus size and total time of thrombus formation in mice injected with IgG aPL compared with controls⁹. The effect was rapid in onset, and the thrombus size reduction was also altered in a dose dependent manner.

Besides experimental data, there are several clinical studies to support the role of HCQ as a preventive agent in thromboembolism. Early trials in the 1970s in more than 12,000 surgical patients have shown a reduction of postoperative deep vein thrombosis and pulmonary embolism when HCQ was used in doses between 600 mg and 1600 mg during the perioperative period¹⁰⁻¹². Another clinical study in postoperative patients found that HCQ significantly reduced plasma and whole blood viscosity¹³.

In patients with systemic lupus erythematosus (SLE), it was first shown by Wallace's group that SLE patients taking HCQ had fewer thrombotic events¹⁴. A followup study in 96 SLE patients with positive anticardiolipin antibodies showed that 11% of those taking HCQ compared with 20% of those without HCQ had thromboembolic events¹⁵. Petri, *et al* from the Johns Hopkins lupus cohort also demonstrated that HCQ usage in SLE patients was associated with a lower odds ratio of 0.36 for thromboembolic events and a reduced dilute Russell's viper venom time¹⁶. A recent study from the Indiana APS Database Project, involving 242 patients, reported that HCQ at 200 mg bid in combination with low dose aspirin were able to reduce APS-related features of migraine, livedo reticularis, and transient ischemic attacks, together with a sustained decrease in aPL titers by 3-6 months.¹⁷ Over a 4 year followup period, there were only 4 thrombotic events in this group and no ocular or gastrointestinal toxicities were documented.

In summary, there is sufficient clinical and experimental data to suggest the use of HCQ as an adjunct antithrombotic and immunomodulatory agent in APS. Large scale randomized controlled trials should be done to further validate the efficacy of HCQ in this regard.

Meanwhile, my practice is to use HCQ as an adjunct therapy in high risk APS subgroups with recurrent thrombosis despite anticoagulation and high aPL titers, and in those who cannot tolerate or have difficulty achieving an adequately high therapeutic INR ratio. There may also be a role for HCQ as primary prophylaxis in patients with a positive aPL but no thrombosis, as longterm followup has shown that up to 50% of patients can develop thrombotic events⁴. Currently aspirin is given empirically, although a trial is under way to evaluate the efficacy of aspirin plus low intensity oral anticoagulation¹⁸.

KAM HON YOON, MBBS (Singapore), M Med(Int Med), MRCP(UK),
Division of Rheumatology, Department of Medicine, National
University Hospital, National University of Singapore, Singapore.

REFERENCES

1. Ruiz-Irastorza G, Khamashta MA, Hughes GRV. Antiaggregant and anticoagulant therapy in systemic lupus erythematosus and Hughes' syndrome. *Lupus* 2001;10:241-5.
2. Khamashta MA, Cuadrado MJ, Mujic F, Taub NA, Hunt BJ, Hughes GRV. The management of thrombosis in the antiphospholipid-antibody syndrome. *N Eng J Med* 1995; 332:993-7.
3. Rosove MH, Brewer PMC. Antiphospholipid thrombosis: clinical course after the first thrombotic event in 70 patients. *Ann Intern Med* 1992;117:303-8.
4. Shah NM, Khamashta MA, Atusmi T, Hughes GRV. Outcome of patients with anticardiolipin antibodies: A ten year follow-up of 52 patients. *Lupus* 1998;7:3-6.
5. Wallace DJ. Antimalarial agents and lupus. *Rheum Dis Clin North Am* 1994;20:243-63.
6. Bertrand E, Cloitre B, Ticolet R, et al. Antiaggregant action of chloroquine. *Med Trop Mars* 1990;50:143-6.
7. Janicinova V, Nasal R, Petrikova M. On the inhibitory effect of

chloroquine on blood platelet aggregation. *Thromb Res* 1994;74:495-504.

8. Nasal R, Janicinova V, Petrikova M. Chloroquine inhibits stimulated platelets at the arachidonic acid pathway. *Thromb Res* 1995;77:531-42.
9. Edwards MH, Pierangeli S, Liu XW, Barker JH, Anderson G, Harris N. Hydroxychloroquine reverses thrombogenic properties of antiphospholipid antibodies in mice. *Circulation* 1997;96:4380-4.
10. Carter A, Eban R. Prevention of postoperative deep vein thrombosis in legs by orally administered hydroxychloroquine sulphate. *BMJ* 1974;3:94-5.
11. Johnson R, Green J, Charnley J. Pulmonary embolism and its prophylaxis following the Charnley total hip replacement. *Clin Orthop* 1977;127:123-32.
12. Johnson R, Orth MC, Charnley J. Hydroxychloroquine in prophylaxis of pulmonary embolism following hip arthroplasty. *Clin Orthop* 1979;144:174-7.
13. Ernst E, Rose M, Lee R. Modification of transoperative changes in blood fluidity by hydroxychloroquine: a possible explanation for the drug's antithrombotic effect. *Pharmatherapeutica* 1984;4:48-52.
14. Wallace DJ. Does hydroxychloroquine protect against clot formation in systemic lupus erythematosus? *Arthritis Rheum* 1987;30:1435-6.
15. Wallace DJ, Linker-Israeli M, Metzger AL, Stecher VJ. The relevance of antimalarial therapy with regard to thrombosis, hypercholesterolemia and cytokines in SLE. *Lupus* 1993;2 Suppl 1:S13-15.
16. Petri M, Hochberg, Hellmann D, Bell W, Goldman D. Incidence and predictors of thrombotic events in SLE: protective role of hydroxychloroquine [abstract]. *Arthritis Rheum* 1992;35 Suppl 9:S54.
17. McCarty GA. Hydroxychloroquine (HCQ) treatment in antiphospholipid antibody syndrome (APS): time course of clinical improvement and antiphospholipid antibody (aPL) titer changes over 4 years [abstract]. *Arthritis Rheum* 2000;43 Suppl 9:S1061.
18. Khamashta MA. Primary prevention of thrombosis in subjects with positive antiphospholipid antibodies. *J Autoimmun* 2000;15:249-53.

Primary Angiitis of the Central Nervous System in Children: 10 Cases Proven by Biopsy

To the Editor:

Gallagher, *et al*¹ describe 5 children with primary angiitis of the central nervous system (PACNS). Children presented with ischemic stroke (n = 3), cerebral hematoma (n = 1), or recurrent headaches, emesis and vertigo (n = 1). Cerebral angiography revealed multifocal arterial stenoses or occlusions consistent with CNS vasculitis. Conditions mimicking PACNS were excluded by clinical evaluation and investigation. In no instance, however, was a CNS biopsy attempted. Children received corticosteroid agents alone (n = 1) or combined with cytotoxic drugs (n = 4), and survived with (n = 4) or without residual neurologic deficit (n = 1).

These authors asserted that only 5 other children with PACNS had been previously reported. Unfortunately, they did not describe their literature search strategy and overlooked several other reports of childhood PACNS either defined by angiography^{2,3} or confirmed by pathology⁴. We recently reviewed the literature on childhood PACNS documented by pathology (8 cases) and reported 2 additional cases⁴. Using cerebral angiography and pathology to determine the size of the affected CNS blood vessels, we classified patients into 2 groups.

Group 1: PACNS affecting large and medium size arteries. Children in this group (n = 5) reached medical attention following ischemic stroke (n = 2), subarachnoid hemorrhage (n = 2), or transient ischemic attack (n = 1). Cerebral angiography, in 3 children, showed single or multiple intracranial aneurysms (n = 2), showed multiple arterial stenoses (n = 1), or was normal

(n = 1). Four children died of neurologic complications of acute stroke within 10 days of presentation. The 5th child had recurrent intracranial aneurysm ruptures and lapsed into a persistent vegetative state. Pathologic analysis of one resected aneurysm disclosed inflammatory infiltration of the aneurysm wall. He did not receive immunosuppressive therapy and died 7 years after presentation. In this group, autopsy showed a granulomatous infiltration of large and medium CNS arteries (n = 5) and inconsistent extension to small CNS arteries (n = 2).

Group 2: PACNS affecting small vessels. Children in this group (n = 5) had gradual symptom onset consisting of persistent headaches (n = 3), additive multifocal neurologic deficits (n = 2), and neurobehavioral impairment (n = 2), and presented with focal seizures (n = 3). Neuroimaging showed multifocal cerebral infarcts (n = 3) or gadolinium enhancing tumor-like lesions (n = 2). Cerebral angiograms were normal (n = 4) or showed a single small artery stenosis (n = 1). In this group, a diagnosis of nongranulomatous PACNS was established by CNS biopsy. Children were treated with prednisone alone (n = 2) or in combination with cyclophosphamide (n = 3). Four children had a favorable outcome with clinical stabilization or improvement. One child experienced seizures and progressive cognitive decline and died of status epilepticus 18 months after presentation.

The article of Gallagher, *et al*¹ and our own⁴ illustrate the wide spectrum of clinical manifestations, investigation results, pathologic features, and outcomes of childhood PACNS in different populations — defined by cerebral angiography versus pathology. We would stress that PACNS affecting small CNS vessels, which is the typical form in adults⁵, also exist in children (group 2) and should be recognized. Patients with small vessel involvement are more likely to experience a progressive disease course, with relapsing or persistent headaches, focal seizures, neurobehavioral impairment, and multifocal neurologic deficits, that reflects cumulative cerebral lesions. Cerebral angiograms are usually unremarkable because the caliber of affected vessels is often below the resolution of this technique. Confirmation of the disease relies on CNS biopsy.

We agree with Gallagher, *et al* that involvement of large and medium size arteries may be more frequent in children (group 1 and series reported by Gallagher, *et al*) than adults with PACNS. When large and medium size CNS arteries are affected, children are likely to present with acute ischemic or hemorrhagic stroke, and may die of stroke complications. However, as exemplified by Gallagher, *et al*, a favorable response to immunosuppression can be expected in stroke survivors. Cerebral angiography generally shows vascular changes consistent with (but not specific for) CNS vasculitis. CNS biopsy can be falsely negative if the disease is restricted to large cerebral arteries not sampled by this procedure. Because coexisting involvement of small CNS vessels has been reported in some children⁴, we believe that CNS biopsy should be considered in all cases.

Our approach in children with suspected PACNS is to attempt to document the diagnosis of CNS vasculitis and to exclude PACNS mimics (e.g., intracranial infection, autoimmune diseases, and prothrombotic conditions) by brain and leptomeningeal biopsy of an approachable, radiologically affected area before initiating immunosuppressive therapy. Subarachnoid hemorrhage from ruptured aneurysm is unusual in childhood and should raise the possibility of PACNS. Clipped intracranial aneurysms should be biopsied whenever feasible and submitted for pathologic analysis. Also, whenever treatment of a peripherally located aneurysm consists in occluding its proximal artery, the sacrificed distal segment of artery should be studied by pathology.

SYLVAIN LANTHIER, MD, Division of Neurology, Stroke Unit, Centre Hospitalier de l'Université de Montréal, 1560 Sherbrooke East, Montreal, Quebec, Canada H2L 4M1.

REFERENCES

1. Gallagher KT, Shaham B, Reiff A, et al. Primary angiitis of the central nervous system in children: 5 cases. *J Rheumatol* 2001;28:616-23.
2. Ilhan A, Budak F. Primary angiitis of the central nervous system:

unusual clinical presentation. *Int J Angiol* 2000;9:23-6.

3. Bettoni L, Juvarrá G, Bortone E, Lechi A. Isolated benign cerebral vasculitis: case report and review. *Arch Neurol Belg* 1984; 84:161-73.
4. Lanthier S, Lortie A, Michaud J, Laxer R, Jay V, de Veber G. Isolated angiitis of the CNS in children. *Neurology* 2001; 56:837-42.
5. Calabrese LH, Duna GF, Lie JT. Vasculitis in the central nervous system. *Arthritis Rheum* 1997;40:1189-201.

Liver Manifestations in Systemic Lupus Erythematosus: High Incidence of Hemophagocytic Syndrome

To the Editor:

Systemic lupus erythematosus (SLE) is an immunologically mediated disease characterized by multiple organ involvement. While it is well established that involvement of kidneys or central nervous system vitally affects the prognosis of SLE, liver involvement is also observed and can be responsible for undesired outcome^{1,2}. Runyon, *et al*³ reported that serum markers for liver function were abnormally elevated in 124 of 206 patients with SLE (60.1%). Fatty degeneration was the most frequent pathological finding in evaluated patients. Gibson, *et al*⁴ and Miller, *et al*⁵ reported that liver disorders were present in 42.2% and 19.7% of patients with SLE, respectively.

Hemophagocytic syndrome (HPS) is a clinicopathological entity characterized by systemic proliferation of benign hemophagocytic cells of the monocyte-macrophage-histiocyte lineage. The syndrome is characterized by clinical manifestations including fever, cytopenia, liver dysfunction, and lymphadenopathy⁶. Wong, *et al* reported that the bone marrow of patients with SLE can manifest a reactive hemophagocytosis, and proposed this be referred to as lupus hemophagocytic syndrome⁷. Since then, cases of HPS with collagen diseases such as SLE, systemic sclerosis, and rheumatoid arthritis have been reported⁸⁻¹⁰.

The reports of liver dysfunction in patients with SLE^{4,5} predate the description of HPS. To determine whether HPS is present in lupus patients, we reviewed the charts of all patients seen in the past decade at Yokohama City University Hospital. Eighty patients with lupus (who had ≥ 4 of the American College of Rheumatology classification criteria) were identified. Among these, 73 had elevated serum AST and/or ALT levels (normal 32 U/ml and 25 U/ml, respectively). The characteristics of these 73 patients are as follows. The male to female ratio was 4:69. Their mean age at onset of SLE was 30.4 years (range 13–53), the mean age at the onset of AST/ALT elevation was 36.7 years (range 15–67), and the mean duration between SLE onset and AST/ALT elevation was 6.4 years (range 0.1–27.7). The mean values of elevated AST and ALT were 135 and 145 U/ml, respectively.

The possible etiology of these elevated liver function tests (LFT) was sought in each subject (e.g., drug toxicity, infection, HPS, fatty liver, myositis, hemolytic anemia, etc.). Liver dysfunction was attributed to SLE if (1) no other reason for the AST/ALT elevation could be found, (2) lupus was active, and (3) LFT abnormalities resolved after therapy with steroid and/or immunosuppressants. Table 1 shows the causes, number of patients, mean values of AST and ALT and duration between SLE onset and AST/ALT elevation, and incidence. "Unknown" was the most frequent cause of the elevation of AST/ALT. Although we could not clarify the cause in 43 patients, most showed mild and transient elevations of AST/ALT that improved spontaneously. Fatty liver and drug induced AST/ALT elevation occurred in 8 patients each (11.0%), and their average AST levels were 54.5 and 244.0 U/ml, respectively. HPS was diagnosed in 7 patients (9.6%) and their mean AST levels were markedly high (494.4 U/ml) compared to all other groups. Active SLE and myositis were identified as the cause of AST elevation in 3 patients (4.1%), yielding AST levels of 245.7 and 110.7 U/ml, respectively.

Table 1. Causes of elevation of serum aspartate aminotransaminase and/or alanine aminotransaminase in patients with SLE.

Cause	Number (%)	AST, U/ml, mean \pm SD	ALT, U/ml, mean \pm SD	Duration, yrs, mean \pm SD	Incidence/100 person-yrs
Unknown	43 (58.9)	67.7 \pm 115.1	84.8 \pm 129.4	7.6 \pm 7.3	8.2
Fatty liver	8 (11.0)	54.5 \pm 23.7	67.4 \pm 34.4	3.9 \pm 4.3	1.5
Drug induced	8 (11.0)	244.0 \pm 391.2	391.0 \pm 704.1	7.3 \pm 7.1	1.5
Hemophagocytic syndrome	7 (9.6)	494.4 \pm 553.1	366.2 \pm 434.8	4.2 \pm 5.3	1.3
Active SLE	3 (4.1)	245.7 \pm 253.6	180.0 \pm 170.5	5.7 \pm 9.7	0.6
Myositis	3 (4.1)	110.7 \pm 62.0	45.0 \pm 27.8	2.1 \pm 2.6	0.6
Heart failure	1 (1.3)	34.0	27	0.1	0.2
Total	73 (100)	135	145	6.4	13.9

The mean age of the 7 patients with HPS was 39.4 years (range 24–53) and the duration of their SLE until onset of HPS was 4.2 years (range 0.1–13.3). As noted, this group had the greatest elevation of AST of any group studied (494.4 U/ml, range 84–1463). The mean level of ferritin was 14,671 mg/dl (range 380–84,651, data not shown). Five of these HPS patients had active SLE (data not shown). All 7 patients improved after steroid therapy (alone or combined with plasmapheresis/cyclosporin A). Optimally, the diagnosis of HPS would have been confirmed based on the Imashuku diagnostic criteria¹¹. Since our study involved a retrospective chart review, that confirmatory data could not be obtained. Despite these limitations, our results suggest that HPS is a major cause of liver dysfunction in SLE.

We demonstrate that a majority of patients with SLE (91.3%) experienced elevated AST/ALT during the course of their disease. While there were many causes for these elevated LFT, HPS represents one of the most serious and life-threatening. HPS is not widely appreciated as a common cause of liver dysfunction in SLE. However, the report of 7 SLE patients with HPS from Wong, *et al*⁷ established the potential importance of this disease. Our study confirms and extends that conclusion, by establishing that HPS may be a complication in nearly 10% of SLE patients with elevated LFT.

TAKASHI TSUJI, MD, PhD; SHIGERU OHNO, MD, PhD; YOSHIAKI ISHIGATSUBO, MD, PhD, Professor and Chairman, First Department of Internal Medicine, Yokohama City University, 3-9 Fukuura, Kanazawa-ku, Yokohama 236-0004, Japan.
E-mail: ishigats@med.yokohama-cu.ac.jp

REFERENCES

- Wallace DJ. Gastrointestinal manifestations and related liver and biliary disorders. In: Wallace DJ, Hahn BH, editors. *Dubois' lupus erythematosus*. 4th ed. Philadelphia: Lea and Febiger; 1993:410-7.
- Mackay IR. Hepatic disease and systemic lupus erythematosus: coincidence or convergence. In: Lahita RG, editor. *Systemic lupus erythematosus*. 3rd ed. San Diego: Academic Press; 1999:747-63.
- Runyon BA, Labrecque DR, Anuras S. The spectrum of liver disease in systemic lupus erythematosus: report of 33 histologically-proved cases and review of the literature. *Am J Med* 1980;69:187-94.
- Gibson T, Myers AR. Subclinical liver disease in systemic lupus erythematosus. *J Rheumatol* 1981;8:752-9.
- Miller MH, Urowitz UB, Gladman DD, Blendis LM. The liver in systemic lupus erythematosus. *Q J Med* 1984;211:401-9.
- Janka G, Imashuku S, Elinder G, Schneider M, Henter JI. Infection and malignancy associated hemophagocytic syndromes. Secondary hemophagocytic lymphohistiocytosis. *Hematol Oncol Clin North Am* 1998;12:435-44.
- Wong KF, Hui PK, Chan JKC, Chan YW, Ha SY. The acute lupus hemophagocytic syndrome. *Ann Intern Med* 1991;114:387-90.

- Takahashi K, Kumakura S, Ishikura H, Murakawa Y, Yamauchi Y, Kobayashi S. Reactive hemophagocytosis in systemic lupus erythematosus. *Intern Med* 1998;37:550-3.
- Kumakura S, Ishikura H, Umegae N, Yamagata S, Kobayashi S. Autoimmune-associated hemophagocytic syndrome. *Am J Med* 1997;102:113-5.
- Onishi R, Namiuchi S. Hemophagocytic syndrome in a patient with rheumatoid arthritis. *Intern Med* 1994;33:607-11.
- Imashuku S. Differential diagnosis of hemophagocytic syndrome: underlying disorders and selection of the most effective treatment. *Int J Hematol* 1997;66:135-51.

Wegener's Granulomatosis Associated with Common Variable Immunodeficiency

To the Editor:

Five to 10%¹ of patients with common variable immunodeficiency (CVID) develop noncaseating granulomatous lesions with or without symptoms. To our knowledge, Wegener's granulomatosis (WG) has never been described in the course of CVID. In September 1996, a 68-year-old woman was admitted to hospital for fever and sinusitis. White blood cell count was 5160/mm³ (polymorphonuclear leukocytes 50%, lymphocytes 34%) and erythrocyte sedimentation rate (ESR) was 53 mm/h. Antineutrophil cytoplasmic antibodies (ANCA) were negative. Serum angiotensin converting enzyme (ACE) and lysozyme levels were normal. Serum immunoglobulin levels were 0.23 g/l for IgA (normal 0.81–2.58), 3.65 for IgG (6.4–12.4), 0.39 for IgM (0.52–1.49). CD4 T cells were 637/mm³ and circulating B cells were 33/mm³ (1.7%, normal 5–20%). The diagnosis of CVID was established. A thoracic computed tomography (CT) scan showed infiltration of the left upper lobe associated with multiple pulmonary nodules. A lung biopsy showed a fibrinous alveolitis. She seemed to improve with a 15 day amoxicillin regimen, and 12 months later pulmonary nodules had disappeared. In March 1998, she had recurrent bronchitis; her cANCA level was 1/40 with antiproteinase 3 (PR3) specificity and ESR was 32 mm/h. A substitutive intravenous immunoglobulin (IVIg) therapy was started. In April 1999, she complained of dysphagia. A laryngeal ulcerated tumor of 5 cm diameter was discovered. Biopsy specimens showed palisading epithelioid histiocyte granulomas with features of necrotizing vasculitis. A localized form of WG was diagnosed. The course and the treatment are described in Table 1. In January 2002, she was asymptomatic. Laryngeal examination found a small cicatricial defect and the laryngeal tumor had completely disappeared on CT scan. CD4 T cell count was 282/mm³.

CVID is the most frequent primary antibody deficiency syndrome. This disorder, characterized by hypogammaglobulinemia and recurrent bacterial infections, is a heterogeneous syndrome². The spectrum of the diseases associated with CVID is broad. Autoimmune diseases and malignant or nonmalignant tumor can develop in such patients and a noncaseating gran-

Table 1. The disease course and treatment.

	Sept 1996	March 1998	April 1999	Feb 1999	Nov 2000	Jan 2002
Clinical symptoms	Fibrinous alveolitis	Recurrent bronchitis	Laryngeal ulceration	Increase of laryngeal lesion	Total remission without recurrent infection	Asymptomatic
Treatment	Amoxicillin ANCA < 0	IVIG 40 g/mo ANCA 1/40	IVIG 2 g/kg/mo PDS 0.7 g/kg T/S 1 tablet/day	IVIG 40 g/mo CYC 100 mg/day PDS 20 mg/day T/S 1 tablet/day	IVIG 40 g/mo CYC 100 mg/day PDS 10 mg/day T/S 1 tablet/day	IVIG 30 g/mo CYC 50 mg/day PDS 10 mg/day T/S 1 tablet/day

IVIG: intravenous immunoglobulin, CYC: cyclophosphamide, T/S: trimethoprim (160 mg)-sulfamethoxazole (800 mg), PDS: prednisone.

uloma may also occur in the lymph nodes, solid organs, central nervous system, or the skin¹. Less frequently, features of sarcoidosis⁴ have been described. On the other hand, the association of CVID and WG has not been reported before.

In our case, the diagnosis of a localized form of WG is supported by the location of the ulceration, the histological findings, and normal values of ACE and lysozyme. WG is most frequently a systemic disease, but it may be located (without renal or lung involvement) in a single site. It is now a well recognized and distinct subtype of this disease. The ENT area is the most frequent site of the localized form of WG¹. The detection of ANCA (anti-PR3) before IVIG therapy was started argues in favor of this diagnosis. The slight ANCA titer is probably explained by the underlying disease, and the fact that the value of ANCA is often correlated to the activity and extent of the inflammatory disease. The combination therapy with IVIG and cyclophosphamide was well tolerated.

After 22 months of treatment, no infectious complications have occurred and clinical recovery of the laryngeal disease is now complete. This case suggests that other kinds of granulomatous diseases such as WG may be associated with CVID, and that conventional treatment by immunosuppressive agents such as cyclophosphamide may be well tolerated despite the underlying disease (CVID).

ISABELLE DELÈVAUX, MD; MARC ANDRÉ, MD;
OLIVIER AUMAÎTRE, MD, Department of Internal Medicine, Hôpital Gabriel Montpied, BP 69, 63003 Clermont-Ferrand Cedex 1, France.
E-mail: oaumaitre@chu-clermontferrand.fr

REFERENCES

1. Mechanic LJ, Dikman S, Cunningham-Rundles C. Granulomatous disease in common variable immunodeficiency. *Ann Intern Med* 1997;127:613-7.
2. Spickett GP, Farrant ME, North ME, et al. Common variable immunodeficiency: how many diseases? *Immunol Today* 1997;19:325-8.
3. Mouthon L, Cohen P, Larroche C, et al. Déficit immunitaire commun variable: une ou plusieurs maladies? *Ann Med Interne* 1999;150:275-82.
4. Fasano MB, Sullivan KE, Sarpon SB, et al. Sarcoidosis and common variable immunodeficiency. Report of 8 cases and review of the literature. *Medicine* 1996;75:251-61.
5. Ahmad I, Lee WC, Nagendran V, Wilson F, Shortridge RT. Localised Wegener's granulomatosis in otolaryngology: a review of six cases. *ORL J Otorhinolaryngol Relat Spec* 2000;62:149-55.

Wegener's Granulomatosis Mimicking Psoas Abscess

To the Editor:

Psoas abscess is a rare condition often presenting with nonspecific symptoms, usually resulting from dissemination of a distant infection^{1,2}. Other

diseases such as plasmacytomas, lymphomas, and foreign body pseudotumors may mimic psoas abscess^{1,4,5}. Wegener's granulomatosis (WG) is a multisystem disease where necrotizing small vessel vasculitis and granuloma formation usually occur in (upper) airways and kidneys. While articular symptoms are frequent, muscle weakness and myositis are rare^{6,7}. We describe the first case of granulomatous vasculitis in psoas muscle as a presentation of WG.

A 31-year-old female gas station employee, with known extrinsic allergic asthma and polycystic ovary syndrome, presented with a 6 week history of pain in the right sacroiliac region unresponsive to local and non-steroidal antiinflammatory drug therapy. After she developed fever and malaise, diagnostic investigations disclosed a pathological process in the region of the right psoas and quadratus lumborum region, which was also active on ^{99m}Tc scintigraphy. Laboratory findings: normocytic anemia, erythrocyte sedimentation rate 77 mm/h, C-reactive protein 266 mg/l, normal results for serum creatinine, liver enzymes, and urine dipstick. Empirical therapy with intravenous cloxacillin was started after 2 percutaneous aspirations failed to produce microorganisms.

Despite broadened antibiotic coverage, no clinical improvement had occurred after one week, with no changes on magnetic resonance image scanning (Figure 1). Serum creatinine levels rose to 269 mmol/l, initially ascribed to nephrotoxic antibiotics that were discontinued. A new rash then prompted a rheumatologic consultation, and a more detailed history revealed chronic sinusitis, 12 kg weight loss, and fluctuating rashes and joint pains, with swelling during the preceding months. Examination revealed right sided conjunctival bleeding, petechial rash on abdomen and lower extremities, ulcers on lower lip, right heel and perineum, and oligoarthritis (right wrist, several metacarpophalangeal joints, and both knees). Proteinuria was at 5.6 g/24 h, and the urinary sediment contained > 20 erythrocytes and > 10 granular casts. An ELISA test for serum antibodies against proteinase-3 was positive (titer 17 U, normal < 12), while antibodies against myeloperoxidase and antinuclear antibodies were not present. Computed tomographic (CT) scanning disclosed bilateral mucosal thickening in the maxillary sinus, with chronic unspecific inflammation upon biopsy. Skin biopsy from areas adjacent to ulcers revealed necrotizing vasculitis and granulomatous infiltrates containing giant cells.

WG was diagnosed and before institution of immunosuppressive therapy another CT guided attempt was made to obtain material from the right psoas muscle. Cultures were sterile, but a 2 mm tissue sample showed striated muscle with a small artery with thickened wall infiltrated by lymphocytes and granulocytes, surrounded by a small granuloma-like formation (Figure 2). Therapy was started with methylprednisolone 1000 mg intravenously on 3 consecutive days followed by oral prednisolone 30 mg daily with gradual tapering, and biweekly intravenous pulse therapy with cyclophosphamide (15 mg/kg). Defervescence, improved well being, disappearance of the rash with gradual ulcer healing, and improvement of renal function soon followed. A deep venous thrombosis of the left calf (confirmed by ultrasound) with pulmonary embolism (confirmed by spiral CT) occurred during reconvalescence and was successfully managed with anticoagulants (antiphospholipid antibodies were absent).

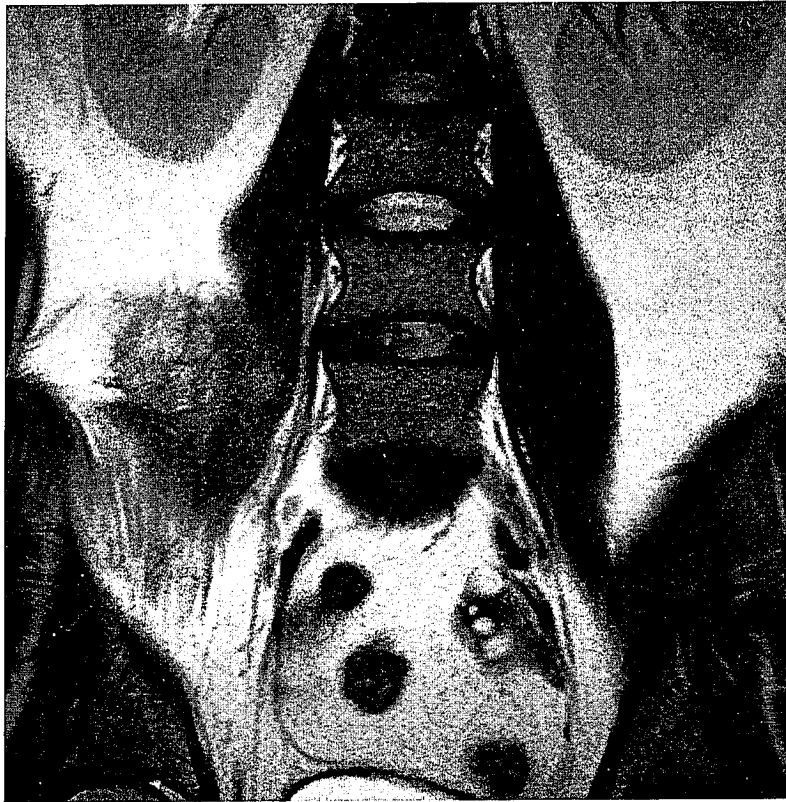


Figure 1. Abdominal MRI scan showing a poorly defined multiloculated right side mass in the m. psoas/lumbar quadratum area.

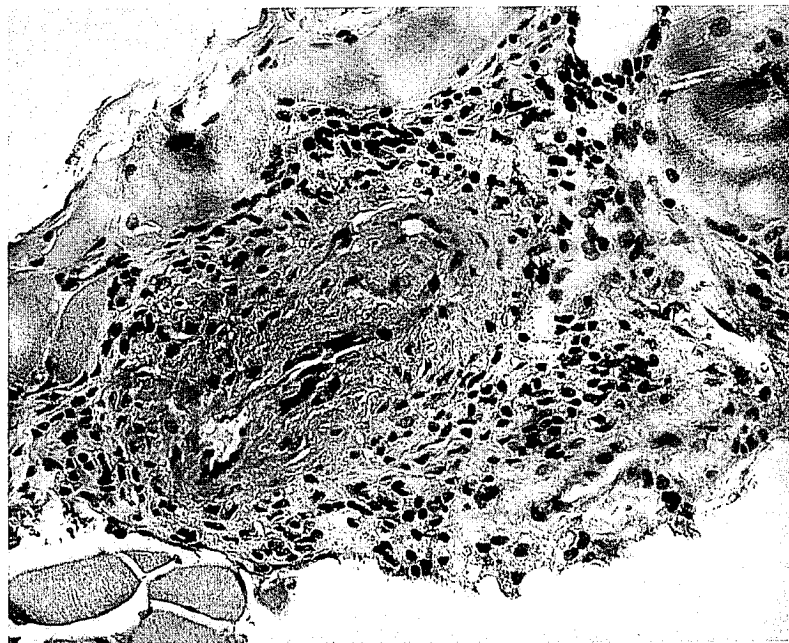


Figure 2. Microscopic findings of CT guided biopsy material from the right m. psoas. A small intramuscular artery with subacute vasculitis is present. There is infiltration of mainly mononuclear and some granulocytes in the vessel wall and the surrounding tissue with signs of necrosis and fibrinous deposits.

One month after the start of treatment abdominal CT scanning showed nearly complete regression of the psoas process, with a few fibrotic strings remaining. At 12 months after diagnosis she was doing well despite some

residual nasal symptoms and serum creatinine is stable at 153 $\mu\text{mol/l}$. Antibodies against proteinase-3 are no longer present, but proteinuria persists at 5 g/24 h with sporadic erythrocytes in the sediment. Current pred-

nisonone dose is 5 mg daily and cyclophosphamide treatment intensity is being reduced, with a shift to maintenance therapy planned.

Both psoas abscess and WG are relatively rare conditions and may present with unspecific symptoms. Manifestations due to vasculitis and granulomas in WG can be protean⁶⁷. Musculoskeletal symptoms in the form of arthralgia or frank oligoarthritis are present in about one-third of WG patients at disease onset. Isolated muscle involvement is very rare; a recent Medline search using (poly) myositis and WG produced no relevant entries. This patient was diagnosed with and treated for a psoas muscle abscess with antibiotics aimed against *Staphylococcus aureus*, which is most prevalent in psoas abscesses in the Western world¹.

While failure to culture a causative microorganism — as in this case — does not preclude a psoas abscess diagnosis, it indicates the need to consider other causes of this syndrome¹. This case illustrates that primary systemic vasculitis must be included in the differential diagnosis of (presumed) psoas abscesses; earlier diagnosis might have led to fewer complications for this patient.

HANS NOSSENT, MD, PhD, Professor of Medicine, Institute for Clinical Medicine; TORMOD EGGEN, MD, Department of Pathology, University Hospital Tromsø, Tromsø, Norway.

REFERENCES

1. Taiwo B. Psoas abscess: a primer for the internist. *South Med J* 2001;94:2-5.
2. Huang JJ, Ruaan MK, Lan RR, Wang MC. Acute pyogenic iliopsoas abscess in Taiwan: clinical features, diagnosis, treatments and outcome. *J Infect* 2000;40:248-55.
3. Kadambari D, Jagdish S. Primary pyogenic psoas abscess in children. *Pediatr Surg Int* 2000;16:408-10.
4. Cortes-Blanco A, Martinez-Lazaro R. Lymphoma mimicking a psoas abscess on Ga-67 scintigraphy. *Clin Nucl Med* 2000; 25:567-8.
5. Negus S, Sidhu PS. MRI of retroperitoneal collections: a comparison with CT. *Br J Radiol* 2000;73:907-12.
6. Huang D, Zhou Y, Hoffman GS. Pathogenesis: immunogenetic factors. *Best Pract Res Clin Rheumatol* 2001;15:239-58.
7. Stone JH, Hoffman GS, Merkel PA, et al. A disease-specific activity index for Wegener's granulomatosis: modification of the Birmingham Vasculitis Activity Score. International Network for the Study of the Systemic Vasculitides (INSSYS). *Arthritis Rheum* 2001;44:912-20.

Book reviews

Disorders of Voluntary Muscle, 7th edition. G. Karpati, D. Hilton-Jones, and R.C. Griggs, editors, Cambridge, UK: Cambridge University Press, 2001, 775 pages, price \$220 (US).

This is the 7th edition of an important multi-author textbook and a valuable asset to basic scientists, neurologists, rheumatologists, and other physicians who manage and treat patients with muscle disease. The book may function as a quick bench-to-bedside reference or as a valuable in-depth and up-to-date resource.

In this edition a shift from an ultrastructural and histopathological perspective to a molecular and genetic perspective is seen. Chapters 1–7 review the basic biology of skeletal muscle including the structure and function of motor units, the developmental biology of skeletal muscle, and the molecular processes underlying normal muscle function. Skeletal muscle biochemistry and its relationship to disease, recovery, and rehabilitation are discussed in Chapter 8.

Chapters 9 and 10 expand on the bench-to-bedside theme as it relates to the neuromuscular junction and the muscle membrane.

Part 2 includes a condensed chapter on the neurophysiology of neuromuscular diseases, and several chapters describing muscle biopsy methodologies. An important addition is an updated chapter that describes the methodology and application of magnetic resonance imaging and spectroscopy to a wide range of muscle disorders including metabolic and inflammatory muscle disease.

Part 3 describes specific muscle syndromes and diseases. Chapter 17 is well illustrated and reviews the clinical features of muscle disease. This bottom-up clinical approach is a much needed reprieve from previous textbooks on muscle disease that have a top-down or biopsy guided perspective. The chapter on inflammatory myopathies is of particular relevance to the practicing rheumatologist. It reviews the important clinical features, pathological findings, and immunological mechanisms. A stepwise approach to treatment is outlined.

The book is well referenced, contains up-to-date material, and is well illustrated. It offers the reader a state-of-the-art reference for the diagnosis and treatment of muscle disease.

RALPH Z. KERN, MD, FRCPC, Department of Neurology, Mount Sinai Hospital and The University Health Network, Toronto ON, Canada.

Dubois' *Lupus Erythematosus*, 6th edition, Daniel J. Wallace, Bevra H. Hahn, editors. Philadelphia: Lippincott, Williams & Wilkins: 2001, 1376 pages, price \$199.00 US.

Regarded as one of the major reference works in the area of systemic lupus erythematosus (SLE), Dubois' 6th edition had been long awaited by many. While no major reorganization was accomplished, editors and authors have been able to integrate some of the recent concepts and update the information in previous editions. In the section on pathogenesis of SLE, we find a new chapter on cytokines that is well written and quite relevant. The chapters on tolerance and role of T cells have unfortunately disappeared from this section. This could probably have been integrated with the chapter on the role of B cells to form a new chapter on cellular immunity in SLE. In the autoantibody section, a new chapter on autoantibodies, autoantigens, and the nervous system is a good addition. The clinical manifestations and laboratory features section has been updated the most. The new chapters on cardiac, pulmonary, CNS, and ENT manifestations of SLE are particularly interesting and well written. The last section, on management and prognosis, where I was expecting the most changes, has actually had only a mild updating except for the chapter on immunosuppressants, which is new.

Overall, this is a complete reference book that is well written and well illustrated. It offers information that is up to date for a book of its size. Finally, the extensive referencing and complete index round up some of the qualities of this book. Welcome additions to the text would include chapters dedicated to late complications encountered in lupus patients as well as pediatric manifestations of SLE.

A book of this magnitude and focus is unfortunately not suited to everyone's needs. Although this would be a worthy reference book for any hospital library or rheumatology training program, other rheumatologists may not find such an extensive monogram useful in their daily practice. I would, nevertheless, recommend it to any sizeable institution or anyone with a particular interest in SLE.

CHRISTIAN A. PINEAU, MD, FRCPC, Assistant Professor of Medicine, Division of Rheumatology, McGill University Health Centre, Montreal, Quebec, Canada.