

# An Unknown Autoinflammatory Syndrome Associated with Short Stature and Dysmorphic Features in a Young Boy

ANDRÉ MÉGARBANÉ, AGNÈS SANDERS, ELIANE CHOUERY, VALÉRIE DELAGUE, MYRNA MEDLEJ-HASHIM, and PAUL-HENRI TORBEY

**ABSTRACT.** A young boy from nonconsanguineous Palestinian parents presented with short stature, motor developmental delay, wide nasal bridge, bilateral periorbital edema, everted lower lip, brachydactyly, large interphalangeal articulations, drumstick extremities of the fingers, bilateral simian crease, clinodactyly of the 5th fingers, painful joints, subcutaneous nodules all over his body and recurrent episodes of fever of unknown origin. Differential diagnoses such as the hyperimmunoglobulinemia D syndrome, tumor necrosis factor receptor associated periodic syndrome (TRAPS), the chronic infantile neurological cutaneous and articular (CINCA) syndrome, and the newly recognized nodulosis, arthropathy, and osteolysis (NAO) syndrome are discussed. This syndrome may not have been previously reported. (*J Rheumatol* 2002;29:1084–7)

*Key Indexing Terms:*

FEVER OF UNKNOWN ORIGIN  
SUBCUTANEOUS NODULES

PERIORBITAL EDEMA  
PAINFUL JOINTS

Autoinflammatory syndromes are systemic disorders characterized by apparently unprovoked inflammation in the absence of high titer autoantibodies or antigen-specific T lymphocytes<sup>1</sup>. The hyperimmunoglobulinemia D syndrome (HIDS), familial Mediterranean fever, systemic onset juvenile rheumatoid arthritis, the nodulosis, arthropathy and osteolysis (NAO) syndrome, the tumor necrosis factor (TNF) receptor associated periodic syndrome (TRAPS), and the chronic infantile neurological cutaneous and articular (CINCA) syndrome are part of this group.

We describe a patient with short stature, dysmorphic features, brachydactyly, large interphalangeal articulations, and unexplained episodes of fever with inflammation consisting of periorbital edema, painful joints, and subcutaneous nodules.

## CASE REPORT

The boy described here is the son of healthy nonconsanguineous parents

*From the Unité de Génétique Médicale, Laboratoire de Biologie Moléculaire et Cytogénétique, Faculté de Médecine, Université Saint-Joseph; Tahaddi Association; and the Service de Pédiatrie, Hôtel-Dieu de France de Beyrouth, Beirut, Lebanon.*

*Supported by grants from the Jérôme Lejeune Foundation.*

*A. Mégarbané, MD, PhD; E. Chouery, MA; V. Delague, PhD; M. Medlej-Hashim, PhD, Unité de Génétique Médicale, Université Saint-Joseph; A. Sanders, MD, Tahaddi Association; P-H. Torbey, MD, Service de Pédiatrie, Hôtel-Dieu de France de Beyrouth.*

*Address reprint requests to Dr. A. Mégarbané, Unité de Génétique Médicale, Faculté de Médecine, Université Saint-Joseph, 42 rue de Grenelle, 75007 Paris, France. E-mail: megarban@dm.net.lb*

*Submitted June 18, 2001; revision accepted October 3, 2001.*

who are Palestinian refugees in Lebanon. The boy has 3 healthy brothers and sisters. Three other sisters died at less than one week of age from unknown reasons. Medical followup during the pregnancy was not performed, but the parents did not recall any toxic exposures or unusual events during that period. Delivery was at 32 weeks of amenorrhea. At that time, the mother's age was 17 years, and the father's 18. Birth weight, length, and head circumference were not reported. At birth, the boy had a large nasal bridge, large interphalangeal articulations, and subcutaneous nodules all over his body (Figure 1). Since birth, he has had recurrent febrile attacks with fever as high as 39–40°C for 3–4 days without chills. Those episodes were accompanied by painful joints and periorbital edema, and followed by weakness lasting about a week. Results of investigations performed several times following those attacks were normal. Developmental delay was noted during the first years of life, as the boy was not able to walk without help until the age of 4 years.

At the time of report, the boy was 10 years old. His intellectual development seemed normal. On examination, his weight was 21.3 kg (< 3rd centile), height 118 cm (<< 3rd centile), and head circumference (OFC) 51 cm (10th centile). He presented with bilateral periorbital edema, wide nasal bridge, especially in its middle part, everted lower lip (edematous on the right side), bifid uvula, brachydactyly (hand length 13.5 cm: ~ 3rd centile), large interphalangeal articulations, drumstick extremities of the fingers, bilateral single palmar creases, clinodactyly of 5th fingers, and flat feet. Joints were painful but without limitation of articulations. Subcutaneous nodules were found all over his body, especially over the limbs, along with a few dark red cutaneous spots (Figure 2). No rashes were noted. The external genitalia were normal. Neurological examination was unremarkable, except for the presence of a mild waddling gait. Deep tendon and abdominal reflexes were present. Plantar responses were in flexion. Ophthalmological evaluation was normal. ENT examination disclosed a perforation of the left eardrum.

Skin specimens were obtained for biopsy and analyzed by 2 different pathologists. Both reported a leukocytoclastic vasculitis. Analysis of 2 subcutaneous nodules showed chronic lymphadenitis. The radiological examination of the skeleton was unremarkable except for the presence of a



Figure 1. The patient at age one year. Note the large nasal bridge and cutaneous spots on the legs.

slight external deviation of the last phalanges of both 2nd fingers. A magnetic resonance image of the brain showed no gross malformations. Abdominal ultrasounds, cardiac echography, and the auditory brainstem response were all normal.

Complete blood count, hemoglobin electrophoresis, blood glucose levels, urinalysis, amino acid assay of plasma and urine, urinary excretion for mucopolysaccharidosis, ceraminidase and mevalonic acid excretion in urine, liver and thyroid function studies, CPK, aldolase, LDH, and VDRL serology were all generally within normal levels. Tests for nDNA, RNP, Sm, SSA, SSB, SCl-70, JO1, and antiplatelet antibodies were negative. Antinuclear antibody result was positive. Elevated serum C-reactive protein levels were found. Chromosome study of lymphocytes with high resolution in G and R banding showed a normal 46,XY karyotype.

Mutations in the marenostirin/pyrin gene for familial Mediterranean fever were investigated by fluorescent sequencing of exon 10 and by polymerase chain reaction digestion for the E148Q mutation in exon 2. No mutation was identified.

## DISCUSSION

The main phenotypic manifestations of this patient consisted of short stature, dysmorphic features, brachydactyly, large interphalangeal articulations, and unexplained episodes of fever with inflammation consisting of periorbital edema, painful joints, and subcutaneous nodules. The

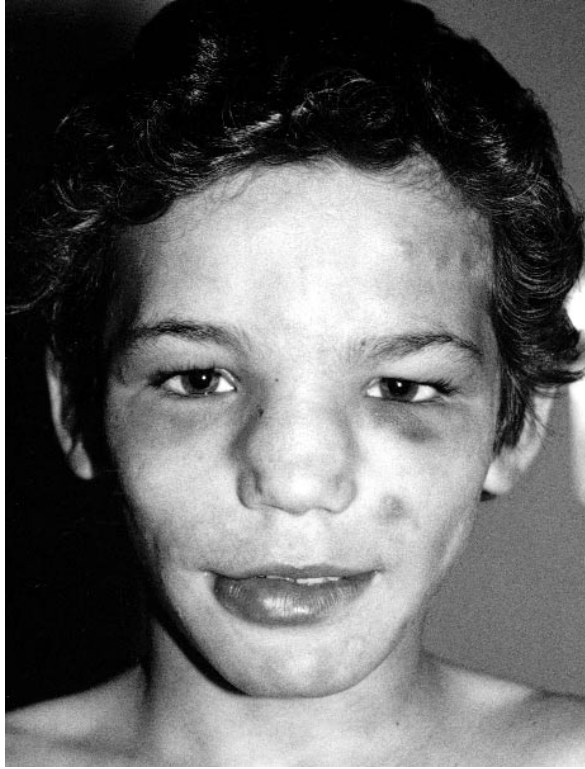disease started to manifest itself directly after birth, but had not caused any detectable psychomotor deterioration by age 10. Differential diagnoses were discussed that included autoinflammatory syndromes and syndromes or diseases that present with subcutaneous nodules and/or periorbital edema.

The hyperimmunoglobulinemia D syndrome is characterized by early onset of attacks of periodic fever and elevated serum polyclonal IgD (> 100 U/ml). Symptoms during attacks include joint inflammation, skin lesions, swollen lymph nodes, headache, and abdominal complaints<sup>2</sup>. In our patient, the normal value of IgD and urinary mevalonic acid allowed us to rule out this syndrome. Chronic infantile neurological cutaneous and articular syndrome is a chronic inflammatory illness that most often starts at birth and persists throughout life. It is characterized by a triad including arthropathy, cutaneous rash, and chronic meningitis<sup>3</sup>. Arthropathy was present in our patient, but the 2 other features of the triad were absent, allowing a simple differentiation. Finally, TNF receptor associated periodic syndrome, an inflammatory disorder characterized by prolonged episodes of periodic fever, localized inflammation, and a spectrum of dermatologic findings including migratory patches, edematous plaques, periorbital edema and/or conjunctivitis<sup>4</sup>, was not retained as a possible diagnosis as our patient never presented skin eruption or abdominal pain, but had short stature and dysmorphic features not reported in TRAPS. Also, skin biopsy specimen showed leukocytoclastic vasculitis but no perivascular dermal infiltrate of lymphocytes and monocytes, as observed in TRAPS<sup>4</sup>.

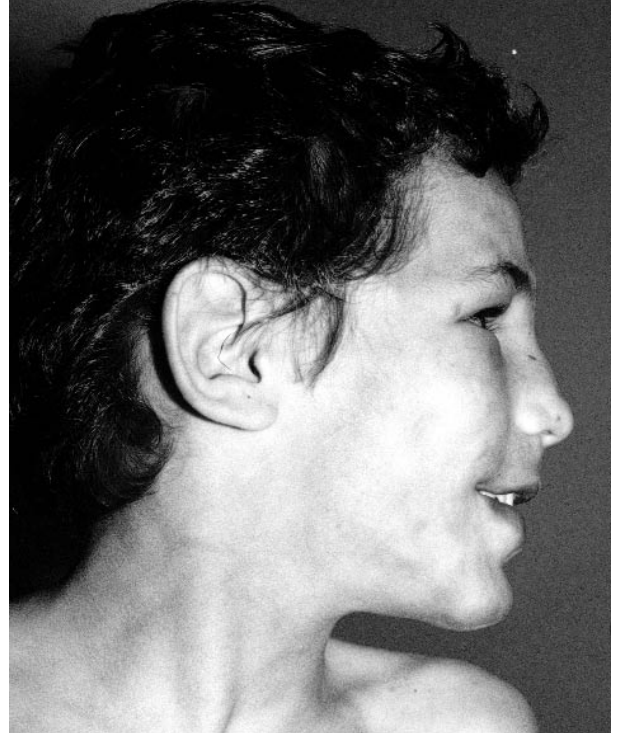
Systemic onset juvenile rheumatoid arthritis, juvenile hyaline fibromatosis, and Henoch-Schönlein disease may present with subcutaneous nodules, fever, painful joints, and a variety of other extraarticular features. They were ruled out as our patient showed no signs of arthritis, joint contractures, nodular skin lesions, generalized osteopenia, or any other signs typically associated with those entities. The newly recognized nodulosis, arthropathy, and osteolysis (NAO) syndrome<sup>5,6</sup> was ruled out as well, since our patient did not have osteolysis with carpal and tarsal resorption and osteoporosis, and because he had subcutaneous nodules all over his body, whereas it is confined to the palmar and plantar region in NAO syndrome.

Farber disease (MIM 228000), a rare condition that may present with painful joints, subcutaneous nodules, and intermittent fevers<sup>7</sup>, was ruled out because of the normal value of the acid ceramidase enzyme.

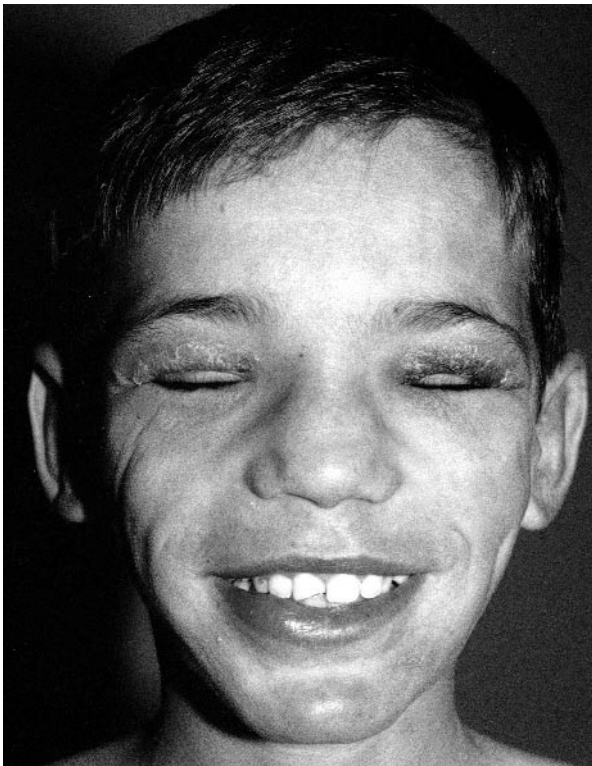Periorbital edema may occur initially or in the course of a wide variety of diseases such as hypo- or hyperthyroidism, hypoalbuminemia, angioedema, trichinosis, allergic reactions, neoplastic diseases, sarcoidosis, dermatomyositis, systemic lupus erythematosus (SLE), and lupus paniculitis (LP). From all these, only the last 3 were candidates for



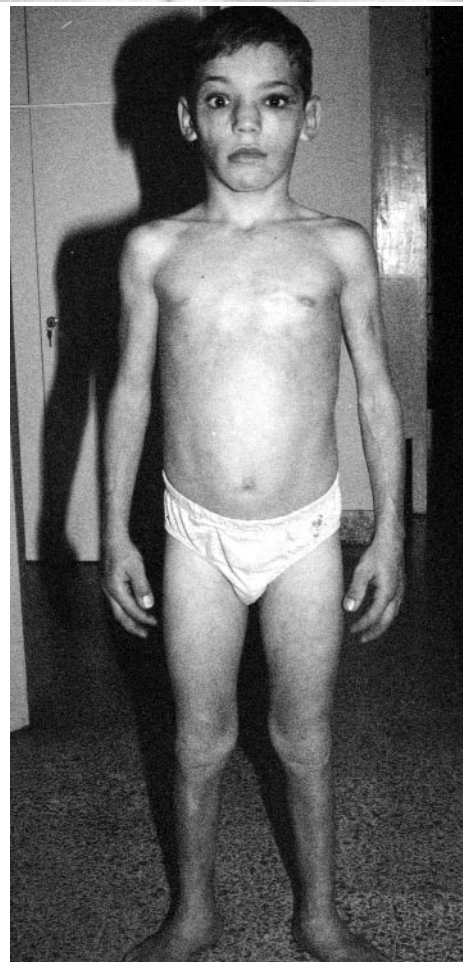
**A**



**B**



**C**



**D**

Figure 2. A–D. The patient at age 10 years. Note the bilateral periorbital edema, wide nasal bridge, dark cutaneous spots, and edematous everted lower lip.

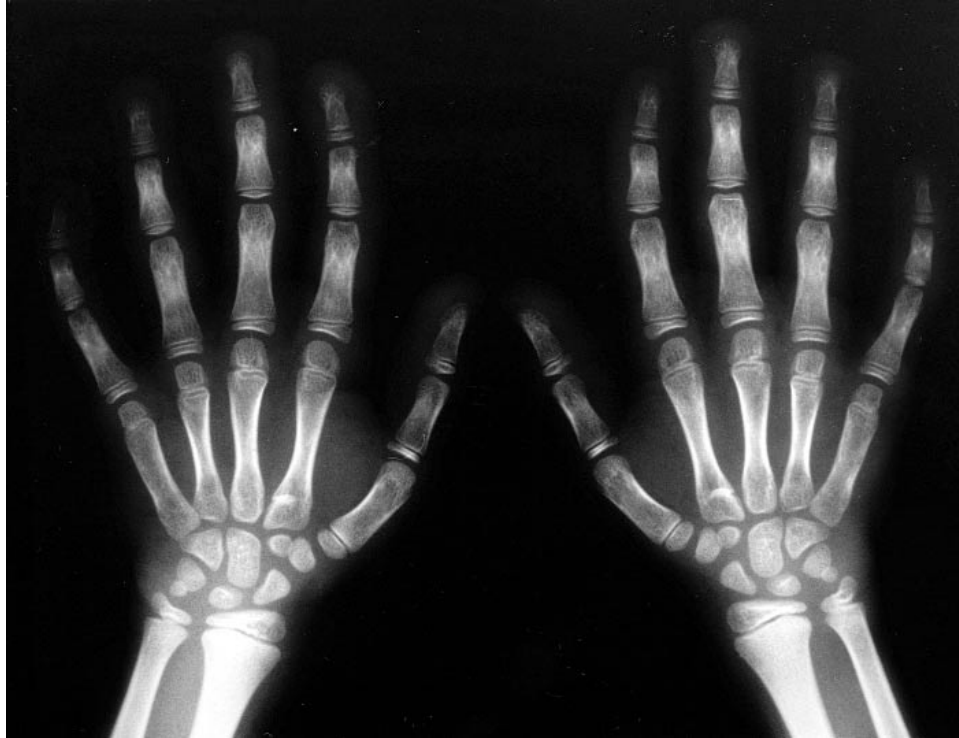

Figure 3. Patient's hand radiographs, age 10 years. Note the normal general aspect and normal bone age, with large interphalangeal articulations and deviation of the last phalanges of both 2nd fingers.

differential diagnosis, all the more because subcutaneous nodules and periorbital edema have been reported in SLE and LP, sometimes as the first clinical feature of the disease<sup>8,9</sup>. Nevertheless, these diseases were ruled out as neither the clinical description nor the pathological result in our patient was consistent with one of them.

This patient presented an inflammatory syndrome with a combination of anatomical features never reported before. It is hoped that this report will alert physicians to the existence of this combination and lead to additional reports confirming that it is a new entity.

#### ACKNOWLEDGMENT

We are thankful to Dr. A.M. Prieur for her clinical comments on this patient.

#### REFERENCES

1. Galon J, Aksentijevich I, McDermott MF, O'Shea JJ, Kastner DL. TNFRSF1A mutations and autoinflammatory syndromes. *Curr Opin Immunol* 2000;12:479-86.
2. Drenth JP, Haagsma CJ, van der Meer JW. Hyperimmunoglobulinemia D and periodic fever syndrome. The clinical spectrum in a series of 50 patients. International Hyper-IgD Study Group. *Medicine (Baltimore)* 1994;73:133-44.
3. Prieur AM. A recently recognised chronic inflammatory disease of early onset characterised by the triad of rash, central nervous system involvement and arthropathy. *Clin Exp Rheumatol* 2001;19:103-6.
4. Toro JR, Aksentijevich I, Hull K, Dean J, Kastner DL. Tumor necrosis factor receptor-associated periodic syndrome: a novel syndrome with cutaneous manifestations. *Arch Dermatol* 2000;136:1487-94.
5. Al-Mayouf SM, Majeed M, Hugosson C, Bahabri S. New form of idiopathic osteolysis: Nodulosis, arthropathy, and osteolysis (NAO) syndrome. *Am J Med Genet* 2000;93:5-10.
6. Inherited multicentric osteolysis with arthritis: A variant resembling Torg syndrome in a Saudi family. *Am J Med Genet* 2000;93:11-8.
7. Qualman SJ, Moser HW, Valle D, et al. Farber disease: pathologic diagnosis in sibs with phenotypic variability. *Am J Med Genet* 1987; Suppl 3:233-42.
8. Cyran S, Douglass MC, Silverstein JL. Chronic cutaneous lupus erythematosus presenting as periorbital edema and erythema. *J Am Acad Dermatol* 1992;26:334-8.
9. Franke W, Kuhn A, Megahed M, Krutmann J, Ruzicka T, Lehmann P. Periorbital edema as presenting symptom of lupus panniculitis: case report and literature review. *Hautarzt* 1999;50:889-92.