

# Vascular Endothelial Growth Factors C and D and Their VEGFR-2 and 3 Receptors in Blood and Lymphatic Vessels in Healthy and Arthritic Synovium

KARRI PAAVONEN, JAMI MANDELIN, TAINA PARTANEN, LOTTA JUSSILA, TIAN-FANG LI, ARI RISTIMÄKI, KARI ALITALO, and YRJÖ T. KONTTINEN

**ABSTRACT. Objective.** To localize vascular endothelial growth factor C (VEGF-C) and VEGF-D in synovial specimens in relation to their VEGFR-2 and VEGFR-3 receptors in blood and lymphatic vessels.

**Methods.** Immunohistochemical staining and messenger RNA analysis from control and arthritic synovial membrane specimens.

**Results.** Quantitative RT-PCR disclosed that VEGF-C mRNA copy numbers were higher than VEGF-D mRNA copy numbers in the rheumatoid arthritis (RA), osteoarthritis, and control patient groups studied ( $p < 0.01$ ). Immunohistochemical staining localized VEGF-C to synovial lining cell layer, pericytes, and smooth muscle cells of blood vessels. The number of VEGF-C positive cells was increased in the synovial lining of ankylosing spondylitis (AS) and RA compared to control synovium. However, in contrast to control synovial lining, little if any VEGF-D was detected in AS or RA synovial lining. VEGFR-2 expressing stromal blood vessels, also positive for the vascular endothelial marker PAL-E and the basement membrane marker laminin, were more abundant in RA and AS than in controls. Interestingly, the lymphatic endothelial receptor VEGFR-3 was also expressed in most synovial vessels, especially in the sublining capillaries and venules.

**Conclusion.** VEGF-C is strongly expressed in the hypertrophic synovial lining of arthritic joints, whereas VEGF-D expression is very low in AS and RA. The expression of VEGF-C and VEGF-D in pericytes and smooth muscle cells suggests that these factors may have a role in maintaining vascular homeostasis. The VEGF receptors VEGFR-2 and VEGFR-3 are present in most of the sublining blood vessels. The expression of the lymphatic marker VEGFR-3 in the sublining blood vessels may relate to fluid filtration and/or fenestrations. The relatively few lymphatic vessels along with increased vascular permeability in RA may contribute to the development of tissue edema and joint stiffness. (J Rheumatol 2002;29:39–45)

## Key Indexing Terms:

RHEUMATOID ARTHRITIS

PATHOLOGIC ANGIOGENESIS

LYMPHATIC ENDOTHELIUM

ENDOTHELIAL GROWTH FACTORS

INFLAMMATION

From the Molecular/Cancer Biology Laboratory and the Department of Anatomy, Biomedicum Helsinki; Department of Medicine/Invärtes Medicin and Department of Pathology, Helsinki University Hospital; ORTON Research Institute, the Orthopaedic Hospital of the Invalid Foundation, Helsinki, Finland.

Supported in part by the Finnish Academy, University of Helsinki, the Sigrid Juselius Foundation, Invalid Foundation, HYKS TYH0215 and HYKS TYH9301 evo grants, and the Finnish State Technology Development Centre. Dr. Paavonen was supported by the Finnish Medical Foundation and the Finnish Cancer Institute.

K. Paavonen, MD, Research Fellow, Molecular/Cancer Biology Laboratory; J. Mandelin, MSc, Research Fellow, Anatomy; T. Partanen, MD, PhD, Molecular/Cancer Biology Laboratory; L. Jussila, BMed, PhD Student, Molecular/Cancer Biology Laboratory; T-F. Li, MD, Visiting Scientist, Anatomy, Biomedicum Helsinki; A. Ristimäki, MD, Consultant, Department of Pathology, Helsinki University Central Hospital; K. Alitalo, MD, Professor, Molecular/Cancer Biology Laboratory, Biomedicum Helsinki; Y.T. Konttinen, MD, Professor, Department of Medicine/Invärtes Medicin, ORTON Research Institute, the Orthopaedic Hospital of the Invalid Foundation.

Address reprint requests to Dr. K. Paavonen, Molecular/Cancer Biology Laboratory, Biomedicum Helsinki, PO Box 63 (Haartmaninkatu 8), 00014 University of Helsinki, Finland. E-mail: Karri.Paavonen@Helsinki.Fi  
Submitted April 4, 2001; revision accepted July 23, 2001.

Angiogenesis, the formation of new blood vessels from preexisting ones, is essential in physiological processes such as inflammation and wound healing, embryonic development, tissue and organ regeneration, and during the female reproductive cycle<sup>1</sup>. Normally, a carefully maintained balance prevails between blood vessel growth stimulating factors such as vascular endothelial growth factor (VEGF) and basic fibroblast growth factor and blood vessel growth inhibitors such as endostatin and angiostatin<sup>2</sup>. This balance is disturbed in rheumatoid arthritis (RA) and other chronic arthritides, which have a strong angiogenic component<sup>1</sup>. Synovial membrane hyperplasia and synovial angiogenesis resemble the processes seen in neoplasia<sup>3-5</sup>. Furthermore, the activity of experimental arthritis can be inhibited with antiangiogenic therapy<sup>6,7</sup>.

VEGF is the prime angiogenic molecule in RA<sup>8</sup>. It binds to VEGF Receptor-1 (VEGFR-1/Flt-1) and VEGFR-2 (KDR/Flk-1). VEGF and its receptors VEGFR-1 and VEGFR-2 are expressed in the vascular endothelium in synovial membranes<sup>9,10</sup>. High VEGF concentrations have

been observed in RA synovial fluid<sup>11</sup> and they correlate with disease activity in juvenile RA<sup>12</sup>.

VEGF-C was discovered as the ligand for the “fms-like tyrosine kinase” receptor (Flt4), now called VEGFR-3<sup>13,14</sup>. VEGF-C mRNA is induced by the inflammatory cytokines tumor necrosis factor- $\alpha$  (TNF- $\alpha$ ) and interleukin 1 $\beta$  (IL-1 $\beta$ )<sup>15</sup> *in vitro*, but in contrast to VEGF mRNA not by hypoxia<sup>16</sup>. VEGF-C is also chemotactic for monocytes<sup>17</sup>. VEGF-C induces angiogenesis in the corneal assay and in the rabbit ischemic hindlimb model<sup>18,19</sup>. Adenoviral expression of VEGF-C induces receptor upregulation and lymphangiogenesis, i.e., the growth of lymphatic vessels in mouse skin<sup>20</sup>. VEGF-C protein also induces lymphangiogenesis in the chick chorioallantoic membrane assay<sup>21</sup>, and overexpression of VEGF-C under the basal keratinocyte-specific keratin-14 promoter in transgenic mice produces dilated and hyperplastic lymphatic vessels of the dermis<sup>22</sup>. VEGF-D is the closest relative to VEGF-C<sup>23</sup>. Its mouse homolog was originally cloned as the c-fos induced growth factor (FIGF)<sup>24</sup>. Like VEGF-C, VEGF-D also binds to VEGFR-2 and VEGFR-3<sup>25</sup>, is angiogenic<sup>26</sup> and induces a similar skin phenotype as VEGF-C when expressed under the K14-promoter in mouse skin<sup>27</sup>.

During embryogenesis, VEGFR-3 is expressed in vascular and lymphatic endothelium<sup>28</sup>. Knockout mouse embryos lacking VEGFR-3 die *in utero* from cardiovascular failure<sup>29</sup>. In adults, VEGFR-3 is largely restricted to the lymphatic endothelium<sup>28</sup> and few specialized endothelia, but it is upregulated in the endothelium of blood vessels of breast carcinomas<sup>30</sup> and of many other tumors<sup>31</sup>. In wound healing angiogenesis VEGFR-3 was found to be restricted to sprouting lymphatic vessels, which are transiently present in the granulation tissue<sup>32</sup>. VEGFR-2 is upregulated in angiogenic vessels in tumors and also during wound healing<sup>33</sup>.

Because of the association of VEGF-C and VEGF-D with angiogenesis, lymphangiogenesis, and lymphatic hyperplasia, we were interested in the analysis of these factors in rheumatoid synovium, where they could possibly act via VEGFR-2 and VEGFR-3 and contribute to the angiogenic and inflammatory phenotype of RA.

## MATERIALS AND METHODS

**Synovial membrane samples.** Synovial membrane samples were collected with the permission of the local ethics committee and with the patients' consent during joint replacement surgery or arthroscopic procedures. Sections were stained with hematoxylin and eosin and reviewed by an experienced histopathologist (YK). Patient records were reviewed to ensure that all the patients met the disease criteria<sup>34,35</sup>. RA medications are summarized in Table 1.

**Immunohistochemistry.** For cryosections, 8 cases of RA (4 hip, 1 metacarpophalangeal, 1 knee, and 2 elbow joints), 4 cases of ankylosing spondylitis (AS; 1 hip, 2 knee, 1 shoulder joint), and 12 controls from trauma knee joints were studied. The tissues were snap frozen in liquid nitrogen and embedded in OCT compound (Sakura, Torrance, CA, USA). Adjacent 5  $\mu$ m tissue sections were air-dried and fixed in cold acetone for 10 min. The

Table 1. Medications used by the patients with RA. Patients with OA or AS used NSAID/acetaminophen as needed.

Patients	Primary Diagnosis	Medication
IHC		
1	Seropos RA	SASP, MTX, PRED, SAND, NSAID
2	Seropos RA	SASP, MTX, PRED, SAND, NSAID
3	Seropos RA	PRED, SAND, OXI, MYO, NSAID
4	Seroneg RA	MTX, SAND, OXI, NSAID
5	Seropos RA	MTX, PRED, NSAID
6	Seropos RA	SASP, PRED, NSAID
7	Seropos RA	MTX, NSAID
8	Seroneg RA	MTX, NSAID
RT-PCR		
1	Seropos RA	SAND, PRED, NSAID
2	Seropos RA	PRED, NSAID
3	Seropos RA	SAND, PRED, NSAID
4	Seropos RA	MTX, PRED, SAND, NSAID
5	Seropos RA	SASP, OXI, PRED, NSAID

IHC: immunohistochemistry, SASP: sulfasalazopyrin, MTX: methotrexate, PRED: prednisolone, SAND: cyclosporine, OXI: hydroxychloroquine, MYO: sodium aurothiomalate, NSAID: nonsteroidal antiinflammatory drug.

sections were incubated with the appropriate blocking serum (5% normal horse or goat serum) and with the appropriate primary antibody overnight at 4°C. Antibodies against VEGF and their receptors are shown in Table 2. Other antibodies used included monoclonal anti-CD31 Ab (1:300; Dako Immunoglobulins, Glostrup, Denmark), monoclonal PAL-E Ab<sup>36</sup> (1:400; Monosan, Uden, the Netherlands), monoclonal anti-laminin Ab (1:2000, clone LAM-89; Sigma, St. Louis, MO, USA), monoclonal anti-smooth muscle  $\alpha$ -actin Ab (1:10,000, clone 1A4; Sigma), monoclonal anti-interferon- $\gamma$  Ab (1:200; PharMingen, San Diego, CA, USA), polyclonal rabbit antiserum to IL-1 $\beta$  (1:500; Genzyme, Cambridge, MA, USA), polyclonal rabbit antiserum to IL-6 (1:1000; Genzyme), and a polyclonal rabbit antiserum to TNF- $\alpha$  (1:500; Monosan). A 30 min incubation with the appropriate secondary antibody (biotinylated anti-mouse or anti-rabbit antibodies) was followed by 60 min incubation with Vectastain Elite avidin-biotin complex (ABC)/HRP kit (Vector Laboratories, Burlingame, CA, USA) and by development of peroxidase activity with 3-amino-9-ethyl carbazole (Sigma) or 3,3'-diaminobenzidine tetrahydrochloride (Sigma). The slides were briefly counterstained with hematoxylin and mounted in Aquamount (BDH Laboratories, Dorset, England). Negative staining controls omitted the primary Ab or used irrelevant primary Ab of the same isotype (mouse IgG1 or rabbit IgG). Specificity controls of VEGF-C Ab were done using an antigen preabsorption test with a 40-fold molar excess of the purified immunogen. Immunoreactivity and specificity of the anti-VEGF-D antibodies was verified by immunofluorescence in 293EBNA cells transiently transfected with VEGF-D (data not shown).

**Quantitative reverse transcription-polymerase chain reaction (RT-PCR).** For RT-PCR analysis, 5 RA samples (from 2 hip and 3 knee joints), 5 OA samples (from hip joints), and 6 control samples (from trauma knee joints) were studied. Total RNA was isolated using TRIzol reagent (Life Technologies, Rockville, MD, USA). Messenger RNA (mRNA) was isolated from total RNA using magnetic (dT)<sub>25</sub>-polystyrene beads (Dyna, Oslo, Norway) and collected with a PickPen™ magnetic collector (BioNobile, Turku, Finland). Forty nanograms of mRNA were used to prepare primary cDNA using (dT)<sub>12-18</sub> primers and SuperScript enzyme, followed by RNase H treatment (Life Technologies). Primers used were 5'-CGGGAGGTGTGTATAGATGTGGGG-3' and 5'-CTGGTTTGGGGC-CTTGAGAGA-3' for VEGF-C (product size 196 bp), 5'-GCAGG-GCTCCAGTAATGAA-3' and 5'-ACTGAGTTCCTTGCCATTCTT-3' for

Table 2. Antibodies against VEGF and their receptors. Clone numbers indicated for the antibodies used.

Antibody Against	Immunizing Antigen	Stained Cells	Source
VEGF-C			
pAb 882	AA 2–10 of mature VEGF-C	Unknown	Joukov, <i>et al</i> , 1996
VEGF-D			
pAb 749-1AP	VHD of mature VEGF-D	Unknown	R&D Systems, Minneapolis, MN
78912.11 (IgG1)	VHD of mature VEGF-D	Unknown	R&D Systems
VEGFR-2			
KDR-1 (IgG1)	ECD of VEGFR-2	VE	Simon, <i>et al</i> , 1996
VEGFR-3			
9D9F9 (IgG1)	ECD of VEGFR-3	LE (VE)	Valtola, <i>et al</i> , 1997

pAb: polyclonal antibodies (all other are monoclonal), AA: amino acid residues, VHD: VEGF homology domain, ECD: extracellular domain, LE: lymphatic endothelium, SMC: smooth muscle cells, VE: vascular endothelium.

VEGF-D (product size 226 bp), and 5'-TCACCCACACTGTGCCCATC-TACGA-3' and 5'-CAGCGGAACCGCTCATTGCCAATGG-3' for the  $\beta$ -actin gene (product size 295 bp). Quantitative PCR was run in duplicate on 4 ng of first-strand cDNA using 0.5 mM primers in a LightCycler- FastStart DNA Master SYBR Green I reagent mix by LightCycler PCR machine (Roche Molecular Biochemicals, Mannheim, Germany). The identity of the product was verified from 50 ng of isolated amplicon (QIAquick, Qiagen Inc., Chatsworth, CA, USA) using an automated Applied Biosystems 373A sequencer. Serial dilutions of plasmid DNA for VEGF-C, VEGF-D, and  $\beta$ -actin were used to determine the copy number of the amplicons. The amount of VEGF-C and VEGF-D mRNA was measured against 10,000  $\beta$ -actin mRNA copies.

**Statistical analysis.** Numerical values are given as mean  $\pm$  standard error of the mean. The comparison of VEGF-C and VEGF-D mRNA expression inside the groups was analyzed with the Mann-Whitney test and the differences for the expression of the genes between the groups were analyzed with the Kruskal-Wallis test.

## RESULTS

**Quantitative RT-PCR of VEGF-C and -D mRNA.** Quantitative RT-PCR disclosed that the mean expression level of VEGF-C was higher than that of VEGF-D (Figure 1). In control trauma samples (TrA) there were  $44 \pm 18$  VEGF-C

mRNA copies vs  $4 \pm 2$  VEGF-D mRNA copies per 10,000  $\beta$ -actin mRNA copies ( $p < 0.01$ ). The corresponding expression levels in OA were  $129 \pm 50$  vs  $3 \pm 1$  copies ( $p < 0.01$ ) and in RA  $56 \pm 11$  VEGF-C mRNA copies vs  $3 \pm 2$  VEGF-D mRNA copies ( $p < 0.01$ ).

*VEGF-C is increased and VEGF-D is decreased in the rheumatoid synovial lining.* Immunostaining disclosed VEGF-C in control synovial lining and fibroblast-like stromal cells (Figure 2A). Also, VEGF-D was seen in control synovial lining (Figure 2A, insert). VEGF-C staining was specific, as it was blocked with a 40-fold molar excess of the immunogen (Figure 2B). Although VEGF-C staining was present in the thin, single-cell synovial lining of control samples, it was stronger and present in many more cells in the thickened lining cell layer in RA (Figures 2C, 2D) and AS (data not shown). In contrast, and unlike in the healthy controls, there was only weak or no VEGF-D staining in the RA (Figures 2C, 2D) or AS samples (data not shown).

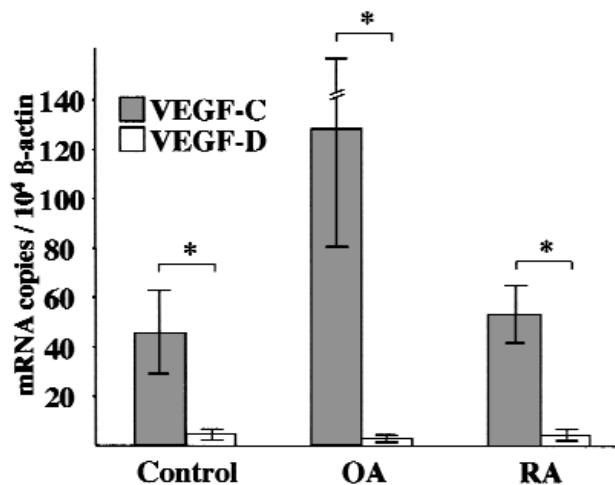


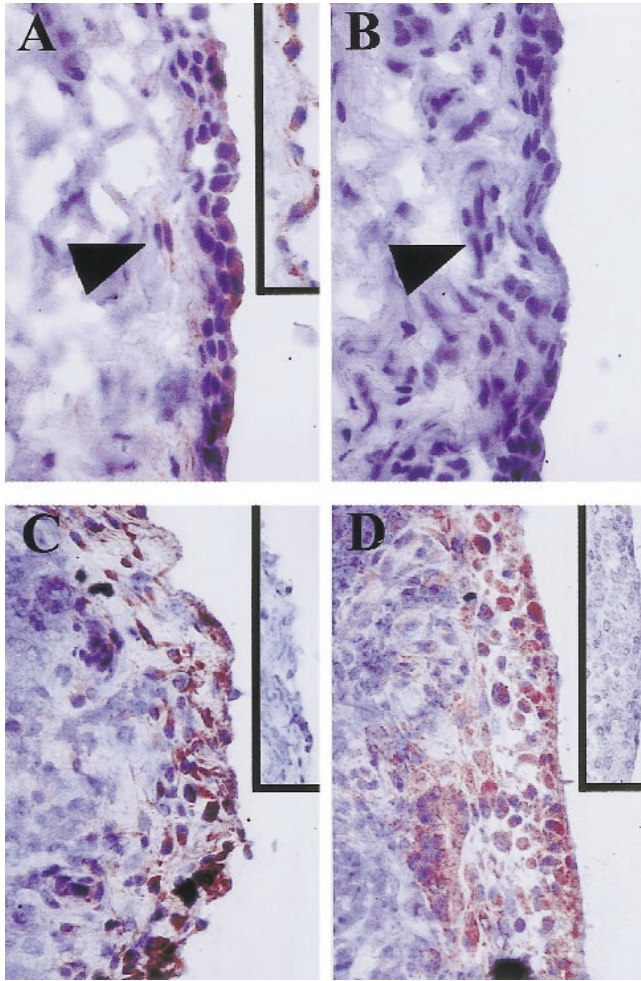
Figure 1. Mean relative VEGF-C and VEGF-D mRNA copy numbers  $\pm$  standard error of mean in the control, OA, and RA study groups normalized to 10,000  $\beta$ -actin mRNA copy numbers. \* $p < 0.01$ .

Table 3. Staining of different structures in control and RA/AS synovial membranes. Staining intensity was graded by blinded histopathological assessment of the entire synovial sample area.

	VEGF-C	VEGF-D	VEGFR-2	VEGFR-3
Lymphatic EC	-	-	-	+++
Vascular EC				
Lining capillaries	-	-	++	++
Stromal veins	-	-	++	+
Stromal arteries	-	-	++	-
Pericytes/SMC	++	++	-	-
Stromal fibroblasts/ macrophages	+	+	-	-
Synovial lining cell layer				
Control (n = 12)	+	++	-	-
RA/AS (n = 7/4)	+++	+	-	-

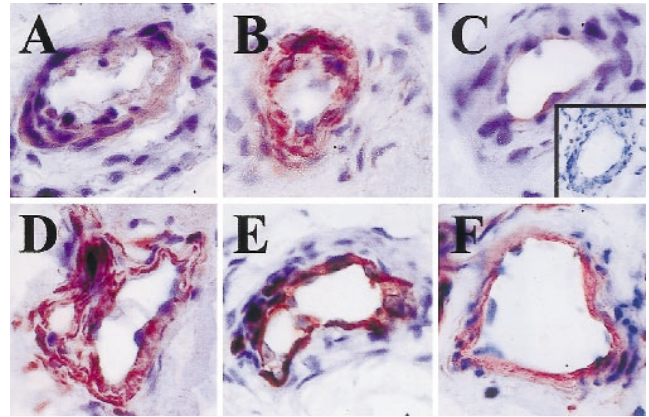
EC: endothelial cells; RA: rheumatoid arthritis; SMC: smooth muscle cells; AS: ankylosing spondylitis; -: no staining; +: weak staining and/or few positive cells; ++: moderate staining and/or moderate numbers of positive cells; +++: strong staining and/or numerous positive cells.





**Figure 2.** Immunoperoxidase staining of VEGF-C and VEGF-D in serial sections of synovial tissue. Control samples stained for VEGF-C (A) and VEGF-D (A insert). Immunoreactivity blocked with a 40-fold molar excess of the immunogenic VEGF-C peptide (B). Arrowhead indicates sublining capillary pericytes (A, B). Synovial membranes from patients with RA stained strongly for VEGF-C (C, D), but only slightly or not at all for VEGF-D (C and D inserts). Original magnification  $\times 700$ .

**VEGF-C/D and their vascular and lymphatic receptors in synovial membrane.** VEGF-C and VEGF-D were localized to blood vessel pericytes and smooth muscle cells in all samples (Figures 3A, 3B and Table 3). VEGFR-2 was detected in the endothelial cells of the same vessels (Figure 3C), suggesting that the ligands have a paracrine mode of action. The distinction between pericytes, smooth muscle cells, and endothelial cells was based on staining using antibodies against smooth muscle actin (SMA; Figure 3D), PAL-E (Figure 3E), and laminin (Figure 3F). VEGF-C and VEGF-D were also weakly expressed in stromal fibroblasts and macrophages in inflamed synovial tissue (data not shown). VEGF-C staining was often found adjacent to its receptor VEGFR-3 in subsynovial capillaries and venules,



**Figure 3.** Serial sections of RA stromal blood vessel stained for VEGF-C (A), VEGF-D (B), VEGFR-2 (C), and VEGFR-3 (C, insert). Blood vessel structures were identified with antibodies to smooth muscle actin (D), PAL-E (E), and laminin (F). Original magnification  $\times 1500$ .

but such a colocalization was much less common in the stromal vessels (Figure 3C).

**VEGF-C and inflammatory cytokines in RA synovium.** VEGF-C (Figure 4A) also partially colocalized with the inflammatory cytokines IL-1 $\beta$  (Figure 4C), IL-6 (Figure 4D), and TNF- $\alpha$  (Figure 4F) in RA synovial lining cell layer. Little VEGF-D (Figure 4B) or IFN- $\gamma$  (Figure 4E) staining was present in the rheumatoid synovial lining.

**Expression of VEGFR-3 in synovial blood vessels.** The lymphatic endothelial receptor VEGFR-3 was detected in most of the blood vessels in control and AS and RA samples, primarily in the sublining capillaries and venules. In particular, in the sublining capillaries responsible for fluid filtration VEGFR-3 (Figure 5A) was expressed in the PAL-E positive blood vascular endothelial cells (Figure 5C). Only a few vessels were VEGFR-3 positive (Figure 5B) and PAL-E negative (Figure 5D), suggesting that they were true synovial lymphatic vessels. VEGFR-3 staining of the lymphatic vessels was more intense than that of the blood vessels. Although it was difficult to count the number of lymphatic vessels due to VEGFR-3 on sublining blood vessel capillary endothelium, the ratio of lymphatic vessels to blood vessels was clearly lower in RA samples than in controls, mainly as a result of increased vascularity.

## DISCUSSION

We report the expression of VEGF-C and VEGF-D in the human synovium. VEGF-D was observed in the lining cell layer of normal synovium, but it was absent or seen only in a few cells in AS/RA synovial lining, indicating that it is downregulated in arthritis<sup>37</sup>. In contrast, VEGF-C staining was clearly more abundant in RA and AS than in controls. This was in contrast to the RT-PCR results, which indicated that there were no statistically significant differences between the numbers of VEGF-C and VEGF-D mRNA between the 3 patient groups (RA, OA, control), perhaps

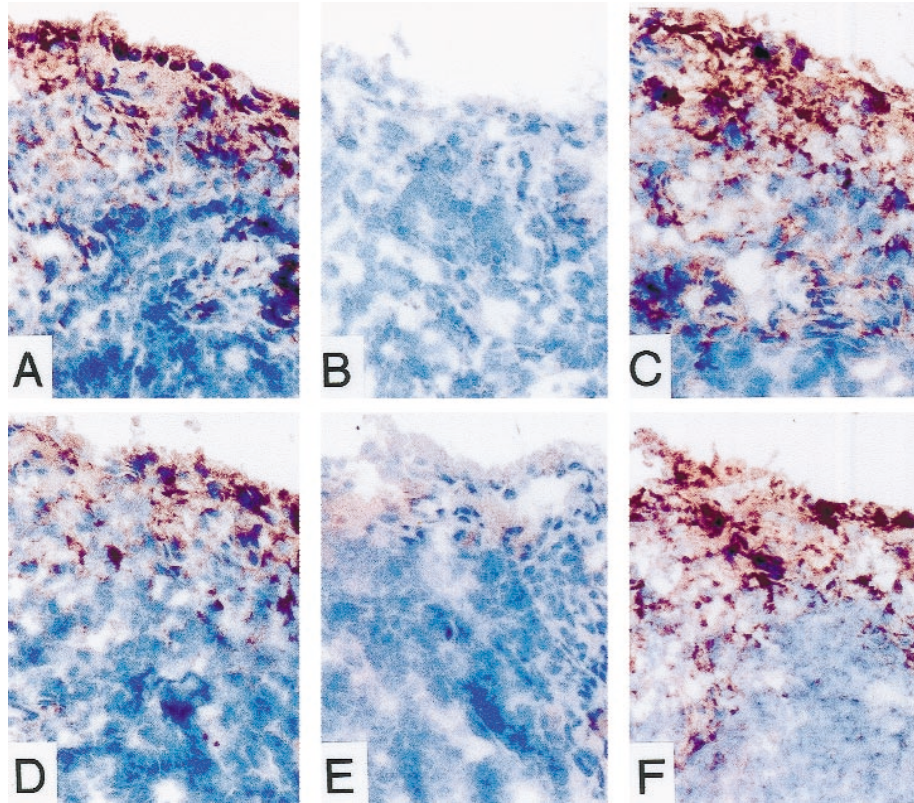


Figure 4. Serial sections stained for VEGF-C (A), VEGF-D (B), IL-1 $\beta$  (C), IL-6 (D), IFN- $\gamma$  (E), and TNF- $\alpha$  (F). Original magnification  $\times 500$ .

indicating posttranscriptional regulation. We also found partial colocalization by immunohistochemistry of VEGF-C with the inflammatory cytokines IL-1 $\beta$ , IL-6, and TNF- $\alpha$ . In RA, VEGF-C may be induced by numerous cytokines and growth factors, such as IL-1 $\beta$  and TNF- $\alpha$ , which have been shown to regulate VEGF-C expression<sup>15</sup>. Further, subsynovial blood vessel endothelium contained VEGFR-2 and VEGFR-3, suggesting that both VEGF-C/VEGFR-2 and VEGF-C/VEGFR-3 interactions may play a role in pathological RA associated angiogenesis. The resulting increased vascularity may contribute to inflammation, pannus forma-

tion, bone and cartilage destruction, and disease progression in RA. Interestingly, most disease modifying antirheumatic drugs have antiangiogenic effects<sup>38</sup> and some of them, such as corticosteroids, may block the induction of VEGF-C by the inflammatory cytokines<sup>15</sup>.

VEGFR-3 has been considered to be a relatively specific marker for lymphatic vessels in adult tissues. We therefore planned to use VEGFR-3 immunostaining to assess the lymphatic vessels in normal and arthritic synovial membrane. Surprisingly, most of the sublining capillaries and venules in both normal and arthritic synovial membrane

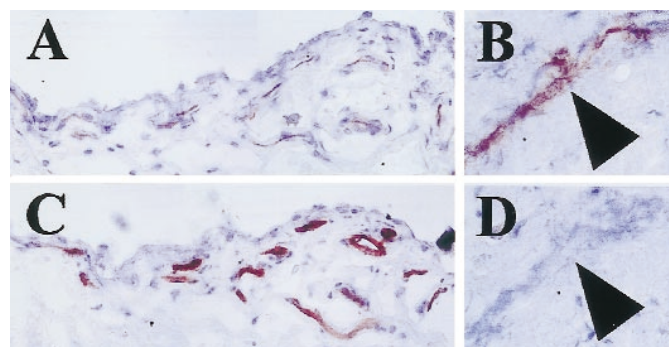


Figure 5. Staining of blood and lymphatic vessels in serial sections of control synovial tissue. Sublining blood vessels stained for VEGFR-3 (A) and the vascular endothelial marker PAL-E (C). A stromal lymphatic vessel positive for VEGFR-3 (B), but negative for PAL-E (D) (arrowheads). Original magnification: A and C  $\times 400$ ; B and D  $\times 2000$ .



were found to be VEGFR-3 positive. The nature of these vessels was ascertained by the use of several blood vessel markers applied to consecutive tissue sections. It was found that in addition to only a few VEGFR-3 positive, but PAL-E and laminin negative lymphatic vessels, most of the VEGFR-3 expressing vessels were also positive for VEGFR-2, PAL-E, and laminin and were thus blood vessels. The functional significance of the ectopic VEGFR-3 expression in synovial blood vessel endothelium is not known. However, synovial membrane contains fenestrated blood vessels, which are involved in the nutrition of the avascular hyaline articular cartilage. Thus, VEGFR-3 may be involved in the maintenance of fenestrations and in the formation of the synovial fluid. The number of VEGFR-3 positive lymphatic vessels was low in relation to blood vessels in RA and AS synovial membrane samples compared to control samples. Wilkinson, *et al* has described the presence of lymphatic vessels in the synovium and a lack of lymphatics in RA synovium<sup>39</sup>. The increased blood vessel permeability in inflamed joints could lead to increased accumulation of interstitial tissue fluid and the relative lack of lymphatic vessels could contribute to this end. Together with the increased local synthesis of hyaluronan, this could contribute to the typical morning stiffness of patients with RA.

We speculate that the overexpression of VEGF-C and lack of VEGF-D in RA, probably induced by inflammatory cytokines, contribute to increased local angiogenesis via the angiogenic VEGF-C/VEGFR-2 and VEGF-C/VEGFR-3 signalling pathways.

#### ACKNOWLEDGMENT

We thank Dr. Herbert Weich for the anti-VEGFR-2 antibodies, Dr. Juulia Paavonen for help with the statistical analysis, Dr. Berndt Enholm for help with the experiments, and Tapio Tainola, Ville Waris and Pipsa Ylikantola for excellent technical assistance.

#### REFERENCES

- Folkman J. Angiogenesis in cancer, vascular, rheumatoid and other disease. *Nat Med* 1995;1:27-31.
- Folkman J, D'Amore PA. Blood vessel formation: What is its molecular basis? *Cell* 1996;87:1153-5.
- Kontinen YT, Nykanen P, Nordstrom D, et al. DNA synthesis in prolyl 4-hydroxylase positive fibroblasts in situ in synovial tissue. An autoradiography-immunoperoxidase double labeling study. *J Rheumatol* 1989;16:339-45.
- Ceponis A, Kontinen YT, Mackevicius Z, et al. Aberrant vascularity and von Willebrand factor distribution in inflamed synovial membrane. *J Rheumatol* 1996;23:1880-6.
- Firestein GS. Invasive fibroblast-like synoviocytes in rheumatoid arthritis. Passive responders or transformed aggressors? *Arthritis Rheum* 1996;39:1781-90.
- de Bandt M, Grossin M, Weber AJ, et al. Suppression of arthritis and protection from bone destruction by treatment with TNP-470/AGM-1470 in a transgenic mouse model of rheumatoid arthritis. *Arthritis Rheum* 2000;43:2056-63.
- Sone H, Kawakami Y, Sakauchi M, et al. Neutralization of vascular endothelial growth factor prevents collagen-induced arthritis and ameliorates established disease in mice. *Biochem Biophys Res Commun* 2001;23:562-8.
- Paleolog EM, Jadwiga MM. Angiogenesis in arthritis: Role in disease pathogenesis and as a potential therapeutic target. *Angiogenesis* 1998;2:295-307.
- Fava RA, Olsen NJ, Spencer-Green G, et al. Vascular permeability factor/endothelial growth factor (VPF/VEGF): Accumulation and expression in human synovial fluids and rheumatoid synovial tissue. *J Exp Med* 1994;180:341-6.
- Ikeda M, Hosoda Y, Hirose S, Okada Y, Ikeda E. Expression of vascular endothelial growth factor isoforms and their receptors Flt-1, KDR, and neuropilin-1 in synovial tissues of rheumatoid arthritis. *J Pathol* 2000;191:426-33.
- Koch AE, Harlow LA, Haines GK, et al. Vascular endothelial growth factor. A cytokine modulating endothelial function in rheumatoid arthritis. *J Immunol* 1994;152:4149-56.
- Maeno N, Takei S, Imanaka H, et al. Increased circulating vascular endothelial growth factor is correlated with disease activity in polyarticular juvenile rheumatoid arthritis. *J Rheumatol* 1999;26:2244-8.
- Joukov V, Pajusola K, Kaipainen A, et al. A novel vascular endothelial growth factor, VEGF-C, is a ligand for the Flt4 (VEGFR-3) and Kdr (VEGFR-2) receptor tyrosine kinases. *EMBO J* 1996;15:290-8.
- Finnerty H, Kelleher K, Morris GE, et al. Molecular cloning of murine FLT and FLT4. *Oncogene* 1993;8:2293-8.
- Ristimaki A, Narko K, Enholm B, Joukov V, Alitalo K. Proinflammatory cytokines regulate expression of the lymphatic endothelial mitogen vascular endothelial growth factor-C. *J Biol Chem* 1998;273:8413-8.
- Enholm B, Paavonen K, Ristimaki A, et al. Comparison of VEGF, VEGF-B, VEGF-C and Ang-1 mRNA regulation by serum, growth factors, oncoproteins and hypoxia. *Oncogene* 1997;14:2475-83.
- Skobe M, Hamberg LM, Hawighorst T, et al. Concurrent induction of lymphangiogenesis, angiogenesis and macrophage recruitment by VEGF-C in melanoma. *Am J Pathol* 2001;159:893-903.
- Cao Y, Linden P, Farnebo J, et al. Vascular endothelial growth factor C induces angiogenesis in vivo. *Proc Natl Acad Sci USA* 1998;95:14389-94.
- Witzenbichler B, Asahara T, Murohara T, et al. Vascular endothelial growth factor-C (VEGF-C/VEGF-2) promotes angiogenesis in the setting of tissue ischemia. *Am J Pathol* 1998;153:381-94.
- Enholm B, Karpanen T, Jeltsch M, et al. Adenoviral expression of VEGF-C induces lymphangiogenesis in the skin. *Circulation Res* 2001;88:623-9.
- Oh SJ, Jeltsch MM, Birkenhager R, et al. VEGF and VEGF-C: specific induction of angiogenesis and lymphangiogenesis in the differentiated avian chorioallantoic membrane. *Dev Biol* 1997;188:96-109.
- Jeltsch M, Kaipainen A, Joukov V, et al. Hyperplasia of lymphatic vessels in VEGF-C transgenic mice. *Science* 1997;276:1423-5.
- Yamada Y, Nezu J, Shimane M, Hirata Y. Molecular cloning of a novel vascular endothelial growth factor, VEGF-D. *Genomics* 1997;42:483-8.
- Orlandini M, Marconcini L, Ferruzzi R, Oliviero S. Identification of a c-fos-induced gene that is related to the platelet-derived growth factor/vascular endothelial growth factor family. *Proc Natl Acad Sci USA* 1996;93:11675-80.
- Achen MG, Jeltsch M, Kukk E, et al. Vascular endothelial growth factor D (VEGF-D) is a ligand for the tyrosine kinases VEGF receptor 2 (Flk1) and VEGF receptor 3 (Flt4). *Proc Natl Acad Sci USA* 1998;95:548-53.
- Marconcini L, Marchio S, Morbidelli L, et al. C-fos-induced growth factor/vascular endothelial growth factor D induces angiogenesis in vivo and in vitro. *Proc Natl Acad Sci USA*

- 1999;96:9671-6.
27. Veikkola T, Jussila L, Makinen T, et al. Signaling via vascular endothelial growth factor receptor-3 is sufficient for lymphangiogenesis in transgenic mice. *EMBO J* 2001;20:1223-31.
  28. Kaipainen A, Korhonen J, Mustonen T, et al. Expression of the fms-like tyrosine kinase FLT4 gene becomes restricted to endothelium of lymphatic vessels during development. *Proc Natl Acad Sci USA* 1995;92:3566-70.
  29. Dumont DJ, Jussila L, Taipale J, et al. Cardiovascular failure in mouse embryos deficient in VEGF receptor-3. *Science* 1998;282:946-9.
  30. Valtola R, Salven P, Heikkila P, et al. VEGFR-3 and its ligand VEGF-C are associated with angiogenesis in breast cancer. *Am J Pathol* 1999;154:1381-90.
  31. Partanen TA, Alitalo K, Miettinen M. Lack of lymphatic vascular specificity of vascular endothelial growth factor receptor 3 in 185 vascular tumors. *Cancer* 1999;86:2406-12.
  32. Paavonen K, Puolakkainen P, Jussila L, Jahkola T, Alitalo K. Vascular endothelial growth factor receptor-3 in lymphangiogenesis in wound healing. *Am J Pathol* 2000;156:1499-504.
  33. Peters KG, De Vries C, Williams LT. Vascular endothelial growth factor receptor expression during embryogenesis and tissue repair suggests a role in endothelial differentiation and blood vessel growth. *Proc Natl Acad Sci USA* 1993;90:8915-9.
  34. Arnett FC, Edworthy SM, Bloch DA, et al. The American Rheumatism Association 1987 revised criteria for the classification of rheumatoid arthritis. *Arthritis Rheum* 1988;31:315-24.
  35. Dougados M, van der Linden S, Juhlin R, et al. The European Spondylarthropathy Study Group preliminary criteria for the classification of spondylarthropathy. *Arthritis Rheum* 1991;34:1218-27.
  36. Schlingemann RO, Dingjan GM, Emeis JJ, Blok J, Warnaar SO, Ruiter DJ. Monoclonal antibody PAL-E specific for endothelium. *Lab Invest* 1985;52:71-6.
  37. Niki T, Iba S, Tokunou M, Yamada T, Matsuno Y, Hirohashi S. Expression of vascular endothelial growth factors A, B, C, and D and their relationships to lymph node status in lung adenocarcinoma. *Clin Cancer Res* 2000;6:2431-9.
  38. Walsh DA. Angiogenesis and arthritis. *Rheumatology* 1999; 38:103-12.
  39. Wilkinson LS, Edwards JCW. Demonstration of lymphatics in human synovial tissue. *Rheumatol Int* 1991;11:151-5.