

Large Artery Vasculitis Following Recombinant Hepatitis B Vaccination: 2 Cases

AIMEE ZAAS, PAUL SCHEEL, ANTHONY VENBRUX, and DAVID B. HELLMANN

ABSTRACT. We describe 2 women who developed large artery vasculitis shortly after receiving recombinant hepatitis B vaccination. One patient developed Takayasu's arteritis, the other a vasculitis involving subclavian and renal arteries. Both developed renal failure. Whether the vasculitis was caused by the vaccination is not known. Although small vessel vasculitis following hepatitis B vaccination has been reported a number of times, large vessel vasculitis associated with hepatitis B vaccination has been reported only once. These cases suggest that large artery vasculitis should be added to the list of possible side effects of hepatitis B vaccination. (J Rheumatol 2001;28:1116–20)

Key Indexing Terms:

VASCULITIS TAKAYASU ARTERITIS HEPATITIS B VACCINATION

Adverse events following vaccination for hepatitis B virus with recombinant yeast derived hepatitis B vaccines have been estimated to occur only once out of every 55,000 to 294,000 doses administered¹. However, several rheumatic diseases, including rheumatoid arthritis²⁻⁵ (RA), systemic lupus erythematosus^{6,7} (SLE), and vasculitis⁸⁻¹⁵, have been reported to follow vaccination for hepatitis B. Among the cases of vasculitis associated with hepatitis B vaccination, all but one patient had vasculitis involving small or medium size vessels⁸⁻¹⁵. The single report of large artery disease was of a woman who developed Takayasu's arteritis following inoculation with a plasma derived vaccine¹⁶. To our knowledge, large artery vasculitis following use of the recombinant hepatitis B vaccination has never before been reported. We describe 2 patients who developed large artery vasculitis, including one patient with Takayasu's arteritis, following recombinant hepatitis B vaccination.

CASE REPORTS

Case 1. A 19-year-old woman received the recombinant hepatitis B vaccine (Engerix B; SmithKline Beecham) in March, April, and September 1995. She had been well except for mild low back pain since 1991 attributed to bilateral sacroiliitis from ankylosing spondylitis (AS) and treated with nonsteroidal antiinflammatory drugs. An uncle had AS and both parents were carriers of hepatitis B. In the summer of 1995, she gradually devel-

oped fatigue and malaise, and was found to have a newly elevated erythrocyte sedimentation rate (ESR) (Westergren) of 49 mm/h in the absence of back pain or other symptoms of active AS. In October 1995 she developed severe headaches and was found to have blood pressure of 220/130 mm Hg. She had never before had hypertension and her blood pressure in August 1995 had been 116/70 mm Hg. After starting enalapril she developed acute renal failure, prompting admission to hospital. Her examination was remarkable for hypertension, a left side abdominal bruit, and normal pulses in her extremities. The ESR (Westergren) was 55 mm/h, the hematocrit value 35.0, and the serum creatinine was 6.8 mg/dl. Urinalysis revealed 3+ proteinuria and 1–2 red blood cells per high power field. Twenty-four hour urine for quantification of proteinuria was not obtained. Russell viper venom time was within normal limits (26.9 s) and anticardiolipin IgG, IgM, and IgA were negative. The antinuclear antibody (ANA), C3, C4, plasma renin, perinuclear antineutrophil cytoplasmic antibody (p-ANCA), cytoplasmic-ANCA (c-ANCA), hepatitis B surface antigen (HBsAg), and hepatitis C antibody (anti-HCV) were normal or negative. Rheumatoid factor and HLA-B27 serology were not obtained. Hepatitis B surface antibody (HBsAb) was positive, but no titer was obtained. Enalapril was discontinued upon hospital admission. Angiography (Figure 1) showed bilateral high grade renal artery stenosis and a large inferior mesenteric artery collateral. Additional angiography (not shown) revealed superior mesenteric and celiac artery stenoses with abdominal aortic thickening. Her renal recovery following emergent aortorenal saphenous vein grafts and pulse methylprednisolone has been reported¹⁷. In October 1997, 90% stenosis of the right renal artery vein graft was treated successfully with angioplasty. At that time a slight stenosis of the mid portion of the right subclavian artery was noted. She has remained stable taking oral prednisone and weekly oral methotrexate. A magnetic resonance image (MRI) in August 1999 showed no further narrowing of the involved arteries. Her HBsAb was undetectable in August 1999. In December 1999 her serum creatinine was 0.8 mg/dl.

Case 2. A 61-year-old normotensive woman with a history of a polymyalgia rheumatica-like illness in 1990 received the first dose of a recombinant hepatitis B vaccine (Engerix B, SmithKline Beecham) in September 1997 in anticipation of travel to India. At that time her blood pressure was 110/70 mm Hg. Hepatitis serologies were negative, including HBsAg, HBsAb, and anti-HCV. The night following the first vaccination, she experienced fatigue, myalgias, and eye pain, which resolved over days. After the second dose of Engerix in October 1997, she rapidly developed fatigue as well as low grade fevers, anorexia, and headache. Over the next

From the Departments of Medicine and Radiology, Johns Hopkins Hospital, and the Johns Hopkins University School of Medicine, Baltimore, Maryland, USA.

A. Zaas, MD, Resident, Osler Medical House Staff; P. Scheel, MD, Associate Professor of Medicine; A. Venbrux, MD, Associate Professor of Radiology, Department of Radiology; D.B. Hellmann, MD, Mary Betty Stevens Professor of Medicine.

Address reprint requests to Dr. D.B. Hellmann, Department of Medicine, A-1-W, Room 110, 4940 Eastern Avenue, Baltimore, MD 21224. E-mail: hellmann@jhmi.edu

Submitted July 12, 2000 revision accepted November 22, 2000.

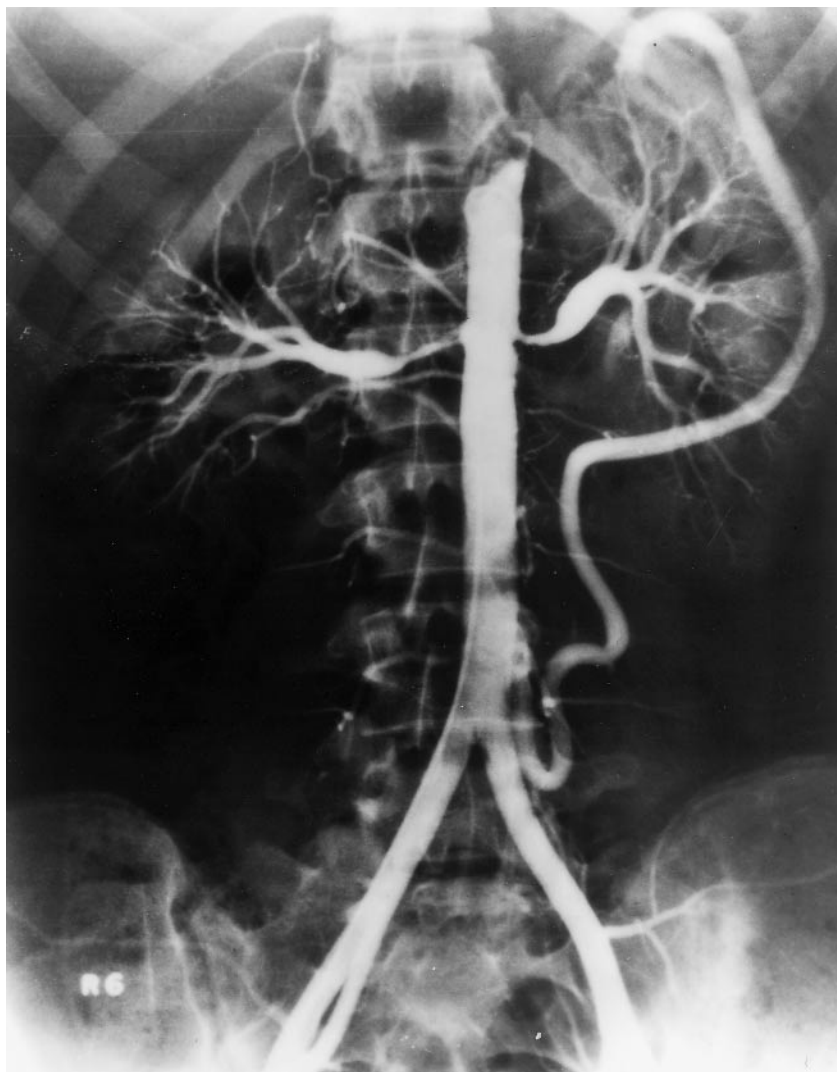


Figure 1. Digital subtraction abdominal angiography of Patient 1 revealing bilateral high grade renal artery stenoses, as well as a large inferior mesenteric collateral vessel on the left.

month, she experienced a 30 lb weight loss and by November 1997, she had developed hypertension (blood pressure 230/140 mm Hg). A retinal hemorrhage was noted. A rise in her serum creatinine to 2.8 mg/dl prompted referral to our hospital. Her history was remarkable for having experienced in 1990, at the age of 54, myalgias of her shoulders and hips associated with an ESR of 100 mm/h that completely resolved with a 2 mo course of oral prednisone. At that time, she had not experienced headache, jaw claudication, or visual symptoms and her blood pressure and serum creatinine were normal. Followup revealed normal blood pressures and serum creatinine of 1.0 mg/dl. She had normal serum cholesterol and no family history of early cardiovascular disease.

Examination in February 1998 showed blood pressure 140/104 mm Hg in the right arm and 180/104 mm Hg in the left arm. Bruits were noted over both axillary arteries, the left supraclavicular area, the left femoral artery, and the abdomen. The right brachial and radial pulses were diminished. The serum creatinine was 2.8 mg/dl and ESR 18 mm/h. Urinalysis revealed no red blood cells per high power field and 24 h urine collection had 870 mg of protein. The following tests were negative or normal: ANA, antistreptolysin O, c-ANCA, p-ANCA, C3, C4, serum protein electrophoresis, plasma renin and morning cortisol level, and 24 h urine for epinephrine,

dopamine, metanephrines, normetanephrines, and vanilylmandelic acid (VMA). HBsAb was positive, but a titer was not performed. Angiography (Figure 2) showed long bilateral subclavian stenoses with the right extending to the axillary artery. Carotid arteries were normal. Upper extremity arterial Doppler evaluation in February 1998 revealed a 30 mm Hg gradient (120 vs 150 mm Hg) between the right and left brachial arteries as well as a significant ankle-brachial pressure gradient (220 mm Hg at the ankles bilaterally) indicating bilateral subclavian disease. Subsequent upper extremity arterial Doppler evaluation in March 1998 following corticosteroid treatment revealed only mild abnormalities in the segmental pressures of the right upper extremity (172 mm Hg) compared to the left upper extremity (184 mm Hg). Bilateral selective renal angiograms in November 1998 (Figure 3) showed evidence of arteritis (focal areas of irregularity as well as caliber changes and an angular and corkscrew appearance) in the small and large renal arteries. Her blood pressure was difficult to control, despite treatment with multiple agents. A left renal biopsy in February 1999 showed changes of acute and chronic ischemia including acute tubular injury with parenchymal scarring and moderate to severe interstitial fibrosis and tubular atrophy. Although she was treated with prednisone and multiple immunosuppressive drugs including monthly pulse cyclophos-

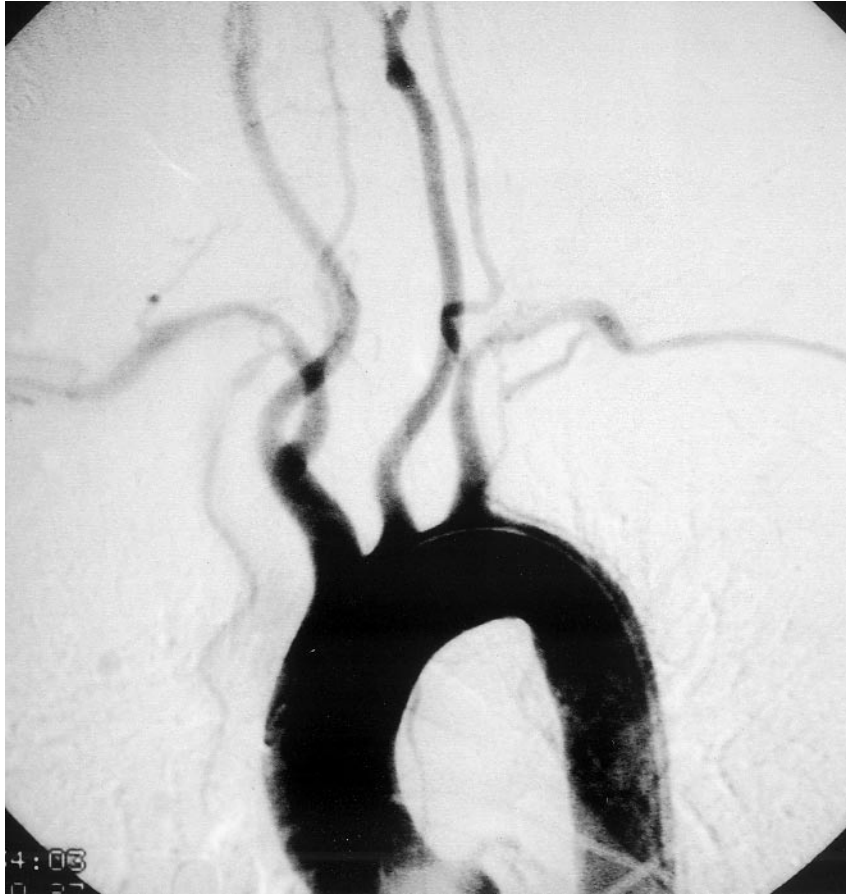

Figure 2. Angiogram in Patient 2 detailing bilateral subclavian artery stenoses.

phamide, her renal function continued to deteriorate and MRI/MR angiography revealed no change in the subclavian stenoses. Progressive renal failure was ascribed to her hypertension and underlying arteritis. Immunosuppressive therapy was discontinued in June 1999 and hemodialysis commenced 2 mo later. In September 1999, her HBsAb was negative. She successfully underwent living related renal transplantation in November 1999. The native kidneys were neither explanted nor biopsied at the time of transplant.

DISCUSSION

A myriad of disorders and autoimmune phenomena have been reported following recombinant hepatitis B vaccination, including RA²⁻⁴, SLE^{6,7}, high titer anti-dsDNA antibodies¹⁸, uveitis¹⁹, immune mediated thrombocytopenia¹⁴, and vasculitis⁸⁻¹⁵. All published cases of vasculitis associated with recombinant hepatitis B vaccination have involved diseases of small or medium size vessels, such as Churg-Strauss, cutaneous leukocytoclastic vasculitis, and angiitis of the central nervous system¹³. Although one case of Takayasu's arteritis developing after inoculation with a plasma derived hepatitis B vaccine has been reported¹⁶, large artery vasculitis following recombinant hepatitis B vaccination has not been noted. Our cases are instructive, therefore, because they suggest that large artery vasculitis may be associated with recombinant hepatitis B vaccination.

Of our 2 patients, one had Takayasu's arteritis and the other had large artery disease that is difficult to classify. The diagnosis of Takayasu's arteritis fits Patient 1 well, as she was a young woman with angiographic abnormalities of the subclavian, celiac, superior mesenteric, and renal arteries that are characteristic of Takayasu's²⁰. The vasculitis in Patient 2, with large artery involvement of her subclavian arteries and renal arteries, also suggests Takayasu's arteritis. However, her advanced age and the sparing of other vessels would be unusual for Takayasu's²⁰. A diagnosis of giant cell arteritis (GCA) would fit her onset of disease after age 50 and the subclavian changes, which may occur in GCA in the absence of temporal artery involvement²¹. However, GCA would not explain the bilateral renal artery disease our patient had²². Since she had had symptoms of polymyalgia rheumatica in 1990, it is worth considering that the subclavian disease was old (secondary to GCA), and that only the renal vascular changes were new. However, followup Doppler examination of her arms in February 1998 showed improvement in the waveforms, suggesting that the subclavian disease was new enough to respond to the corticosteroids. Thus, it is most likely that the subclavian and renal disease developed at about the same time, making the diagnosis of GCA less likely. Fibromuscular dysplasia can

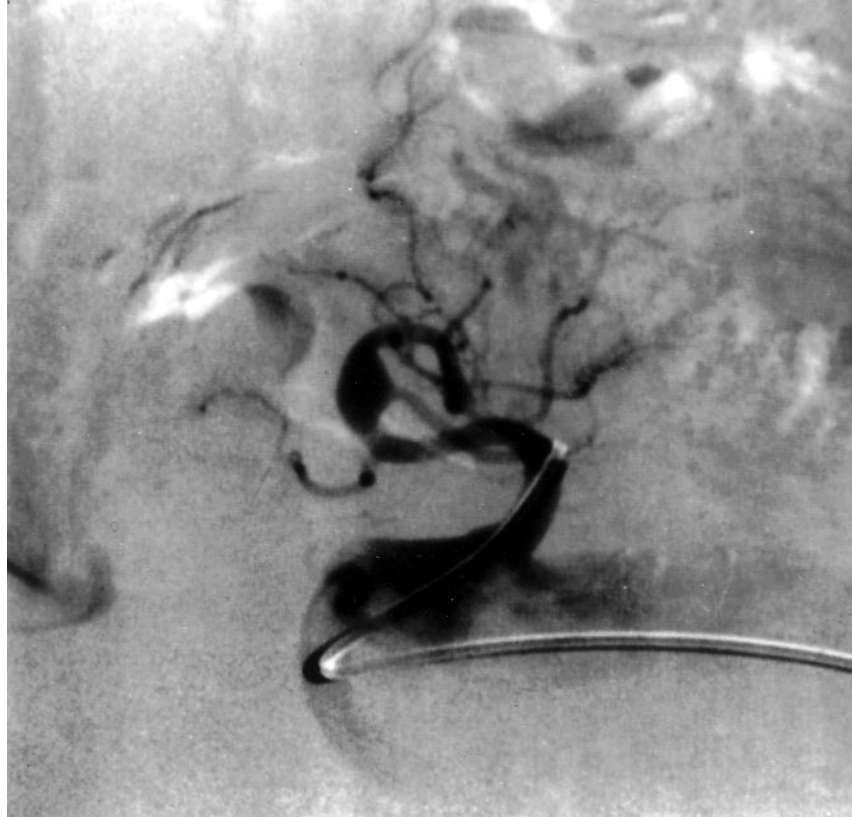

Figure 3. Digital subtraction imaging from selective catheterization of the left renal artery of Patient 2 showing fusiform dilatation of the renal artery visualized at the apex of the renal artery curve. Subtle irregularities and punctate accumulations of contrast suggestive of microaneurysm are seen in the branch vessels proximal to the large renal artery aneurysm.

mimic some of the renal artery changes seen in the second patient, can rarely involve the subclavian arteries, and is associated with a normal ESR²³. However, the older age of our patient, the profound systemic symptoms (i.e., malaise, fatigue, anorexia), the documented improvement of the subclavian wave forms after prednisone, the rapid progression of the renal lesions, and the angiographic changes of the left renal artery would be atypical for that diagnosis²³. Arteriosclerosis causes chiefly proximal disease of the renal artery and would not produce the subclavian lesions²¹. Pheochromocytoma, a rare cause of beading of renal arteries²³, was excluded in our patient. As well, she had no features of neurofibromatosis or Ehlers-Danlos syndrome, other rare diseases that can affect the renal arteries²³. Thus, Patient 2 appears to have had large artery vasculitis that defies precise classification.

It is not possible to determine whether the large artery vasculitis evident in our patients was caused by the vaccination or simply temporally associated. The number of cases of vasculitis that have been reported following vaccinations at least raises the possibility of a causal relationship. Vasculitis has been reported following vaccination not only for hepatitis B but also for vaccination against influenza A²⁴, hepatitis A²⁵, rubella, and smallpox²⁶. In the cases of

vasculitis associated with hepatitis B, HBsAb status and antibody titers were not consistently reported. However, several authors report very high HBsAb titers^{2,4,11,13,15,16}. Extrahepatic manifestations of hepatitis B infection are thought to be an immune complex mediated phenomenon whose intensity and nature are determined by antigen and antibody titers^{27,28}. Perhaps a brisk response to vaccination is a component of postvaccination autoimmune phenomena. However, antibody response cannot be the sole factor as both of our patients initially developed HBsAb, but became seronegative following immunosuppressive treatment. An antibody response may be necessary but not sufficient for vaccine related vasculitis development. Small vessel vasculitides (i.e., leukocytoclastic vasculitis) that develop after infection or vaccination have been attributed to an immune complex mediated process^{27,28}. It is possible that large vessel vasculitis, such as manifested in our patients, could develop in a similar fashion. That both our patients had had an underlying rheumatic disease (ankylosing spondylitis in one and polymyalgia rheumatica in the other) suggests the possibility that patients with immunologic dysfunction may be more susceptible to developing vasculitis following vaccination.

The prognosis with vasculitis associated with hepatitis B

vaccination is variable. Most cited cases of small vessel vasculitis associated with recombinant hepatitis B vaccination have had favorable outcomes^{10-14,27}. The patient reported to have developed Takayasu's arteritis following plasma derived hepatitis B vaccination also improved¹⁶. In contrast, our second patient had relentlessly progressive disease despite a variety of immunosuppressive therapies and eventually needed renal transplantation.

Our cases indicate that large artery vasculitis should be added to the list of rheumatic diseases that can follow recombinant hepatitis B vaccination.

REFERENCES

1. Carmeli Y, Oren R. Hepatitis B vaccination side effect. *Lancet* 1993;341:250-1.
2. Gross K, Combe C, Kruger K, et al. Arthritis after hepatitis B vaccination: report of three cases. *Scand J Rheumatol* 1995; 24:50-2.
3. Pope JE, Stevens A, Howson W, et al. The development of rheumatoid arthritis after recombinant hepatitis B vaccination. *J Rheumatol* 1998;25:1687-93.
4. Soubrier M, Dubost JJ, Bielsa C, et al. Polyarthrite érosive déclenchée par une vaccination contre l'hépatite B [Erosive polyarthritis following hepatitis B vaccination]. *Presse Méd* 1997;26:75.
5. Vautier G, Carty JE. Acute sero-positive rheumatoid arthritis occurring after hepatitis B vaccination [letter]. *Br J Rheumatol* 1994;33:991.
6. Guiserix J. Systemic lupus erythematosus following hepatitis B vaccine [letter]. *Nephron* 1996;74:441.
7. Tudela P, Marti S, Bonal J. Systemic lupus erythematosus and vaccination against hepatitis B [letter]. *Nephron* 1992;62:236.
8. Christian CL. Hepatitis B virus and systemic vasculitis. *Clin Exp Rheumatol* 1991;9:1-2.
9. Cockwell P, Allen MB, Page R. Vasculitis related to hepatitis B vaccine [letter]. *BMJ* 1990;301:1281.
10. Devin F, Roques G, Disdier P, Rodor F, Weiller PJ. Occlusion of central retinal vein after hepatitis B vaccination [letter]. *Lancet* 1996;347:1626.
11. Granel B, Disdier P, Devin F, et al. Occlusion de la veine centrale de la rétine après vaccination contre l'hépatite virale B par vaccin recombinant. Quatre observations [Central retinal vein occlusion after hepatitis B recombinant vaccination. 4 cases]. *Presse Méd* 1997;26:62-5.
12. Kerleau JM, Lésvesque H, Lari G, et al. La vaccination contre l'hépatite B est-elle une nouvelle cause de vascularite nécrosante? [Is vaccination for hepatitis B a new cause for necrotizing vasculitis?]. *Rev Méd Interne* 1997;18:491-6.
13. Le Hello C, Cohen P, Bousser MG, et al. Suspected hepatitis B vaccine related vasculitis. *J Rheumatol* 1999;26:191-4.
14. Neau D, Laharie D, Zerbib F, et al. Vascularite grave après vaccination contre l'hépatite B: une observation [Vasculitis after vaccination for hepatitis B]. *Rev Méd Interne* 1996;17 Suppl 1:142.
15. Vanoli M, Gambirini D. A case of Churg-Strauss vasculitis after hepatitis B vaccination. *Ann Rheum Dis* 1998;57:256-7.
16. Castrensa-Ilsa C, Herrera-Martinez G, Vega-Molina J. Erythema nodosum and Takayasu's arteritis after immunization with plasma-derived hepatitis B vaccine. *J Rheumatol* 1993;20:1417-8.
17. Dardik A, Ballermann BJ, Williams GM. Successful delayed bilateral renal revascularization during active phase of Takayasu's arteritis. *J Vasc Surg* 1998;27:552-4.
18. Lilic D, Ghosh SK. Liver dysfunction and DNA antibodies after hepatitis B vaccination. *Lancet* 1994;344:1292-3.
19. Fried M, Conen D, Conzelmann M, et al. Uveitis after hepatitis B vaccination. *Lancet* 1987;2:631-2.
20. Kerr GS, Hallhan CW, Giordano J, et al. Takayasu's arteritis. *Ann Intern Med* 1994;120:919-29.
21. Brack A, Martinez-Taboada V, Stanson A, et al. Disease pattern in cranial and large vessel giant cell arteritis. *Arthritis Rheum* 1999;42:311-7.
22. Hunder GG. Giant cell arteritis and polymyalgia rheumatica. *Med Clin N Am* 1997;81:195-217.
23. Luscher TF, Lie JT, Stanson AW, et al. Arterial fibromuscular dysplasia. *Mayo Clin Proc* 1987;62:931-52.
24. Mader R, Narendran A, Lewtas J, et al. Systemic vasculitis following influenza vaccination. Report of three cases and literature review. *J Rheumatol* 1993;20:1429-31.
25. Bani-Sadr F, Guet I, Humbert G. Vasculitis related to hepatitis A vaccination. *Clin Infect Dis* 1996;22:596.
26. Somer T, Finegold SM. Vasculitides associated with infections, immunizations, and antimicrobial drugs. *Clin Infect Dis* 1995;20:1010-36.
27. Carmeli Y, DeMedina T. Serious hepatitis B vaccine adverse reactions, are they immune mediated? *Vaccine* 1993;11:1358-9.
28. Mathieu E, Fain O, Krivitsky A. Cryoglobulinemia after hepatitis B vaccination [letter]. *N Engl J Med* 1996;335:355.