

Anti- α -Fodrin Antibodies in Sjögren's Syndrome in Children

NOBUAKI MAENO, SYUJI TAKEI, HIROYUKI IMANAKA, HIROSHI ODA, KUMIKO YANAGI, YOSHIO HAYASHI, and KOICHIRO MIYATA

ABSTRACT. Objective. To investigate the prevalence of anti- α -fodrin antibody specific for adult Sjögren's syndrome (SS) in patients with juvenile onset SS.

Methods. Serum anti- α -fodrin antibody was examined in 15 patients with juvenile SS (11 cases of primary SS and 4 secondary SS) and in 16 children with systemic lupus erythematosus (SLE) by Western blot analysis using a recombinant 120 kDa α -fodrin fusion protein.

Results. All the 15 serum samples from patients with SS reacted with a recombinant α -fodrin fusion protein in Western blot analysis. In contrast, reactivity was found in only 2 of the 16 patients with SLE. The clinical features of the 15 patients with juvenile onset SS were very specific; only 4 patients complained of dryness, while 6 had abnormal excretion ability. Salivary gland enlargement was the most common clinical manifestation. Characteristic laboratory findings in juvenile onset SS included a higher prevalence of antinuclear antibodies, anti-SSA/Ro antibodies, and rheumatoid factor, as well as increased erythrocyte sedimentation rate and hypergammaglobulinemia.

Conclusion. The pathogenesis of juvenile SS seems to be the same as that of adult SS, although subjective symptoms of dryness are less frequent in juvenile cases. This discrepancy may indicate that SS is a slowly progressive disease with a long time span. The anti- α -fodrin antibody is likely to be a reliable diagnostic marker for juvenile SS. (J Rheumatol 2001;28:860-4)

Key Indexing Terms:

SJÖGREN'S SYNDROME CHILDREN α -FODRIN SYSTEMIC LUPUS ERYTHEMATOSUS

Sjögren's syndrome (SS) is a chronic autoimmune disorder of unknown etiology affecting mainly the lacrimal and salivary glands^{1,2}. Lymphocytic infiltration of the lacrimal and salivary glands leads to dry mouth (xerostomia) and dry eyes (xerophthalmia). SS is regarded as a disease of adulthood, commonly affecting middle aged women³. The onset of SS in childhood has been thought to be rare⁴⁻⁷. Recently, however, juvenile SS has been considered to be more frequent than previously suspected^{8,9}. Further, the clinical features of juvenile SS differ slightly from those of adult SS. Comparatively, a lower frequency of subjective symptoms of dryness is characteristic of juvenile SS^{8,10-12}. It is unknown whether this difference in clinical findings between juvenile SS and adult SS is related to some differ-

ence in their pathogenesis. Recently, Haneji, *et al* purified a candidate organ-specific autoantigen from the salivary gland tissue of a NFS/sld mouse model of human SS¹³. The amino-terminal residues of the 120 kDa autoantigen were identical to the NH₂-terminal sequence of α -fodrin. It was also reported that in the non-obese diabetic (NOD) mouse model of SS, the specific anti-120 kDa α -fodrin immune response was observed in the development of autoimmune sialadenitis¹⁴. Moreover, antibodies against 120 kDa α -fodrin are highly detected in sera from adult patients with SS, but not in sera from patients with other autoimmune diseases or from healthy controls^{13,15}. Therefore, it was suggested that the 120 kDa α -fodrin molecule may be an important autoantigen in the pathogenesis of SS. We examined the prevalence of anti- α -fodrin antibody in juvenile SS to determine whether 120 kDa α -fodrin is involved in the pathogenesis of juvenile SS as it is in adult SS. We also investigated whether anti- α -fodrin antibody is a reliable diagnostic marker for juvenile SS, and the presence of anti- α -fodrin antibody is associated with some clinical and laboratory findings. To our knowledge, this is the first report to investigate the relationship between α -fodrin and juvenile SS.

MATERIALS AND METHODS

Subjects. We studied 15 patients with juvenile onset SS (12 girls, 3 boys) who were diagnosed and followed at the Pediatric Department of Kagoshima University Hospital. Eleven patients had primary SS and 4 had

From the Department of Pediatrics and the Department of Bacteriology, Faculty of Medicine, Kagoshima University, Kagoshima, and the Department of Pathology, Tokushima University School of Dentistry, Tokushima, Japan.

N. Maeno, MD; S. Takei, MD; H. Imanaka, MD, Department of Pediatrics, Faculty of Medicine; H. Oda, MD, PhD, Professor, Department of Bacteriology, Faculty of Medicine, Kagoshima University; K. Yanagi, DDS, PhD; Y. Hayashi, MD, PhD, Professor, Department of Pathology, Tokushima University School of Dentistry; K. Miyata, MD, Professor, Department of Pediatrics, Faculty of Medicine, Kagoshima University.

Address reprint requests to Dr. N. Maeno, Department of Pediatrics, Faculty of Medicine, Kagoshima University, 8-35-1 Sakuragaoka, Kagoshima City, 890-8520 Japan.

Submitted July 5, 2000 revision accepted October 19, 2000.

secondary SS with other autoimmune disorders. Three of the patients had secondary SS associated with systemic lupus erythematosus (SLE); in the fourth patient, secondary SS was associated with mixed connective tissue disease. The diagnosis of SS was based on preliminary criteria for the classification of SS¹⁶ with some modifications, as described¹⁰. Subjective symptoms documenting dryness are not common in juvenile SS, so the diagnosis of SS was made mainly according to objective findings such as laboratory abnormalities, parotid sialography, and minor salivary gland biopsy. All 15 patients had histopathological findings typical of and/or sialographic changes in salivary glands consistent with SS. Three patients were being treated with prednisolone while they were enrolled in this study. For comparison with patients with juvenile SS, we tested 16 children who met the American College of Rheumatology criteria for SLE¹⁷ as disease controls. All investigations were carried out with informed consent.

Serological investigations. Laboratory evaluations for each patient were performed as follows: rheumatoid factor (RF) by nephelometric method; antinuclear antibodies (ANA) by indirect immunofluorescence on HEp-2 cells; anti-SSA/Ro, anti-SSB/La, anti-Sm, and anti-RNP antibodies by ELISA (MBL, Nagoya, Japan); antibodies to single stranded and double stranded DNA by ELISA (Dia-iatron, Tokyo, Japan).

Western blotting. A recombinant human 120 kDa α -fodrin fusion protein, constructed by the glutathione S-transferase (GST) fusion system in *Escherichia coli* as described¹³, was used as the antigen source for the immunoblot. In brief, JS-1 cDNA¹⁸, which encoded the NH₂ 1-1 terminal portion of human α -fodrin, was constructed by inserting cDNA (base pairs 1–1784) into the Eco RI site of plasmid pGEX-2T. Then GST and recombinant JS-1-GST fusion protein were expressed and purified with a GST gene fusion system (Pharmacia) as described¹⁹. Recombinant JS-1 fusion protein (97 kDa) was electrophoresed on sodium dodecyl sulfate 7.5% polyacrylamide gels and transferred to nitrocellulose membranes (Schleicher & Schuell, Keene, NH, USA). Immunoblots were processed as described¹³, with human serum used as the primary antibody at a dilution of 1:100. The second antibody was a horseradish peroxidase conjugated goat anti-human IgG Fab' (diluted 1:5000; IBL, Gunma, Japan). Detection of reactivity was analyzed using ECL Western blotting detection reagents (Amersham International, Princeton, NJ, USA). GST, a component of the JS-1 fusion protein, was used as a negative control protein. Anti-GST antibody was purchased from Upstate Biotechnology (Lake Placid, NY, USA).

RESULTS

The mean age of our 15 patients at the onset of symptoms was 11.6 years (range 5.3–14.5 yrs). The mean duration of illness was 1.6 years (range 0.1–11.9 yrs). Eight of the 15 patients were at the early stage of the disease, that is, within 3 months from disease onset.

Western blot analysis results of recombinant JS-1-GST fusion protein with serum samples from representative patients are shown in Figure 1. All serum samples from the 15 patients with juvenile SS reacted with the JS-1-GST fusion protein. In contrast, the reactivity was detected in only 2 of 16 patients in the SLE group. To exclude the possibility that positive sera might have bound to GST protein (which is a component of the JS-1-GST fusion protein), the reaction between sera and GST protein alone was examined. As shown in Figure 2, the serum sample from the representative SS patient reacted with JS-1-GST fusion protein, but not with GST protein. None of the remaining serum samples exhibited reactivity to GST protein. Therefore, it was confirmed that positive sera reacted specifically to the

portion of JS-1 that encodes the NH₂ 1-1 terminal portion of human α -fodrin.

Clinical features of SS patients in which the anti- α -fodrin antibody was examined are shown in Figure 3. Subjective manifestations of dryness such as xerophthalmia or xerostomia were observed in only 4 of 15 patients (26.7%), and objective examination for dryness, such as Schirmer test, Rose-Bengal test, and measurement of salivary flow, showed abnormality in 6 of 15 patients (40.0%). The most common clinical manifestation was salivary gland enlargement (10 patients, 66.7% of cases). Salivary gland enlargement, fever, and annular erythema seem to be characteristic symptoms in patients with primary SS. Laboratory findings of patients with juvenile SS showed a higher frequency of ANA, anti-SSA/Ro antibody, RF, accelerated erythrocyte sedimentation rate (ESR), and hypergammaglobulinemia. Anti-SSB/La antibody seemed to be specific for primary SS. The patients with salivary gland enlargement did not always show elevated serum levels of amylases. Serum complement (C3 and C4) and C-reactive protein were within normal limits in all patients with SS. The 2 patients with SLE possessing the anti- α -fodrin antibody did not have symptoms suggesting SS. Both patients had elevated ESR and were positive for ANA and anti-SSA/Ro antibodies, and were negative for RF and anti-SSB/La antibodies. Neither had hypergammaglobulinemia.

DISCUSSION

Fodrin is an actin-binding cytoskeletal protein that has been postulated to play a pivotal role in secretion^{20,21}. It forms heterodimers composed of α (240 kDa) and β (235 kDa) subunits. The α subunit is cleaved in association with apoptosis, and the 120 kDa fragment is a breakdown product of α -fodrin^{22,23}. We detected the anti-120 kDa α -fodrin antibody in all patients with juvenile onset SS. It has been reported that autoimmune response against 120 kDa α -fodrin may play a critical role in the development of adult SS^{13,14}. Our findings raise the possibility that the pathogenesis of juvenile onset SS is the same as that of adult SS. However, the clinical features of our patients with juvenile SS differed from those of adult SS. In patients with juvenile SS, low frequencies of subjective symptoms of dryness were remarkable despite the high prevalence of salivary gland enlargement; positivity for ANA, RF, anti-SSA/Ro and/or SSB/La; hypergammaglobulinemia; and elevated ESR. These findings are compatible with previous reports on juvenile SS^{8-11,24,25}. The association of anti- α -fodrin antibody with RF positivity and hyperglobulinemia was reported in a previous study¹⁵. Similarly, in our patients with anti- α -fodrin antibody, a high prevalence of both RF and hyperglobulinemia was observed. This suggests that the anti- α -fodrin antibody may reflect potentially activated autoimmunity in both adults and children with SS.

Considering the high prevalence of α -fodrin antibody in

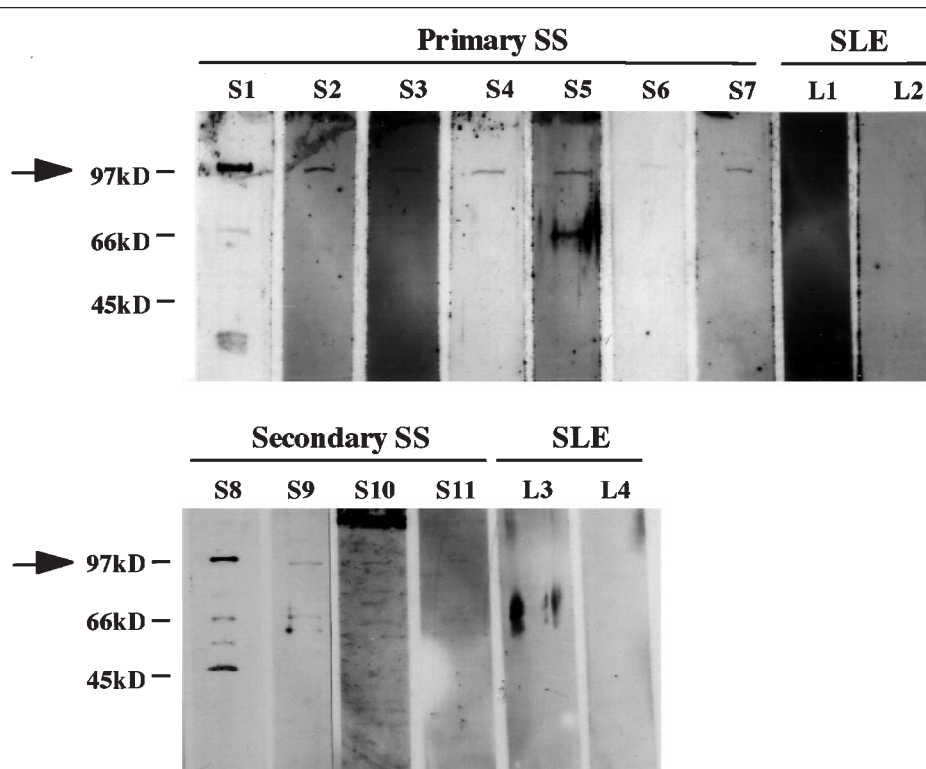
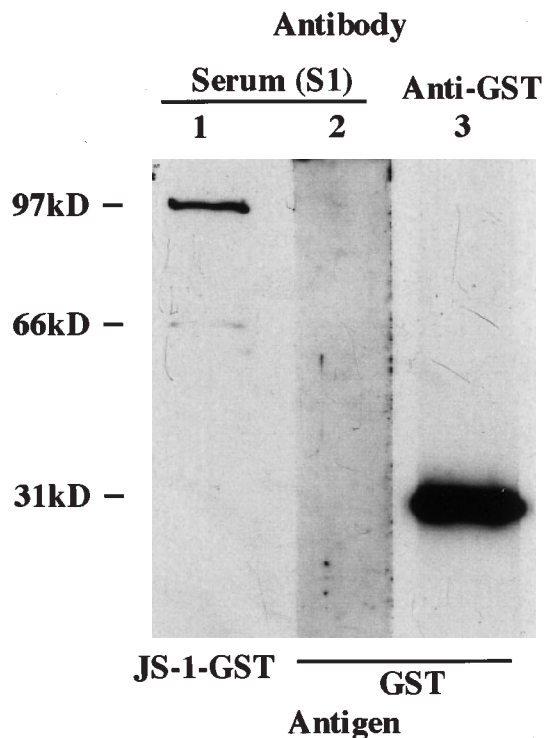


Figure 1. Western blot analysis of recombinant 120 kDa α -fodrin fusion protein JS-1 with sera from representative patients with juvenile onset SS and SLE. Serum samples were tested in duplicate at 1:100 dilution. Serum samples from patients with SS, including primary SS (S1–7) and secondary SS (S8–11), reacted with JS-1 protein (predicted size was 97 kDa). Sera from SLE patients (L1–4) were negative for anti-JS-1 protein. The 70 and 50 kDa protein is an artifact band of *E. coli* degradation. Molecular weight markers are shown to the left.



patients with juvenile SS, which suggests a similar if not identical pathogenesis of SS in adults and children, it is speculated that juvenile onset SS might be an early stage of adult SS, one prior to the development of subjective symptoms of dryness. In support of this hypothesis, Tomiita, *et al* reported that children with SS without symptoms of dryness (so-called subclinical SS) showed the same immunological characteristics as patients with clinical SS, and that some patients with subclinical SS ultimately developed exocrinopathy during the followup period¹¹. In this regard, it seems reasonable to consider that even subclinical SS should be treated immediately to prevent irreversible damage of the glands. However, the efficacy of therapeutic intervention in juvenile SS is still controversial^{9,26,27}. The

Figure 2. Representative Western blot showing specific reactivity of serum from a patient with SS to the portion of JS-1 of the recombinant fusion protein. The serum from the SS patient (S1) reacted with JS-1-GST fusion protein (lane 1), but not with prepared GST protein alone (lane 2). As a positive control, a commercial anti-GST antibody showed reactivity to the 29 kDa GST protein (lane 3). Similarly, no serum samples exhibited reactivity to GST protein by Western blot analysis. Molecular weight markers are shown to the left.

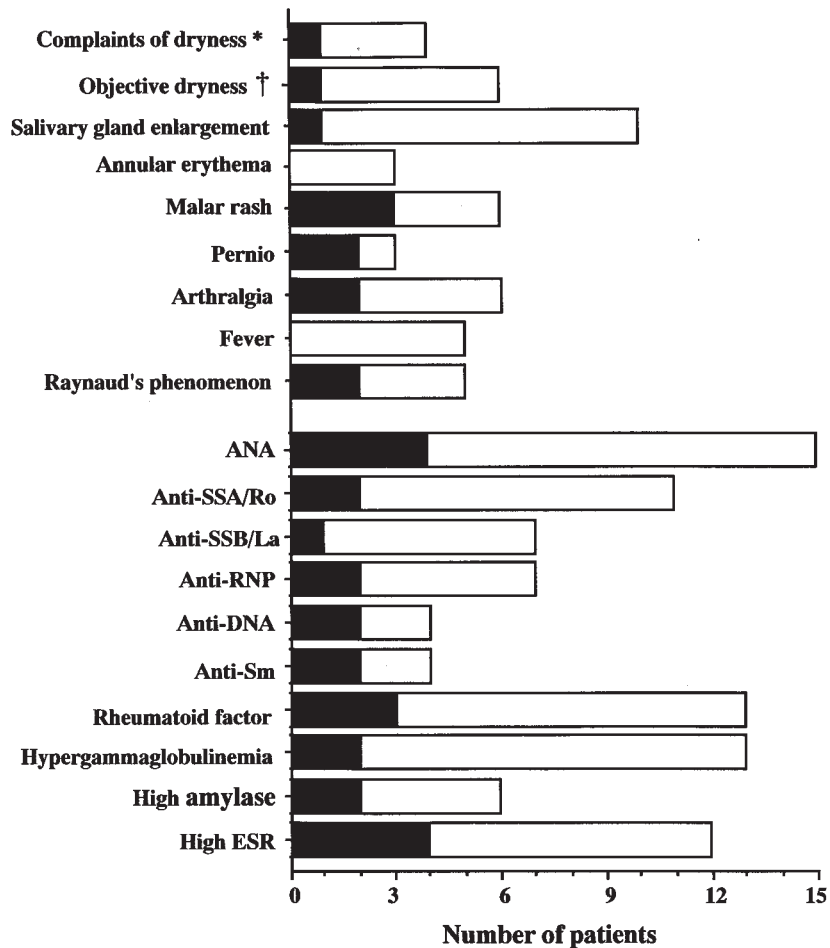


Figure 3. Clinical features of 15 patients with juvenile SS at onset. □: Primary SS (n = 11). ■: Secondary SS (n = 4). *Subjective symptoms of dryness such as xerostomia and xerophthalmia. †: Abnormality in Schirmer test, Rose-Bengal test, or measurement of salivary flow. Positive limits for each test were as follows: hypergammaglobulinemia: IgG \geq 2000 mg/dl; high amylase: \geq 130 IU/l; high ESR: \geq 20 mm/h.

usefulness of therapy for subclinical SS in children remains to be confirmed by additional longterm followup studies.

The clinical usefulness of anti- α -fodrin antibody has been discussed in adult SS and neonatal lupus erythematosus^{13,15,28}. Similarly, our results raise the possibility that determination of anti- α -fodrin antibody in serum is useful for diagnosis of juvenile SS. Notably, the sensitivity of anti- α -fodrin antibody in our patients with SS was higher than that reported in adult SS^{13,15} (Table 1). The discrepancy in sensitivity among studies may be due to the fact that all our patients had typical histopathological changes in the salivary glands. In addition, abnormal autoimmune response may be much more involved in the pathogenesis of SS in children than in adults; it is known that factors such as aging, several kinds of viruses, and sex hormones can be a trigger of autoimmune diseases. With regard to specificity, 2 of 16 patients with SLE revealed antibodies reacting with 120 kDa α -fodrin. Neither patient had clinical or laboratory findings indicative of SS. However, given that neither

Table 1. The prevalence of anti- α -fodrin antibody in adult and pediatric patients with Sjögren's syndrome.

	Haneji, <i>et al</i> ¹³ , Adults (%)	Watanabe, <i>et al</i> ¹⁵ , Adults (%)	This Report, Children (%)
Primary SS	41/43 (95.3)	7/9 (77.8)	11/11 (100)
Secondary SS	5/8 (62.5)	9/15 (60.0)	4/4 (100)
SLE	0/21 (0)	3/44 (6.8)	2/16 (12.5)
RA	0/14 (0)	ND	ND
Healthy controls	0/15 (0)	ND	ND

Each value represents the number of patients with positive results over the number of tested patients. ND: Not done.

parotid sialography nor salivary gland biopsy were performed, we cannot rule out the possibility that they might have secondary SS. Further studies are needed to confirm the specificity of anti- α -fodrin antibody in diagnosis of juvenile SS. We believe that detection of antibodies to 120 kDa α -fodrin in patients suspected to have SS would indi-

cate that further invasive examination, such as parotid sialography or lip biopsy, should be considered.

Our results suggest that (1) 120 kDa α -fodrin, the apoptosis associated breakdown product, may have a role in the development of juvenile SS similar to its role in adult SS; and (2) the anti- α -fodrin antibody is likely to be a useful diagnostic marker for juvenile SS. However, at present we have no substantive data confirming these possibilities. Further investigations are necessary to determine the role of 120 kDa α -fodrin in the pathogenesis of juvenile SS and the utility of anti- α -fodrin antibody as a diagnostic marker.

REFERENCES

1. Talal N. Clinical and pathogenetic aspects of Sjögren's syndrome. *Semin Clin Immunol* 1993;6:11-20.
2. Fox RI, Tornwall J, Maruyama T, Stern M. Evolving concepts of diagnosis, pathogenesis, and therapy of Sjögren's syndrome. *Curr Opin Rheumatol* 1998;10:446-56.
3. Bjerrum K, Prause JU. Primary Sjögren's syndrome: a subjective description of the disease. *Clin Exp Rheumatol* 1990;8:283-8.
4. Deprettere AJ, Van Acker KJ, De Clerck LS, et al. Diagnosis of Sjögren's syndrome in children. *Am J Dis Child* 1988;142:1185-7.
5. Kraus A, Alarcon-Segovia D. Primary juvenile Sjögren's syndrome. *J Rheumatol* 1988;15:803-6.
6. Siamopoulou-Mavridou A, Drosos AA, Andonopoulos AP. Sjogren syndrome in childhood: report of two cases. *Eur J Pediatr* 1989;148:523-4.
7. Franklin DJ, Smith RJH, Person DA, Pflugfelder SC. Sjögren's syndrome in children. *Otolaryngol Head Neck Surg* 1986;94:230-5.
8. Anaya JM, Ogawa N, Talal N. Sjögren's syndrome in childhood. *J Rheumatol* 1995;22:1152-8.
9. Ostuni PA, Ianniello A, Sfriso P, et al. Juvenile onset of primary Sjögren's syndrome: report of 10 cases. *Clin Exp Rheumatol* 1996;14:689-93.
10. Bartunkova J, Sediva A, Vencovsky J, Tesar V. Primary Sjögren's syndrome in children and adolescents: proposal for diagnostic criteria. *Clin Exp Rheumatol* 1999;17:381-6.
11. Tomiita M, Saito K, Kohno Y, et al. The clinical features of Sjögren's syndrome in Japanese children. *Acta Paediatr Jpn* 1997;39:268-72.
12. Tanaka H, Onodera N, Ito R, et al. Subclinical Sjögren's syndrome: A significant ⁶⁷gallium accumulation in the orbits and parotid glands. *Acta Paediatr Jpn* 1998;40:621-3.
13. Haneji N, Nakamura T, Takio K, et al. Identification of alpha-fodrin as a candidate autoantigen in primary Sjögren's syndrome. *Science* 1997;276:604-7.
14. Yanagi K, Ishimaru N, Haneji N, et al. Anti-120-kDa α -fodrin immune response with Th1-cytokine profile in the NOD mouse model of Sjögren's syndrome. *Eur J Immunol* 1998;28:3336-45.
15. Watanabe T, Tsuchida T, Kanda N, Mori K, Hayashi Y, Tamaki K. Anti- α -fodrin antibodies in Sjögren's syndrome and lupus erythematosus. *Arch Dermatol* 1999;135:535-9.
16. Vitali C, Bombardieri S, Moutsopoulos HM, et al. Preliminary criteria for the classification of Sjögren's syndrome. Results of a prospective concerted action supported by the European Community. *Arthritis Rheum* 1993;36:340-7.
17. Tan EM, Cohen AS, Fries JF, et al. The 1982 revised criteria for the classification of systemic lupus erythematosus. *Arthritis Rheum* 1982;25:1271-7.
18. Moon RT, McMahon AP. Generation of diversity in nonerythroid spectrins. Multiple polypeptides are predicted by sequence analysis of cDNAs encompassing the coding region of human nonerythroid alpha-spectrin. *J Biol Chem* 1990;265:4427-33.
19. Qadri I, Maguire HF, Siddiqui A. Hepatitis B virus transactivator protein X interacts with the TATA-binding protein. *Proc Natl Acad Sci USA* 1995;92:1003-7.
20. Perrin D, Aunis D. Reorganization of α -fodrin induced by stimulation in secretory cells. *Nature* 1985;315:589-92.
21. Perrin D, Langley OK, Aunis D. Anti- α -fodrin inhibits secretion from permeabilized chromaffin cells. *Nature* 1987;326:498-501.
22. Martin SJ, O'Brien GA, Nishioka WK, et al. Proteolysis of fodrin (non-erythroid spectrin) during apoptosis. *J Biol Chem* 1995;270:6425-8.
23. Vanags DM, Pörn-Ares MI, Coppola S, Burgess DH, Orrenius S. Protease involvement in fodrin cleavage and phosphatidylserine exposure in apoptosis. *J Biol Chem* 1996;271:31075-85.
24. Mizuno Y, Hara T, Hatae K, et al. Recurrent parotid gland enlargement as an initial manifestation of Sjögren's syndrome in children. *Eur J Pediatr* 1989;148:414-6.
25. Hearth-Holmes M, Baethge BA, Abreo F, Wolf RE. Autoimmune exocrinopathy presenting as recurrent parotitis of childhood. *Arch Otolaryngol Head Neck Surg* 1993;119:347-9.
26. Vermynen C, Meurant A, Noel H, Claus D, Cornu G. Sjögren's syndrome in children. *Eur J Pediatr* 1985;144:266-9.
27. Takei S. Sjögren's syndrome. In: Yanagisawa M, Nakazawa S, Miyata K, et al, editors. *The manual of therapy for specified pediatric chronic diseases [Japanese]*. Tokyo: Shindan-To-Chiryosha; 1999:272-4.
28. Miyagawa S, Yanagi K, Yoshioka A, Kidoguchi K, Shirai T, Hayashi Y. Neonatal lupus erythematosus: maternal IgG antibodies bind to a recombinant NH₂-terminal fusion protein encoded by human α -fodrin cDNA. *J Invest Dermatol* 1998;111:1189-92.