

Correspondence



INSTRUCTIONS FOR LETTERS TO THE EDITOR

Editorial comment in the form of a Letter to the Editor is invited; however, it should not exceed 800 words, with a maximum of 10 references and no more than 2 figures or tables and no subdivision for an Abstract, Methods, or Results. Letters should have no more than 3 authors. Full name(s) and address of the author(s) should accompany the letter as well as the telephone number and fax number (if available). Financial associations or other possible conflicts of interest should always be disclosed. To expedite receipt of letters, we encourage authors outside Canada to communicate by fax (416-967-7556).

Self-Injection of Gold and Methotrexate

To the Editor:

We read with interest the paper by Arthur, *et al*¹ and the correspondence relating to it. We recently completed a small, pragmatic study to compare the safety and efficacy of methotrexate (MTX) administered by 2 different routes, intramuscular (im) and subcutaneous (sc), and to teach patients to self-administer MTX by the subcutaneous route. A literature search produced little evidence about the bioavailability of MTX between the 2 parenteral routes^{2,3} and nothing relating to the safety of patient administration. We recognized that there could be potential advantages in terms of convenience, cost, and active patient involvement.

Eight patients receiving a stable weekly dose of intramuscular MTX, who attended the nurse specialist clinics, were invited to participate in the study. Of the 8 participants, 6 were female and 2 were male. The mean age was 43 years (range 36–58). Four had rheumatoid arthritis, 2 psoriatic arthritis, one Wegener's granulomatosis, and one polymyositis. The mean disease duration was 11 years 4 months.

The study was undertaken over 13 weeks. At week 1 variables of disease activity were measured. The nurse specialists administered weekly im MTX at weeks 1 to 3. Serum levels of MTX were measured 1 h after the 3 injections. At week 4 the route of administration was switched to subcutaneous. The nurse specialists administered weekly sc MTX at weeks 4 to 6. Serum levels of MTX were measured 1 h after these. Patients were taught during this phase by practical demonstration and with the addition of written information. For weeks 7 to 9 patients administered their own MTX by sc injection under the supervision of the nurse specialists. At week 9 patients were discharged to self-administer the injections at home. They were provided with pre-drawn syringes, gloves, needles, swabs, sharps disposal boxes, and spillage kits. They had the backup facility of the rheumatology nurses' telephone help-line.

The participants self-administered the MTX at home for weeks 10 to 12. At week 13 they returned to the nurse specialist clinic. At this visit variables of disease activity and patient satisfaction were assessed. Safety monitoring was undertaken for MTX therapy and patients were observed administering their own injections to ensure that their technique was still correct. Used sharps boxes were returned and new supplies were provided. A further appointment for one month was given.

The results from this study have shown that there was no significant difference between sc and im MTX. Individual patients had serum levels of MTX that ranged from 0.34–1.56 mm/l. There was no significant difference

in respect of pain, fatigue, early morning stiffness, and tender joints. Erythrocyte sedimentation rate and C-reactive protein levels fluctuated slightly as would normally occur. No difficulties were encountered with self-administration. One patient experienced a transient local reaction around the injection site. All participants were satisfied with the teaching procedure. Patients preferred the sc route of administration as it was less painful and permitted them to self-inject.

It would appear that self-administration of sc MTX is a safe and effective procedure for patients with reasonable dexterity. As a result of this study, we have changed our practice with the development and adoption of a new protocol. Patients are given MTX by the sc route rather than the im, those that are willing are taught to self-administer and encouraged to undertake this procedure at home. Weekly hospital visits have been reduced to monthly with benefit to patients in terms of cost, time, and convenience.

University Hospital,
Birmingham, UK.

Valerie Arthur, RN, MPhil;
Ronald Jubb, MD, FRCP;
Dawn Homer, RN.

REFERENCES

1. Arthur AB, Klinkhoff AV, Teufel A. Safety of self-injection of gold and methotrexate. *J Rheumatol* 1999;26:302–5.
2. Lourdes M, Montserrat R, Rozadilla A, Cintero MI. Evaluating the safety and self-injection of gold and methotrexate in patients with inflammatory arthritis [letter]. *J Rheumatol* 2000;27:818.
3. Brookes PJ, Spruill WJ, Prish RC, Birchmore DA. Pharmacokinetics of methotrexate administered by intramuscular and subcutaneous injections in patients with rheumatoid arthritis. *Arthritis Rheum* 1990;33:91–5.
4. Jundt JW, Browne B, Fiocco GP, Steele AD, Mock DA. A comparison of low dose methotrexate bioavailability: oral solution, oral tablet, subcutaneous and intramuscular dosing. *J Rheumatol* 1993;20:1845–9.

Dr. Klinkhoff, *et al* reply

To the Editor:

The team from Birmingham are to be commended for piloting a self-injection program for methotrexate (MTX). While 8 patients is a small sample to determine preferences and safety, their conclusions are similar to our own. We have employed a successful self-injection program for gold and MTX for 5 years. Patients are taught either intramuscular or subcutaneous injection technique. We have encountered no serious problems after routine use of self-injection or partner injection for years in more than 100 patients. Because of the high incidence of annoying and potentially dangerous side effects that require close supervision, we have targeted for self-injection education those arthritis patients who are stable taking injectable medication and who have not encountered any potentially serious adverse events over a followup period of 6 months.

Mary Pack Arthritis Centre,
Vancouver, Canada.

Alice V. Klinkhoff, MD, FRCP;
Anne B. Arthur, RN;
Alvena Teufel, RN.

Radiographic Diagnosis of Sacroiliitis — Are Sacroiliac Views Really Better?

To the Editor:

Readers were invited to comment on Figure 1 of page 2713 of the December 1999 issue of *The Journal*. Like Dr. McDuffie we are pretty experienced rheumatologists, but we must admit that we are often in doubt about the diagnosis of sacroiliitis on radiographs. In these cases, like McDuffie, we order a computer tomography (CT) scan. However, we disagree when he writes that

To continue
please scroll
to next page

oblique sacroiliac views are better than anteroposterior views¹. The problem is not a loss of resolution when radiographs are published, as claimed by Dr. Battistone¹, but the incidence of the radiographs. Figure 1 on page 2713 is very well reproduced, but we are not sure that it shows sacroiliitis. Sclerotic changes are visible, but joint widening and erosive changes are not obvious on the left and are absent on the right side. We must consider osteitis condensans ilii. We think that the best incidence is the anteroposterior one but it must be angled upwards 15° to 30° depending on the degree of lumbosacral

angulation². This view has the advantage of showing the sclerotic changes very well, but it cannot always distinguish sclerotic changes of the iliac margin from those of the sacral margin of the joint because of the anterolateral orientation of the sacroiliac joint. Oblique sacroiliac views have the advantage of making this distinction, but they have the disadvantage of narrowing the projection of sclerotic changes and of masking erosive changes. To determine exactly the prevalence of ankylosing spondylitis we may not define sacroiliitis based only on radiologic changes, because sacroiliitis is an impor-

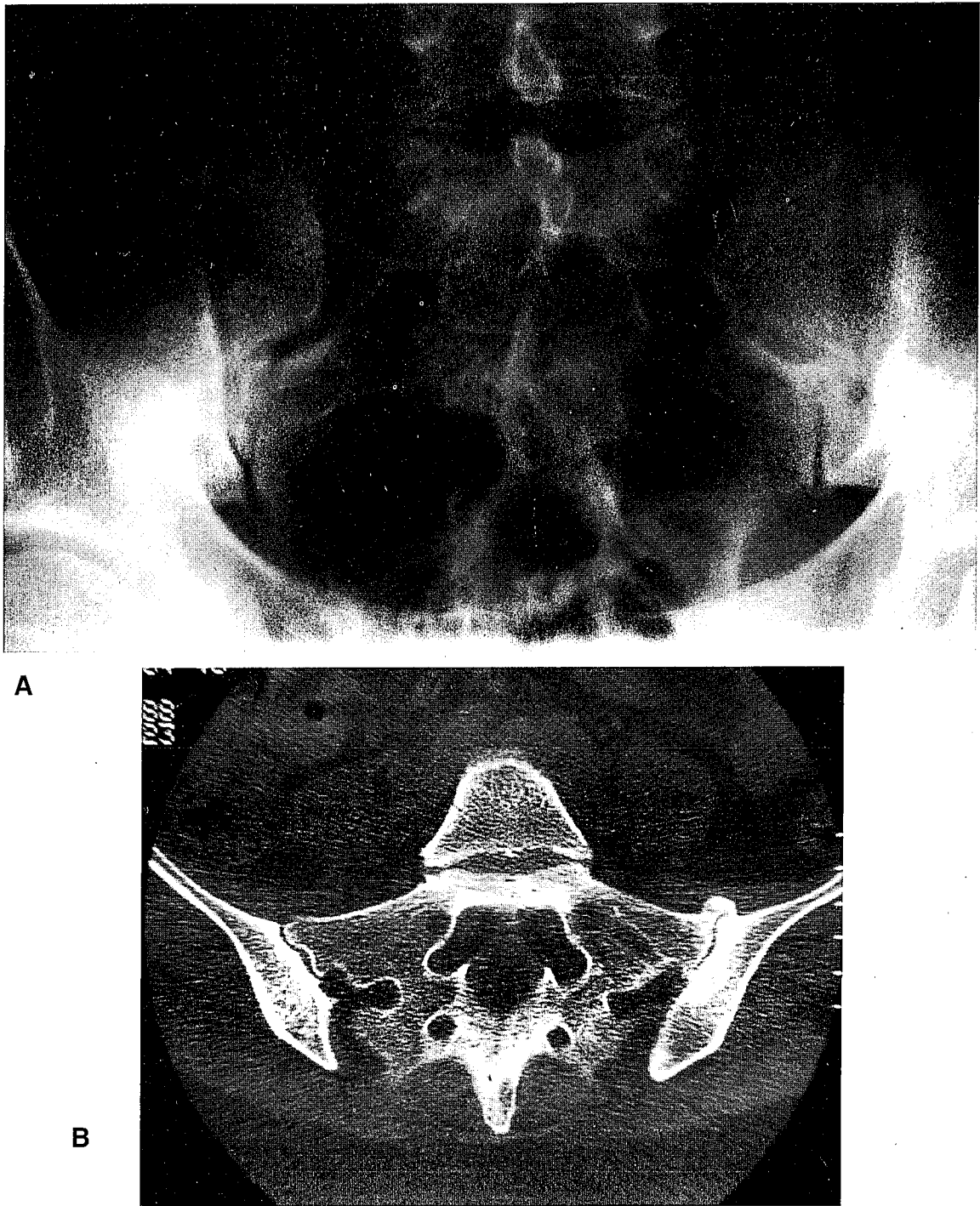
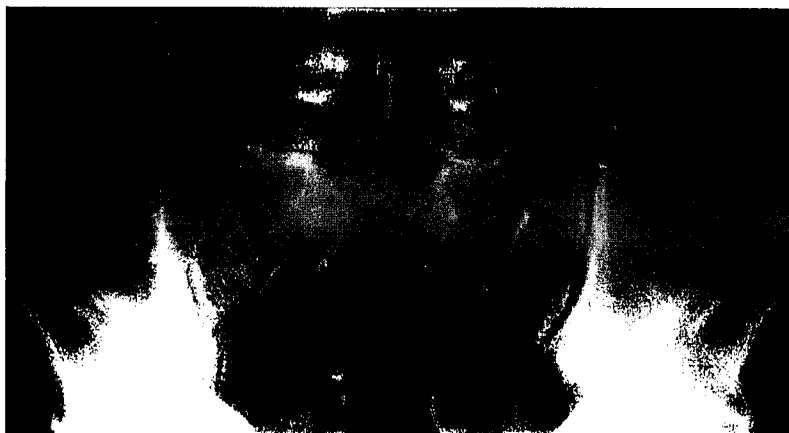


Figure 1. On radiograph (A): is there sacroiliitis on the left? On tomodensitometry (B): osteoarthrosis of the left SI joint.

A



B

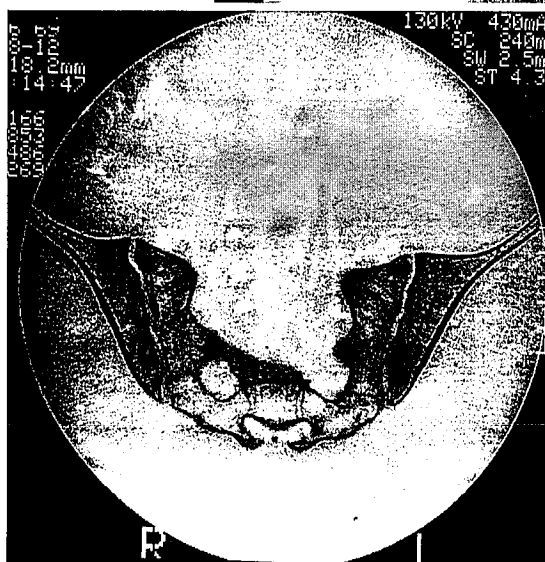


Figure 2. On radiograph (A): is there sacroiliitis on the right? On tomodensitometry (B): normal SI joints.

tant criterion of both the Amor³ and the European Spondylarthropathy Study Group criteria⁴. In many of our patients the preliminary diagnosis of sacroiliitis on radiographs was not confirmed by CT scan. Two examples are shown in Figures 1 and 2.

Rheumatology Department,
Hôpital Cavale Blanche,
Brest University Medical School,
29609 Brest, France.

Paul Le Goff, MD;
Alain Saraux, MD;
Dominique Baron, MD.

REFERENCES

1. McDuffie FC. Radiographic diagnosis of sacroiliitis — are sacroiliac views really better? [letter]. *Battistone MJ*. [reply]. *J Rheumatol* 1999;26:2712–4.
2. Wellinger C. *La sacroiliaque*. Paris: Editions Médicales Specia; 1988.
3. Amor B, Dougados M, Mijiyawa M. Critères de classification des spondyloarthropathies. *Rev Rhum* 1990;57:85–9.
4. Dougados M, van der Linden S, Juhlin R, et al. The European Spondylarthropathy Study Group preliminary criteria for the classification of spondyloarthropathy. *Arthritis Rheum* 1991;34:1218–27.

Dr. McDuffie replies

To the Editor:

It may well be that an angled anteroposterior (AP) view may have advantages over the usual radiographs but I have not ever made such a comparison. I certainly do agree that computed tomography (CT) is the gold standard. It is my practice, if I am pretty sure of the diagnosis and there are physical findings to support it, that I simply get an AP view. If there is some doubt, I get the oblique views also. If the radiographs themselves are not sufficiently definitive, then I have a CT study. Osteitis condensans ilii can be confusing, but it only involves the ilium and, of course, does not produce any joint space narrowing. Osteoarthritis as shown in Figure 1 (above) is unusual, but certainly easy to distinguish on CT.

Phoebe Specialty Medical Group,
Albany, Georgia 31701, USA.

Frederic C. McDuffie, MD.

Dr. Battistone replies

To the Editor:

The comments of Dr. Le Goff and colleagues are greatly appreciated and their points well taken. The data from our series of patients with seronegative spondyloarthropathies suggest that in most cases a series of detailed oblique views of the sacroiliac joints do not provide more useful information in establishing the presence or absence of sacroiliitis than a single frontal projection of the pelvis¹.

Their observation of “false positive” radiographs (i.e., sacroiliitis observed on plain radiographs but not confirmed by computed tomography (CT) is intriguing. In 1981, Kozin, *et al* published data in which CT demonstrated superior sensitivity and comparable specificity to a series of radiographs that included a frontal posteroanterior projection, as well as angled (30° caudal) and oblique views². In their study, 5 (of 8) patients with “equivocal” radiographic findings had negative CT scans; no patient (of 15) with “positive” radiographs was found to have sacroiliitis on CT.

University of Utah School of Medicine,
Salt Lake City, Utah 84132, USA.

Michael J. Battistone, MD.

REFERENCES

1. Battistone MJ, Manaster BJ, Reda DJ, Clegg DO. Radiographic diagnosis of sacroiliitis — are sacroiliac views really better? *J Rheumatol* 1998;25:2395–401.
2. Kozin F, Carrera GF, Ryan LM, et al. Computed tomography in the diagnosis of sacroiliitis. *Arthritis Rheum* 1981;24:1479–85.

Disappointing Longterm Result with Disease Modifying Antirheumatic Drugs

To the Editor:

I read with interest the paper by Galindo-Rodriguez, *et al*¹. The following considerations regarding the analysis of treatment discontinuation seem pertinent. (1) As regards the discontinuation for all causes (Figure 1 and Table 3, left part) the use of the Kaplan-Meier method and of the log-rank test is appropriate. On the other hand, this approach becomes questionable in analyzing toxicity and inefficacy as separate causes of discontinuation. In fact, the key factor in making the 2 above mentioned methods valid is the assumption of independence of the failure time and censoring time distributions. As toxicity and inefficacy act here in a competitive way, the assumption cannot be fulfilled, by definition. In these cases, as suggested by books dealing with the statistical methodology of survival analysis², the correct approach relies on the computation of the crude cumulative incidence and on the use of Gray's test³. (2) As stated on page 2338, methotrexate was used as a first choice drug in only 14% of the patients. This information is of concern when trying to disentangle the effect of the drug and the order with which it was administered in the sequence of drugs. Such information could have been inserted in the multivariate Cox regression model as a dummy variable and according to its effect on the hazard rate it could have been fruitful in reaching clinical conclusions.

Istituto di statistica medica et biometria,
Milan, Italy.

Ettore Marubini, PhD.

REFERENCES

1. Galindo-Rodriguez G, Avina-Zubieta JA, Russell AS, Suarez-Almazor ME. Disappointing longterm results with disease modifying antirheumatic drugs. A practice based study. *J Rheumatol* 1999;26:2337-43.
2. Marubini E, Valsecchi MG. Analysing survival data from clinical trials and observational studies. New York: J Wiley; 1996.
3. Gray RJ. A class of K-sample tests for comparing the cumulative incidence of a competing risk. *Ann Statistics* 1988;16:1141-54.

Drs. Suarez-Almazor and Russell reply

To the Editor:

Our study¹ was based on a survival analysis of terminations of disease modifying antirheumatic drugs (DMARD) in rheumatoid arthritis. We analyzed separately as failures all terminations (any cause), discontinuations due to toxicity, and discontinuations due to lack of efficacy. This type of analysis is commonly used in observational studies and clinical trials. We acknowledge Dr. Marubini's comments, pointing out a common problem with analyses including competing risks. An assumption underlying survival analysis is the independence between the distribution of events and censoring, which is very difficult to prove or disprove in many situations. However, we do not believe that considering toxicity and lack of efficacy separately has violated this assumption in a way that compromises the validity of the findings. The technique suggested by Dr. Marubini² is proposed by Gray for situations where the different failures are considered to be mutually exclusive. It is not clear that toxicity and lack of efficacy are exclusive; moreover, a number of patients had discontinued treatment for both reasons. Although toxicity and efficacy may be related on occasion, there is no evidence of a strong association between these 2 effects in the treatment of rheumatoid arthritis with DMARD. Differential timing among the drugs in the occurrence of the events could affect the results, but there is no clear evidence from our data that this was the case. The reader should be aware nevertheless that the analysis including all terminations is the most robust of all 3, when considering the assumptions of the models.

In relation to the second point, we agree with Dr. Marubini that the sequence of administration of the DMARD may be an important confounding

factor, and thus we indeed included it in the Cox regression analyses reported in our publication, as the rank order of administration, not only for methotrexate, but also for all the other drugs (see Materials and Methods, Table 4).

VAMC, Houston TX, USA;
University of Alberta,
Edmonton, Canada.

Maria E. Suarez-Almazor, MD, PhD;
Anthony S. Russell, FRCP.

REFERENCES

1. Galindo-Rodriguez G, Avina-Zubieta JA, Russell AS, Suarez-Almazor ME. Disappointing longterm results with disease modifying antirheumatic drugs. A practice based study. *J Rheumatol* 1999;26:2337-43.
2. Gray RJ. A class of K-sample tests for comparing the cumulative incidence of a competing risk. *Ann Statistics* 1988;16:1141-54.

Nocardia Pleural Empyema Complicating Anti-Jo1 Positive Polymyositis During Immunoglobulin and Steroid Therapy

To the Editor:

We were greatly interested in the article by Leong, *et al*¹ reporting the clinico-radiological features due to nocardiosis in 5 subjects in a series of 786 patients with systemic lupus erythematosus. The authors point to a large variability of clinical presentations of infection and the difficulty to make a prompt diagnosis.

Nocardiosis affects immunocompromised subjects secondary to organ transplantation, lymphoma, AIDS, and different autoimmune disorders²⁻⁶. In over two-thirds of infected patients the lungs are the prevalent target of *Nocardia*; but when antibiotic therapy is delayed, this agent may also affect the brain, jeopardizing the patient's survival⁷.

We describe the history of a 63-year-old man referred to our hospital in October 1999 because of severe muscular weakness and dyspnea. Patient history was unremarkable for stay abroad or surgery. Since January 1999 our patient was taking prednisone 60 mg/day for interstitial lung alveolitis and anti-Jo1 positive polymyositis. Due to unresponsive polymyositis, intravenous immunoglobulins (16 g/day for 5 consecutive days per month) were associated to steroids since July 1999. Table 1 shows his main clinicoserological and radiological features recorded over the period preceding the present hospital admission. On admission, he complained of fever and left thoracalgia in the absence of cough since one month, severe exertional dyspnea, and diffuse weakness. At examination, typical cushingoid features "moon" facies, overweight, easy bruising, bibasilar lung hypophonesis, and bilateral ankle edema with pitting were detected. Laboratory investigations were as presented in Table 1. At chest radiography abundant, bilateral pleural effusions involving ventilation of the right lung were detected; by computed tomographic scan effusion was found to be multiloculated. Standard electrocardiography and abdomen echography were normal or negative. Virological study, including hepatitis B virus markers, anti-hepatitis C virus, anti-Epstein-Barr virus, anti-cytomegalovirus, and anti-human immunodeficiency virus were negative. Microbiological examination of the drained pleural fluid by Gram stain revealed the presence of *Nocardia asteroides* colonies. Magnetic resonance imaging of the brain excluded cerebral abscess. Considering the high risk of blood spreading of *Nocardia* in immunosuppressed patients and since pleural synechiae were present, our patient had daily pleural instillation of urokinase (0.2 MU) and netilmicin (300 mg) followed by pleural washing by iodine solution (nearly 1500 cc), until complete drainage of the effusion. He was treated by intramuscular netilmicin (300 mg/day) and oral trimethoprim (320 mg/day) and sulfamethoxazole (1600 mg/day) for 3 weeks and subsequently only trimethoprim and sulfamethoxazole to date. Six months later he fully recovered his gait, his exertional dyspnea was mild, and no features of pulmonary infection were detectable at chest radiography.

We describe a case of nocardial pleural empyema in a patient with anti-Jo1 positive polymyositis during the treatment with high steroid dosages and

Table 1. Main clinicoserological and radiological features of our patient at preceding and present hospital admissions.

	Onset of Symptoms	Time after Onset		
		1 mo (1 st H.A.)	4 mo (2 nd H.A.)	10 mo (present H.A.)
Fever	+++	+	++	++
Arthritis	Bilateral genus	—	—	—
Muscular weakness	++	++	+++	+++
Raynaud's phenomenon	+	+	+	+
Dyspnea	+++	+	+	+++
Cough	++	+	—	—
Chest radiograph	Bibasilar alveolitis	Mild alveolitis	Normal	Bilateral pleural effusion
ESR (mm/h)	36	30	84	120
CRP (mg/l)	15	27	65	25
AST (× ULN)	2.1	1.5	0.8	0.9
CPK (× ULN)	ND	5.3	10.8	0.5
LDH (× ULN)	ND	1.9	3.4	1.4
WBC (5–10.5 × 10 ³)	11.6	13.7	15.3	25
Neutrophils (%)	76	79	81	87
Lymphocytes (%)	13	12	11	10
ANA	ND	ND	1:80	1:40
Anti-ENA ¹	ND	ND	anti-Jo1	anti-Jo1
Viral markers*	a	a	a	a

H.A.:Hospital admission, × ULN: value expressed as multiple of upper limit of normal, a: absent, ND: not done, ANA: antinuclear antibody, anti-ENA: anti-extractable nuclear antigens, ¹anti-SSA/Ro, anti-SSB/La, anti-Sm, anti-RNP, anti-Scl70, anti-Jo1, anti-histone; *hepatitis B virus markers, anti-hepatitis C virus, anti-Epstein-Barr virus, anti-cytomegalovirus, and anti-human immunodeficiency virus.

immunoglobulins. Due to a timely diagnosis and conservative treatment the pleural empyema was successfully controlled without further harmful complications.

In Italy nocardiosis is a very uncommon infection⁷. Its incidence has not been estimated. However, Farina and coworkers documented 29 cases of human nocardiosis in northern Italy from 1982 to 1992; interestingly, no case had an immunological systemic disorder, such as systemic lupus erythematosus or polymyositis⁷. The low incidence of the nocardiosis, the difficulty of isolating the agent from the blood, and the unavailability of commercial serologic tests are a few reasons that explain the difficulty of making a timely diagnosis.

In a number of patients with systemic disorders related to immunological alteration, such as polymyositis, systemic lupus, or malignancies, immune status involvement is, at least in part, secondary to steroid and cytotoxic drug treatment. Indeed, Leong and other authors underlined the predisposing role of immunomodifying drugs for this infection^{1,4-6,8}. In our patient the immunosuppression depended on both polymyositis and intensive immunomodulating therapy. In particular, high steroid dosage and, paradoxically, Ig therapy could have affected the patient's immune system and, consequently, compromised his response to *Nocardia*.

Finally, the conservative treatment for nocardial pleuritis meant that our patient avoided undergoing pleural decortication. Apart from possible specific troubles due to decortication⁹, such an approach could, to our knowledge, represent for our patient an additional risk of further infectious complications and/or extrapulmonary dissemination of *Nocardia*. Conversely, the choice of pleural instillation of antibiotics and fibrinolytic drugs allowed us to easily drain the effusion and sterilize the pleural space without further compromising his clinical status.

We suggest that patients with systemic immunological disorders, such as polymyositis or systemic lupus, undergoing intensive immunomodulating therapy such as steroids, immunosuppressors, and/or immunoglobulins should be carefully monitored for early signs of possible dangerous infectious complications, such as nocardiosis.

S. Carlo Hospital,
Potenza, Italy.

Luca La Civita, MD, PhD;
Raimondo Battiloro, MD;
Mariano Celano, MD.

REFERENCES

1. Leong KP, Tee NWS, Yap WM, Chee TSG, Koh ET, and The Singapore Lupus Study Group. Nocardiosis in patients with systemic lupus erythematosus. *J Rheumatol* 2000;27:1306–12.
2. Laurent F, Mick V, Boiron P. Nocardia infections: clinical and biological aspects. *Ann Biol Clin* 1999;57:545–54.
3. Kramer MR, Uttamchandani RB. The radiographic appearance of pulmonary nocardiosis associated with AIDS. *Chest* 1990;98:382–5.
4. Mok CC, Yuen KY, Lau CS. Nocardiosis in systemic lupus erythematosus. *Semin Arthritis Rheum* 1997;26:675–83.
5. Klein-Gitelman MS, Szer IS. Disseminated *Nocardia brasiliensis* infection: an usual complication of immunosuppressive treatment for childhood dermatomyositis. *J Rheumatol* 1991;18:1243–6.
6. Gupta D, Misra R, Agarwal P, et al. Hospital acquired pulmonary nocardiosis complicating polymyositis. *J Assoc Physicians India* 1995;43:641–2.
7. Farina C, Boiron P, Goglio A, Provost F. Human nocardiosis in northern Italy from 1982 to 1992. Northern Italy collaborative group on nocardiosis. *Scand J Infect Dis* 1995;27:23–7.
8. Toukap AN, Hainaut P, Moreau M, Pieters T, Noirhomme P, Gigi J. Nocardiosis: a rare cause of pleuropulmonary disease in the immunocompromised host. *Acta Clin Belg* 1996;51:161–5.
9. Magdeleinat P, Icard P, Pouzet B, Fares B, Rognard JF, Lévassieur P. Current indications and results of pulmonary decortication for nontuberculous chronic empyema. *Ann Chir* 1999;53:41–7.

Dr. Leong replies
To the Editor:

We thank La Civita, *et al* for their interest in our paper. We appreciate that they have reported the first successful treatment of a loculated nocardial pleural empyema in a patient with polymyositis with closed tube drainage, urokinase instillation, iodine lavage, and systemic and intrapleural antibiotics without recourse to open surgery.

It was thought that thoracotomy is mandatory in all patients with complex non-tuberculous pleural empyema to forestall the development of a fibrothorax, but in recent years, attention has been drawn to the use of fibrinolytic agents¹. These factors lyse intrapleural adhesions enzymatically and allow efficient drainage of the pleural fluid. The therapeutic efficacy may be gauged from clinical progress and radiologic imaging. Urokinase is felt to be more effective than streptokinase and the intrapleural instillation of these agents does not affect the coagulation profile markedly¹. At least one of our 5 patients with nocardiosis could have been a candidate for this treatment.

We are also intrigued by La Civita, *et al*'s postulate that intravenous immunoglobulin (IVIG) could have compromised their patient's resistance against *Nocardia*. IVIG modulates the humoral immune system through anti-idiotypic effects, Fcγ receptor blockade, and other mechanisms, but B cells and antibodies are not thought to have a major role in host defence against the organism². However, monocytes and macrophages, which are important in nocardial resistance, are now known to be affected by IVIG as well³.

As the lung is the major portal of entry of *Nocardia*, and a nocardial parapneumonic effusion often progresses to an empyema, the introduction of a new treatment of this complication must be lauded. Further studies are needed to determine if, and under what circumstances, this less invasive approach is better than surgical decortication⁴. Nevertheless, for patients with nocardial infection localized in the pleural space who are too ill to undergo open surgery, this can be a life-saving approach.

Tan Tock Seng Hospital,
Singapore.

Khai Pang Leong, MRCPUK.

REFERENCES

1. Bouros D, Schiza S, Siafakas N. Utility of fibrinolytic agents for draining intrapleural infections. *Semin Respir Infect* 1999;14:39-47.
2. Beaman BL, Beaman L. *Nocardia* species: host-parasite relationships. *Clin Microbiol Rev* 1994;7:213-64.
3. Rhoades CJ, Williams MA, Kelsey SM, Newland AC. Monocyte-macrophage system as targets for immunomodulation by intravenous immunoglobulin. *Blood Rev* 2000;14:14-30.
4. Ferguson MK. Surgical management of intrapleural infections. *Semin Respir Infect* 1999;14:73-81.

Hemodynamics in Vasculitides

To the Editor:

In his reply to my letter, Mercado¹ gives one example of disturbed laminar flow. He finds that serum sickness lesions at branching points of arteries suggest turbulence and that hypertension increases the severity of lesions. Poiseuille and Reynolds¹ may have interpreted the findings differently. Turbulence does not correlate with pressure but with flow velocity, greater in elastic arteries than in small muscular serum sickness arteri(ol)es, which further have a short radius so that flow in these could hardly turn turbulent. These small vessels probably lack vasa vasorum, leaving most of the wall at the mercy of luminal blood flow that, being laminar, correlates with vessel radius (4th power) and is opposed by blood viscosity (1st power). If vasoconstriction contributed to the serum sickness hypertension, energy supply to these vessel walls may have been limited, contributing to cell damage as in vasoconstrictive secondary vasculitis¹, and more readily so if blood viscosity in serum sickness was high.

Perhaps our knowledge of vasculitis would be better if the physics of biology were also considered?

University of Turku,
Turku, Finland.

Johan Ahlqvist, MD.

REFERENCE

1. Ahlqvist J. 160 years of laminar flow (what have we learned?) [letter]; Mercado U. [reply]. *J Rheumatol* 2000;27:2053.

Dr. Mercado replies

To the Editor:

In reflecting over the past decades since the first experimental models of vasculitis (Arthus reaction and serum sickness), 2 facts seem to be evident. First, there has been enormous progress, particularly in recent years, toward understanding the pathophysiology and pathogenesis of the different vasculitides. Second, we have a long way to go.

In addition to the endothelium, all vessels except the true capillaries comprise varying amounts of elastic, collagen, and smooth muscle fibers. Under physiological conditions, flow is laminar and under certain conditions, laminar flow can give way to turbulent flow. The latter is characterized by whirlpools in which the fluid particles move not only parallel to the vascular axis but also perpendicular to it. The smaller the vessel, the more the central layers are slowed by viscous interaction with the stationary wall, because they are closer to it; the mean velocity of flow is therefore low¹.

Both Arthus reaction and serum sickness have been pathogenetic models for small vessel vasculitis. In each of these, immune complexes form in the presence of antigen excess following injection of foreign protein. Occurrence of vasculitis lesions at the bifurcation of vessels in experimental models may represent a role for sustained injury caused by turbulence at these sites, which, in turn, enhances deposition of immune complexes². Hypertension can also enhance the vascular lesions in the experimental model of serum sickness. This has been noted for a long time by a number of investigators³.

Hospital General Mexicali and Universidad
Autonoma de Baja California,
Mexicali, BC, Mexico.

Ulises Mercado, MD, MS, FACR.

REFERENCES

1. Witzleb E. Functions of the vascular system. In: Schmidt RF, Thews G, editors. *Human physiology*. Berlin: Springer-Verlag; 1989:480-542.
2. Gauthier VJ, Mannik M. Immune complexes in the pathogenesis of vasculitis. In: LeRoy BC, editor. *Systemic vasculitis. The biological basis*. New York: Marcel Dekker; 1992:401-20.
3. Fisher ER, Bark J. Effect of hypertension on vascular and other lesions of serum sickness. *Am J Pathol* 1961;39:665-75.



Multifocal *Staphylococcus aureus* Infection Originating from the Sacroiliac Joint in a Patient with Rheumatoid Arthritis

To the Editor:

Despite the common occurrence of septic arthritis in rheumatoid arthritis (RA), involvement of the sacroiliac (SI) joint has not been reported^{1,2}. We describe a case of recurrent SI joint infection due to *Staphylococcus aureus* in a patient with RA, with extensive contiguous and hematogenous spread to the adjacent psoas muscle, thigh, and epidural space and concomitant vertebral osteomyelitis.

A 63-year-old white male with a 10 year history of seropositive, steroid dependent RA was admitted with 3 weeks of pain in the right gluteal region and lower back and intermittent fevers to 102.6°F. His history was remarkable for multiple episodes of *S. aureus* infection, involving the right knee in 1984,

the right SI joint in 1991, and the left olecranon bursa in 1993. Medications included prednisone 20 mg daily and methotrexate 15 mg po weekly.

On examination there was extensive ecchymosis, swelling, and induration of the posterior lateral right thigh, as well as SI joint tenderness. Laboratory data were notable for a white blood cell count of 21,100/mm³ with a left shift, a hematocrit of 26, and a sedimentation rate of 120 mm/h. Empirical therapy was begun with intravenous (iv) cefazolin 2 g every 6 h. Multiple blood cultures subsequently grew a methicillin sensitive *S. aureus*.

Magnetic resonance imaging revealed right SI joint enhancement/destruction with extensive contiguous spread of infection proximally and distally (Figures 1 and 2), osteomyelitis of the L3 vertebral body, and an epidural fluid collection within the sacrum (images not shown). Computed tomography guided percutaneous drainage of the posterior thigh, iliopsoas, and pelvic collections revealed grossly bloody fluid infected with *S. aureus* of the same sensitivity as the blood isolates.

Given the patient's initial clinical improvement with iv antibiotics conservative management with home iv cefazolin was continued in an attempt to reduce and delimit the extent of frank purulence, which would eventually require surgical debridement. However, the patient was readmitted 15 days later with increasing right thigh pain and fever, and operative drainage was undertaken. Three liters of "old blood" were drained from the anterior and

posterior compartments of the thigh. The right psoas abscess was drained by a retroperitoneal approach, and decompressive laminectomy/drainage of the epidural fluid collection was performed. Multiple surgical specimens grew *S. aureus*.

After a 6 week course of iv cefazolin, antibiotic coverage was changed to trovafloxacin with several months concomitant rifampin for synergy and better bone penetration, followed by suppressive therapy with trimethoprim/sulfamethoxazole.

In the present case, the data points to reactivation of a primary SI joint infection with extensive contiguous and hematogenous spread. Radiographs early in the course of the current illness showed changes consistent with old sacroiliitis, and a contemporaneous bone scan showed uptake confined to the SI joint, consistent with reactivation. Magnetic resonance imaging, 10 days later, confirmed SI joint infection and additionally detailed contiguous spread of infection to the psoas muscle and posterior thigh compartment (through fascial planes) and the epidural space. The etiology of the concomitant vertebral osteomyelitis was likely hematogenous spread, given the patient's documented bacteremia. The hemorrhagic component of all the infected fluid collections is unusual and not easily explained, though infection may have predisposed to secondary tendon damage and bleeding.

Interestingly, review of the literature did not identify RA as a risk factor

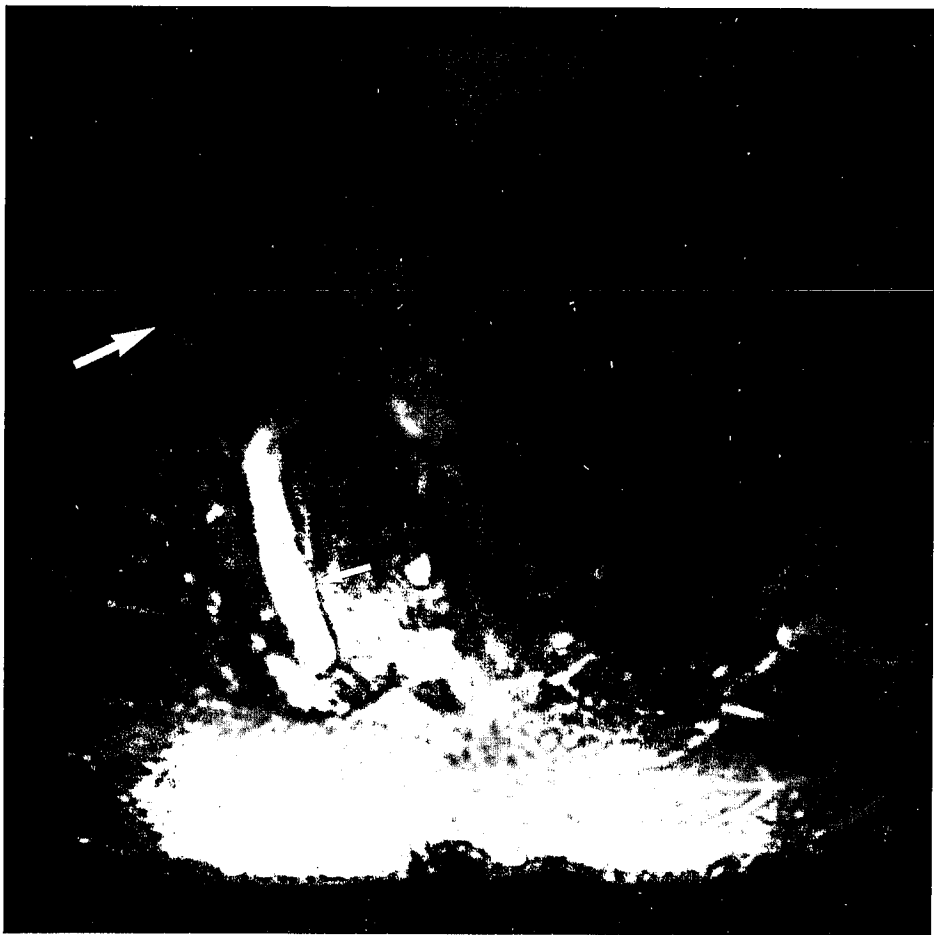

Figure 1. Axial T1 weighted fat suppressed image of the right SI joint and adjacent iliopsoas abscesses after gadolinium injection. Enhancement of the SI joint (small white arrow) is indicative of chronic sacroiliitis and superimposed osteomyelitis. The SI joint is widened and adjacent sacral (medial) and iliac (lateral) cortex is destroyed. On other caudad images (not shown) fluid is seen extending posterolaterally through the sciatic notch into the thigh. A large complex fluid collection (abscess) is seen in the iliopsoas muscle (large white arrow). On other cranial images (not shown) SI joint infection is seen to connect with the iliopsoas abscess 2 × 3 × 6 cm in extent and paraspinal abscesses medially.

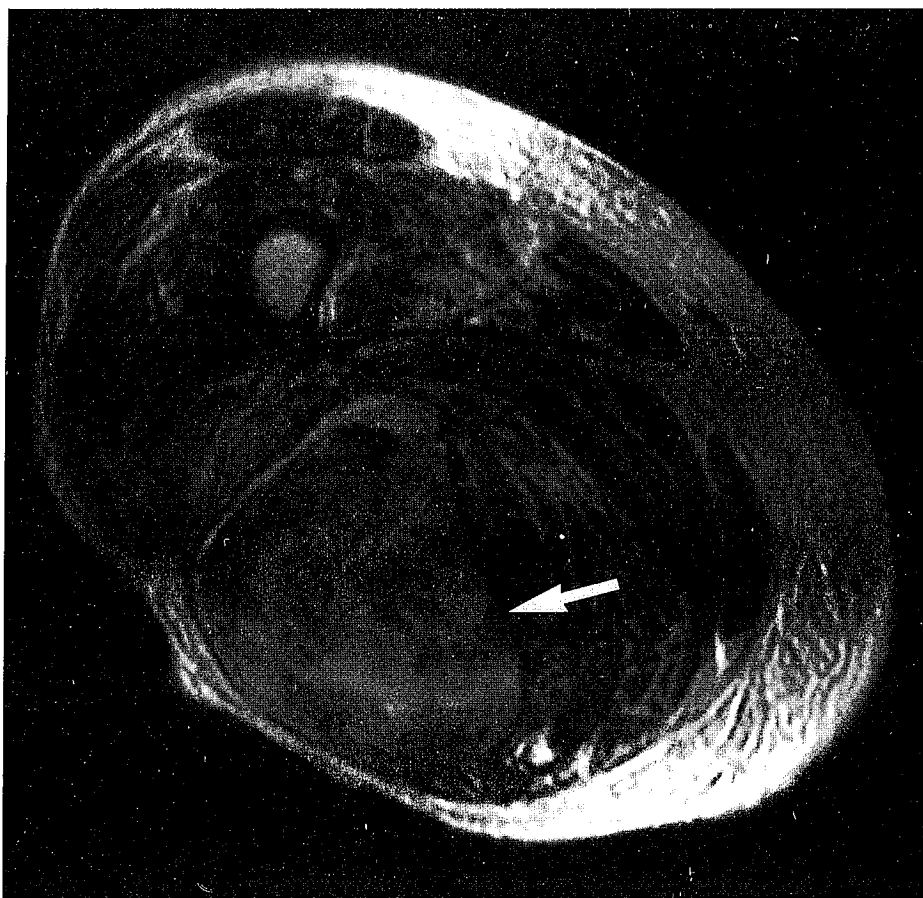


Figure 2. Axial T2 weighted image of biceps femoris abscess/hematoma (large white arrow). This complex fluid collection is 8 × 8 cm in diameter and extends 32 cm long from the insertion on the ischial tuberosity down to the knee.

for infectious sacroiliitis^{3,8}. A recent review of 166 cases reported in the literature identified iv drug use, trauma, and a focus of infection elsewhere as predisposing factors⁹. As with infectious arthritis in general, the most common causative organisms are *S. aureus* and streptococcus species. Prolonged antibiotic treatment for 4–6 weeks is recommended, with surgery generally reserved for abscess formation, as in the present case^{5,8}. Of note, spread of infection from the SI joint to the psoas and iliacus is unusual, despite their anatomic proximity, and has been noted in only 3 case reports^{6,8}. One of these reports details contiguous spread distally to the lower extremities and proximally to the paraspinals, as in our patient⁸. However, these reports were in non-RA patients. In contrast, RA may be a risk factor for isolated psoas abscess⁹.

The reason for such an extensive infection in our patient without previous trauma or surgery is likely his relatively immunocompromised state secondary to RA and its therapy. Infection is a well recognized complication of RA¹⁰, with the higher incidence of pyarthrosis presumably due to abnormal joint architecture and the increased risk of systemic infection blamed on defects in the immune system¹¹. Several investigators have described defective polymorphonuclear cell phagocytic activity in RA patients^{12,13} in addition to the well known effects of glucocorticoids. Our patient's recurrent *S. aureus* infections and presentation with multifocal infection is in keeping with the idea that patients with RA may be particularly susceptible to infections with *S. aureus*. Colonization with *S. aureus* may be higher in RA patients¹⁴, and transient bacteremia may be more common, due to skin breakdown. Once bacteremia ensues *S. aureus* has a particular propensity to cause metastatic infection in bones and joints, particularly in patients with impaired immune function and abnormal joint architecture.

In summary, our case illustrates the rare occurrence of SI joint septic arthritis with contiguous and hematogenous spread to multiple locations in a patient with RA. The case serves as a reminder of the increased susceptibility of RA patients to pyarthrosis and the possibility of infectious spread from the SI joint.

University of Rochester Medical Center,
Rochester, NY, USA.

Jennifer H. Anolik, MD, PhD;
Katherine Wildy, MD;
Susan E. Cohn, MD.
John D. Marquardt, MD;
Saara Totterman, MD;
Samuel H. Zwilllich, MD.

REFERENCES

1. Goldenberg DL. Infectious arthritis complicating rheumatoid arthritis and other chronic rheumatic disorders. *Arthritis Rheum* 1989;32:496-501.
2. Gardner GC, Weisman MJ. Pyarthrosis in patients with rheumatoid arthritis: a report of 13 cases and a review of the literature from the past 40 years. *Am J Med* 1990;88:503-11.
3. Ickovitz JM, Leek JC, Robbins DL. Pyogenic sacroiliitis. *J Rheumatol* 1981;8:157-60.
4. Oka M, Mottonen T. Septic sacroiliitis. *J Rheumatol* 1983;10:475-8.
5. Vyskocil JJ, McIlroy MA, Brennan TA, Wilson FM. Pyogenic infection of the sacroiliac joint. *Medicine* 1991;70:188-97.
6. Simons GW, Sty JR, Starshak RR. Iliacus abscess. *Clin Orthop Rel Res* 1984;183:61-3.

7. Assalia A, Volpin G, Hashmonai M, Angel A, Stein H, Schein M. Psoas muscle abscess associated with pyogenic sacroiliitis. *Eur J Surg* 1996;162:415-7.
8. Dangles CJ. Two unusual presentations of pyogenic sacroiliitis. *Orthop Rev* 1987;16:77-80.
9. Isdale AH, Foley-Nolan DF, Butt WP, Birkenhead D, Wright V. Psoas abscess in rheumatoid arthritis — an inperspicuous diagnosis. *Br J Rheumatol* 1994;33:853-8.
10. Wolfe F, Mitchell DM, Sibley JT, et al. The mortality of rheumatoid arthritis. *Arthritis Rheum* 1994;37:481-94.
11. van Albada-kuipers GA, Linthorst J, Peeters EAJ, et al. Frequency of infection among patients with rheumatoid arthritis versus patients with osteoarthritis or soft tissue rheumatism. *Arthritis Rheum* 1988;31:667-71.
12. Breedveld FC, Lafeber GJM, van den Barselaar MT, van Dissel JT, Leijh PJ. Phagocytosis and intracellular killing of *S. aureus* by polymorphonuclear cells from synovial fluid of patients with rheumatoid arthritis. *Arthritis Rheum* 1986;29:166-73.
13. Van Riessen D, Daha MR, Smeets TJ, Breedveld FC. The influence of synovial fibroblasts on the phagocytosis of staphylococcus by polymorphonuclear cells. *Rheumatol Int* 1992;12:1-5.
14. Jacobson JJ, Patel B, Asher G, Woolliscroft JO, Sachaber D. Oral staphylococcus in older subjects with rheumatoid arthritis. *J Am Geriatr Soc* 1997;45:590-3.

Systemic Onset Juvenile Idiopathic Arthritis: A Retrospective Study of 80 Consecutive Patients Followed for 10 Years

To the Editor:

We read with interest the thoughtful and comprehensive study by Lomater, *et al*¹. We are impressed with the duration of followup and appreciate the enormous work required in performing a retrospective study covering such a long period. There are a few issues that remain unclear in the publication that, if resolved, would greatly aid other rheumatologists in interpreting the results in relation to their own clinical situation. The first relates to a potential greater loss to followup in those systemic JA patients (using the terminology of the authors) who demonstrated a monocyclic course. Since the requirement was for at least 3 years of followup for inclusion in the study, there is a potential for those with a very limited duration of active disease, for example 6 months or less, to not continue to be followed in a rheumatology referral center and thus not be included in the study. Loss of such patients in the study population would result in a bias of the results toward seeing more severe outcomes and underestimating the rate of spontaneous remission. It would be helpful if the authors would report the mean duration of followup for each of the 3 disease course types described in the article — monocyclic, intermittent, and persistent. If the duration of followup were similar for all 3 subtypes, it would support the fact of comprehensive longterm followup of all systemic JA patients at this institution independent of disease severity. Another issue that was unclear for us was the definition of “systemic phase.” Did the authors actually require patients to demonstrate all of the following clinical manifestations to be considered to be in active systemic phase of the JA: fever, maculopapular rash, pericarditis, hepatomegaly, splenomegaly, and polyarthritis? If it was required that the patients have all these manifestations, then this set a very high standard to be considered to be in the systemic phase. In the definition of “cumulative duration of active periods in months,” did the authors use the EULAR definition of active disease that they include in the article? This definition of “active disease” requires an *increasing* number of joints irrespective of treatment. If strictly applied, this would mean that if a patient increased from 18 to 20 actively inflamed joints over a 3 month period but then continued to have 20 active joints for the next 3 months, the patient would be considered to have “active” arthritis for only the first 3 months. If this is correct, then the definition of “active” disease used in this article is more stringent than most definitions of “active” disease.

These questions are not intended as criticisms but to help us and other

readers better understand the data included in this very well designed, scientifically performed, and important contribution to our understanding of systemic juvenile arthritis.

Children’s Hospital Medical Center,
University of Cincinnati,
Cincinnati, Ohio, USA.

Daniel J. Lovell, MD, MPH;
Murray Passo, MD;
Edward Giannini, MSc, DrPH;
Hermine Brunner, MD, MSc.

REFERENCE

1. Lomater C, Gerloni V, Gattinara M, Mazzotti J, Cimaz R, Fantini F. Systemic onset juvenile idiopathic arthritis: a retrospective study of 80 consecutive patients followed for 10 years. *J Rheumatol* 2000;27:491–6.

Autoantibodies to CTLA-4 Enhance T Cell Proliferation

To the Editor:

Production of various autoantibodies is a characteristic abnormality in systemic autoimmune diseases such as systemic lupus erythematosus (SLE). Their biological effects as well as diagnostic importance are of great interest. So far, antinuclear antibodies (ANA), which are among the most frequently detected autoantibodies, have been widely studied and some of them, like the anti-Sm antibody (Ab) and anti-topoisomerase I, have been established as diagnostic markers. Despite the frequent detection of ANA, with the exception of a small proportion, they are not thought to be directly responsible for clinical symptoms. Other types of frequently detected autoantibodies include the anti-lymphocyte Ab (ALA). ALA are poorly understood; indeed, only a small number of ALA targets, such as HLA class I molecules¹ and CD45², have been identified. Since ALA may be able to modulate lymphocyte function through binding to their target molecules on the cell surface, it is important to investigate the functional effects of ALA.

We reported that autoantibodies to CTLA-4 (CD152) were detected in more than 10% of patients with systemic autoimmune diseases³. CTLA-4, belonging to the T cell costimulatory system, is a negative regulator of T cell activation. Abnormalities of CTLA-4 could be involved in autoimmune disorders, as suggested by the following findings: (1) autoimmune-like lymphocyte infiltration into various organs is seen in CTLA-4 deficient mice^{4,5}; (2) experimental autoimmune encephalomyelitis is exacerbated by administration of anti-CTLA-4 monoclonal Ab in mice⁶; (3) skewed CTLA-4 gene polymorphism was reported in human autoimmune diseases^{7,8}. Thus, autoantibodies to CTLA-4 could be modulators of T cell immunity.

To determine whether autoantibody to CTLA-4 can affect T cell function, we examined the effects of anti-CTLA-4 autoantibody on lymphocyte proliferation in the mixed lymphocyte reaction (MLR). Autoantibodies to CTLA-4 were prepared from sera of 4 patients, one of whom had SLE, one rheumatoid arthritis, and 2 Behçet’s disease. The autoantibodies were purified using affinity columns with recombinant CTLA-4 proteins fused with β-galactosidase (β-gal). As a control, anti-Ro/52 kDa autoantibodies were similarly prepared using recombinant Ro/52 kDa proteins fused with β-gal. Two peripheral blood mononuclear cell samples from different healthy donors were prepared, and one was irradiated and then was mixed with the other (MLR). The purified autoantibodies were added to the MLR, and after incubation for 7 days, proliferation of the lymphocytes was assayed by measuring ³H-thymidine uptake. The results showed that proliferative responses in the MLR were not affected by the addition of anti-Ro/52 kDa autoantibodies at a concentration of 1–50 ng/ml. However, the anti-CTLA-4 autoantibodies enhanced the proliferative responses significantly in a dose dependent manner at concentrations of 25 and 50 ng/ml. All 4 purified anti-CTLA-4 autoantibody samples showed a similar effect on the lymphocytes. A representative result is shown in Figure 1.

Our results indicate that anti-CTLA-4 autoantibodies can block inhibitory signals mediated by CTLA-4 molecules on T cells and thus

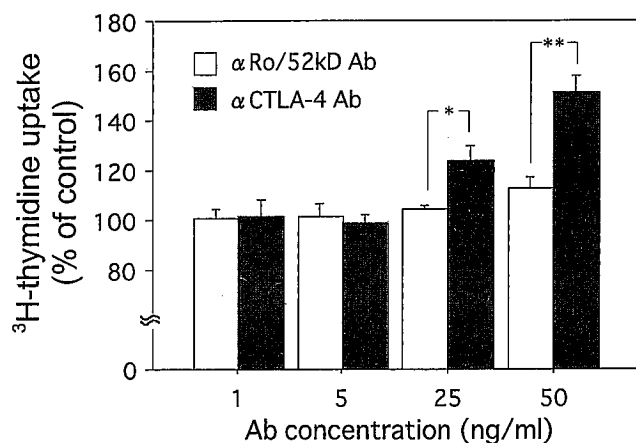


Figure 1. Effects of anti-CTLA-4 autoantibodies on lymphocyte proliferation in the mixed lymphocyte reaction. Proliferative responses of lymphocytes incubated for 7 days with anti-CTLA-4 autoantibodies or anti-Ro/52 kDa autoantibodies assayed by measuring ^3H -thymidine uptake. Results from a representative experiment are shown. * $p < 0.05$, ** $p < 0.01$ by unpaired t test.

enhance the T cell response. This phenomenon may occur in patients with autoimmune diseases *in vivo*, leading to immune disorders linked to abnormally downregulated CTLA-4 signaling. Our findings suggest a new pathway by which anti-lymphocyte antibodies may modulate autoimmune reactions.

Institute of Medical Science, St. Marianna University School of Medicine, Kawasaki; Department of Allergy and Rheumatology, University of Tokyo Graduate School of Medicine, Tokyo, Japan.

Toshihiro Matsui, MD, PhD; Kusuki Nishioka, MD, PhD; Tomohiro Kato, MD, PhD; Kazuhiko Yamamoto, MD, PhD.

Supported in part by a grant-in-aid from the Ministry of Health and Welfare and the Ministry of Education, Science and Culture, Japan, and by the Japan Rheumatism Foundation.

Address reprint requests to Dr. T. Matsui, Rheumatology, Immunology and Genetics Program, Institute of Medical Science, St. Marianna University School of Medicine, 2-16-1, Sugao, Miyamae-ku, Kawasaki, Kanagawa, 216-8512, Japan. E-mail address: tmatsui@marianna-u.ac.jp

REFERENCES

- Propper DJ, Lehney WA, Urbaniak SJ, Catto GR, Macleod AM. Lymphocytotoxins in sera from highly sensitized multiparous dialysis patients: antibody class, relationship with the HLA and with paternal antigens. *Clin Sci* 1991;80:87-93.
- Mimura T, Fernsten P, Jarjour W, Winfield JB. Autoantibodies specific for different isoforms of CD45 in systemic lupus erythematosus. *J Exp Med* 1990;172:653-6.
- Matsui T, Kurokawa M, Kobata T, et al. Autoantibodies to T cell costimulatory molecules in systemic autoimmune diseases. *J Immunol* 1999;162:4328-35.
- Waterhouse P, Penninger JM, Timms E, et al. Lymphoproliferative disorders with early lethality in mice deficient in CTLA-4. *Science* 1995;270:985-8.
- Tivol EA, Borriello F, Schweitzer AN, Lynch WP, Bluestone JA, Sharpe AH. Loss of CTLA-4 leads to massive lymphoproliferation and fetal multiorgan tissue destruction, revealing a critical negative regulatory role of CTLA-4. *Immunity* 1995;3:541-7.
- Karandikar NJ, Vanderlugt CL, Walunas TL, Miller SD, Bluestone JA. CTLA-4: a negative regulator of autoimmune disease. *J Exp Med* 1996;184:783-8.
- Yanagawa T, Hidaka Y, Guimaraes V, Soliman M, DeGroot LJ. CTLA-4 gene polymorphism associated with Graves' disease in a Caucasian population. *J Clin Endocrinol Metab* 1995;80:41-5.
- Donner H, Rau H, Walfish PG, et al. CTLA4 alanine-17 confers genetic susceptibility to Graves' disease and to type 1 diabetes mellitus. *J Clin Endocrinol Metab* 1997;82:143-6.

Adverse Reactions to Rifabutin

To the Editor:

An increasing number of side effects, mainly arthritis and uveitis, have been reported with the combination treatment of rifabutin with clarithromycin, as described by Le Gars, *et al*¹. Rifabutin, a semisynthetic rifamycin derivative, has activity against atypical mycobacteria. Anterior uveitis and vitritis have been described in association with rifabutin therapy in patients with AIDS and AIDS related complex². Also, retinal vascular changes associated with uveitis have earlier been reported³. Vision and ocular changes have returned to normal after 6 to 10 weeks from discontinuation of rifabutin. Drug induced polyarthralgia-arthritis syndrome has been described in up to 19% of the users of rifabutin⁴. Severe neutropenia among healthy volunteer subjects who received rifabutin was described, and administration of rifabutin and clarithromycin concomitantly also caused decrease in platelet counts⁵. Similar adverse events have been described among patients taking the above noted combination treatment⁶. In such a combination rifabutin metabolism is inhibited by clarithromycin via inhibition of the hepatic cytochrome P450 enzyme.

We describe a patient who had oligoarthritis, retinal vasculitis, and neutro- and thrombocytopenia during concomitant treatment of rifabutin, clarithromycin, and ethambutol.

A 48-year-old woman with a history of allergic rhinitis and asthma had had chronic otitis since 1988. After tympanomastectomy in 1993 the infection was quite silent, but flared again in 1998 when *Mycobacterium malmoense* was cultured from the extract of her left ear. Her blood cell count, liver enzyme profile, and creatinine were normal. She was prescribed rifabutin 300 mg/24 h, clarithromycin 1 g/24 h, and ethambutol 1 g/24 h in January 1999. During this treatment her laboratory tests showed leuko- and neutropenia, thrombocytopenia, and anemia. Her leukocytes were $1.8\text{--}3.9 \times 10^9/\text{l}$ and neutrophils $1.1\text{--}1.4 \times 10^9/\text{l}$. Her platelet count was 110,000–145,000 and hemoglobin 110 g/l. In June 1999 she complained of arthralgia and swelling of her ankles. In July she discontinued her therapy because of nausea. Thereafter her joint pain started to resolve, but in the beginning of August she still had arthritis in both talocrural joints. Tests for rheumatoid factor, antinuclear antibody, and antinuclear cytoplasmic antibody were negative. Radiographs of hands and feet were normal. Synovial fluid was transparent and there were only 64 leukocytes/mm³. She also complained of decreased vision. Ophthalmological examination showed retinal vascular changes in both eyes. After discontinuation of rifamycin, joint pain and swelling disappeared in 4 weeks and ophthalmological changes in 2 months. The treatment was continued with clarithromycin 1 g/24 h, ethambutol 1 g/24 h, and rifampicillin, at first 450 mg/24 h and after 3 months 600 mg/24 h. Her blood count has been normal during this treatment.

Gastrointestinal symptoms and pigmentation of skin and urine are common side effects of rifabutin. Anterior uveitis and other ophthalmological adverse reactions are reversed when rifabutin is discontinued, as is the case also with arthritis and arthralgia. The clinical features of our patient fit the description of adverse events associated with rifabutin in the literature. In addition to rheumatological and ophthalmological side effects our patient also showed myelotoxic adverse reactions, which all were reversible after discontinuation of treatment.

Department of Medicine,
Department of Pulmonary Diseases,
Kuopio University Hospital,
Kuopio, Finland.

Oili Kaipainen-Seppänen, MD;
Liisa Hyvärinen, MD.

REFERENCES

1. Le Gars L, Collon T, Picard O, Kaplam G, Berenbaum F. Polyarthralgia-arthritis syndrome induced by low dose rifabutin. *J Rheumatol* 1999;26:1201-2.

2. Siegal FB, Bilbott D, Burger H, et al. Dose-limiting toxicity of rifabutin in AIDS-related complex, syndrome of arthralgia/arthritis. *AIDS* 1990;4:433-41.

3. Arvelo JF, Russack V, Freeman WR. New ophthalmic manifestations of presumed rifabutin-related uveitis. *Ophthalmic Surg Las* 1997;28:321-4.

4. Griffith DE, Brown BA, Girard WM, Wallace RJ Jr. Adverse events associated with high dose rifabutin in macrolide-containing regimens for treatment of *Mycobacterium avium* complex lung disease. *Clin Infect Dis* 1995;21:594-8.

5. Apseloff G, Foulds G, LaBoy-Goral L, Kraut E, Vincent J. Severe neutropenia caused by recommended prophylactic doses of rifabutin. *Lancet* 1996;348:685.

Book Reviews

Autoimmune Rheumatic Disease, 2nd edition

John Morrow, Lee Nelson, Richard Watts, and David Isenberg, editors. New York: Oxford University Press, 1999, 277 pages, price \$75.00 US.

In 11 short chapters autoimmune diseases are summarized. Articles reviewed are relatively recent, most within the last decade. Much credit is given to authors from North America. In the chapter on therapeutics no mention of the efficacy of antimalarial therapy is made, although it is mentioned in chapters on systemic lupus erythematosus and dermatomyositis. It is pleasant to see milestones in the history of each autoimmune disease mentioned at the introduction of each chapter. As well there is a good summary of the immunopathology on each disease along with immunogenetics and animal models. The only section that seems a little disorganized is that on overlap syndromes. Interestingly, MCTD stands for “muddled concept to be discarded” in that chapter.

Vasculitis in greater detail needs to be obtained from larger textbooks. Advances in rheumatology are being made very rapidly, especially in the area of therapeutics. Even at the time of the review, this book is already outdated, despite its recent publication.

Midtown Medical Centre,
Saskatoon, Saskatchewan S7K 0H6, Canada. Janet J. Markland, MD, FRCPC.

Primary Care Rheumatology

Edward D. Harris, Jr, Mark C. Genovese, Editors. Philadelphia: W.B. Saunders Company, 1999, 413 pages, price \$50.00 US.

This book for primary care physicians places most emphasis on the presentation and evaluation of rheumatologic conditions. Its approach is more practical and more patient centered than most texts and it takes a balanced and respectful approach to the primary care-specialist interface. The layout is welcoming and the format a mix of narratives, case examples, figures and tables, and an extensive collection of algorithms.

Topics with most relevance to primary care are well covered, including helping patients to learn to live with arthritis, laboratory testing, spinal pain, soft tissue disorders, foot pain, and protocols for monitoring disease modifying antirheumatic drugs.

Appropriate emphasis is placed on the central role of history and physical examination. Conditions rarely encountered in primary care are well presented but are unobtrusively placed and do not dominate the book. The shift in management of people with inflammatory arthritis toward early referral and early therapy with disease modifying antirheumatic drugs is well explained and the arguments presented are convincing. At the same time, medication toxicities and contraindications are clearly described. The approach to laboratory testing takes account of the pretest probability of specific diseases and provides cautionary lessons about interpreting laboratory tests that were ordered without appropriate clinical indications. Nonpharmacologic therapy is well explained and generally follows the recommendations of current guidelines.

In summary, this book is a very appropriate resource and it can be highly recommended for undergraduate medical students in their clinical years, graduate primary care trainees, and practicing primary care physicians. The editors and authors are to be congratulated for a book that is readable, informative, practical, suitable for different learning styles, and highly relevant to the needs of primary care physicians.

Department of Family and Community Medicine,
University of Toronto,
Arthritis Community Research and Evaluation Unit,
University Health Network,
Toronto, Ontario M5G 2M9,
Canada
Richard H. Glazier, MD, MPH, CCFP, FCFP.