

# Antimelanoma Differentiation-Associated Gene 5 Antibody–Positive Interstitial Lung Disease After Vaccination With COVID-19 mRNA Vaccines

Takamasa Kitajima<sup>1</sup>, Atsushi Funauichi<sup>1</sup>, Toshiki Nakajima<sup>2</sup>, Satoshi Marumo<sup>1</sup>, Yoshitaka Imura<sup>2</sup>, and Motonari Fukui<sup>1</sup>

**ABSTRACT. Objective.** Melanoma differentiation-associated gene 5 (MDA5) is a viral RNA sensor induced by SARS-CoV-2. Similarities have been reported between the clinical presentations of coronavirus disease 2019 (COVID-19) pneumonia and anti-MDA5 antibody–positive interstitial lung disease (anti-MDA5-ILD). However, it is unknown whether COVID-19 mRNA vaccines are associated with anti-MDA5-ILD.

**Methods.** We retrospectively reviewed consecutive patients with anti-MDA5-ILD admitted to our hospital between April 2017 and March 2022. In addition, we investigated the clinical presentations of patients who developed anti-MDA5-ILD after vaccination with COVID-19 mRNA vaccines. We also examined the annual number of anti-MDA5-ILD cases before and after the COVID-19 vaccination campaign.

**Results.** Nine patients with anti-MDA5-ILD were seen during the study period, of whom 4 developed anti-MDA5-ILD between August and October 2021, approximately 6 to 12 weeks after vaccination with a COVID-19 mRNA vaccine and a few months after the rapid mRNA COVID-19 vaccination campaign in Japan. None of the 4 patients had evidence of SARS-CoV-2 infection. The difference in the annual number of anti-MDA5-ILD cases before vs after the COVID-19 vaccination campaign ( $1.25 \pm 0.96$  cases/yr vs 4.0 cases/yr) was not statistically significant ( $P = 0.08$ ).

**Conclusion.** We encountered 4 cases of anti-MDA5-ILD after COVID-19 vaccination. Further large population studies are needed to clarify the relationship between anti-MDA5-ILD and vaccination with COVID-19 mRNA vaccines.

**Key Indexing Terms:** antimelanoma differentiation-associated gene 5, dermatomyositis, interstitial lung disease, COVID-19, mRNA vaccine, SARS-CoV-2

Melanoma differentiation-associated gene 5 (MDA5) is a viral RNA sensor, which can be induced by SARS-CoV-2.<sup>1</sup> Patients with interstitial lung disease (ILD) and antibodies against MDA5 are recognized as having anti-MDA5 antibody–positive ILD (anti-MDA5-ILD), which has a high mortality rate due to rapidly progressive ILD (RP-ILD).<sup>2</sup> It typically manifests clinically as amyopathic dermatomyositis (DM), with a DM-specific rash but less muscular involvement than with classic DM.<sup>2</sup> Hyperferritinemia and elevated Krebs von den Lungen 6 (KL-6) levels are also observed, and significant radiological features are the presence of ground-glass attenuation

(GGA) and consolidation in the lower lobes of the lungs on high-resolution computed tomography (HRCT).<sup>3</sup> Notably, these clinical features are similar to coronavirus disease 2019 (COVID-19) pneumonia.<sup>3</sup> Further, the serum cytokine profiles are also similar, and serum levels of interleukin (IL)-6, IL-8, and IL-10 were elevated in patients with severe COVID-19 and anti-MDA5-ILD.<sup>3,4</sup>

In the COVID-19 pandemic, mRNA vaccines have been approved for protection against COVID-19,<sup>5,6</sup> and more than 1.7 billion doses have already been administered worldwide. In Japan, mRNA vaccines are recommended. On April 1, 2021, less than 0.01% of the population had received a single dose of vaccine; however, by October 31, 2021, 77.3% of the population had received at least 1 dose.

Four cases of anti-MDA5-ILD were diagnosed at our hospital in September and October 2021, which is a higher incidence than normal for our hospital. We speculated that this might be related to COVID-19 vaccination. Here, we describe the clinical course of the 4 cases and their association with COVID-19 vaccination. We also describe the annual positive rate of the anti-MDA5 antibody test and the annual number of cases of anti-MDA5-ILD at our hospital before and after the COVID-19 vaccination campaign.

<sup>1</sup>T. Kitajima, MD, A. Funauichi, MD, S. Marumo, MD, PhD, M. Fukui, MD, PhD, Respiratory Disease Center, Kitano Hospital, Tazuke Kofukai Medical Research Institute; <sup>2</sup>T. Nakajima, MD, PhD, Y. Imura, MD, PhD, Department of Clinical Immunology and Rheumatology, Kitano Hospital, Tazuke Kofukai Medical Research Institute, Osaka, Japan.

The authors declare no conflicts of interest relevant to this article.

Address correspondence to Dr. T. Kitajima, Respiratory Disease Center, Tazuke Kofukai Medical Research Institute, Kitano Hospital, 2-4-20 Ohgimachi, Kita-ku, Osaka 530-8480, Japan.

Email: m-kitajima@kitano-hp.or.jp.

Accepted for publication June 2, 2022.

## METHODS

We retrospectively reviewed consecutive patients with anti-MDA5-ILD admitted to our hospital between April 2017 and March 2022. We also examined the total number of anti-MDA5 tests conducted in our hospital between April 2017 and March 2022. Anti-MDA5-ILD was defined as positivity for anti-MDA5 antibody and typical shadows consistent with ILD on HRCT, with radiological features such as reticular opacities, GGA, or a honeycomb appearance. Anti-MDA5 antibody levels were measured using MESACU anti-MDA5 test (Medical & Biological Laboratories Co. Ltd). KL-6 was measured by latex coagulating nephelometry. SARS-CoV-2 testing was performed using BioFire FilmArray System (BioFire Diagnostics) PCR, Loopamp Viral RNA Extraction Kit (Eiken Chemical Co., Ltd), SARS-CoV-2 real-time loop-mediated isothermal amplification (RT-LAMP) assay, and Lumipulse G SARS-CoV-2 Ag (Fujirebio Inc.) rapid SARS-CoV-2 antigen test.

An independent-samples *t* test was used to compare the annual number of anti-MDA5-ILD cases before vs after the COVID-19 vaccination campaign. The statistical analysis was performed using IBM SPSS version 25 for Windows (IBM Corp). A 2-sided *P* value < 0.05 was considered statistically significant.

The study conforms to the Declaration of Helsinki and was approved by the Kitano Hospital Medical Research Institute Ethics Committee (approval no. P220300400). Consent was obtained from all patients involved.

## RESULTS

Nine patients had anti-MDA5-ILD during the 6-year (72-month) study period. Four of 9 patients were diagnosed with anti-MDA5-ILD in the 3-month period from August to October 2021, a few months after the rapid vaccination campaign began in Japan (Figure). All 4 patients received a first dose of COVID-19 mRNA vaccine approximately 6 to 12 weeks prior to the onset of anti-MDA5-ILD, and none of them had evidence of SARS-CoV-2 infection. The key demographic and

clinical characteristics and laboratory results of the 4 patients who presented with anti-MDA5-ILD from August to October 2021 are shown (Table).

*Patient 1.* Patient 1 was a 71-year-old woman who was vaccinated with the mRNA-1273 vaccine (Moderna) late June and late July 2021. She developed shortness of breath in early September and a dry cough in early October. The patient visited our hospital mid-October. On examination, she had a DM-specific rash (Gottron papules, Gottron sign, and nailfold abnormalities), and her peripheral oxygen saturation was 97% breathing 2 L/min of oxygen by nasal cannula. Laboratory tests revealed elevated ferritin and KL-6 levels of 525 ng/mL (normal: 22-322 ng/mL) and 489 U/mL (normal: 105.3-401.2 U/mL), respectively, and a normal creatine kinase (CK) level of 63 U/L (normal in females: 41-153 U/L). HRCT showed bilateral GGA and consolidations in the lower lobes of her lungs. A SARS-CoV-2 RT-LAMP assay and SARS-CoV-2 antigen test were negative, and PCR tests for respiratory viruses including SARS-CoV-2, performed 24 hours after SARS-CoV-2 antigen testing, were also negative. The anti-MDA5 antibody titer was high (1400 index, normal: < 32 index). Based on these findings, the patient was diagnosed with anti-MDA5-ILD, and was treated with high-dose glucocorticoids (GCs), tacrolimus, and intravenous (IV) cyclophosphamide (CYC). However, she died on the 174th day of hospitalization.

*Patient 2.* Patient 2 was an 82-year-old man who was vaccinated with the BNT162b2 vaccine (Pfizer-BioNTech) in June and July 2021. He developed a dry cough in late August, followed by shortness of breath on exertion that appeared mid-September. He visited our hospital in late September. On examination, he had a DM-specific rash (Gottron papules,

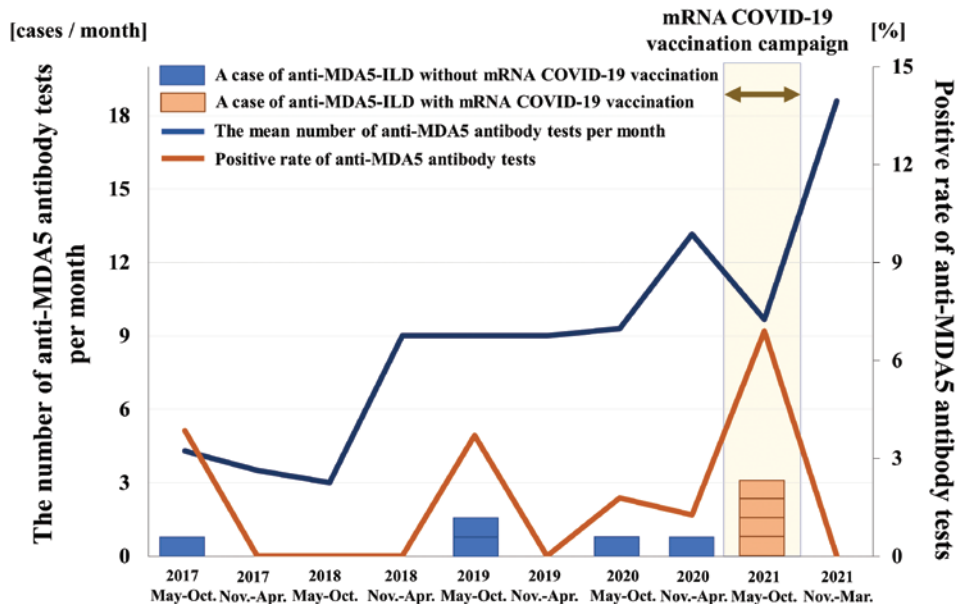


Figure. The time course of the number of anti-MDA5-ILD cases, the number of anti-MDA5 antibody tests, and positivity rate of anti-MDA5 antibody tests. The anti-MDA5 antibody test positivity rate was higher directly after the COVID-19 vaccination campaign. Anti-MDA5: anti-melanoma differentiation-associated gene 5; anti-MDA5-ILD: antimelanoma differentiation-associated gene 5 antibody-positive interstitial lung disease; COVID-19: coronavirus disease 2019.

Table. Characteristics of the 4 patients who developed anti-MDA5-ILD after vaccination with a COVID-19 mRNA vaccine.

	Patient 1	Patient 2	Patient 3	Patient 4
Age (yrs), sex	71, F	82, M	68, M	59, F
COVID-19 vaccine	mRNA-1273	BNT162b2	BNT162b2	BNT162b2
Time to anti-MDA5-ILD onset <sup>a</sup> , weeks	12	8	6	6
DM-specific signs	Gottron papules, Gottron sign, nailfold abnormalities	Gottron papules, Gottron sign, nailfold abnormalities	Gottron papules, nailfold abnormalities	Gottron papules, Gottron sign, nailfold abnormalities
ALT <sup>b</sup> , U/L	19	38	19	18
LDH <sup>c</sup> , U/L	387	644	304	342
CK <sup>d</sup> , U/L	63	451	40	63
CRP <sup>e</sup> , mg/dL	8.08	8.07	1.82	5.84
KL-6 <sup>f</sup> , U/mL	489	1394	4224	618
Ferritin <sup>g</sup> , ng/mL	525	406	2008	503
ANA <sup>h</sup>	1: < 40	1:80	1: < 40	1: < 40
Anti-MDA5 antibody <sup>i</sup>	1400	1550	6300	2150
Treatment	High-dose GC, tacrolimus, IV CYC	High-dose GC, tacrolimus	High-dose GC, tacrolimus, IV CYC, tofacitinib, plasma exchange	High-dose GCs, tacrolimus, IV CYC
Outcome	Died	Died	Survived	Survived

<sup>a</sup> Time from first vaccination to onset of anti-MDA5-ILD. <sup>b</sup> Normal ALT: 7-23 U/L. <sup>c</sup> Normal LDH: 124-222 U/L. <sup>d</sup> Normal CK: in females, 41-153 U/L; in males, 59-248 U/L. <sup>e</sup> Normal CRP: 0-0.14 mg/dL. <sup>f</sup> Normal KL-6: 105.3-401.2 U/mL. <sup>g</sup> Normal ferritin: 22-322 ng/mL. <sup>h</sup> Normal ANA: < 40. <sup>i</sup> Normal anti-MDA5 antibody: < 32 index. ALT: alanine aminotransferase; ANA: antinuclear antibody; anti-MDA5-ILD: anti-melanoma differentiation-associated gene 5 antibody-positive interstitial lung disease; CK: creatine kinase; COVID-19: coronavirus disease 2019; CRP: C-reactive protein; DM: dermatomyositis; GC: glucocorticoid; IV CYC: intravenous cyclophosphamide; KL-6: Krebs von den Lungen 6; LDH: lactate dehydrogenase; MDA5: melanoma differentiation-associated gene 5.

Gottron sign, and nailfold abnormalities). His peripheral oxygen saturation was 88% breathing 11 L/min of oxygen with a reservoir mask. Laboratory tests revealed elevated ferritin, KL-6, and CK levels of 406 ng/mL, 1394 U/mL, and 451 U/L, respectively. HRCT showed GGA and consolidation in the lower lobes of both lungs. A SARS-CoV-2 RT-LAMP assay and SARS-CoV-2 antigen test were negative, and PCR tests for respiratory viruses, including SARS-CoV-2, were also all negative. The anti-MDA5 antibody titer was high (1550 index). Based on these findings, the patient was diagnosed with anti-MDA5-ILD. He was treated with high-dose GCs and tacrolimus; however, he died on the 22nd day of hospitalization.

**Patient 3.** Patient 3 was a 68-year-old man who was vaccinated with the BNT162b2 vaccine in July and August 2021. He developed dyspnea in late August and visited our hospital in early September. On examination, he had a DM-specific rash (Gottron papules and nailfold abnormalities). His peripheral oxygen saturation was 95% breathing room air. HRCT showed GGA and consolidations in the lower lobes of both lungs. A SARS-CoV-2 RT-LAMP assay and SARS-CoV-2 antigen test were negative, and PCR tests for respiratory viruses, including SARS-CoV-2, were also negative. Laboratory tests revealed elevated ferritin and KL-6 levels of 2008 ng/mL and 4224 U/mL, respectively, a normal CK level of 40 U/L, and a high anti-MDA5 antibody titer (6300 index). Based on these findings, the patient was diagnosed with anti-MDA5-ILD. He was treated with high-dose GCs, tacrolimus, IV CYC, tofacitinib, and plasma exchange, and was transferred to a rehabilitation hospital on the 182nd day of hospitalization.

**Patient 4.** Patient 4 was a 59-year-old woman who was vaccinated with the BNT162b2 vaccine in early August and early September 2021. She developed dyspnea and visited our hospital mid-September. On examination, she had a DM-specific rash (Gottron papules, Gottron sign, and nailfold abnormalities). Her peripheral oxygen saturation was 88% breathing room air. HRCT showed bilateral GGA and consolidation in the lower lobes of both lungs. A SARS-CoV-2 RT-LAMP assay and SARS-CoV-2 antigen test were negative, and PCR tests for respiratory viruses, including SARS-CoV-2, performed 24 hours after SARS-CoV-2 antigen testing, were also negative. Laboratory tests revealed elevated ferritin, KL-6, and CK levels of 503 ng/mL, 618 U/mL, and 63 U/L, respectively, and a high anti-MDA5 antibody titer (2150 index). Based on these findings, the patient was diagnosed with anti-MDA5-ILD. She was treated with high-dose GCs, tacrolimus, and IV CYC, and was discharged from our hospital on the 82nd day of hospitalization. Notably, the patient developed Gottron papules before her first vaccination in early August 2021.

*Comparison of the annual number of cases of anti-MDA5-ILD before and after the COVID-19 vaccination campaign.* A total of 522 anti-MDA5 antibody tests were performed in our hospital from April 2017 to March 2022. There was no significant difference in the annual positivity rate of the anti-MDA5 antibody test (0.09% ± 0.09% vs. 0.25%,  $P = 0.21$ ), or the annual mean number of anti-MDA5-ILD cases diagnosed (1.25 ± 0.96 cases/yr vs 4.0 cases/year,  $P = 0.08$ ), before and after the COVID-19 vaccination campaign.

## DISCUSSION

We report a cluster of 4 cases of anti-MDA5-ILD that occurred in August and October 2021, a few months after the COVID-19 vaccination campaign in Japan. All 4 patients developed anti-MDA5-ILD approximately 6 to 12 weeks after the first COVID-19 vaccination, without SARS-CoV-2 infection. Although the increase in the incidence of anti-MDA5-ILD at our hospital before and after the COVID-19 vaccination campaign was not statistically significant, this case cluster suggests that attention should be paid to a possible increase in the incidence of anti-MDA5-ILD associated with COVID-19 mRNA vaccinations.

MDA5 is a retinoic acid-inducible gene I-like receptor that functions as a key protein sensor of viral RNA.<sup>2</sup> Picornaviruses, such as hepatitis A virus, coxsackie B virus, enterovirus, rhinovirus,<sup>2</sup> and SARS-CoV-2,<sup>1</sup> can activate MDA5, causing it to produce type I interferon (IFN-I) and other inflammatory proteins. MDA5-mediated overactivation of the IFN-I pathway can lead to autoinflammatory diseases.<sup>7</sup> Even before the COVID-19 pandemic, viruses were known to be a major environmental factor affecting the immune system.<sup>8</sup> MDA5 is reported to be involved in the pathogenesis of several autoinflammatory diseases, including systemic lupus erythematosus, multiple sclerosis, and type 1 diabetes.<sup>9-12</sup>

RNA or DNA released by tissue damage can promote autoantibody production.<sup>13</sup> COVID-19 has been found to be associated with at least 15 different types of autoantibodies and at least 10 distinct autoimmune diseases.<sup>8</sup> Autoantigens that have been detected in patients with COVID-19 include antinuclear antibody, lupus anticoagulant, and anti-MDA5 antibody, although the frequency varies between studies.<sup>13-16</sup> In addition, some viral infections might induce the development of anti-MDA5-ILD.<sup>2</sup> COVID-19 can trigger a flare of autoimmune inflammatory disease, including anti-MDA5-ILD.<sup>17</sup> We could not confirm a history of SARS-CoV-2 infection in any of the 4 patients. The presence of antibodies to SARS-CoV-2 prior to the onset of anti-MDA5-ILD could not be evaluated, but none of the 4 patients had a history of symptoms suggestive of SARS-CoV-2 infection (such as fever, olfactory disturbance, taste disorder, or sore throat), or history of a case of COVID-19 in the household preceding the onset of anti-MDA5-ILD. Previous studies have shown that production of autoantibodies is associated with heparin treatment, high C-reactive protein levels, and severe illness owing to conditions other than COVID-19.<sup>14,18</sup> None of our 4 patients had a history of treatment with heparin or a history of severe disease with high levels of systemic inflammation.

In this study, we considered the possibility that COVID-19 mRNA vaccination induced anti-MDA5-ILD. COVID-19 mRNA vaccines are designed based on the mRNA that encodes the SARS-CoV-2 spike protein.<sup>5,6</sup> The genes for MDA5 have been reported to be significantly activated by vaccination with an influenza A (H1N1pdm09) mRNA vaccine.<sup>19</sup> COVID-19 mRNA vaccines may also upregulate MDA5 expression. However, there have been few other reports of COVID-19 mRNA vaccine-induced anti-MDA5-ILD, and few reports of anti-MDA5-ILD in patients with severe COVID-19, to date.

The COVID mRNA vaccines, mRNA-1273 and BNT162b2, do not include any adjuvants.<sup>8</sup> Nevertheless, by stimulating the maturation of dendritic cells and eliciting robust T- and B-cell responses, mRNA vaccines may activate autoreactive lymphocytes.<sup>17</sup> This process, known as intrinsic adjuvant activity, can theoretically reactivate autoimmune disease.<sup>17</sup> In the 4 patients, vaccination with COVID-19 mRNA vaccines may have activated an immune response that led to the development of anti-MDA5-ILD. Moreover, a combination of genetic predisposition and a hyperstimulated state of the immune system, including an uncontrolled response to infection, may trigger an autoimmune response.<sup>8,17</sup> Genetic factors are thought to contribute to the high incidence of anti-MDA5-ILD in East Asia.<sup>2</sup> Therefore, our 4 patients may have been genetically predisposed. In the present study, the increase in the annual number of anti-MDA5-ILD cases before vs after the national COVID-19 vaccination campaign was not statistically significant. Further large population studies are needed to evaluate the relationship between anti-MDA5-ILD and COVID-19 mRNA vaccinations.

COVID-19 mRNA vaccines are strongly recommended because of their effectiveness at preventing COVID-19.<sup>5,6</sup> In addition, booster vaccination has been approved worldwide because of the emergence of the B.1.1.529 (Omicron) variant and reduced protection provided by COVID-19 vaccines.<sup>20</sup> Therefore, the incidence of anti-MDA5-ILD should be carefully monitored for a possible increase, especially in Japan, where many people are genetically predisposed to anti-MDA5-ILD.<sup>2</sup>

This study has several limitations. First, we do not have data on the anti-MDA5 antibody status of the 4 patients before they developed MDA5-ILD. Therefore, it is unclear whether patients with preexisting MDA5 antibodies developed anti-MDA5-ILD as a result of COVID-19 vaccination, or whether the COVID-19 mRNA vaccines induced the production of MDA5 antibodies and anti-MDA5-ILD. However, patient 4 had a DM-specific rash before COVID-19 mRNA vaccination. Hence, the COVID-19 mRNA vaccine may have led latent DM to progress to anti-MDA5-ILD in this patient.

Second, the difference in the annual anti-MDA5 test positivity rate before and after the COVID-19 vaccination campaign was not statistically significant. There were no clinical studies of MDA5-ILD and anti-MDA5 antibodies conducted at our hospital during the study period. Therefore, the patients who were tested for anti-MDA5 antibodies were considered to have clinically suspected DM or ILD. Since the onset of the COVID-19 pandemic, anti-MDA5 tests may have been evaluated more frequently because of the clinical similarity of anti-MDA5-ILD to COVID-19.<sup>21</sup> As a result, the annual positivity rate of anti-MDA5 tests could be expected to be lower during the COVID-19 pandemic. On the other hand, it is possible that the increase of anti-MDA5 testing led to increased detection of potential cases of anti-MDA5-ILD. However, the prevalence of anti-MDA5-ILD is much lower than that of COVID-19. Therefore, the annual positivity rate of anti-MDA5 antibody tests may have been reduced by the increasing number of anti-MDA5 tests performed.

In conclusion, we report 4 cases of anti-MDA5-ILD with onset soon after COVID-19 mRNA vaccination. Ongoing monitoring of COVID-19 mRNA vaccine-related anti-MDA5-ILD is needed to determine whether COVID-19 mRNA vaccines play a causal role.

## REFERENCES

1. Yin X, Riva L, Pu Y, et al. MDA5 governs the innate immune response to SARS-CoV-2 in lung epithelial cells. *Cell Rep* 2021;34:108628.
2. Wu W, Guo L, Fu Y, et al. Interstitial lung disease in anti-MDA5 positive dermatomyositis. *Clin Rev Allergy Immunol* 2021; 60:293-304.
3. Giannini M, Ohana M, Nespola B, Zanframundo G, Geny B, Meyer A. Similarities between COVID-19 and anti-MDA5 syndrome: what can we learn for better care? *Eur Respir J* 2020;56:2001618.
4. Kawasumi H, Gono T, Kawaguchi Y, et al. IL-6, IL-8, and IL-10 are associated with hyperferritinemia in rapidly progressive interstitial lung disease with polymyositis/dermatomyositis. *Biomed Res Int* 2014;2014:815245.
5. Walsh EE, Frenck RW Jr, Falsey AR, et al. Safety and immunogenicity of two RNA-based Covid-19 vaccine candidates. *N Engl J Med* 2020;383:2439-50.
6. Polack FP, Thomas SJ, Kitchin N, et al. Safety and efficacy of the BNT162b2 mRNA Covid-19 Vaccine. *N Engl J Med* 2020;383:2603-15.
7. Dias AG Jr, Sampaio NG, Rehwinkel J. A balancing act: MDA5 in antiviral immunity and autoinflammation. *Trends Microbiol* 2019;27:75-85.
8. Dotan A, Muller S, Kanduc D, David P, Halpert G, Shoenfeld Y. The SARS-CoV-2 as an instrumental trigger of autoimmunity. *Autoimmun Rev* 2021;20:102792.
9. Sadler AJ. The role of MDA5 in the development of autoimmune disease. *J Leukoc Biol* 2018;103:185-92.
10. Robinson T, Kariuki SN, Franek BS, et al. Autoimmune disease risk variant of IFIH1 is associated with increased sensitivity to IFN- $\alpha$  and serologic autoimmunity in lupus patients. *J Immunol* 2011;187:1298-1303.
11. Martínez A, Santiago JL, Cénit MC, et al. IFIH1-GCA-KCNH7 locus: influence on multiple sclerosis risk. *Eur J Hum Genet* 2008;16:861-4.
12. Nejentsev S, Walker N, Riches D, Egholm M, Todd JA. Rare variants of IFIH1, a gene implicated in antiviral responses, protect against type 1 diabetes. *Science* 2009;324:387-9.
13. Chang SE, Feng A, Meng W, et al. New-onset IgG autoantibodies in hospitalized patients with COVID-19. *Nat Commun* 2021;12:5417.
14. Trahtemberg U, Fritzler MJ. COVID-19-associated autoimmunity as a feature of acute respiratory failure. *Intensive Care Med* 2021;47:801-4.
15. Wang G, Wang Q, Wang Y, et al. Presence of anti-MDA5 antibody and its value for the clinical assessment in patients with COVID-19: a retrospective cohort study. *Front Immunol* 2021;12:791348.
16. Gazzaruso C, Carlo Stella N, Mariani G, et al. High prevalence of antinuclear antibodies and lupus anticoagulant in patients hospitalized for SARS-CoV2 pneumonia. *Clin Rheumatol* 2020;39:2095-7.
17. Velikova T, Georgiev T. SARS-CoV-2 vaccines and autoimmune diseases amidst the COVID-19 crisis. *Rheumatol Int* 2021; 41:509-18.
18. Damoiseaux J, Dotan A, Fritzler MJ, et al. Autoantibodies and SARS-CoV2 infection: the spectrum from association to clinical implication: report of the 15th Dresden symposium on autoantibodies. *Autoimmun Rev* 2022;21:103012.
19. Edwards DK, Jasny E, Yoon H, et al. Adjuvant effects of a sequence-engineered mRNA vaccine: translational profiling demonstrates similar human and murine innate response. *J Transl Med* 2017;15:1.
20. Shrotri M, Navaratnam AMD, Nguyen V, et al; Virus Watch Collaborative. Spike-antibody waning after second dose of BNT162b2 or ChAdOx1. *Lancet* 2021;398:385-7.
21. Hayano S, Tokunaga K, Imamura Y, Oshikawa H. Dermatomyositis-related interstitial lung disease mimicking COVID-19 pneumonia. *Cleve Clin J Med* 2021;88:484-6.