

The Role of Sural Nerve Biopsy in the Diagnosis of Vasculitis

Karl Gisslander¹ , Lars B. Dahlin² , Rona Smith³ , David Jayne³ , Dominic G. O'Donovan⁴,
and Aladdin J. Mohammad⁵ 

ABSTRACT. *Objective.* The diagnostic yield of sural nerve biopsy (SNB) in vasculitis is uncertain. Our aim was to document relevant characteristics of patients undergoing SNB in the investigation of vasculitis; determine the diagnostic yield; relate positive biopsy findings to patient demographic, laboratory, and clinical variables; and to calculate the rate of surgical complications.

Methods. Patients with suspected vasculitis that underwent SNB as part of diagnostic evaluation at academic medical centers in Sweden and the United Kingdom were identified by searching local pathology databases and clinic registers. A structured review of medical case records and pathology reports was conducted. Histological findings were categorized as definite, probable, or no vasculitis in accordance with the 2015 Brighton Collaboration reinterpretation and update of the Peripheral Nerve Society guidelines for vasculitic neuropathy. Definite and probable findings were considered positive for vasculitis.

Results. Ninety-one patients that underwent SNB were identified (45% female). Forty (44%) patients showed histological evidence of vasculitis: 14 definite and 26 probable. A concomitant muscle biopsy conducted in 10 patients did not contribute to the diagnostic yield. Positive antineutrophil cytoplasmic antibody test, organ involvement other than the nervous system, and a longer biopsy sample were associated with a positive biopsy. The reported surgical complication rate was 15%.

Conclusion. SNB of sufficient length is a useful procedure to confirm a diagnosis of vasculitis.

Key Indexing Terms: antineutrophil cytoplasmic antibodies, biopsy, neurologic manifestations, vasculitis

Vasculitis of the peripheral nerves is a disorder characterized by inflammation of the vasa nervorum leading to ischemic damage to the affected nerve trunk.¹ It may occur as part of a systemic disorder, most commonly antineutrophil cytoplasmic antibody (ANCA)-associated vasculitis (AAV) or polyarteritis nodosa (PAN), or as a disorder restricted to the peripheral nervous system, such as single organ vasculitis or nonsystemic vasculitic neuropathy.²⁻⁴

There are no pathognomonic signs to confirm vasculitis. Clinical findings and laboratory/serology tests may provide guidance, but the diagnosis can be confirmed only by histology of an affected organ. The typical clinical manifestation of

peripheral nerve vasculitis is acute onset of painful asymmetric sensorimotor neuropathy predominantly affecting a lower limb (mononeuritis multiplex), but clinical manifestations may vary.⁴ Clinical investigations in suspected cases of vasculitis include laboratory tests, medical imaging, and electrophysiological evaluation.

As in other organs affected by vasculitis, histological confirmation of active vasculitis is of high diagnostic value in suspected peripheral nerve vasculitis. Therefore, biopsy of an affected nerve is usually required. Confirmation of vasculitis is essential, as therapy includes immunosuppression with cytotoxic agents, biologics, and high doses of glucocorticoids (GCs), bringing associated risks of treatment toxicity.

The recommended nerve for biopsy varies among clinical centers and published reports.⁵⁻⁹ The biopsy specimen should preferably be obtained from a nerve identified as affected in the clinical or electrophysiological evaluation.¹⁰ This includes the superficial radial nerve, the dorsal cutaneous branch of the ulnar nerve, and the superficial peroneal nerve. However, the most commonly biopsied nerve is the sural nerve of the posterolateral lower leg.

The results of organ biopsy can be affected by aspects of sampling as well as length and representativeness of the collected specimen. As vasculitic lesions are distributed in a skip pattern along blood vessels, negative biopsies are common, even in the context of evident systemic disease. The estimated mean sensitivity of nerve biopsy in systemic vasculitis is 50%.⁴ The diagnostic yield of nerve biopsy in suspected vasculitis is uncertain, and published reports vary.^{5,9,11,12}

This study was supported by grants from the Swedish Research Council (Vetenskapsrådet: 2019-01655), and the Faculty of Medicine, Lund University (ALF-medel).

¹K. Gisslander, MSc, Department of Rheumatology, Lund University, Lund, Sweden; ²L.B. Dahlin, MD, PhD, Department of Translational Medicine - Hand Surgery, Lund University, Malmö, Sweden; ³R. Smith, MD, PhD, D. Jayne, MD, PhD, Department of Medicine, Vasculitis and Lupus Research Group, University of Cambridge, Cambridge, UK; ⁴D.G. O'Donovan, MD, Department of Neuropathology, Addenbrooke's Hospital, Cambridge University Hospitals NHS Foundation Trust, Cambridge, UK;

⁵A.J. Mohammad, MD, PhD, Department of Rheumatology, Lund University, Lund, Sweden, and Department of Medicine, Vasculitis and Lupus Research Group, University of Cambridge, Cambridge, UK.

The authors declare no conflicts of interest related to this article.

Address correspondence to K. Gisslander, Department of Rheumatology, Department of Medicine, Lund University, 221 85 Lund, Sweden.

Email: karl.gisslander@med.lu.se.

Accepted for publication May 17, 2022.

Peripheral nerve biopsies are not without risk. Postsurgical sensory deficit is seen in a majority of patients, depending on the extent of preexisting neuropathy.^{13,14} Other less frequent adverse effects and sequelae include persistent postoperative pain, paresthesia, dysesthesia, and cold sensitivity.¹³⁻¹⁵ Surgical complications such as wound infection, wound dehiscence, delayed healing, and hematoma also occur rarely.^{14,15}

In this study, we aimed to (1) record relevant characteristics of patients who underwent sural nerve biopsy (SNB) in conjunction with investigation for vasculitis at 2 academic medical centers; (2) estimate SNB diagnostic yield; (3) determine if there are differences between positive and negative biopsies regarding patient demographic, laboratory, and clinical variables; and (4) calculate the surgical procedure complication rate.

METHODS

Setting. A retrospective cohort study was conducted at Skåne University Hospital in Lund-Malmö, Sweden, and Addenbrooke's Hospital in Cambridge, United Kingdom.

Patients. Patients that underwent peripheral nerve biopsy from 2005 through 2019 in Lund-Malmö, Sweden, were identified by searching the database of the Department of Pathology for the surgical procedure code ACW99, "other surgery of peripheral nerve," using the Swedish Classification of Health Care Measures (KVÅ). Inclusion required a SNB referral based on a suspicion of vasculitis. Patients undergoing SNB at Addenbrooke's Hospital between 2015 and 2019 were identified by searching the database of the Department of Pathology, using SNOMED-CT (Systematized Nomenclature of Medicine – Clinical Terms) "Structure of sural nerve (body structure) 82097001." Cut-off dates were selected to simplify data collection by ensuring data were readily available in electronic records. Each study site generated a list of potentially eligible patients that were reviewed to ascertain eligibility.

Definitions of positive biopsy. Nerve biopsy specimens were processed as standard at the study sites. In order to enhance comparability, pathology results were assessed according to the 2015 Brighton Collaboration reinterpretation and update of the Peripheral Nerve Society guidelines for vasculitic neuropathy (Table 1).^{16,17} Pathology results were specified as definite, probable, or no vasculitis. Patients with biopsy showing either definite or probable vasculitis were combined to form 1 patient group that was considered as having a positive biopsy.

Data collection. A pro forma was designed for data collection. Baseline was defined as the day of the SNB. Laboratory data and clinical characteristics were collected, and results of the electrophysiological evaluation (nerve conduction studies [NCS] and/or electromyography) were recorded. Pathology reports were subjected to a structured review. When in-hospital follow-up information was available in the patient case records, the initiation time and dose of GC and/or immunosuppressive treatment was recorded. ANCA positivity was defined as ELISA positive for proteinase 3 (PR3)-ANCA or myeloperoxidase (MPO)-ANCA. Information concerning surgical complications (wound infection, wound dehiscence, delayed wound healing and/or postsurgical hematoma) was recorded when available. Wound infection was defined as a condition requiring antibiotic treatment.

Statistical analysis. Categorical data are expressed as percentages, with differences tested using the chi-square test or Fisher exact test. Continuous variables are presented as mean and SD or as median and IQR, depending on the normality of distribution as shown by Shapiro-Wilk test. Differences of continuous variables were tested using *t* test or nonparametric Mann-Whitney *U* test. A *P* value of < 0.05 was considered significant. Statistical analysis was performed using IBM SPSS Statistics for Windows, version 25.0 (IBM Corp). The regional ethical review board for southern Sweden

Table 1. Diagnostic criteria for histopathological definite and probable vasculitis.

Definite vasculitis
<p>a. Inflammatory cells in vessel wall (acute or chronic) AND</p> <p>b. Vascular damage – characterized by either:</p> <p>1. Acute vascular damage Any of the following: 1. Fibrinoid necrosis; OR 2. Loss or disruption of endothelium; OR 3. Loss or fragmentation of internal elastic lamina; OR 4. Loss or fragmentation of smooth muscle cells in media; OR 5. Acute thrombosis; OR 6. Vascular or perivascular hemorrhage; OR 7. Leukocytoclasia</p> <p>OR</p> <p>2. Chronic vascular damage with repair Any of the following: 1. Intimal hyperplasia; OR 2. Fibrosis of media; OR 3. Adventitial or periadventitial fibrosis; OR 4. Chronic thrombosis with or without recanalization</p>
Probable vasculitis
<p>a. Nerve biopsy shows changes of primary axonal neuropathy, without significant demyelination AND</p> <p>b. Nerve biopsy shows:</p> <p>1. Perivascular inflammation AND signs of acute or chronic vascular damage (as defined above); OR b. Perivascular OR vascular inflammation AND</p> <p>2. At least one of the following: 1. Vascular deposition of complement, or IgM, or fibrinogen; OR 2. Haemosiderin deposits; OR 3. Asymmetric or multifocal nerve fiber loss or degeneration; OR 4. Prominent active axonal degeneration</p>

Adapted from Hadden et al.¹⁷

approved the study (LU 2015/51) and no informed consent of participants was required to be obtained. In accordance with the UK National Health Service Research Ethics Committee guidelines an ethical approval was not warranted as the study is retrospective and all treatment decisions were made prior to evaluation.

RESULTS

Patients. Of 346 (94 in Cambridge, 252 in Lund-Malmö) identified cases, 91 (34 Lund-Malmö, 57 Cambridge) fulfilled the study criteria and were included in the investigation. (Figure and Table 2). The mean age at the time of biopsy was 58 years (SD 15.02, range 20-84). Fifty (55%) of patients were male. The median duration of clinical symptoms attributed to vasculitis prior to biopsy was 8 months (IQR 4.75-24). Systemic organ involvement was more common in the Lund-Malmö cohort. The most commonly affected organ system apart from the nervous

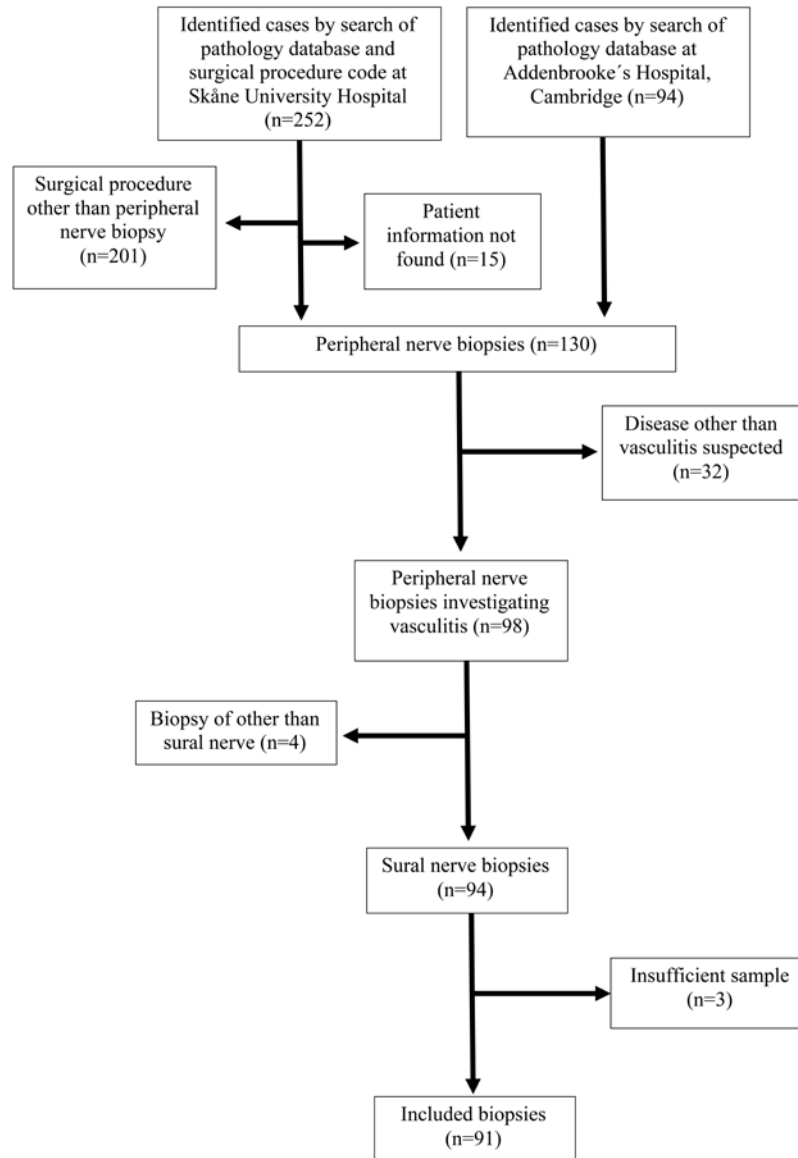


Figure. Flowchart of subjects meeting inclusion and exclusion criteria by study site.

system was the skin, occurring in 17%, followed by mucous membranes and/or eyes (10%), pulmonary (9%), renal (8%), ear-nose-throat (ENT; 5%), cardiovascular (3%), and gastrointestinal (1%). Nerve conduction study was performed in 81 patients, and results of PR3-ANCA or MPO-ANCA analysis was available for 71 patients. Twenty (28%) patients were ANCA positive, 12 (17%) with PR3, and 8 (11%) with MPO antigen.

Assessment of biopsies. Two of the 91 patients, in addition to SNB, underwent simultaneous radial nerve biopsies: 1 of the superficial and 1 of the deep radial nerve branch. A concomitant muscle biopsy was performed in 10 patients: 9 of the quadriceps femoris muscle group and, in 1 case, of the peroneus muscle. A biopsy of the entire sural nerve was performed in 77 cases, while in 11 patients from the Lund-Malmö cohort, a fascicular biopsy was performed. In 3 cases it was unclear if a fascicular biopsy or a biopsy of the entire nerve was performed. The median length of

the sural nerve sample was 22 mm (IQR 15-40). Definite vasculitis was reported in 14 patients (15%) and probable in 26 (29%), with no vasculitis found in 51 (56%). The radial nerve and muscle biopsies provided no additional diagnostic information.

Correlation of histology findings and disease characteristics. ANCA positivity ($P = 0.03$), suspected organ involvement in addition to the nervous system ($P = 0.04$), and greater length of biopsy sample ($P = 0.04$) were associated with positive biopsy findings (Table 3). No association was seen with PR3-ANCA or MPO-ANCA specificity ($P = 0.15$ and $P = 0.13$). In the electrophysiological evaluations, sensorimotor neuropathy was the most prevalent feature, occurring in 75% of patients. Pure motor or pure sensory symptoms were uncommon. No patient presenting with pure motor neuropathy showed a positive biopsy. Apparent axonal neuropathy in NCS was seen in 73% of the cohort. Biopsies were negative in the 2 patients presenting with demyelinating neuropathy. The remaining patients were

Table 2. Characteristics of 91 patients undergoing sural nerve biopsy.

	Skåne (n = 34)	Cambridge (n = 57)	Total (n = 91)
Demographics			
Age at biopsy, yrs, mean (SD)	60 (13.0)	57 (16.1)	58 (15.0)
Male	23 (68)	27 (47)	50 (55)
Clinic, laboratory, and neurophysiology findings			
Systemic organ involvement ^a	16/34 (47)	14/53 (26)	30/87 (34)
Pathological neurophysiological evaluation	31/33 (94)	48/48 (100)	79/81 (98)
ANCA positive ^b	15/31 (48)	5/40 (13)	20/71 (28)
CRP, mg/L, mean (SD) ^c	33 (55.9)	15 (28.6)	24 (45.8)
Treatment ^d	24/34 (71)	17/46 (37)	41/80 (51)
Biopsy result			
Definite vasculitis	8 (24)	6 (11)	14 (15)
Probable vasculitis	9 (26)	17 (30)	26 (29)
Complications			
Any surgical complication	5/34 (15)	4/25 (16)	9/59 (15)
Wound infection	3/34 (9)	3/25 (12)	6/59 (10)
Wound dehiscence	1/34 (3)	3/25 (12)	4/59 (7)
Delayed wound healing	2/34 (6)	1/25 (4)	3/59 (5)
Other complication ^e	1/34 (3)	0/26 (0)	1/59 (2)

Values are expressed as n (%) unless indicated otherwise. The n excluding missing for each variable is presented after slash. ^a Symptoms from organ systems other than the nervous system at the time of sural nerve biopsy (skin, mucous membrane, eyes, ear-nose-throat, pulmonary, cardiovascular, gastrointestinal, renal). ^b PR3-ANCA or MPO-ANCA in ELISA. ^c Available in 54 subjects. ^d Any immunosuppressive treatment or glucocorticoids at the time of the sural nerve biopsy. ^e One patient with postsurgical hematoma. ANCA: antineutrophil cytoplasmic antibody; CRP: C-reactive protein; MPO: myeloperoxidase; PR3: proteinase 3.

Table 3. Clinical, neurophysiological, and surgical characteristics of patients with positive vs negative sural nerve biopsy for vasculitis.

	Positive Biopsy, n = 40	Negative Biopsy, n = 51	P
Clinical and laboratory			
Symptom duration, months, median (IQR) ^a	6 (3-22)	12 (6-29)	0.06
Systemic organ involvement ^b	18/39 (46)	12/48 (25)	0.04
ANCA positivity ^c	14/35 (40)	6/36 (17)	0.03
CRP, mg/L, mean (SD) ^d	28 (44)	21 (48)	0.62
Treatment	20/36 (56)	21/44 (48)	0.64
Length of biopsy sample, mm, median (IQR) ^e	30 (18-43)	21 (14-33)	0.04
Neurophysiological			
Sensorimotor neuropathy	27/36 (75)	34/45 (76)	0.95
Pure motor neuropathy	0/36 (0)	4/45 (9)	0.13
Pure sensory neuropathy	8/36 (22)	6/45 (13)	0.32
Axonal neuropathy	27/36 (75)	35/45 (78)	0.77
Asymmetric pattern	21/30 (70)	21/34 (62)	0.60
Affected sural nerve	25/28 (89)	27/35 (77)	0.32

Values are expressed as n (%) unless indicated otherwise. For continuous variables, the valid n is presented in footnotes. For categorical variables, n excluding missing is presented after slash. ^a Available for evaluation in 82 patients. ^b Symptoms from organ systems other than the nervous system at the time of sural nerve biopsy (skin, mucous membrane, eyes, ear-nose-throat, pulmonary, cardiovascular, gastrointestinal, or renal). ^c PR3-ANCA or MPO-ANCA in ELISA. ^d Available for evaluation in 54 patients. ^e Available for evaluation in 78 patients. ANCA: antineutrophil cytoplasmic antibody; CRP: C-reactive protein; MPO: myeloperoxidase; PR3: proteinase 3.

not designated axonal or demyelinating neuropathy. In 66% of the electrophysiological reports, the pattern of neuropathy was described as patchy or asymmetric. However, no association

of an electrophysiologically affected sural nerve or asymmetric electrophysiological pattern with a positive biopsy was found (Table 3).

Complications. Postsurgical follow-up information was available for 59 patients. Surgical complications arose in 9 (15%). The most common complication was wound infection ($n = 6$), followed by wound dehiscence ($n = 4$) and delayed wound healing ($n = 3$). A fascicular biopsy was not observed to reduce the surgical complication rate ($P > 0.99$), nor was a shorter biopsy sample ($P = 0.18$).

DISCUSSION

The comparability of our results with previously published studies of biopsy for the diagnosis of peripheral nerve vasculitis is limited by differences in vasculitis pathology criteria and unclearly described recruitment methods.^{5,12,18,19} In this study, histopathological vasculitis was categorized as definite or probable in accordance with the 2015 Brighton Collaboration reinterpretation and update of the Peripheral Nerve Society guidelines for vasculitic neuropathy,^{16,17} enabling comparability with future studies. Including cases with vessel wall inflammation, without necrosis but exhibiting other vasculitis-associated signs, increased sensitivity with only a marginal loss in specificity.²⁰

The demographic features of our cohort were similar to those reported in other studies, with biopsies conducted in patients approximately 60 years of age after a relatively long duration of symptoms.^{5,9,12}

A positive biopsy was associated with ANCA positivity and symptoms involving organs other than the nervous system. In a large European cohort of patients with AAV, vasculitic neuropathy was found in 28%, occurring more frequently in eosinophilic granulomatosis with polyangiitis than in microscopic polyangiitis or granulomatosis with polyangiitis, and in patients with MPO-ANCA than in PR3-ANCA.²¹

Neurologic involvement of systemic vasculitis is associated with cutaneous, mucous membrane/eye, and ENT involvement rather than the usually more severe manifestations such as pulmonary, cardiovascular, gastrointestinal, or renal symptoms.²² In our study, involvement of any organ outside the nervous system was associated with a positive biopsy result.

We found a rate of positive biopsies comparable to previous studies using similar definitions. Claussen et al,⁵ using a “definite and probable” definition as in our study, reported a positive SNB rate of 39% in patients with suspected vasculitis. Nathani et al,¹² using diagnostic criteria similar to ours, identified definite vasculitis in 10% and probable vasculitis in 19% of patients with suspected vasculitis undergoing predominantly SNBs.

Biopsy of the superficial peroneal nerve combined with biopsy of the peroneus brevis muscle using a single incision has been suggested to provide greater diagnostic yield than SNB in suspected vasculitis.^{6,23} However, one should consider the greater risk of severe neurological sequelae.¹⁴ In our cohort, the muscle biopsy included in 10 of the 91 cases provided no additional diagnostic information, further confirming reports that no increase in diagnostic yield is seen with combined SNB and muscle biopsy.^{5,9} The majority of muscle biopsies in this study were taken from the quadriceps, as opposed to the more distal peroneus brevis muscle. It is possible, as hypothesized by Bennett et al,⁹ that distal predominance of muscle vasculitis or greater

inflammation in muscles in the proximity of an affected nerve may result in enhanced diagnostic yield of combined superficial peroneal nerve and peroneus brevis biopsy.

We saw no association between being treated for vasculitis (GCs or immunosuppression) at the time of biopsy and a positive biopsy result. We hypothesized that treatment may have masked a positive biopsy result, explaining the relatively high proportion of negative biopsies. The effect of timing of treatment on biopsy result is unknown in SNB. In patients with suspected giant cell arteritis, a biopsy of the temporal artery still yields clinically useful information weeks after initiation of GC treatment.²⁴

The finding of lack of association of an electrophysiological pattern with a positive biopsy result was unexpected. In accordance with previous descriptions of vasculitic neuropathy, the majority of patients included in this study experienced the typical pattern of sensory or sensorimotor axonal neuropathy.⁴ Four patients presented with pure motor neuropathy and 2 with demyelinating neuropathy on the NCS, with none exhibiting a positive biopsy. In 2 patients, SNB was performed despite a normal electrophysiological evaluation, due to clinical neuropathy. We did not observe the association of objective asymmetric neuropathy with a positive biopsy of the sural nerve that has previously been reported.^{12,25} It is feasible, given the long duration of symptoms prior to biopsy and the natural progression of vasculitic neuropathy, that the typical asymmetrical pattern in some positive cases has been blurred into a more symmetrical neuropathic distribution.⁴

We found length of the biopsy sample to be positively associated with diagnostic yield. This is not surprising, given the increased quantity of tissue for analysis, the skip lesion distribution of vasculitis along a blood vessel, and the asymmetry of axonal degeneration within an affected nerve.^{23,26} The importance of harvesting a suitable portion of the nerve with a sufficient number of intra-/extraneural microvessels must be stressed. Hence, an experienced surgeon should perform the procedure. The recommended length of the specimen¹⁰ is 50 mm. The median length of the samples in this study was 22 mm. The length of the sample may not, however, accurately reflect the length of the harvested nerve segment due to postresection shrinkage.²⁷

Inconsistent information concerning the correlation of the length of the nerve resection and postsurgical sensory deficits has been reported.^{10,27} Due to our retrospective study design, information concerning subsequent sensory deficit was not available. However, residual deficits as well as additional symptoms have been reported in healthy subjects and in subjects with type 1 and 2 diabetes.^{13,28} In our study, 15% of patients for whom follow-up information was available experienced surgical complications, similar to previously reported rates.^{14,19} No positive relationship was observed between surgical complication rate and length of biopsy specimen, which was generally short.

Our study has limitations. Due to its retrospective nature, missing data may have affected the assessment of correlation between biopsy findings and clinical characteristics, as well as the rate of surgical complications. This also precluded us from

investigating predictors of a positive biopsy by fitting a multivariable regression model.

Strengths of this study include using a well-defined definition of biopsy positive for vasculitis. In addition, investigating SNB at 2 academic centers in different countries enabled us to include, in the context of vasculitic neuropathy, a relatively large number of patients.

In conclusion, SNB should be of sufficient length and include the relevant intraneural blood vessels. Routine conduction of combined muscle biopsy and SNB is not recommended. A thorough clinical examination should be done before performing SNB, and may guide you in the usefulness of the procedure. A SNB of sufficient length is of value in confirming a diagnosis of vasculitis.

ACKNOWLEDGMENT

We thank Mr. Simon Brown, for searching the pathology database at Addenbrooke's Hospital, Cambridge, UK.

REFERENCES

1. Graf J, Imboden J. Vasculitis and peripheral neuropathy. *Curr Opin Rheumatol* 2019;31:40-5.
2. Gwathmey KG, Burns TM, Collins MP, Dyck PJ. Vasculitic neuropathies. *Lancet Neurol* 2014;13:67-82.
3. Gwathmey KG, Tracy JA, Dyck PJB. Peripheral nerve vasculitis: classification and disease associations. *Neurol Clin* 2019;37:303-33.
4. Collins MP, Hadden RD. The nonsystemic vasculitic neuropathies. *Nat Rev Neurol* 2017;13:302-16.
5. Claussen GC, Thomas TD, Goynes C, Vázquez LG, Oh SJ. Diagnostic value of nerve and muscle biopsy in suspected vasculitis cases. *J Clin Neuromuscul Dis* 2000;1:117-23.
6. Vital C, Vital A, Canron MH, et al. Combined nerve and muscle biopsy in the diagnosis of vasculitic neuropathy. A 16-year retrospective study of 202 cases. *J Peripher Nerv Syst* 2006;11:20-9.
7. Prada V, Massucco S, Venturi C, et al. Diagnostic Value of Sural Nerve Biopsy: Retrospective Analysis of Clinical Cases From 1981 to 2017. *Front Neurol* 2019;10:1218.
8. Agadi JB, Raghav G, Mahadevan A, Shankar SK. Usefulness of superficial peroneal nerve/peroneus brevis muscle biopsy in the diagnosis of vasculitic neuropathy. *J Clin Neurosci* 2012;19:1392-6.
9. Bennett DL, Groves M, Blake J, et al. The use of nerve and muscle biopsy in the diagnosis of vasculitis: a 5 year retrospective study. *J Neurol Neurosurg Psychiatry* 2008;79:1376-81.
10. Weis J, Brandner S, Lammens M, Sommer C, Vallat JM. Processing of nerve biopsies: a practical guide for neuropathologists. *Clin Neuropathol* 2012;31:7-23.
11. Dyck PJ, Benstead TJ, Conn DL, Stevens JC, Windebank AJ, Low PA. Nonsystemic vasculitic neuropathy. *Brain* 1987;110:843-53.
12. Nathani D, Barnett MH, Spies J, Pollard J, Wang MX, Kiernan MC. Vasculitic neuropathy: comparison of clinical predictors with histopathological outcome. *Muscle Nerve* 2019;59:643-9.
13. Dahlin LB, Eriksson KF, Sundkvist G. Persistent postoperative complaints after whole sural nerve biopsies in diabetic and non-diabetic subjects. *Diabet Med* 1997;14:353-6.
14. Hilton DA, Jacob J, Househam L, Tengah C. Complications following sural and peroneal nerve biopsies. *J Neurol Neurosurg Psychiatry* 2007;78:1271-2.
15. Ruth A, Schulmeyer FJ, Roesch M, Woertgen C, Brawanski A. Diagnostic and therapeutic value due to suspected diagnosis, long-term complications, and indication for sural nerve biopsy. *Clin Neurol Neurosurg* 2005;107:214-7.
16. Collins MP, Dyck PJ, Gronseth GS, et al. Peripheral Nerve Society Guideline on the classification, diagnosis, investigation, and immunosuppressive therapy of non-systemic vasculitic neuropathy: executive summary. *J Peripher Nerv Syst* 2010;15:176-84.
17. Hadden RDM, Collins MP, Živković SA, et al. Vasculitic peripheral neuropathy: case definition and guidelines for collection, analysis, and presentation of immunisation safety data. *Vaccine* 2017;35:1567-78.
18. Luigetti M, Di Paolantonio A, Bisogni G, et al. Sural nerve biopsy in peripheral neuropathies: 30-year experience from a single center. *Neurol Sci* 2020;41:341-6.
19. Rappaport WD, Valente J, Hunter GC, et al. Clinical utilization and complications of sural nerve biopsy. *Am J Surg* 1993;166:252-6.
20. Collins MP, Mendell JR, Periquet MI, et al. Superficial peroneal nerve/peroneus brevis muscle biopsy in vasculitic neuropathy. *Neurology* 2000;55:636-43.
21. Bischof A, Jaeger VK, Hadden RDM, et al. Peripheral neuropathy in antineutrophil cytoplasmic antibody-associated vasculitides: insights from the DCVAS study. *Neurol Neuroimmunol Neuroinflamm* 2019;6:e615.
22. Suppiah R, Hadden RD, Batra R, et al; European Vasculitis Study Group. Peripheral neuropathy in ANCA-associated vasculitis: outcomes from the European Vasculitis Study Group trials. *Rheumatology* 2011;50:2214-22.
23. Said G, Lacroix-Ciaudo C, Fujimura H, Blas C, Faux N. The peripheral neuropathy of necrotizing arteritis: a clinicopathological study. *Ann Neurol* 1988;23:461-5.
24. Jakobsson K, Jacobsson L, Mohammad AJ, et al. The effect of clinical features and glucocorticoids on biopsy findings in giant cell arteritis. *BMC Musculoskelet Disord* 2016;17:363.
25. Živković SA, Ascherman D, Lacomis D. Vasculitic neuropathy--electrodiagnostic findings and association with malignancies. *Acta Neurol Scand* 2007;115:432-6.
26. Morozumi S, Koike H, Tomita M, et al. Spatial distribution of nerve fiber pathology and vasculitis in microscopic polyangiitis-associated neuropathy. *J Neuropathol Exp Neurol* 2011;70:340-8.
27. Theriault M, Dort J, Sutherland G, Zochodne DW. A prospective quantitative study of sensory deficits after whole sural nerve biopsies in diabetic and nondiabetic patients. Surgical approach and the role of collateral sprouting. *Neurology* 1998;50:480-4.
28. Dahlin LB, Lithner F, Bresäter LE, Thomsen NO, Eriksson KF, Sundkvist G. Sequelae following sural nerve biopsy in type 1 diabetic subjects. *Acta Neurol Scand* 2008;118:193-7.