

# Doppler Signal and Bone Erosions at the Enthesis Are Independently Associated With Ultrasound Joint Erosive Damage in Psoriatic Arthritis

Gianluca Smerilli<sup>1</sup> , Edoardo Cipolletta<sup>1</sup> , Giulia Maria Destro Castaniti<sup>2</sup>, Andrea Di Matteo<sup>1</sup> , Marco Di Carlo<sup>1</sup> , Erica Moscioni<sup>1</sup>, Francesca Francioso<sup>1</sup>, Riccardo Mashadi Mirza<sup>3</sup>, Walter Grassi<sup>1</sup>, and Emilio Filippucci<sup>1</sup> 

**ABSTRACT. Objective.** To explore the association of the Outcome Measures in Rheumatology ultrasound (US) enthesal abnormalities with the presence of US joint bone erosions in psoriatic arthritis (PsA).

**Methods.** Consecutive patients with PsA were included in this cross-sectional study. Demographic and clinical variables were collected. A bilateral US assessment was carried out at the following entheses: plantar fascia, and the quadriceps, patellar (proximal and distal), and Achilles tendons. The following US enthesal abnormalities were registered: hypoechogenicity, thickening, Doppler signal < 2 mm from the bony cortex, calcification/enthesophyte, and bone erosion. The presence of US joint bone erosions was investigated at the second and fifth metacarpophalangeal joints, ulnar head, and fifth metatarsophalangeal (MTP) joint, bilaterally, as well as at the level of the most inflamed joint on physical examination. Multiple linear regression analysis was performed to identify clinical and/or US variables associated with US-detected joint bone erosions.

**Results.** A total of 104 patients with PsA were enrolled. At least 1 joint bone erosion was found in 47 of 104 patients (45.2%). Bone erosions were most frequently detected at the fifth MTP joint level (42/208 joints [20.2 %] in 32/104 patients [30.8%]). In the multivariate model, only a power Doppler (PD) signal at the entheses ( $P < 0.001$ , standardized  $\beta = 0.51$ ), bone erosions at the entheses ( $P = 0.02$ , standardized  $\beta = 0.20$ ), PsA disease duration ( $P = 0.04$ , standardized  $\beta = 0.17$ ), and greyscale joint synovitis ( $P = 0.03$ , standardized  $\beta = 0.42$ ) were associated with US-detected joint bone erosions.

**Conclusion.** PD signal and bone erosions at the entheses represent sonographic biomarkers of a more severe subset of PsA in terms of US-detected joint erosive damage.

**Key Indexing Terms:** enthesitis, power Doppler signal, psoriatic arthritis, ultrasound

Enthesitis is one of the hallmarks of psoriatic arthritis (PsA), it is part of the Classification for Psoriatic Arthritis (CASPAR) criteria,<sup>1</sup> and it is one of the 6 clinical domains to be considered

in the treatment of patients with PsA according to the Group for Research and Assessment of Psoriasis and Psoriatic Arthritis.<sup>2</sup>

The clinical identification of enthesitis is rarely straightforward<sup>3,4</sup>; thus, interest has grown regarding the imaging assessment of this condition in the last decades. Ultrasound (US) accurately detects enthesal morphostructural and vascular abnormalities and may be considered the first-line imaging method for the assessment of enthesitis.<sup>5-8</sup> According to the Outcome Measures in Rheumatology (OMERACT) US Task Force, the elementary changes composing the spectrum of US enthesitis are the following: hypoechogenicity, thickening, and power Doppler (PD) signal (ie, inflammatory components); and calcification/enthesophyte and bone erosion at entheses (ie, structural components).<sup>9</sup>

Evidence is growing on the possible link between enthesal and joint pathology.<sup>10,11</sup> Indeed, US-detected enthesal pathology assessed using the Madrid Sonographic Enthesitis Index (MASEI) scoring system (which includes the OMERACT elementary changes plus perienthesal bursitis) appeared to be a potential marker of disease severity, with a higher MASEI score associated with more severe radiographic damage at the peripheral joint level.<sup>12</sup>

<sup>1</sup>G. Smerilli, MD, E. Cipolletta, MD, A. Di Matteo, MD, PhD, M. Di Carlo, MD, E. Moscioni, MD, F. Francioso, MD, W. Grassi, MD, PhD, E. Filippucci, MD, PhD, Marche Polytechnic University, Rheumatology Unit, Department of Clinical and Molecular Sciences, "Carlo Urbani" Hospital, Jesi, Ancona; <sup>2</sup>G.M. Destro Castaniti, MD, University of Palermo, Department of Health Promotion, Mother and Child Care, Internal Medicine and Medical Specialties, Rheumatology section, "P. Giaccone" Hospital, Palermo; <sup>3</sup>R. Mashadi Mirza, MD, Radiology Department, A.O. Ospedali Riuniti Marche Nord, Pesaro, Italy.

EF has received speaking fees from AbbVie, Amgen, BMS, Janssen-Cilag, Eli Lilly, Novartis, Pfizer, Roche, and Union Chimique Belge Pharma. WG has received speaking fees from AbbVie, Celgene, Grünenthal, Pfizer, and Union Chimique Belge Pharma. All other authors disclose no conflict of interest relevant to this article.

Address correspondence to Dr. G. Smerilli, Polytechnic University of Marche, Rheumatology Unit, Department of Clinical and Molecular Sciences, "Carlo Urbani" Hospital, Via Aldo Moro 25, 60035 Jesi, Ancona, Italy. Email: smerilligianluca@gmail.com.

Accepted for publication January 14, 2022.

However, several previous studies have demonstrated that some of the OMERACT US abnormalities (ie, hypoechogenicity, thickening, and calcification/enthesophyte) are frequently encountered in healthy subjects and in patients with metabolic syndrome,<sup>13-16</sup> undermining the specificity of these US findings. We hypothesized that this “background noise” might impair the role of enthesal US pathology as a biomarker of disease severity, since not all of the elementary components of US enthesitis might be linked to joint erosive damage.

The main objective of the present study was to explore the association of the OMERACT US enthesal abnormalities with the presence of US joint bone erosions in PsA.

## METHODS

**Patients.** Consecutive patients with PsA according to CASPAR criteria<sup>1</sup> were enrolled at the Rheumatology Unit of “Carlo Urbani” Hospital, Jesi (Ancona, Italy) from June 2020 through February 2021. Patients aged < 18 years were excluded.

The study was conducted in accordance with the Declaration of Helsinki and was approved by the local ethics committee (Comitato Etico Regionale delle Marche [CERM #352]). All patients signed an informed consent.

**Clinical assessment.** A rheumatologist (GMDC) recorded the following demographic and clinical data: age, sex, BMI, disease duration (PsA and psoriasis), physical activity (low, medium, intense), comorbidities (diabetes mellitus, metabolic syndrome, fibromyalgia), type of employment, swollen/tender joint count in 66/68 joints (SJC, TJC), numerical rating scale (NRS) of pain (0-10 scale), patient global assessment (PGA), C-reactive protein (CRP), Disease Activity Index for Psoriatic Arthritis (DAPSA), Leeds Enthesitis Index (LEI), Psoriasis Area Severity Index (PASI), minimal disease activity (MDA) criteria, Health Assessment Questionnaire (HAQ), and clinical enthesitis (defined as tenderness on palpation) at the insertions of lateral and medial epicondyles, patellar insertion of the quadriceps tendon, proximal and distal insertions of the patellar tendon, and calcaneal insertions of the Achilles tendon and plantar fascia.

The presence of current dactylitis, history of nail disease, and history of hand, feet, and/or axial involvement was registered. The most inflamed joint at physical examination (excluding the second and fifth metacarpophalangeal [MCP] joints and fifth metatarsophalangeal [MTP] joint) was identified.

**US assessment.** The US examination was carried out on the same day as the clinical evaluation by another rheumatologist (GS) using a My Lab Class C ( Esaote) US device equipped with a high frequency linear probe (6-18 MHz). Greyscale (GS) gain and dynamic range values were set in order to obtain the maximal contrast resolution of the tissues under examination. Main PD variables were set with a frequency of 9.1 MHz and a pulse repetition frequency of 750 Hz. The PD gain was increased to the highest value not generating signals under the bony cortex. The sonographer was blinded to clinical data.

The scanning protocol was conducted in accordance with the 2017 European Alliance of Associations for Rheumatology (EULAR) guidelines for US imaging in rheumatology.<sup>17</sup>

**Entheses.** Five entheses of the lower limb were examined bilaterally: patellar insertion of the quadriceps tendon, proximal and distal insertions of the patellar tendon, calcaneal insertions of the Achilles tendon, and plantar fascia.

The knee entheses were examined with the patient in neutral position, lying supine on the examination bed. PD signal was assessed with extended lower limbs, whereas GS abnormalities were investigated with the knees in semiflexed position. The Achilles tendon and the plantar fascia were evaluated with the patient lying in the prone position with the feet hanging over

the examination bed in neutral position. All entheses were scanned in GS and PD mode both in longitudinal and transverse planes.

According to the OMERACT definitions, the presence of the following US elementary lesions was registered: enthesal hypoechogenicity, enthesal thickening, PD signal < 2 mm from the bony cortex, calcification/enthesophyte, and enthesal bone erosion.<sup>5,9</sup>

The PD signal was also scored according to a semiquantitative scale from 0 to 3, where grade 0 = absent, grade 1 = mild, grade 2 = moderate, and grade 3 = severe. This score ranges from 0 to 3 for each enthesis and from 0 to 30 for each patient.<sup>13,18</sup>

A dichotomous score (0 = absence, 1 = presence) was provided for the following enthesal abnormalities: hypoechogenicity, thickening, calcification/enthesophyte, and enthesal bone erosion. This score ranges from 0 to 1 for each enthesis and from 0 to 10 for each patient.

**Joints.** The following areas were examined: second and fifth MCP joints, ulnar head, and fifth MTP joint, bilaterally.<sup>19-23</sup> Additionally, in patients with clinical synovitis, the most inflamed joint at the physical examination (as previously defined) was evaluated.

The US assessment was performed with GS and PD mode both in the longitudinal and transverse planes, as indicated by the 2017 EULAR standardized procedures for US imaging in rheumatology.<sup>17</sup>

The presence of the following abnormalities was recorded: GS and PD synovitis (semiquantitative score 0-3), extensor carpi ulnaris tenosynovitis (dichotomous score, 0 = absence, 1 = presence), and bone erosions, according to OMERACT definitions.<sup>24-26</sup> The GS and PD synovitis scores ranged from 0 to 21 for each patient.

The largest diameter of the bone erosion was measured and the semiquantitative score proposed by Ohrndorf et al in patients with rheumatoid arthritis was adopted: grade 0, no erosion; grade 1, < 1 mm; grade 2, 1 to < 2 mm; grade 3, 2 to ≤ 3 mm; grade 4, > 3 mm; grade 5, multiple bone erosions.<sup>27</sup>

**Statistical analysis.** Results are expressed as mean and SD for quantitative variables with a normal distribution, as median and IQR for quantitative variables with a nonnormal distribution, and as number and/or percentage for qualitative variables. Quantitative variables were tested for normality using the Shapiro-Wilk normality test. The *t* test was used for quantitative variables with a normal distribution, whereas the Mann-Whitney *U* test was used for quantitative variables with a nonnormal distribution and the chi-square test for qualitative variables.

Multiple linear regression analysis was performed to identify the variables associated with US joint bone erosions. The number of joints (including the ulnar head) with US-detected bone erosions was used as the dependent variable. Demographic, clinical, and laboratory independent variables were as follows: age, sex, disease duration, BMI, disease duration (PsA and psoriasis), physical activity (< 2 times a week, 2-3 times a week, > 3 times a week), diabetes mellitus (yes/no), metabolic syndrome (yes/no), fibromyalgia (yes/no), employment (blue collar, white collar, or unemployed), SJC, TJC, NRS pain, PGA, CRP, DAPSA, LEI, PASI, MDA, HAQ, clinical enthesitis (sum of tender entheses at physical examination), current dactylitis (yes/no), history of nail disease, and history of hand, feet, and/or axial inflammatory involvement (yes/no). The following US pathologic findings were also included as independent variables: GS and PD synovitis scores at patient level, extensor carpi ulnaris tenosynovitis, and enthesal US elementary lesions scores at the patient level (enthesal hypoechogenicity, thickening, PD signal, calcification/enthesophyte, and enthesal bone erosion).

Logistic regression analysis was also performed to define the variables associated with US erosive disease at joint level (dependent variable: presence of ≥ 1 joint US bone erosion). Independent variables were included in the multivariate analyses only if *P* < 0.10 at univariate analyses. Two-tailed *P* < 0.05 was considered significant.

Statistical analysis was performed using SPSS Statistics for Windows, Version version 26.0 (IBM Corp).

## RESULTS

**Patients.** A total of 104 patients with PsA were enrolled. Table 1 shows their demographic, clinical, and laboratory data.

**Prevalence and distribution of enthesal and joint US abnormalities: entheses.** A total of 1040 entheses were evaluated. Table 2 shows the prevalence and distribution of the US abnormalities at enthesal level. Out of 104 patients, the most common finding was calcification/enthesophyte with  $\geq 1$  entheses affected in 100 (96.2%) patients, followed by hypoechogenicity in 93 (89.4%) patients, thickening in 81 (77.9%) patients, PD signal in 58 (55.8%) patients, and bone erosion in 24 (23.1%) patients.

**Prevalence and distribution of enthesal and joint US abnormalities: joints.** Table 3 shows the prevalence and the distribution of US-detected joint abnormalities. At least 1 joint bone erosion was found in 47 of 104 patients (45.2%). Bone erosions were most frequently detected at the level of the fifth MTP joint (42/208 joints [20.2%] in 32/104 patients [30.8%]). Among joints with  $> 0$  bone erosions, according to the Ohnrodorf et al erosion score,<sup>27</sup> 21 of 100 (21%) were grade 1, 26 of 100 (26%)

Table 1. Demographic and clinical data.

	Value
Age, yrs	52.1 $\pm$ 13.2
Male:female	1.8:1
BMI, kg/m <sup>2</sup>	26.6 $\pm$ 4.7
PsA duration, yrs	7.6 $\pm$ 7.9
Psoriasis duration, yrs	15.6 $\pm$ 13.3
Physical activity	
Low	65 (62.5)
Medium	33 (31.7)
Intense	6 (5.8)
Employment	
Unemployed	38 (36.5)
White collar	33 (31.7)
Blue collar	33 (31.7)
Tender joint count	4.7 $\pm$ 7.1
Swollen joint count	2.2 $\pm$ 3.7
C-reactive protein, mg/dL	0.9 $\pm$ 2.4
DAPSA	16.5 $\pm$ 14.8
Minimal disease activity	33 (31.7)
Leeds Enthesitis Index	1.1 $\pm$ 1.4
Psoriasis Area Severity Index	1.4 $\pm$ 3.7
Health Assessment Questionnaire	0.6 $\pm$ 0.6
Patients with dactylitis	11 (10.6)
Patients with past/current nail disease	32 (30.8)
History of hand inflammatory involvement	80 (76.9)
History of feet inflammatory involvement	67 (64.4)
History of axial inflammatory involvement	8 (7.7)
Diabetes mellitus	8 (7.7)
Metabolic syndrome	29 (27.9)
Fibromyalgia	11 (10.6)
Current treatment	
Conventional DMARD	44 (42.3)
Biologic DMARD	42 (40.4)

Values are n (%) or mean  $\pm$  SD. DAPSA: Disease Activity Index for Psoriatic Arthritis; DMARD: disease-modifying antirheumatic drug; PsA: psoriatic arthritis.

were grade 2, 4 of 100 (4%) were grade 3, 1 of 100 (1%) was grade 4, and 48 of 100 (48%) were grade 5.

The bilateral US assessment of the fifth MTP joint, second MCP joint, and ulnar styloid would have been sufficient to identify erosive disease in 46 of 47 patients with  $\geq 1$  joint US bone erosion (97.9%).

**Clinical and sonographic variables associated with US joint bone erosions.** In the univariate analysis, the following variables were associated with US joint bone erosions: PD signal at entheses ( $P < 0.001$ ,  $\beta = 0.56$ ), hypoechogenicity at entheses ( $P < 0.001$ ,  $\beta = 0.38$ ), enthesal thickening ( $P < 0.001$ ,  $\beta = 0.41$ ), enthesal bone erosion ( $P < 0.001$ ,  $\beta = 0.40$ ), TJC ( $P = 0.04$ ,  $\beta = 0.20$ ), PsA disease duration ( $P < 0.001$ ,  $\beta = 0.39$ ), and GS ( $P < 0.001$ ,  $\beta = 0.42$ ) and PD ( $P < 0.001$ ,  $\beta = 0.39$ ) synovitis.

However, in the multivariate model (multiple linear regression analysis), only PD signal at entheses ( $P < 0.001$ , standardized  $\beta = 0.51$ ), enthesal bone erosions ( $P = 0.02$ , standardized  $\beta = 0.20$ ), PsA disease duration ( $P = 0.04$ , standardized  $\beta = 0.17$ ), and GS synovitis ( $P = 0.03$ , standardized  $\beta = 0.42$ ) remained significantly associated with US-detected joint bone erosions. The association of PD signal with US-detected joint bone erosions remained significant considering only PD grade  $> 1$  as positive ( $P < 0.01$ , standardized  $\beta = 0.49$ ).

The logistic regression analysis confirmed the results of the multiple linear regression analysis, with the following variables associated with the presence of  $\geq 1$  joint US bone erosion: PD signal at entheses (OR 1.74, 95% CI 1.17-2.59,  $P < 0.01$ ), enthesal bone erosions (OR 3.17, 95% CI 1.30-7.77,  $P = 0.01$ ), and GS synovitis (OR 2.59, 95% CI 1.16-5.78,  $P = 0.02$ ). The association of PD signal with the presence of  $\geq 1$  joint US bone erosion remained significant considering only PD grade  $> 1$  as positive (OR 2.16, 95% CI 1.18-3.94,  $P < 0.01$ ; Figure).

Supplementary Table 1 (available from the authors on request) shows the different prevalence of enthesal PD signal and enthesal bone erosions in patients with and without US joint bone erosions.

All the patients with  $\geq 1$  entheses showing the presence of both PD signal and bone erosion had  $\geq 1$  joint US bone erosion (15/15).

## DISCUSSION

PsA is a heterogeneous disease, characterized by a considerable variability in terms of inflammation and consequent damage at joint level, ranging from oligosymptomatic involvement to a destructive arthropathy.<sup>28</sup> Despite being traditionally considered a "benign" form of arthritis, in the last 2 decades several scientific contributions have highlighted that peripheral joint damage is a common feature of PsA.<sup>29-31</sup> The presence and entity of structural damage has a major role in defining the severity of the disease and should be considered in therapeutic decisions, as stated by EULAR and American College of Rheumatology recommendations.<sup>32-34</sup> The identification of biomarkers of disease severity is still an unmet need in PsA.<sup>35</sup>

The main purpose of this study was to explore the association of the OMERACT US enthesal abnormalities with the presence of US joint bone erosions in PsA. To the best of our

Table 2. Prevalence and distribution of enthesal US abnormalities.

US Abnormalities <sup>a</sup>	Quadriceps Tendon		Patellar Tendon Proximal Insertion		Patellar Tendon Distal Insertion		Achilles Tendon		Plantar Fascia		Sum	
	Enthesal Level	Patient Level	Enthesal Level	Patient Level	Enthesal Level	Patient Level	Enthesal Level	Patient Level	Enthesal Level	Patient Level	Enthesal Level	Patient Level
Hypoechogenicity	150 (51.5)	71 (68.3)	24 (11.5)	19 (18.3)	46 (22.1)	34 (32.7)	49 (23.5)	29 (27.9)	30 (14.4)	18 (17.3)	299 (28.7)	93 (89.4)
Thickening	23 (11.1)	19 (18.3)	39 (18.7)	31 (29.8)	64 (30.8)	46 (44.2)	30 (14.4)	21 (20.2)	62 (29.8)	38 (36.5)	218 (21.0)	81 (77.9)
PD signal ≥ 1	31 (14.9)	24 (23.1)	17 (8.2)	13 (12.5)	42 (20.2)	32 (30.8)	17 (8.2)	17 (16.3)	3 (1.4)	2 (1.9)	110 (10.6)	58 (55.8)
PD signal = 1	12 (5.8)	11 (10.6)	6 (2.9)	6 (5.8)	16 (7.7)	16 (15.4)	8 (3.8)	8 (7.7)	3 (1.4)	2 (1.9)	45 (4.3)	36 (34.6)
PD signal = 2	19 (9.1)	15 (14.4)	7 (2.4)	7 (6.7)	25 (12.0)	19 (18.3)	9 (4.3)	9 (8.6)	0 (0.0)	0 (0.0)	60 (5.8)	39 (37.5)
PD signal = 3	0 (0.0)	0 (0.0)	4 (1.9)	3 (2.9)	1 (0.5)	1 (1)	0 (0.0)	0 (0.0)	0 (0.0)	0 (0.0)	5 (0.5)	4 (3.8)
Calcification/ enthesophyte	136 (65.4)	82 (78.8)	38 (18.3)	28 (26.9)	32 (15.4)	26 (25)	136 (65.4)	77 (74)	59 (28.4)	37 (35.6)	401 (38.5)	100 (95.1)
Bone erosion	1 (0.5)	1 (1.0)	11 (5.3)	11 (10.6)	2 (1.0)	2 (1.9)	14 (6.7)	10 (9.6)	5 (2.4)	5 (4.8)	33 (3.2)	24 (23.1)

Values are n (%). <sup>a</sup> Values at “enthesal level” refer to the total number of entheses scanned; values at “patient level” refer to the total number of patients included with ≥ 1 enthesis involved. PD: power Doppler; US: ultrasound.

Table 3. Prevalence and distribution of joint US abnormalities.

	Joints With ≥ 1 BE		GS-Syn ≥ 1		PD-Syn ≥ 1	
	Joint Level	Patient Level	Joint Level	Patient Level	Joint Level	Patient Level
Second MCP joint	24 (11.5)	20 (19.2)	16 (7.7)	13 (12.5)	15 (7.2)	13 (12.5)
Fifth MCP joint	5 (2.4)	5 (4.8)	0 (0.0)	0 (0.0)	0 (0.0)	0 (0.0)
Ulnar head	22 (10.6)	17 (16.3)	NA	NA	NA	NA
Fifth MTP joint	42 (20.2)	32 (30.8)	21 (10.1)	16 (15.4)	20 (9.6)	15 (14.4)
Most inflamed joint at physical examination <sup>a</sup>	7 (10.9)	7 (10.9)	42 (65.6)	42 (65.6)	32 (50.0)	32 (50.0)

Values are n (%). <sup>a</sup> The percentages refer to the total number of patients in which the most inflamed joint at physical examination was examined, as defined in the Methods section (ie, 64 patients). BE: bone erosion; GS-Syn: greyscale synovitis; MCP: metacarpophalangeal; MTP: metatarsophalangeal; NA: not applicable; PD-Syn: power Doppler synovitis; US: ultrasound.

knowledge, the present study is the first to separately analyze the association of each of the OMERACT US elementary components of enthesitis with joint bone erosions and to include in the multivariate analysis an extended set of clinical and US variables.

Our results showed that enthesal PD signal, enthesal bone erosions, GS synovitis, and PsA disease duration were independently associated with US joint bone erosions.

These data confirm the association between US enthesitis and a more severe disease subset highlighted for the first time by Polachek et al.<sup>12</sup> Importantly, we demonstrated that not all the US enthesal abnormalities were equally relevant, as only PD signal and bone erosions were associated with joint damage at multivariate analysis.

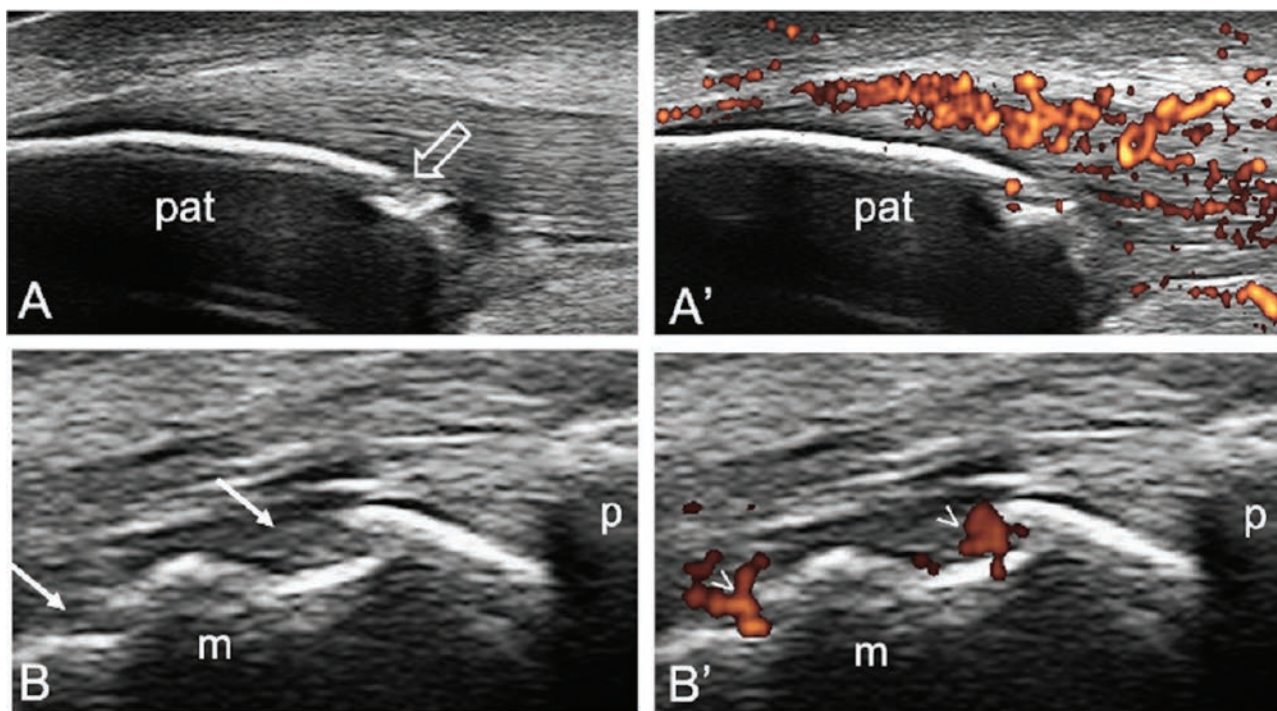
Our results could be explained considering that PD signal and bone erosions represent the more convincing expressions of an inflammatory process (active or previous) at the enthesis. In support of this assumption, studies on healthy subjects pointed out that the prevalence of PD signal and bone erosions was low compared with hypoechogenicity, thickening, and calcification/enthesophyte.<sup>13-15</sup> Similarly, dysmetabolic enthesopathy was also characterized by a low prevalence of PD signal and bone erosions in a previous study; thus, it is conceivable that PD signal and bone erosions might be less influenced by this commonly encountered PsA comorbidity.<sup>16</sup>

The interplay between enthesal and synovial tissues (ie, the synovio-enthesal complex) is a crucial element in the pathogenesis of spondyloarthritis.<sup>36,37</sup> The association between enthesal pathology detected with US and synovial inflammation was previously explored in a study by Ayan et al.<sup>10</sup> In this study, an US assessment of 46 joints and 12 large entheses was performed in patients with PsA and the authors found a correlation between the entity of US enthesal pathology and GS synovitis, but joint damage was not assessed. Our results provide further insight on this enthesitis–joint link, focusing on the correlation between the individual components of US enthesitis and joint damage instead of joint inflammation.

Of note, an intriguing hypothesis formulated by McGonagle et al was that articular bone erosion formation in inflammatory arthritis may be at least partially a result of microdamage occurring at the level of small entheses.<sup>38</sup> The enthesal hypothesis on the nature of periarticular bone erosion might represent the pathophysiological basis of the link between enthesal pathology and articular damage in PsA. However, longitudinal studies are needed to further corroborate this theory.

Interestingly, when simultaneously present at the same enthesis, PD signal and bone erosion were invariably associated with the presence of at least 1 joint US bone erosion. Thus, we strongly suggest that articular erosive damage should be





**Figure.** Ultrasound enthesitis (PD signal plus bone erosion) and joint bone erosions in the same patient. Longitudinal scans of the proximal patellar tendon insertion, without (A) and with (A') PD mode, showing an enthesitis with intense PD signal (score 3) and an enthesal bone erosion (open arrow). Longitudinal scans of the fifth metatarsophalangeal joint of the same patient, without (B) and with (B') PD mode, showing the presence of 2 cortical bone interruptions (arrows) with PD signal (arrowheads) indicative of joint bone erosions. m: metatarsal head; p: proximal phalanx, pat: patella; PD: power Doppler.

carefully and actively sought in the presence of such enthesal findings.

Finally, the correlation between both joint synovitis and disease duration with a higher burden of joint bone erosions is not surprising. Several studies have demonstrated that these are 2 key drivers of articular damage development and progression in inflammatory arthritis.<sup>29,39-42</sup>

The main limitation of the present study is that we included a relatively limited number of joints in the scanning protocol. These joints were chosen both for the high prevalence of joint bone erosions in previous studies conducted with computed tomography and for the possibility to perform a multiplanar US assessment.<sup>20,21,23</sup> To mitigate this potential drawback, we decided to also include in the scanning protocol the most clinically inflamed joint. However, the bilateral assessment of the fifth MTP joint, second MCP joint, and ulnar styloid would have been sufficient to identify erosive disease in all but 1 patient.

Another limitation is that only large entheses were assessed. It would be interesting to verify our results studying small entheses of hands and feet, even though the standardization of the US assessment of such entheses is still a challenging task and the OMERACT definitions may not be applicable *sic et simpliciter*.<sup>43-45</sup> An interesting aspect to be further addressed in future research is the association of PD signal and/or bone erosions at enthesal level with radiographic joint damage.

Whereas the sonographer was blinded to clinical variables, this was not possible for US variables, as the same sonographer performed both joint and enthesal US assessments. Other

limitations are represented by the fact that this is a single-center study (only 1 sonographer performed all US examinations); thus, a selection bias cannot be completely excluded even if the patients were consecutively enrolled.

In conclusion, our results highlight the relevance of PD signal and bone erosions at enthesis as biomarkers of an aggressive behavior of PsA at joint level. Such findings represent potential key elements for stratification of patients with PsA.

## REFERENCES

1. Taylor W, Gladman D, Helliwell P, et al. Classification criteria for psoriatic arthritis: development of new criteria from a large international study. *Arthritis Rheum* 2006;54:2665-73.
2. Coates LC, Kavanaugh A, Mease PJ, et al. Group for Research and Assessment of Psoriasis and Psoriatic Arthritis 2015 treatment recommendations for psoriatic arthritis. *Arthritis Rheumatol* 2016;68:1060-71.
3. Helliwell PS. Assessment of enthesitis in psoriatic arthritis. *J Rheumatol* 2019;46:869-70.
4. Mease P. Enthesitis in psoriatic arthritis (part 3): clinical assessment and management. *Rheumatology* 2020;59 Suppl 1:i21-8.
5. Terslev L, Naredo E, Iagnocco A, et al. Defining enthesitis in spondyloarthritis by ultrasound: results of a Delphi process and of a reliability reading exercise. *Arthritis Care Res* 2014;66:741-8.
6. Balint PV, Kane D, Wilson H, McInnes IB, Sturrock RD. Ultrasonography of enthesal insertions in the lower limb in spondyloarthropathy. *Ann Rheum Dis* 2002;61:905-10.
7. Delle Sedie A, Riente L, Filippucci E, et al. Ultrasound imaging for the rheumatologist XXVI. Sonographic assessment of the knee in patients with psoriatic arthritis. *Clin Exp Rheumatol* 2010; 28:147-52.

8. D'Agostino MA, Said-Nahal R, Hacquard-Bouder C, Brasseur JL, Dougados M, Breban M. Assessment of peripheral enthesitis in the spondylarthropathies by ultrasonography combined with power Doppler: a cross-sectional study. *Arthritis Rheum* 2003;48:523-33.
9. Balint PV, Terslev L, Aegerter P, et al. Reliability of a consensus-based ultrasound definition and scoring for enthesitis in spondyloarthritis and psoriatic arthritis: an OMERACT US initiative. *Ann Rheum Dis* 2018;77:1730-5.
10. Ayan G, Tinazzi I, Bakirci S, et al. Disease activity at the entheses and joints are correlated in psoriatic arthritis when explored with ultrasound. *Clin Exp Rheumatol* 2022;40:44-8.
11. Macía-Villa C, Cruz Valenciano A, De Miguel E. Enthesis lesions are associated with X-ray progression in psoriatic arthritis. *Int J Rheum Dis* 2021;24:828-33.
12. Polachek A, Cook R, Chandran V, Gladman DD, Eder L. The association between sonographic enthesitis and radiographic damage in psoriatic arthritis. *Arthritis Res Ther* 2017;19:189.
13. Di Matteo A, Filippucci E, Cipolletta E, et al. How normal is the enthesitis by ultrasound in healthy subjects? *Clin Exp Rheumatol* 2020;38:472-8.
14. Bakirci S, Solmaz D, Stephenson W, Eder L, Roth J, Aydin SZ. Enthesal changes in response to age, body mass index, and physical activity: an ultrasound study in healthy people. *J Rheumatol* 2020;47:968-72.
15. Guldberg-Møller J, Terslev L, Nielsen SM, et al. Ultrasound pathology of the entheses in an age and gender stratified sample of healthy adult subjects: a prospective cross-sectional frequency study. *Clin Exp Rheumatol* 2019;37:408-13.
16. Falsetti P, Conticini E, Baldi C, Acciai C, Frediani B. High prevalence of ultrasound-defined enthesitis in patients with metabolic syndrome. Comment on: how normal is the enthesitis by ultrasound in healthy subjects? Di Matteo et al. *Clin Exp Rheumatol* 2021;39:435-6.
17. Möller I, Janta I, Backhaus M, et al. The 2017 EULAR standardised procedures for ultrasound imaging in rheumatology. *Ann Rheum Dis* 2017;76:1974-9.
18. Freeston JE, Coates LC, Nam JL, et al. Is there subclinical enthesitis in early psoriatic arthritis? A clinical comparison with gray-scale and power Doppler ultrasound. *Arthritis Care Res* 2014;66:432-9.
19. Milosavljevic J, Lindqvist U, Elvin A. Ultrasound and power Doppler evaluation of the hand and wrist in patients with psoriatic arthritis. *Acta Radiol* 2005;46:374-85.
20. Tâmaş MM, Filippucci E, Becciolini A, et al. Bone erosions in rheumatoid arthritis: ultrasound findings in the early stage of the disease. *Rheumatology* 2014;53:1100-7.
21. Poggenborg RP, Bird P, Boonen A, et al. Pattern of bone erosion and bone proliferation in psoriatic arthritis hands: a high-resolution computed tomography and radiography follow-up study during adalimumab therapy. *Scand J Rheumatol* 2014;43:202-8.
22. Zabotti A, Piga M, Canzoni M, et al. Ultrasonography in psoriatic arthritis: which sites should we scan? *Ann Rheum Dis* 2018;77:1537-8.
23. Finzel S, Englbrecht M, Engelke K, Stach C, Schett G. A comparative study of periarticular bone lesions in rheumatoid arthritis and psoriatic arthritis. *Ann Rheum Dis* 2011;70:122-7.
24. D'Agostino MA, Terslev L, Aegerter P, et al. Scoring ultrasound synovitis in rheumatoid arthritis: a EULAR-OMERACT ultrasound taskforce—part 1: definition and development of a standardised, consensus-based scoring system. *RMD Open* 2017;3:e000428.
25. Naredo E, D'Agostino MA, Wakefield RJ, et al. Reliability of a consensus-based ultrasound score for tenosynovitis in rheumatoid arthritis. *Ann Rheum Dis* 2013;72:1328-34.
26. Wakefield RJ, Balint PV, Szkudlarek M, et al. Musculoskeletal ultrasound including definitions for ultrasonographic pathology. *J Rheumatol* 2005;32:2485-7.
27. Ohrndorf S, Messerschmidt J, Reiche BE, Burmester GR, Backhaus M. Evaluation of a new erosion score by musculoskeletal ultrasound in patients with rheumatoid arthritis: is US ready for a new erosion score? *Clin Rheumatol* 2014;33:1255-62.
28. Gladman DD, Antoni C, Mease P, Clegg DO, Nash O. Psoriatic arthritis: epidemiology, clinical features, course, and outcome. *Ann Rheum Dis* 2005;64 Suppl 2:ii14-7.
29. Kane D, Stafford L, Bresnihan B, FitzGerard O. A prospective, clinical and radiological study of early psoriatic arthritis: an early synovitis clinic experience. *Rheumatology* 2003;42:1460-8.
30. Taylor WJ, Helliwell PS. Psoriatic arthritis is a joint-damaging disease -- a call for action! *Rheumatology* 2007;46:1747-8.
31. Morgan C, Lunt M, Bunn D, Scott DG, Symmons DP. Five-year outcome of a primary-care-based inception cohort of patients with inflammatory polyarthritis plus psoriasis. *Rheumatology* 2007;46:1819-23.
32. Gossec L, Baraliakos X, Kerschbaumer A, et al. EULAR recommendations for the management of psoriatic arthritis with pharmacological therapies: 2019 update. *Ann Rheum Dis* 2020;79:700-12.
33. Kerschbaumer A, Baker D, Smolen JS, Aletaha D. The effects of structural damage on functional disability in psoriatic arthritis. *Ann Rheum Dis* 2017;76:2038-45.
34. Singh JA, Guyatt G, Ogdie A, et al. Special article: 2018 American College of Rheumatology/National Psoriasis Foundation guideline for the treatment of psoriatic arthritis. *Arthritis Rheumatol* 2019;71:5-32.
35. Mahmood F, Coates LC, Helliwell PS. Current concepts and unmet needs in psoriatic arthritis. *Clin Rheumatol* 2018;37:297-305.
36. Watad A, Cuthbert RJ, Amital H, McGonagle D. Enthesitis: much more than focal insertion point inflammation. *Curr Rheumatol Rep* 2018;20:41.
37. Benjamin M, Moriggl B, Brenner E, Emery P, McGonagle D, Redman S. The "enthesitis organ" concept: why enthesopathies may not present as focal insertional disorders. *Arthritis Rheum* 2004;50:3306-13.
38. McGonagle D, Tan AL, Döhn UM, Ostergaard M, Benjamin M. Microanatomic studies to define predictive factors for the topography of periarticular erosion formation in inflammatory arthritis. *Arthritis Rheum* 2009;60:1042-51.
39. Vreju FA, Filippucci E, Gutierrez M, et al. Subclinical ultrasound synovitis in a particular joint is associated with ultrasound evidence of bone erosions in that same joint in rheumatoid patients in clinical remission. *Clin Exp Rheumatol* 2016;34:673-8.
40. Naredo E, Collado P, Cruz A, et al. Longitudinal power Doppler ultrasonographic assessment of joint inflammatory activity in early rheumatoid arthritis: predictive value in disease activity and radiologic progression. *Arthritis Rheum* 2007;57:116-24.
41. Cipolletta E, Smerilli G, Di Matteo A, et al. The sonographic identification of cortical bone interruptions in rheumatoid arthritis: a morphological approach. *Ther Adv Musculoskelet Dis* 2021;13:1759720X211004326.
42. Bond SJ, Farewell VT, Schentag CT, Gladman DD. Predictors for radiological damage in psoriatic arthritis: results from a single centre. *Ann Rheum Dis* 2007;66:370-6.
43. Filippucci E, Smerilli G, Di Matteo A, Grassi W. Ultrasound definition of enthesitis in spondyloarthritis and psoriatic arthritis: arrival or starting point? *Ann Rheum Dis* 2021;80:1373-75.
44. Smerilli G, Cipolletta E, Di Carlo M, Di Matteo A, Grassi W, Filippucci E. Power Doppler ultrasound assessment of A1 pulley. A new target of inflammation in psoriatic arthritis? *Front Med* 2020;7:204.
45. Smerilli G, Di Matteo A, Cipolletta E, Grassi W, Filippucci E. Enthesitis in psoriatic arthritis, the sonographic perspective. *Curr Rheumatol Rep* 2021;23:75.