

Images in Rheumatology

Cystic Ganglionosis in a 3-year-old Mimicking Juvenile Idiopathic Arthritis

Marcela Edith Perez Acosta, MD, Rheumatology Fellow, University of Central Florida, Orlando, Florida; Arthur B. Meyers, MD, Cincinnati Children's Hospital, Department of Radiology Cincinnati, Ohio; Mary Bratovich Toth, MD, Division Chief, Rheumatology, Nemours Children's Hospital, Orlando, Florida, USA. Address correspondence to Dr. M.B. Toth, 6535 Nemours Pkwy, Orlando, FL 32827, USA. Email: Mary.Toth@nemours.org. The authors declare no conflicts of interest relevant to this article. Written consent to publish the case was obtained from the patient's family. Case reports do not require IRB approval according to the authors' institutions.

Ganglion cysts are common periarticular/peritendinous masses, which are thought to form from myxoid degeneration of collagen that becomes encased by connective tissue.¹ This differentiates them from synovial cysts, which are lined by synovium.^{2,3} The presence of numerous ganglion cysts in multiple locations is very rare and has been termed *cystic ganglionosis*.⁴

A 3-year-old male was referred with concern for juvenile idiopathic arthritis (JIA). Brain magnetic resonance imaging, performed for unrelated reasons, showed cystic lesions at the temporomandibular joints (TMJs) and atlantoaxial articulations, suggestive of joint effusions (Figure 1).

Clinical history was negative for joint pain or swelling, and family history was negative for rheumatologic conditions. His musculoskeletal examination was normal. A complete blood count was normal, and he was negative for antinuclear antibodies and rheumatoid factor. An alternative diagnosis of cystic ganglionosis was considered due to the lack of rheumatologic findings. Ultrasound of the hands/wrists was performed to screen for other lesions and showed multiple asymptomatic ganglion cysts (Figure 2). During the follow-up period, the patient has remained asymptomatic without treatment.

We found only 4 other case reports of cystic ganglionosis, 3 of

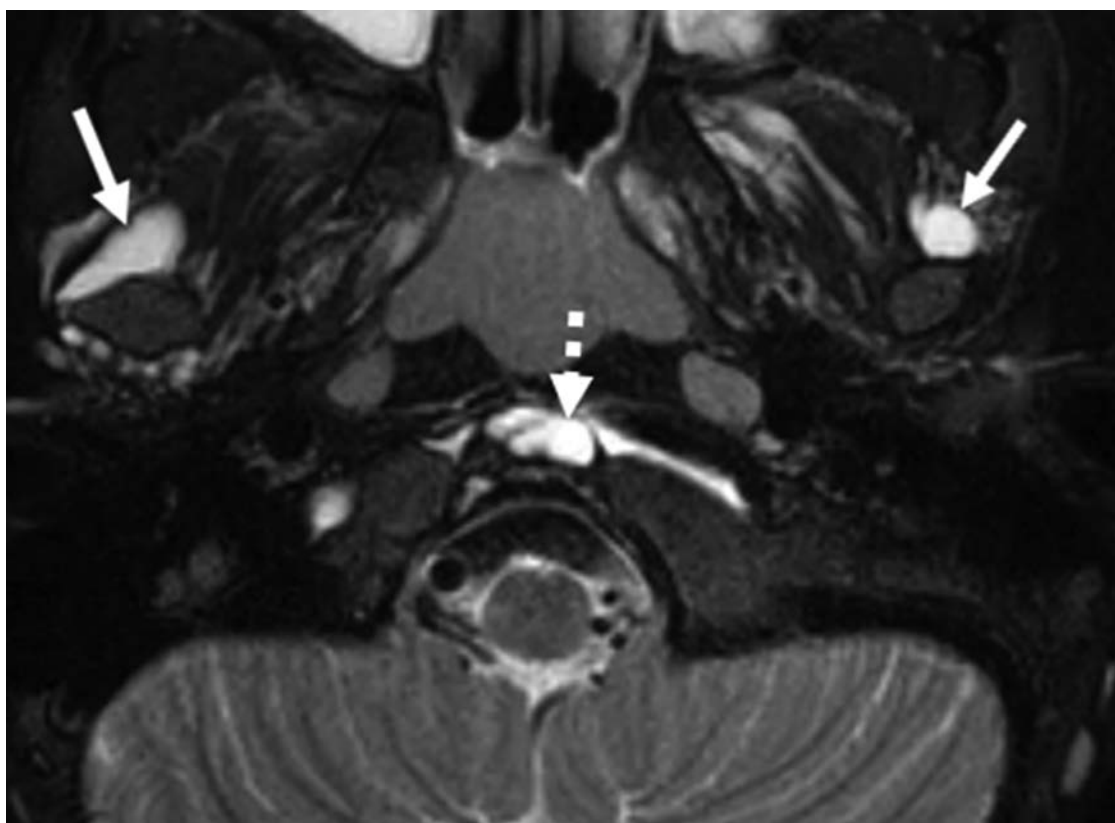


Figure 1. MRI obtained when the child was 3 years old. Axial T2-weighted MRI image shows cystic lesions at the atlanto-dens articulation (dashed arrow) and adjacent to the bilateral TMJs (solid arrows). The lesions are bright signal intensity on this T2-weighted image and showed only rim enhancement on postcontrast images (not shown). MRI: magnetic resonance imaging; TMJ: temporomandibular joint.

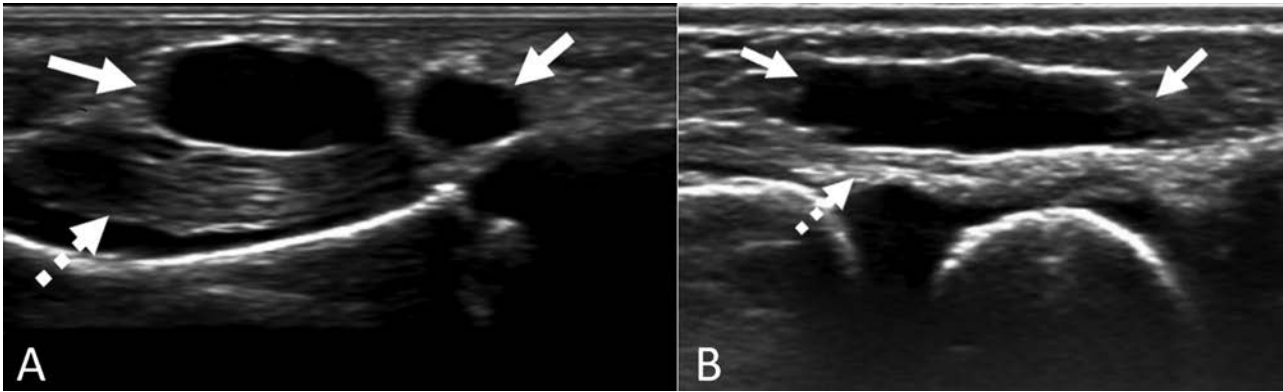


Figure 2. Images from bilateral wrist and hand ultrasound. (A) There is a bilobed 10-mm simple cystic lesion (solid arrow) in the palmar aspect of the left hand along the 5th flexor tendon (dashed arrow). (B) In the dorsal aspect of the right wrist, there is a 17-mm cystic lesion (solid arrow) along the extensor tendons (dashed arrow). Both these lesions were confirmed on a second plane. Similar, multiple lesions were present (not shown).

which were on children.^{5,6,7} Management is usually conservative unless a lesion is symptomatic. This case highlights that cystic ganglionosis can mimic joint effusions in small joints such as the TMJs, leading to concern for JIA, which was also a diagnostic consideration in another report of cystic ganglionosis.⁵ The detection of numerous ganglion cysts and absence of other findings of arthritis should lead to the consideration of cystic ganglionosis to avoid unnecessary treatment.

REFERENCES

1. Soren A. Pathogenesis, clinic, and treatment of ganglion. *Arch Orthop Trauma Surg* 1982;99:247-52.
2. O'Valle F, Hernández-Cortés P, Aneiros-Fernández J, et al. Morphological and immunohistochemical evaluation of ganglion cysts. Cross-sectional study of 354 cases. *Histol Histopathol* 2014;29:601-7.
3. Giard MC, Pineda C. Ganglion cyst versus synovial cyst? Ultrasound characteristics through a review of the literature. *Rheumatol Int* 2015;35:597-605.
4. Shinawi M, Hicks J, Guillerman RP, Jones J, Brandt M, Perez M, et al. Multiple ganglion cysts ('cystic ganglionosis'): an unusual presentation in a child. *Scand J Rheumatol* 2007;36:145-8.
5. Meyer NP, Meyers AB, Szabo S, Vo NJ. A rare case of cystic ganglionosis in a child with associated imaging findings. *Skeletal Radiol* 2016;45:419-26.
6. MacMahon J, Carter MJ, Moore M, McSweeney N. Cystic ganglionosis in an 18-month-old child. *Arch Dis Child* 2020;105:86.
7. Rao A, Nandikoor S, Mallarajapatna G, Meghanathan P. Unusual presentation of an usual condition-cystic ganglionosis. *BJR Case Rep* 2015;2:20150231.