

## Images in Rheumatology

# A Case of Chilblains-like Lesions Post SARS-CoV-2 Vaccine?

Alexa Simon Meara, MD, MS, Molly Silkowski, MD, Kai Quin, MD, Wael Jarjour, MD, The Ohio State University Wexner Medical Center, Columbus, Ohio, USA. Address correspondence to Dr. A.S. Meara, Assistant Professor, Division of Rheumatology and Immunology, The Ohio State University Wexner Medical Center, 480 Medical Center Drive, Davis Building, Suite 2058, Columbus, OH 43210, USA. Email: [Alexa.meara@osumc.edu](mailto:Alexa.meara@osumc.edu). The authors declare no conflicts of interest. The patient's written informed consent to publish the material was obtained. No institutional review board approval was required according to the authors' institution.

SARS-CoV-2 has been described to cause "COVID [coronavirus disease] toes," a chilblains-like syndrome.<sup>1,2,3</sup>

A 33-year-old White woman was evaluated in the hospital for painful new-onset blue and purple nodules on the tips of 3 fingers and 2 toes, 7 days after receiving the Moderna SARS-CoV-2 vaccine (Figure 1). She was admitted to the hospital for evaluation and her SARS-CoV-2 PCR was negative twice. She had no fevers, chest pain, myalgias or arthralgias, or shortness of breath. Her past medical history is notable only for mild persistent asthma, for which she uses an inhaled corticosteroid. She had no personal or family history of autoimmune disease. She continued to have normal blood work with negative inflammatory markers and autoimmune serologies. Skin biopsies (Figure 2) were obtained from the left thumb and right index finger showing the following on histopathology review: "Superficial and mid-dermal perivascular cuffed lymphocytic infiltrate. Mild superficial dermal edema is present. No interface changes are present. There is no evidence of vasculitis or vasculopathy. Initial and multiple deeper sections were examined. Direct immunofluorescence of the skin showed no specific immunoreactants detected."

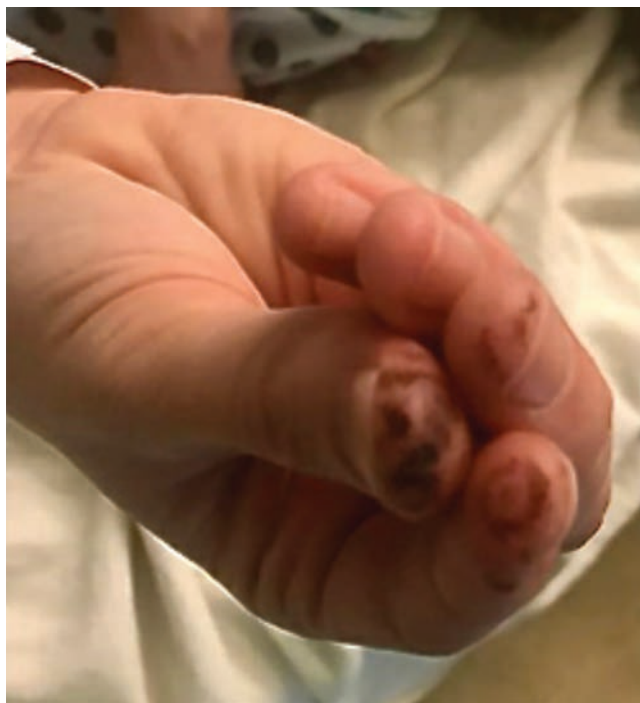


Figure 1. The 3 fingers affected, showing chilblains-like lesions.

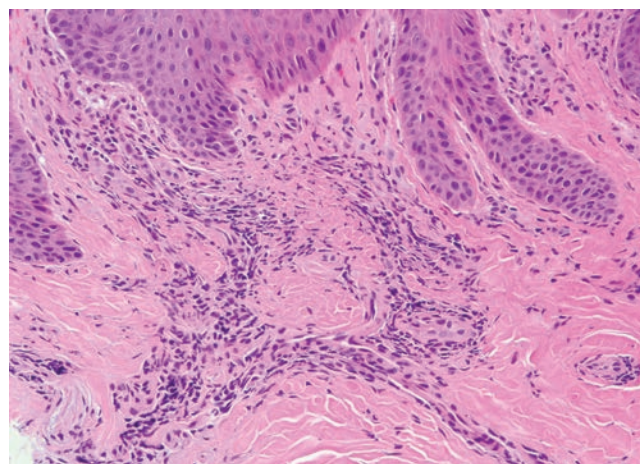


Figure 2. Histopathologic sections from a punch biopsy of a representative area demonstrate a superficial and deep perivascular lymphocytic infiltrate, characteristic of perniosis (H&E 200×).

The patient presented with symptoms similar to chilblains, a lymphocytic dermatitis. Her fingers healed, and she has weaned off the corticosteroids. She will not get the second vaccine dose; however, she did have positive COVID-19 IgGs present 1 month post vaccine. The chilblains-like lesions suggest that she had an antibody response from either 1 vaccine dose or a previous PCR-negative COVID-19 infection.<sup>4</sup> The understanding of the SARS-CoV-2 virus and the vaccines against it is a rapidly evolving landscape.<sup>5</sup>

## REFERENCES

1. Kanitakis J, Lesort C, Danset M, Jullien D. Chilblain-like acral lesions during the COVID-19 pandemic ("COVID toes"): histologic, immunofluorescence, and immunohistochemical study of 17 cases. *J Am Acad Dermatol* 2020;83:870-5.
2. Sachdeva M, Gianotti R, Shah M, Bradanini L, Tosi D, Veraldi S, et al. Cutaneous manifestations of COVID-19: report of three cases and a review of literature. *J Dermatol Sci* 2020;98:75-81.
3. Piccolo V, Bassi A. Acral findings during the COVID-19 outbreak: chilblain-like lesions should be preferred to acroischemic lesions. *J Am Acad Dermatol* 2020;83:e231.
4. Davido B, Mascitti H, Fortier-Beaulieu M, Jaffal K, de Truchis P. 'Blue toes' following vaccination with the BNT162b2 mRNA COVID-19 vaccine. *J Travel Med* 2021 Feb 23 (E-pub ahead of print).
5. Rodríguez Y, Novelli L, Rojas M, De Santis M, Acosta-Ampudia Y, Monsalve DM, et al. Autoinflammatory and autoimmune conditions at the crossroad of COVID-19. *J Autoimmun* 2020;114:102506.