

Follow-up Contrast-Enhanced Ultrasonography of the Carotid Artery in Patients With Takayasu Arteritis: A Retrospective Study

Jin Ding¹ , Dangjie Wu², Qing Han¹ , Kui Zhang¹, Zhaohui Zheng¹, and Ping Zhu¹ 

ABSTRACT. Objective. The literature describing follow-up carotid contrast-enhanced ultrasonography (CEUS) is limited. We report our experience with monitoring CEUS that is performed in patients with Takayasu arteritis (TAK).

Methods. We retrospectively analyzed patients with TAK who had undergone carotid CEUS 2 or more times with a follow-up duration of 12 or more months at Xijing Hospital between 2017 and 2020. We described how CEUS interpretation changed, and we recorded the state of remission (ie, bilateral CEUS visual grades ≤ 1) or relapse as determined by imaging.

Results. In total, 106 patients with TAK and 425 CEUS visits were included in the study; the median follow-up was 25 (IQR 18–30) months. The CEUS vascularization grade was significantly associated with the Kerr criteria ($r = 0.532$, $P < 0.001$), erythrocyte sedimentation rate ($P < 0.001$), and C-reactive protein level ($P < 0.001$). At baseline, 76 patients (71.7%) had active disease as determined by CEUS and 30 (28.3%) had inactive disease. The midterm assessment (median 13, IQR 10–16 months) showed that 29 out of 76 CEUS-active patients (38.2%) achieved complete response, 34 (44.7%) achieved partial response, and 13 (17.1%) did not respond. At the last visit, the total number of responders was 78 out of 94 (83.0%). CEUS relapse was observed in 28 out of 57 (49.1%) patients, with a median of 16 (IQR 10–21) months. The Kaplan-Meier curve demonstrated that the remission rate evaluated by the CEUS-combined method (median 22 months) was lower than that of the clinical-only evaluation (median 11 months; $P < 0.001$).

Conclusion. Response or relapse according to CEUS was detected in most patients during follow-up. CEUS is an effective technique for detecting carotid artery inflammation in patients with TAK.

Key Indexing Terms: contrast-enhanced ultrasonography, follow-up, retrospective study, Takayasu arteritis

Takayasu arteritis (TAK) is a chronic inflammatory disease that primarily involves the aorta and its major branches.¹ It has a higher prevalence in individuals from Southeast Asia.² In China, the peak prevalence of TAK in Shanghai is 7.01 cases per million, with a mean annual incidence of 2.33 cases per million, which is higher than that in some Western countries.³ TAK can lead to organ ischemia and damage resulting from stenosis, aneurysm, or

occlusion of vessels, although clinical symptoms are nonspecific and vary depending on the affected vessels.

Noninvasive imaging techniques, including ultrasonography, magnetic resonance imaging (MRI), computed tomography (CT), and ¹⁸F-fluorodeoxyglucose (FDG)-positron emission tomography (PET), are increasingly being used to diagnose and monitor the disease.^{4–6} The European Alliance of Associations for Rheumatology recommends noninvasive imaging techniques to be used as the first or alternative imaging test to diagnose TAK.⁴ However, the role of imaging in determining disease activity remains unknown. MRI and PET are promising for assessing disease activity over clinical and laboratory assessments alone,^{5,7} but radiation exposure, restricted availability, and high cost limit their use in routine clinical practice for follow-up.

Carotid contrast-enhanced ultrasonography (CEUS), a method of quantifying vascularization within the vessel wall,⁸ allows for the dynamic assessment of carotid wall vascularization. It is a potential marker of disease activity in patients with TAK.^{9,10} Increasing evidence has demonstrated that CEUS is an effective imaging technique for detecting carotid artery inflammation and can provide additional information on disease activity.^{11–14} Previously, we showed the correlation between CEUS vascularization and FDG-PET/CT uptake and supported the use of

This study has received funding from the Xijing Zhutui Project (XJZT19ML55) and the National Natural Science Foundation of China (Grant No: 81871273).

¹J. Ding, PhD, Q. Han, PhD, K. Zhang, PhD, Z. Zheng, PhD, P. Zhu, PhD, Department of Clinical Immunology, Xijing Hospital, Fourth Military Medical University; ²D. Wu, MS, Department of Ultrasound, Xijing Hospital, Fourth Military Medical University, Xi'an, Shaanxi, China.

J. Ding and D. Wu contributed equally to this work.

The authors declare no conflicts of interest relevant to this article.

Address correspondence to Dr. Z. Zheng, Department of Clinical Immunology, Xijing Hospital, Fourth Military Medical University, No. 127 Changle West Rd., Xi'an, Shaanxi 710032, China. Email: zhengzh@fmmu.edu.cn. Or P. Zhu, Department of Clinical Immunology, Xijing Hospital, Fourth Military Medical University, No. 127 Changle West Rd., Xi'an, Shaanxi 710032, China. Email: zhuping@fmmu.edu.cn.

Accepted for publication June 2, 2022.

CEUS to help clinicians identify active lesions in the carotid vascular region, especially for patients with TAK whose disease is clinically inactive.¹⁵

The role of CEUS in the assessment of disease activity during follow-up has not been investigated, and the related literature is limited. There is substantial uncertainty about whether CEUS might be helpful in monitoring disease activity and how often CEUS should be performed as part of a routine surveillance protocol. Therefore, we report our experience with follow-up CEUS performed in patients with TAK.

METHODS

Ethics statements. The Ethics Committee of Xijing Hospital approved this study (approval number: KY20163015-1). All patients provided written informed consent prior to participation.

Study design and patients. We conducted a retrospective study at a large center in Xijing Hospital. In total, 313 patients with TAK who attended our outpatient and inpatient services from January 2017 to November 2020 and fulfilled the TAK criteria from the American College of Rheumatology were included in the study.¹ Patients with no carotid artery and/or subclavian artery involvement or no long-term follow-up information were excluded.

Data collection. Demographics; clinical information, including symptoms and results of physical examinations; and angiographic features were recorded. Laboratory test results, including complete blood count, C-reactive protein (CRP) level, erythrocyte sedimentation rate (ESR), and serum amyloid A protein (SAA) level, were also extracted from the patients' electronic medical records. An elevated inflammatory marker was defined as CRP > 5 mg/L, ESR > 15 mm/h (for males) or > 20 mm/h (for females), or SAA > 10 mg/L.

Acquisition and analysis of carotid CEUS. Acquisition and analysis of carotid CEUS were performed as previously described.¹⁵ Carotid CEUS was performed with an iU22 device (Philips Medical Systems) equipped with an L9-3 transducer. The bilateral carotid arteries were examined, and the wall thickness of the carotid artery was measured as an image of intima-media thickness (IMT). CEUS was performed at the thickest site of the common carotid artery. All examinations were performed and evaluated by 2 expert sonographers who were blinded to the individual's clinical information. In case of a discrepancy, a final consensus was achieved by reviewing the video sequences and discussion. CEUS clips of the carotid arteries were scored according to the extent of wall vascularization. Wall vascularization was visually estimated as follows: grade 0, no vascularization (no appearance of microbubble contrast agent in the carotid lesion); grade 1, limited vascularization (limited visualization of moving microbubbles in the carotid lesion); grade 2, moderate vascularization (moderate visualization of moving microbubbles in the carotid lesion); and grade 3, severe vascularization (extensive wall vascularization with microbubbles clearly seen).

Study definitions. TAK was categorized into 5 subtypes according to the Numano classification criteria based on angiographic findings.¹⁶ Patients with types 1, 2, and 5 were included in our study.

At each visit, disease activity was assessed based on symptom assessment, physical examination, and laboratory results. Clinical disease activity was evaluated using the modified National Institutes of Health criteria (ie, clinically active: ≥ 2 points; clinically inactive: < 2 points).¹⁷ This was assessed by 2 experienced rheumatologists who were blinded to the ultrasound results. Clinical remission was defined as satisfying all the following criteria: absence of all clinical signs and symptoms attributable to active TAK, normalization of ESR and CRP, and glucocorticoid (GC) dose ≤ 15 mg/day.

It is challenging to evaluate the disease status of patients with no symptoms; thus, in this study, we focused on the CEUS status of patients and evaluated the changes. The imaging activity of the disease was evaluated according to the CEUS results. If the visual grade of unilateral or bilateral

CEUS was ≥ 2 , the disease was defined as active. Imaging remission, or inactive status of the patients, was defined as a visual grade of ≤ 1 on bilateral CEUS. Changes in image activity according to CEUS were classified as follows:

1. Complete response (CR): the visual grades of bilateral CEUS improved from active to inactive status.
2. Partial response (PR): improvement in CEUS scores (ie, a decrease in the total CEUS score of ≥ 2 or a change from 3 to 2 for unilateral involvement, but not achieving an inactive status).
3. No response (NR): no change or a change of ≤ 1 in the total CEUS score, indicating an active status.
4. Stable: no change or a change of ≤ 1 in the total CEUS score, indicating an inactive status.
5. Relapse: visual grades of CEUS increased from inactive to active status.

Clinical remission combined with CEUS remission was defined as satisfying both clinical remission criteria and CEUS inactive status.

Data and statistical analyses. Demographic variables are shown as mean (SD) or median (IQR) wherever applicable. Categorical variables are expressed as number (%). Intergroup comparisons were performed using a nonparametric test—the Mann-Whitney *U* test—for continuous variables or chi-square test for categorical variables. Spearman rank correlation analysis was used to evaluate the correlation between the indices used for grading ultrasonography and clinical and laboratory variables. For CEUS-active patients, the difference in the remission rate between the clinical remission evaluation and the clinical remission combined with CEUS evaluation was compared using Kaplan-Meier survival curve analysis.

Statistical analyses were performed using SPSS software (version 22.0; IBM Corp.) and Prism (version 8.0; GraphPad Software, Inc). Statistical significance was set at $P < 0.05$.

RESULTS

Baseline demographics. In total, 106 patients who had undergone carotid CEUS 2 or more times with a follow-up duration of ≥ 12 months were included. Patients originated from China and were mostly of Han nationality (99.1%). Most patients ($n = 94$, 88.7%) were women. The clinical and demographic characteristics of patients with TAK are presented in the Table.

Based on a previous analysis and our experiences, we observed that the differences between grades 0 and 1 were minor, and both could be seen as an inactive status. Therefore, we consolidated them into 1 category. To compare the differences in carotid vascularization between the different types of TAK, we categorized the patients into 2 groups—types I and II vs type V—according to the Numano classification. Among 47 patients with types I and II disease, the proportions of patients with grades 0/1, 2, and 3 were 14 (29.8%), 13 (27.7%), and 20 (42.6%), respectively. Among 59 patients with type V disease, the proportions of patients with grades 0/1, 2, and 3 were 16 (27.1%), 28 (47.5%), and 15 (25.4%), respectively. There were no significant differences in the proportions among the groups ($P = 0.08$ for all).

At baseline, 76 patients (71.7%) had CEUS-active disease, while 30 had an inactive status (Figure 1). Among the CEUS-inactive patients, only 3 showed signs of clinically active disease (all type V). However, in the CEUS-active group, 12 patients showed no signs of clinical disease activity. The analysis showed that there were no significant differences in sex, disease duration, type of arterial lesions, Numano classification, and treatment

Table. Clinical characteristics of patients with Takayasu arteritis at baseline.

| | n = 106 |
|--|--------------------|
| Age, yrs, median (IQR) | 31 (25.75-41.00) |
| Age at disease onset, yrs, median (IQR) | 25 (20.25-31.75) |
| Disease duration, yrs, median (IQR) | 4.0 (1.25-9.00) |
| Female | 94 (88.7) |
| Newly diagnosed | 47 (44.3) |
| Numano classification | |
| I | 23 (21.7) |
| IIA | 9 (8.5) |
| IIB | 15 (14.2) |
| V | 59 (55.7) |
| Arterial hypertension | 40 (37.7) |
| Involvement of renal artery | 29 (27.4) |
| Involvement of pulmonary artery | 20 (18.9) |
| CEUS level at baseline | |
| Grade 1 (including 0) | 30 (28.3) |
| Grade 2 | 41 (38.7) |
| Grade 3 | 35 (33.0) |
| Carotid arterial wall thickness, mm, mean (SD) | 2.0 (0.6) |
| ESR, mm/h, median (IQR) | 10 (5-20) |
| Increased level of ESR | 37 (34.9) |
| CRP, mg/L, median (IQR) | 3.20 (1.98-7.58) |
| Increased level of CRP | 37 (34.9) |
| SAA, mg/L, median (IQR) | 13.05 (3.57-41.10) |
| Increased level of SAA | 43 (40.6) |
| Treatment | |
| Prednisone | 102 (96.2) |
| Prednisone dose, mg, median (IQR) | 20 (10-40) |
| Cyclophosphamide | 29 (27.4) |
| Mycophenolate mofetil | 21 (19.8) |
| Methotrexate | 43 (40.6) |
| Leflunomide | 23 (21.7) |
| Tocilizumab | 18 (17.0) |
| 1 DMARD | 74 (69.8) |
| ≥ 2 DMARDs | 30 (28.3) |

Data are in n (%) unless otherwise indicated. CEUS: contrast-enhanced ultrasonography; CRP: C-reactive protein; DMARD: disease-modifying antirheumatic drug; ESR: erythrocyte sedimentation rate; SAA: serum amyloid A protein.

between these 2 groups ($P > 0.05$ for all). The Mann-Whitney U tests showed that the active group was younger in age (median 29.50, IQR 25.00-37.75 years) than the inactive group (median 35.50, IQR 28.75-46.00 years; $P = 0.007$) and that the active group had a lower age at disease onset (median 24.00, IQR 19.00-30.00 years) than the inactive group (median 30, IQR 24.00-36.50 years; $P = 0.004$).

Correlation of clinical activity and imaging activity. This study included 425 CEUS visits from 106 patients. Among them, 65 patients (61.3%) had ≥ 3 CEUS evaluations, with a median of 4 (IQR 3-5) visits; 35 patients (33.0%) had ≥ 5 CEUS evaluations, with a maximum of 9 CEUS evaluations. Overall, 158 out of 425 visit results (37.2%) indicated grade 0/1, 184 (43.3%) indicated grade 2, and 83 (19.5%) indicated grade 3. The correlation analysis showed that the vascularization grade determined using CEUS was significantly associated with the Kerr criteria ($r = 0.532$, $P < 0.001$), ESR ($r = 0.306$, $P < 0.001$),

and CRP ($r = 0.286$, $P < 0.001$). ESR, CRP, and SAA values were significantly higher in CEUS-active patients, especially in the grade 3 group, than in the CEUS-inactive patients (Figure 2). A significant correlation between IMT and CEUS grading ($r = 0.480$, $P < 0.001$) was also observed. The patients with CEUS-active disease had a significantly higher IMT (grade 3: mean 2.4, SD 0.5 mm; grade 2: mean 2.0, SD 0.6 mm) compared to inactive patients (grade 0/1: mean 1.6, SD 0.5 mm; $P < 0.001$).

CEUS outcome during follow-up. The median time between the initial and last follow-up was 25 (IQR 18-30) months (maximum 44 months), with 54 out of 106 patients (50.9%) being followed up for 24 or more months. For the 76 CEUS-active patients, at the midterm assessment (median 13, IQR 10-16 months), 29 of them (38.2%) achieved CR, while 34 (44.7%) patients had a PR (Figure 1). During further follow-up (median 26, IQR 20-31 months), 17 out of the 29 initial patients (58.6%) who achieved CR maintained their CR status until their last visit, while 6 patients in the initial PR group achieved CR. Among the total patients who achieved CR ($n = 45$), the median time to response was 11 (IQR 8-17.5) months (minimum 2 and maximum 37 months), with 27 (60%) patients responding before 12 months follow-up and 7 (15.6%) responding after 24 months. CR confirmed by CEUS was found in many patients ($n = 21$) who had been examined 1 to 3 times, and no changes were seen before. For the responders, there was a significant decrease in IMT after treatment (mean 2.1, SD 0.6 mm vs mean 1.7, SD 0.5 mm; $P < 0.001$). Meanwhile, in the NR group, there was no significant change in IMT (mean 2.3, SD 0.5 mm vs mean 2.3, SD 0.6 mm; $P = 0.73$).

Relapse of disease detected by CEUS was observed in 28 out of 57 patients (49.1%)—including the initial CR group (10/27, 37.0%) and the inactive group (18/30, 60%)—with a median time to relapse of 16 (IQR 10-21) months (minimum 3 months). Among them, most (18/28, 64.3%) experienced relapse after 12 months of follow-up, and only 10 (35.7%) experienced relapse before 12 months. Only 1 patient in the inactive group died of gastrointestinal hemorrhage at month 28 of follow-up. Among the inactive and CR groups, 16 patients maintained a stable status for more than 2 years.

We found that for 33 patients with type I and II disease in the CEUS-active group, 28 (84.8%) of them—including 10 (35.7%) in the CR group and 18 (64.3%) in the PR group—responded by the midterm assessment, and 3 patients had CEUS relapse. There were 35 responders out of 43 (81.4%)—including 19 (54.3%) in the CR group and 16 (45.7%) in the PR group—and 7 patients who relapsed among the CEUS-active patients with type V disease. In the CEUS-inactive group, 57.1% (8/14) with types I and II disease and 62.5% (10/16) with type V disease experienced relapse. There were no significant differences in the response and relapse rates between the 2 groups ($P > 0.05$). Of the 13 nonresponders, there were 8 patients with type V disease.

Imaging activity status at various time intervals of the follow-up. Each change in the CEUS activity status during all time intervals of the follow-up was evaluated (Figure 3). For patients who underwent CEUS at intervals of 3 months, we found that 75.0% (24/32) had no changes in grade. Therefore, we calculated the

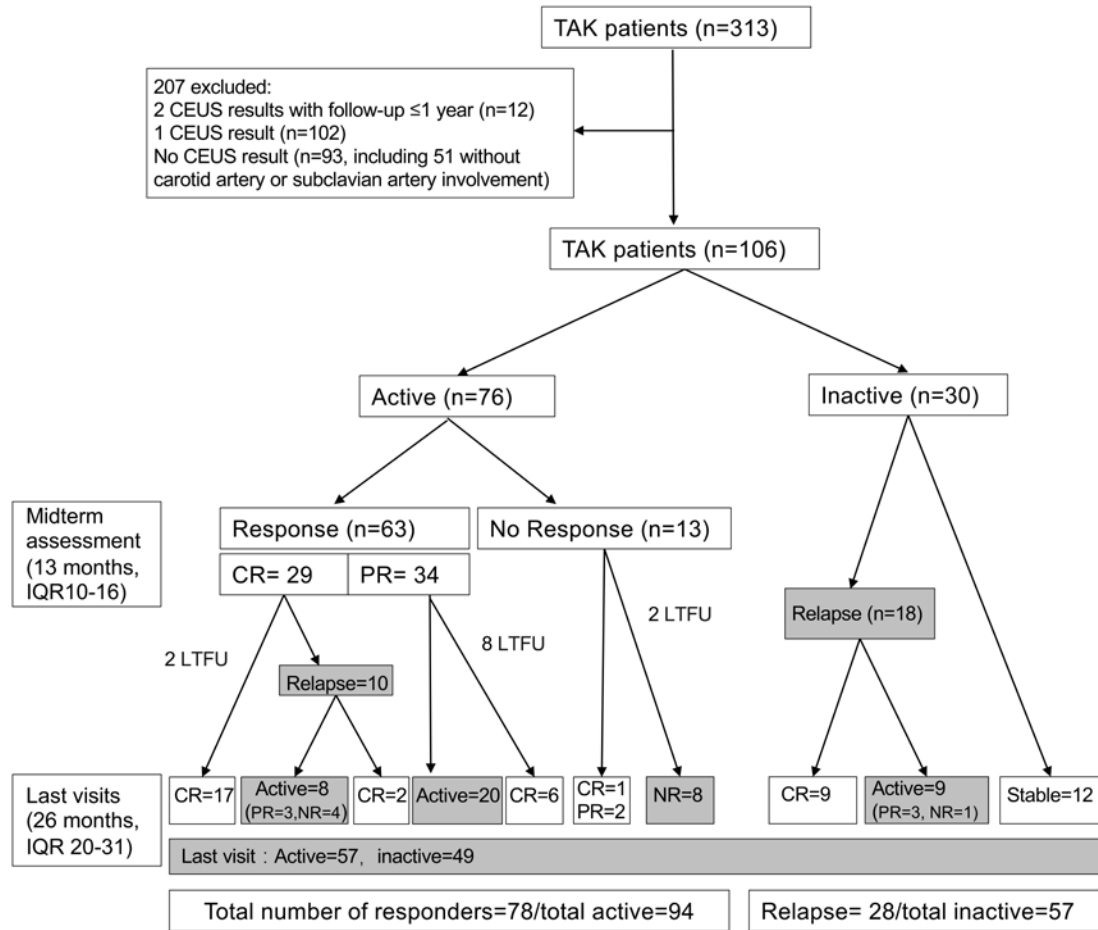


Figure 1. CEUS-evaluated outcome of patients with Takayasu arteritis. CEUS: contrast-enhanced ultrasonography; CR: complete response; LTFU: lost to follow-up; NR: no response; PR: partial response; TAK: Takayasu arteritis.

changes at intervals of every 6 months. At the time interval of 2 to 6 months, 40.3% of patients had NR, while 21.7% and 17.1% had PR and CR, respectively. Although there were no differences between time intervals regarding the percentage of patients with each CEUS activity status, the percentage of patients with NR was lower in the 19- to 24-month group (28.4%) than in the other groups. In addition, the percentages of patients with increased activity (10.9%), including relapse or increase of grade from low-level to high-level activity, and a stable status (10.1%) were lower in the 2- to 6-month group than in the other groups.

During the follow-up, there were 94 active patients: 76 in the active group and 18 in the inactive group who relapsed. After excluding 3 patients from the relapse group who had no follow-up records, 91 patients were studied. We compared the differences in the remission rate between the 2 methods used to evaluate remission. Among these patients, 76 had achieved clinical remission, whereas with the CEUS-combined method, only 52 had reached remission status. The median remission time of the clinical-only evaluation was 11 (IQR 7-18) months, while that of the CEUS-combined method was 22 (IQR 12-26) months. The survival curve demonstrated that the remission rate of the CEUS-combined method was lower than that of the clinical-only evaluation ($P < 0.001$; Figure 4).

DISCUSSION

This is the largest study to date that assesses follow-up outcomes of patients with TAK based on CEUS, to our knowledge. We confirmed that the vascularization grade determined by CEUS was significantly associated with disease activity indices, including the Kerr criteria score, ESR, and CRP. At a median follow-up of 25 months, most patients with active disease responded to CEUS evaluation, while relapse was observed in half of the patients with a median time to relapse of 16 months. Moreover, the remission rate of the combined CEUS evaluation was lower than that of the clinical-only evaluation.

Accurate assessment and close monitoring of disease activity are critical because untreated inflammation can result in irreversible damage to the large arteries and require intensive treatment during the active periods.¹⁸ To date, it is challenging to evaluate disease activity because symptoms, physical examination findings, and laboratory variables may not reliably reflect vascular inflammation.^{13,17,19} Carotid CEUS may be a reliable and valuable tool for evaluating disease activity in TAK.¹¹⁻¹⁵ This study provides further evidence of CEUS as a helpful method that allows dynamic assessment of carotid wall vascularization, a potential marker of disease activity in patients with TAK.

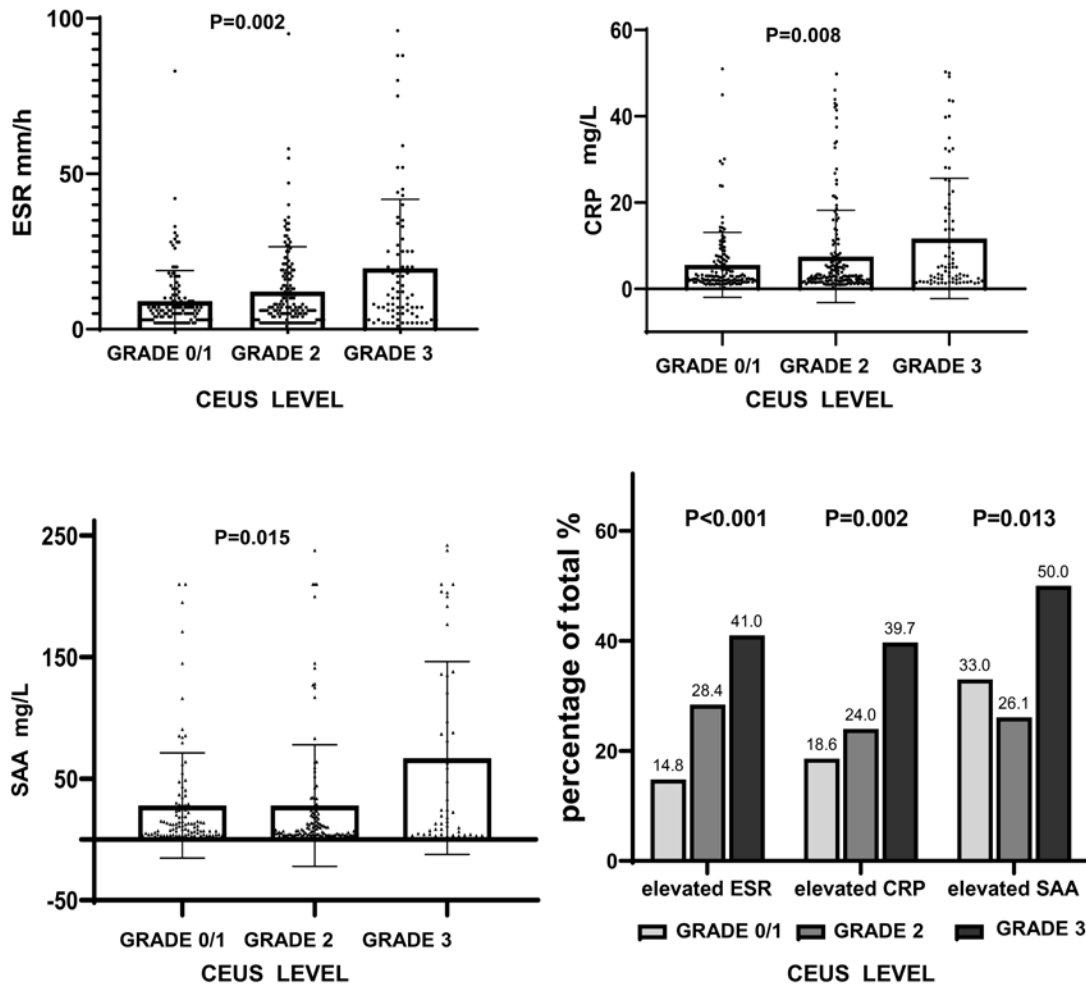


Figure 2. ESR, CRP, and SAA levels in patients with different carotid CEUS grades. CEUS: contrast-enhanced ultrasonography; CRP: C-reactive protein; ESR: erythrocyte sedimentation rate; SAA: serum amyloid A protein.

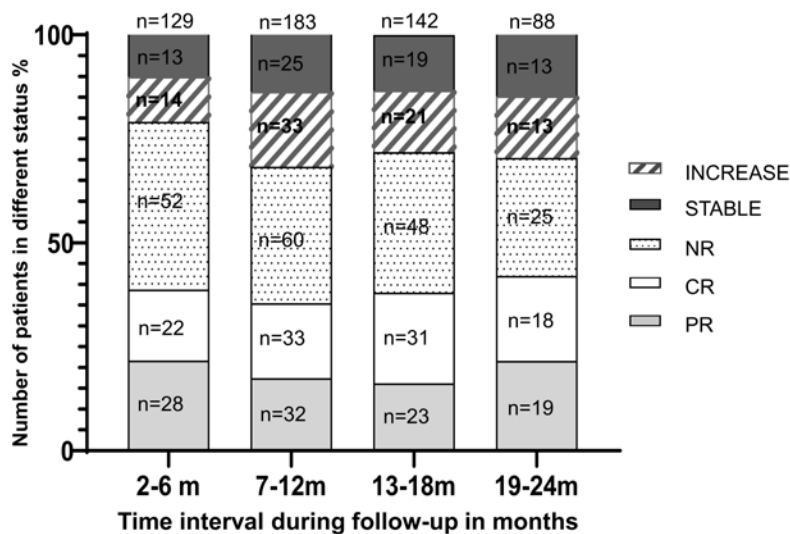


Figure 3. Carotid CEUS activity status of patients at various time intervals of follow-up (months). CEUS: contrast-enhanced ultrasonography; CR: complete response; PR: partial response; NR: no response; Increase: including relapse or increase of grades from low-level to high-level activity.

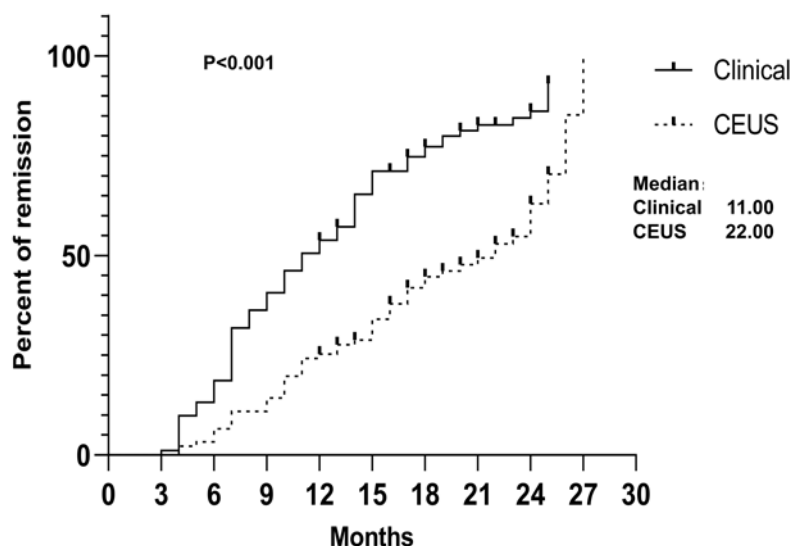


Figure 4. Remission rate of active patients evaluated by clinical and CEUS-combined methods. Kaplan-Meier curves show the difference between clinical remission alone and clinical remission combined with CEUS remission. CEUS: contrast-enhanced ultrasonography.

Only very limited experience with CEUS in the follow-up of TAK has been reported so far. In a single TAK case, a decrease of inflammation of the carotid arterial wall after steroid treatment evaluated by CEUS has been observed.¹⁰ Ma et al¹⁴ studied 38 patients who completed a 3-month follow-up. They found that the proportion of severe vascularization decreased from 52.6% to 34.3%. Neovascularization can still be observed in the vascular lesion sites of patients who have reached clinical remission after treatment. Compared to Ma et al's study, our study included many more patients with a much longer follow-up period with different visit intervals. We demonstrated consistent results showing that patients with active vascularization as determined by CEUS could achieve partial or complete remission to an inactive status. Additionally, relapses reflected by an increase in the CEUS grade were observed in 49.1% of the patients who had already attained remission before. Most relapses confirmed by imaging were in accordance with clinical relapses of patients who needed treatment escalation. Hence, CEUS is a sensitive method to monitor disease activity and guide treatment for patients with TAK.

There are no data available to guide the long-term follow-up of patients with TAK. Routine imaging for disease activity assessment is not recommended for patients in clinical and serological remission.²⁰ However, patients with large-vessel vasculitis may develop new arterial lesions on vascular imaging during periods of apparent clinical remission. Image detection may be more sensitive than clinical and laboratory variables and may predict clinical relapse and angiographic progression of the disease.¹⁸ Kenar et al²¹ and Dua et al²² also suggested that imaging is the major determinant and should be included in the regular scheduled assessment of disease activity. When clinical and laboratory results are inconclusive, imaging may be used to decide whether to change treatment.⁴ Because of the limitations, it is not possible to perform PET, MRI, or magnetic resonance angiography (MRA) examinations at every scheduled 6-month or 1-year interval. According to our results, CEUS is

sensitive to detecting worsening or improving disease, and it can be used as a critical alternate method to monitor disease activity. Moreover, the patients at our center had good compliance with CEUS. Nearly one-third of the patients had 5 or more CEUS examinations during the entire follow-up period. By comparing changes in CEUS at different time intervals, we discovered that conducting CEUS at 6-month intervals may be reasonable and sensitive to changes. Several advantages of CEUS, including the low cost, rapid and repetitive availability, lack of radiation exposure, and not using iodine-containing contrast agents,^{19,23} may be why it has great potential for application in clinical long-term follow-up practice.

To date, high-quality evidence to guide TAK treatment has not been found.^{22,24} A systematic review and metaanalysis showed that non-GC drugs were moderately effective in inducing remission in TAK, and pooled remission rates ranged from 58% to 64%.²⁵ In a long-term outcome study, complete remission was observed in 68.9% of patients, PR was observed in 16.7% of patients, and NR was observed in only 14% of patients at the first follow-up.²⁶ The CR rate of our patients was lower (38.2%) at a median follow-up of 13 months. The Kaplan-Meier survival curve showed that the remission rate of the CEUS-combined method was lower than that of the clinical-only evaluation. It is possible that the recovery of vascular inflammation would be slower than the recovery of the clinical signs, and discordance between symptoms and imaging abnormalities may exist. Several histopathologic studies have demonstrated active ongoing inflammation of arteries in > 40% of patients who were thought to be in clinical remission.^{17,21,27,28} Additionally, previous reports have detected persistent disease activity as detected by FDG-PET and MRA during periods of clinical remission in many patients, supporting this potential discordance.^{29,30} Therefore, the response as detected by CEUS may be closer to the local histological response of vasculitis.

Previous reports have demonstrated that the cumulative

relapse rate of TAK varies from 27% to 96%.^{17,26,31,32} Data from 318 European patients with TAK showed that 42% of patients experienced their first relapse during the first 5 years.³³ Another study demonstrated that at least 1 relapse was observed in 46% of patients at the 5-year follow-up, and the median time to relapse was 7.8 months.³² The relapse rate detected by CEUS in our study is similar to those in the previously mentioned studies, with a median time to relapse of 16 months. For patients, especially those without clinical symptoms, high-grade carotid wall neovascularization, especially grade 3, as detected by CEUS could provide important clues of disease relapse and alert physicians to order a further detailed and comprehensive examination using FDG-PET or MRI/MRA.

The main disadvantage of CEUS is that it investigates only a limited number of vessels, which restricts its application to a subset of patients and overlooks other active arterial segments.³⁴ Although the frequency of different TAK types differs between races and regions, the involvement of the carotid arteries is common. A study of 411 Chinese patients with TAK showed that subclavian arteries (79.8%) and carotid arteries (79.1%) were the most frequently involved arteries.³⁵ In our cohort, carotid artery involvement was the most common. Our results showed that CEUS was sensitive to changes in disease activity and relapse for types I, II, and V TAK. It was able to detect these cases whose disease activity may be underestimated. Undeniably, there was an inconsistency between CEUS activity and clinical activity, especially in patients with type V TAK. At the individual level, if the patients have strong evidence of clinical activity with no signs of CEUS activity, it is recommended to perform other imaging techniques. Nonetheless, for most patients with TAK, CEUS could be a valuable complementary tool for evaluating vascular inflammation.

There are some limitations to our study. First, our analysis was performed as a retrospective review at a single center. Prospective enrollment and data collection would have been ideal; however, they are challenging to achieve with such rare diseases. Second, because the personalized treatment strategy varied significantly, we did not analyze the prognostic factors, including treatments associated with the imaging outcome of patients. Regardless of the different treatment methods, we could still acquire the overall outcome schema of patients in the real world. Finally, CEUS requires qualified professionals to manually select the regions and analyze the images. It may have interoperator variability, which hinders its application in comparative quantification of vasculitis for large-scale multicenter studies. Similar to Pereira et al's study,³⁶ future studies need to explore the development of new methods that can speed up image analysis and eliminate user subjectivity.

In conclusion, CEUS evaluation is sensitive to changes in disease activity during follow-up for most patients with TAK. It may be an effective technique for detecting carotid artery inflammation and monitoring therapeutic interventions in these patients.

REFERENCES

1. Arend WP, Michel BA, Bloch DA, et al. The American College

- of Rheumatology 1990 criteria for the classification of Takayasu arteritis. *Arthritis Rheum* 1990;33:1129-34.
2. Watts RA, Hatemi G, Burns JC, Mohammad AJ. Global epidemiology of vasculitis. *Nat Rev Rheumatol* 2022;18:22-34.
3. Sun Y, Yin MM, Ma LL, et al. Epidemiology of Takayasu arteritis in Shanghai: a hospital-based study and systematic review. *Int J Rheum Dis* 2021;24:1247-56.
4. Dejaco C, Ramiro S, Duftner C, et al. EULAR recommendations for the use of imaging in large vessel vasculitis in clinical practice. *Ann Rheum Dis* 2018;77:636-43.
5. Direskeneli H. Clinical assessment in Takayasu's arteritis: major challenges and controversies. *Clin Exp Rheumatol* 2017;35:189-93.
6. Esatoglu SN, Hatemi G. Takayasu arteritis. *Curr Opin Rheumatol* 2022;34:18-24.
7. Sun Y, Huang Q, Jiang L. Radiology and biomarkers in assessing disease activity in Takayasu arteritis. *Int J Rheum Dis* 2019;22:53-9.
8. Feinstein SB, Coll B, Staub D, et al. Contrast enhanced ultrasound imaging. *J Nucl Cardiol* 2010;17:106-15.
9. Schinkel AFL, van den Oord SCH, van der Steen AFW, van Laar JAM, Sijbrands EJG. Utility of contrast-enhanced ultrasound for the assessment of the carotid artery wall in patients with Takayasu or giant cell arteritis. *Eur Heart J Cardiovasc Imaging* 2014;15:541-6.
10. Giordana P, Baque-Juston MC, Jeandel PY, et al. Contrast-enhanced ultrasound of carotid artery wall in Takayasu disease: first evidence of application in diagnosis and monitoring of response to treatment. *Circulation* 2011;124:245-7.
11. Huang Y, Ma X, Li M, Dong H, Wan Y, Zhu J. Carotid contrast-enhanced ultrasonographic assessment of disease activity in Takayasu arteritis. *Eur Heart J Cardiovasc Imaging* 2019;20:789-95.
12. Wang Y, Wang YH, Tian XP, et al. Contrast-enhanced ultrasound for evaluating arteritis activity in Takayasu arteritis patients. *Clin Rheumatol* 2020;39:1229-35.
13. Germanò G, Macchioni P, Possemato N, et al. Contrast-enhanced ultrasound of the carotid artery in patients with large vessel vasculitis: correlation with positron emission tomography findings. *Arthritis Care Res* 2017;69:143-9.
14. Ma LY, Li CL, Ma LL, et al. Value of contrast-enhanced ultrasonography of the carotid artery for evaluating disease activity in Takayasu arteritis. *Arthritis Res Ther* 2019;21:24.
15. Li Z, Zheng ZH, Ding J, et al. Contrast-enhanced ultrasonography for monitoring arterial inflammation in Takayasu arteritis. *J Rheumatol* 2019;46:616-22.
16. Hata A, Noda M, Moriwaki R, Numano F. Angiographic findings of Takayasu arteritis: new classification. *Int J Cardiol* 1996;54:S155-63.
17. Kerr GS, Hallahan CW, Giordano J, et al. Takayasu arteritis. *Ann Intern Med* 1994;120:919-29.
18. Banerjee S, Quinn KA, Gribbons KB, et al. Effect of treatment on imaging, clinical, and serologic assessments of disease activity in large-vessel vasculitis. *J Rheumatol* 2020;47:99-107.
19. Lottspeich C, Dechant C, Köhler A, et al. Assessment of disease activity in Takayasu arteritis: potential role of contrast-enhanced ultrasound. *Ultraschall Med* 2019;40:638-45.
20. Hellmich B, Agueda A, Monti S, et al. 2018 Update of the EULAR recommendations for the management of large vessel vasculitis. *Ann Rheum Dis* 2020;79:19-30.
21. Kenar G, Karaman S, Çetin P, et al. Imaging is the major determinant in the assessment of disease activity in Takayasu's arteritis. *Clin Exp Rheumatol* 2020;38:55-60.
22. Dua AB, Kalor MA, Husainat NM, et al. Takayasu Arteritis: a systematic review and meta-analysis of test accuracy and benefits and harms of common treatments. *ACR Open Rheumatol* 2021;3:80-90.
23. Czihal M, Lottspeich C, Hoffmann U. Ultrasound imaging in the diagnosis of large vessel vasculitis. *Vasa* 2017;46:241-53.

24. Águeda AF, Monti S, Luqmani RA, et al. Management of Takayasu arteritis: a systematic literature review informing the 2018 update of the EULAR recommendation for the management of large vessel vasculitis. *RMD Open* 2019;5:e001020.
25. Barra L, Yang G, Pagnoux C, Canadian Vasculitis Network (CanVasc). Non-glucocorticoid drugs for the treatment of Takayasu's arteritis: a systematic review and meta-analysis. *Autoimmun Rev* 2018;17:683-93.
26. Goel R, Danda D, Joseph G, et al. Long-term outcome of 251 patients with Takayasu arteritis on combination immunosuppressant therapy: single centre experience from a large tertiary care teaching hospital in Southern India. *Semin Arthritis Rheum* 2018;47:718-26.
27. Salvarani C, Cantini F, Boiardi L, Hunder GG. Laboratory investigations useful in giant cell arteritis and Takayasu's arteritis. *Clin Exp Rheumatol* 2003;21:S23-8.
28. Miller DV, Maleszewski JJ. The pathology of large-vessel vasculitides. *Clin Exp Rheumatol* 2011;29:S92-8.
29. Michailidou D, Rosenblum JS, Rimland CA, Marko J, Ahlman MA, Grayson PC. Clinical symptoms and associated vascular imaging findings in Takayasu's arteritis compared to giant cell arteritis. *Ann Rheum Dis* 2020;79:262-7.
30. Quinn KA, Ahlman MA, Malayeri AA, et al. Comparison of magnetic resonance angiography and ¹⁸F-fluorodeoxyglucose positron emission tomography in large-vessel vasculitis. *Ann Rheum Dis* 2018;77:1165-71.
31. Mutoh T, Shirai T, Fujii H, Ishii T, Harigae H. Insufficient use of corticosteroids without immunosuppressants results in higher relapse rates in Takayasu arteritis. *J Rheumatol* 2020;47:255-63.
32. Schmidt J, Kermani TA, Bacani AK, et al. Diagnostic features, treatment, and outcomes of Takayasu arteritis in a US cohort of 126 patients. *Mayo Clin Proc* 2013;88:822-30.
33. Comarmond C, Biard L, Lambert M, et al. Long-term outcomes and prognostic factors of complications in Takayasu arteritis: a multicenter study of 318 patients. *Circulation* 2017;136:1114-22.
34. Schafer VS, Jin L, Schmidt WA. Imaging for diagnosis, monitoring, and outcome prediction of large vessel vasculitides. *Curr Rheumatol Rep* 2020;22:76.
35. Li J, Sun F, Chen Z, et al. The clinical characteristics of Chinese Takayasu's arteritis patients: a retrospective study of 411 patients over 24 years. *Arthritis Res Ther* 2017;19:107.
36. Pereira T, Muguruza J, Mária V, et al. Automatic methods for carotid contrast-enhanced ultrasound imaging quantification of adventitial vasa vasorum. *Ultrasound Med Biol* 2018;44:2780-92.