A Multidisciplinary Evaluation Helps Identify the Antisynthetase Syndrome in Patients Presenting as Idiopathic Interstitial Pneumonia

Sandra Chartrand, Jeffrey J. Swigris, Lina Peykova, Jonathan Chung, and Aryeh Fischer

ABSTRACT. ***Introduction.*** Interstitial lung disease (ILD) is 1 possible manifestation of the idiopathic inflammatory myopathies (IIM). Occasionally, patients presenting with ILD are mistakenly diagnosed with idiopathic interstitial pneumonia (IIP), but after multidisciplinary evaluation, their ILD is determined to be because of antisynthetase syndrome (SynS) or myositis spectrum of disease.

Methods. We used retrospective analytic methods to identify patients with ILD evaluated at the National Jewish Health between February 2008 and August 2014 and believed initially to have IIP but ultimately diagnosed with SynS or myositis spectrum of disease.

Results. The cohort included 33 patients; most were white women with a mean age at presentation of 55 years. Their pulmonary physiologic impairment was moderate. In 31 cases, the ILD pattern by thoracic high-resolution computed tomography scan was nonspecific interstitial pneumonia (NSIP), organizing pneumonia (OP), or a combination of the 2. Surgical lung biopsy was performed in 21 patients; NSIP was the most common pattern. Less than one-third of the cohort had positive antinuclear antibodies. Two-thirds had positive SSA. All patients had either myositis-specific or myositis-associated autoantibody. Most had subtle extrathoracic symptoms or signs of SynS; 12 had an elevated serum creatine phosphokinase, but none had clinical evidence of myositis. None met the Peter and Bohan classification criteria for polymyositis/dermatomyositis.

Conclusion. Among patients who present with presumed IIP, a multidisciplinary evaluation that includes the integration of clinical evaluations by rheumatologists and pulmonologists, morphologic (both histopathologic and radiographic) data, and serologic features is helpful in the detection of occult SynS or the myositis spectrum of disease. (First Release March 1 2016; J Rheumatol 2016;43:887–92; doi:10.3899/jrheum.150966)

Key Indexing Terms:

ANTISYNTHETASE SYNDROME
INTERSTITIAL LUNG DISEASE
IDIOPATHIC INFLAMMATORY MYOSITIS
IDIOPATHIC INTERSTITIAL PNEUMONIA

The idiopathic inflammatory myopathies (IIM) are a heterogeneous group of connective tissue diseases (CTD) grouped together because they share the common feature of inflammatory myopathy. Although their clinical features vary, the muscle histopathology is relatively specific, and many patients with IIM have a circulating myositis-specific or -associated antibody.

The antisynthetase syndrome (SynS) falls within the spectrum of IIM and is classically characterized by an anti-tRNA-synthetase antibody, inflammatory myopathy (myositis), nonerosive arthritis, Raynaud phenomenon, mechanic hands (fissuring of the distal lateral aspect of the fingers), sicca symptoms, recurrent fevers, and interstitial lung disease (ILD)[1]. Clinical evidence of myositis is not a sine qua non for SynS. In fact, many patients with SynS have no evidence of myositis at presentation; some will develop it, while others remain amyopathic throughout the course of their disease. Indeed, up to 50% of patients with SynS can present with ILD in the absence of clinically apparent myositis[2,3,4,5,6]. A series demonstrated that the clinical features of patients with antibody positivity for antipolymyositis-systemic sclerosis (anti-PM-Scl) or anti-tRNA-synthetase autoantibodies largely overlap, especially with regard to ILD[7], highlighting similarities with regards to SynS and patients with "myositis spectrum of disease."

Because ILD is a common manifestation of the SynS and myositis spectrum of disease, it is important to consider these diagnoses when evaluating patients presumed to have, or diagnosed with, idiopathic interstitial pneumonia (IIP)[8]. We

From the Department of Medicine, Hôpital Maisonneuve-Rosemont, Université de Montréal, Montréal, Quebec, Canada; Department of Medicine, National Jewish Health, Denver; University of Colorado School of Medicine, Aurora, Colorado; University of Chicago School of Medicine, Chicago, Illinois, USA.

S. Chartrand, MD, FRCPC, Department of Medicine, Hôpital Maisonneuve-Rosemont, Université de Montréal; J.J. Swigris, DO, MS, Department of Medicine, National Jewish Health, and the University of Colorado School of Medicine; L. Peykova, MS, Department of Medicine, National Jewish Health; J. Chung, MD, University of Chicago School of Medicine; A. Fischer, MD, University of Colorado School of Medicine.

Address correspondence to Dr. Aryeh Fischer, Department of Medicine, University of Colorado School of Medicine, 1775 Aurora Court, Box B115, Aurora CO 80045. E-mail: aryeh.fischer@ucdenver.edu

Accepted for publication January 12, 2016.

Personal non-commercial use only. The Journal of Rheumatology Copyright © 2016. All rights reserved.

Downloaded on April 19, 2024 from www.jrheum.org

describe a cohort of patients presenting with IIP who were ultimately diagnosed with SynS or myositis spectrum of disease after comprehensive, multidisciplinary evaluation.

MATERIALS AND METHODS

Cohort identification. We searched the National Jewish Health medical database to identify all patients initially referred for IIP between February 2008 and August 2014, and ultimately confirmed to have myositis spectrum of disease and/or SynS based on multidisciplinary evaluation (n = 33). Nine were described in a previous publication[9]. All clinical data were extracted from the electronic medical record.

The multidisciplinary evaluations consisted of clinical consultative encounters with pulmonary and rheumatology clinicians and discussion of each case in a weekly clinical conference with participation by thoracic radiologists, pulmonary pathologists, and pulmonary and rheumatology physicians. Serologic autoantibody testing was performed as part of a standardized clinical evaluation and included assessment of myositis-associated and -specific autoantibody panels. The myositis antibody autoantibody testing was performed at the National Jewish Health clinical laboratory using the EUROLINE myositis antibody profile 3 by Euroimmun (www.euroimmun.ch/uploads/media/DL_1530_D_UK_A03.pdf) which assesses for the presence of 5 myositis-specific, anti-tRNA-synthetase antibodies (Jo1, PL-7, PL-12, EJ, OJ), 2 other myositis-specific antibodies (Mi-2, SRP), and 3 myositis-associated antibodies (Ku, PM-Scl, Ro-52). An expert thoracic radiologist (JC) performed systematic scoring of all the initial thoracic high-resolution computed tomography (HRCT) scans done at our center. The earliest thoracic HRCT scans of diagnostic quality for ILD (as deemed by the radiologist) in the medical record were scored. Any combination of diagnoses and level of confidence was scored, including usual interstitial pneumonia (UIP), nonspecific interstitial pneumonia (NSIP), respiratory bronchiolitis-ILD, organizing pneumonia (OP), desquamative interstitial pneumonia (DIP), or hypersensitivity pneumonitis. All pattern determinations were based on current accepted criteria, definitions, and guidelines[10,11]. In addition to lung injury pattern determination, the extent of ILD, pattern distribution, and other features (subpleural sparing, ground-glass opacification, honeycombing, air-trapping, consolidation) were systematically scored. Pulmonary function was performed at our center as described[12]. Forced vital capacity (FVC) and diffusing capacity of the lung for carbon monoxide (DLCO) were expressed and analyzed as percentages of sex-, age-, and height-specific predicted values (i.e., FVC% or DLCO%, respectively).

This study was compliant with the Health Insurance Portability and Accountability Act, and approved by the National Jewish Health institutional review board (protocol HS-2917). Data are presented as counts or means with SD.

RESULTS

Clinical characteristics of the cohort. Of the 33 identified patients, 27 were considered to have SynS based on the presence of characteristic ILD pattern of disease along with specific clinical features and a positive anti-tRNA synthetase-antibody (12 Jo1, 5 PL-7, 5 PL-12, 3 EJ, 2 OJ). Six of the 33 patients were considered to have myositis spectrum of disease based on the presence of characteristic ILD pattern of disease along with specific clinical features and the presence of either a myositis-associated or -specific antibody (3 PM-Scl, 1 Ku, 2 Ro-52). No other etiology for IIP was identified. The clinical characteristics of the study cohort are displayed in Table 1. Most were never smokers (60.6%), non-Hispanic (78.8%), and women (66.7%), and the mean age at initial evaluation at our center was 54.7 ± 11.8 years.

Table 1. Characteristics of patients with antisynthetase syndrome presenting as IIP at first encounter. Values are n (%) or mean ± SD unless otherwise specified.

Characteristic	Patients with IIP, n = 33
Age at first consult, yrs	54.7 ± 11.8
Sex	
Female	22 (66.7)
Male	11 (33.3)
Ethnicity	
Non-Hispanic	26 (78.8)
Hispanic	6 (18.2)
Unknown	1 (3.0)
Race	
White	27 (81.8)
African American	1 (3.0)
Native Hawaiian or other Pacific Islander	1 (3.0)
American Native or Alaskan Native	3 (9.1)
Unknown	1 (3.0)
Tobacco status	
Never smokers	20 (60.6)
Past smokers	13 (39.4)
Current smokers	0 (0.0)
Pack-yr	15.7 ± 13.1
BMI, kg/m^2	31.0 ± 5.5
Died	1 (3.0)
Positive family history of CTD	6 (18.2)
Biopsy	21/33 (63.6)
NSIP	7 (33.3)
NSIP + OP	6 (28.6)
OP	4 (19.0)
NSIP + DAD	1 (4.8)
OP + DAD	1 (4.8)
DIP	1 (4.8)
Undetermined	1 (4.8)
Suggestive features of CTD on biopsy*, n	7/21
Other compartment involvement on biopsy**, n	2/21
PFT variables at baseline, % predicted	
FVC	54.3 ± 13.6
Forced expired volume in 1 s	56.2 ± 14.6
DLCO	39.1 ± 12.6
TLC	69.2 ± 14.5

* Includes lymphoplasmacytic infiltration, lymphoid hyperplasia with or without germinal centers, and increased perivascular collagen. ** Includes evidence of a pathologic airway process and/or pleuritis. IIP: idiopathic interstitial pneumonia; BMI: body mass index; CTD: connective tissue disease; NSIP: nonspecific interstitial pneumonia; OP: organizing pneumonia; DAD: diffuse alveolar damage; DIP: desquamative interstitial pneumonia; PFT: pulmonary function testing; FVC: forced vital capacity; TLC: total lung capacity.

Percent predicted FVC and percent predicted DLCO were reduced (54.3 ± 13.6% and 39.1 ± 12.6%, respectively).

ILD morphologic features. Based on thoracic HRCT scans, a mixed NSIP/OP pattern was suggested in 20 patients (60.6%, 18 definite, 2 probable; Figure 1). A NSIP pattern was observed on thoracic HRCT scan in 8 patients (24.2%, 4 definite, 3 probable, 1 possible), and a definite OP was observed in 2 (6.1%) and an UIP pattern was observed in 2 (6.1%, 1 definite, 1 probable). The median estimated disease

Personal non-commercial use only. The Journal of Rheumatology Copyright © 2016. All rights reserved.

Downloaded on April 19, 2024 from www.jrheum.org

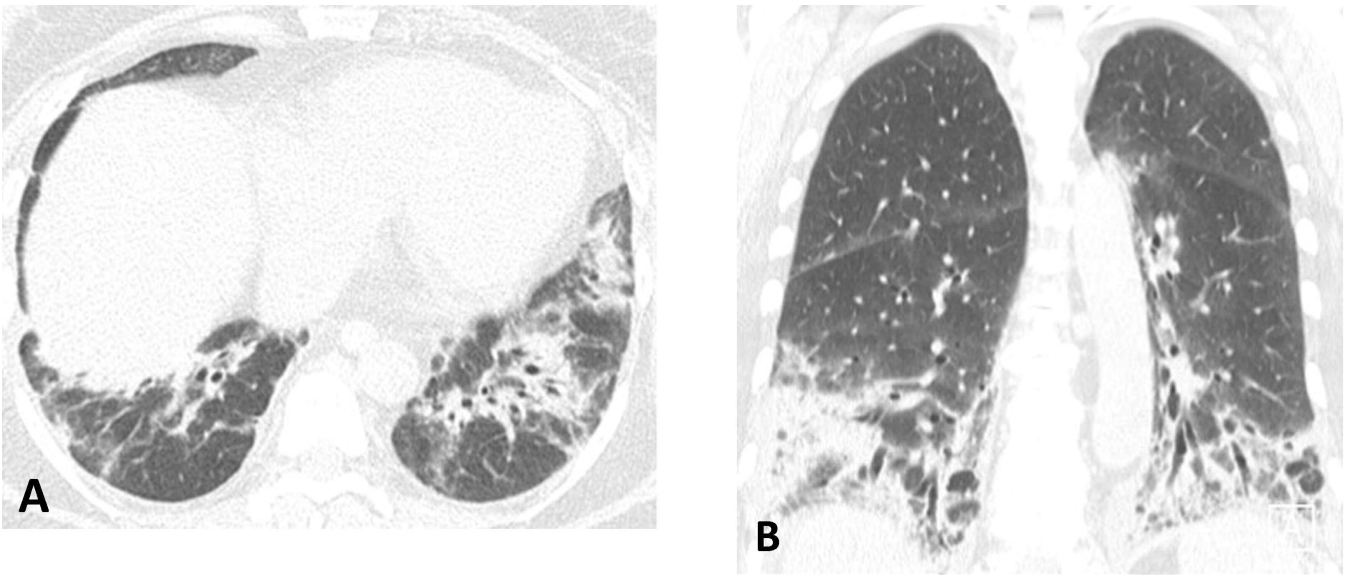

Figure 1. (A) Axial and (B) coronal images at the time of clinical presentation in this patient with antisynthetase syndrome showing basilar predominant consolidations and ground-glass opacities most consistent with combined organizing pneumonia and nonspecific interstitial pneumonia.

extent by thoracic HRCT scan was 25.0% [interquartile range (IQR) 20.0–30.0 (difference being 10.0); Table 2]. The cranio-caudal distribution on thoracic HRCT scan was almost exclusively restricted to lower lung zones (31/33, 93.9%). Ground-glass opacities were present in 29 patients (87.9%) and consolidation in 22 (66.7%).

Twenty-one patients underwent surgical lung biopsy as part of their evaluation for presumed IIP prior to evaluation at our center. NSIP was the predominant pattern identified on surgical lung biopsy (14/21, 67%; Table 1). Further, of those biopsied, 7 (33.3%) had additional histopathologic features beyond the primary pattern consistent with an underlying autoimmune phenotype [lymphoplasmacytic infiltration, lymphoid hyperplasia with or without germinal centers, increased perivascular collagen, or evidence of multicompartment lung involvement (pleuritis or inflammatory airways disease)], 5 in patients with NSIP pattern on the biopsy, 1 with combined NSIP + OP pattern on biopsy, and 1 with DIP pattern on biopsy.

Systemic autoimmune features (Table 3). Twenty-eight of the 33 patients (84.8%) had at least 1 symptom or sign of an underlying CTD at presentation. Seven (21.2%) had recurrent fevers. Cutaneous or peripheral vascular manifestations were common: Raynaud phenomenon was present in 11 (33.3%), mechanic hands in 13 (39.4%), Gottron sign in 10 (30.3%), nailfold capillary abnormalities in 5 (15.2%), and periungueal erythema in 5 (15.2%). Clinical evidence of myositis was present in the minority of cases: only 9 patients reported muscle weakness (but none had weakness on objective assessment) and 7 reported myalgias (21.3%). Creatine phosphokinase levels were elevated in 12 cases (36.4%). Electromyography was done in only 2 patients prior to their first encounter at our center (both negative for myopathic changes), and muscle biopsy was performed in only 1 patient (no abnormalities were identified). Arthritis was present in 42.4% of the cohort (14/33). Through a median followup of 934.0 days (IQR 548.0–1453.0), 5 patients developed new symptoms or signs of SynS (mechanic hands in 3 and biochemical evidence of myositis in 3).

Although less specific for CTD, a high prevalence of gastrointestinal manifestations were also found: 20 (60.6%) had symptomatic reflux, 11 (33.3%) had gastroesophageal reflux on barium contrast esophagography, and 23 (69.7%) had an abnormal esophagus (distended and/or thickened) on thoracic HRCT scan.

Antibody profiles (Table 4). All 33 patients had either a myositis-specific (n = 27) or myositis-associated (n = 6) autoantibody. Twenty-seven had a specific anti-tRNA-synthetase antibody; Jo1 was the most common one identified (n = 12) followed by PL-7 and PL-12 (5 each). Only 10 patients (30.3%) had a positive antinuclear antibody (ANA); 22 (66.7%) were either SSA-positive or Ro52-positive.

DISCUSSION

In our study, we describe a cohort of patients that presented with IIP and were ultimately confirmed to have SynS and/or myositis spectrum of disease after multidisciplinary evaluation. Most of the cohort was ANA-negative, yet two-thirds had a positive SSA or Ro52 antibody. All had positive myositis-specific or -associated antibody. Although nearly all had subtle extrathoracic features of CTD, biochemical evidence of myositis was present only in a minority of patients. No patient met the traditional Bohan and Peter classification criteria[13,14] for IIM. Our data build on

Personal non-commercial use only. The Journal of Rheumatology Copyright © 2016. All rights reserved.

Downloaded on April 19, 2024 from www.jrheum.org

Table 2. Thoracic HRCT scan scoring of patients with antisynthetase syndrome presenting as IIP at first encounter.

Variable	Patients with IIP, n = 33
Extension	
Mean ± SD, %	30.0 ± 17.8
Median, %	25.0
Max, %	75.0
Min, %	5.0
25th quartile, %	20.0
75th quartile, %	30.0
≤ 10%, n (%)	2 (6.1)
11–20%, n (%)	11 (33.3)
21–30%, n (%)	12 (36.4)
≥ 31%, n (%)	8 (24.2)
Cranio-caudal distribution, n (%)	
Upper	0 (0.0)
Mid	0 (0.0)
Lower	31 (93.9)
Diffuse	2 (6.1)
Axial distribution, n (%)	
Central	9 (27.3)
Peripheral	18 (54.5)
Diffuse	6 (18.2)
Subpleural sparing, n (%)	3 (9.1)
Features, n (%)	
Ground-glass opacities	29 (87.9)
Consolidations	22 (66.7)
Honeycombing	2 (6.1)
Air trapping	1 (3.0)
Patterns*	
Definite NSIP + OP	18 (54.5)
Probable NSIP + OP	2 (6.1)
Definite NSIP	4 (12.1)
Probable NSIP	3 (9.1)
Possible NSIP	1 (3.0)
Definite OP	2 (6.1)
Definite UIP	1 (3.0)
Possible UIP	1 (3.0)
Probable hypersensitivity pneumonitis**	1 (3.0)

* Probability (definite, probable, possible) based on the radiologist confidence. ** Based on the presence of air trapping, suggestive of a combination of parenchymal and airway processes. HRCT: high-resolution computed tomography; IIP: idiopathic interstitial pneumonia; NSIP: nonspecific interstitial pneumonia; OP: organizing pneumonia; UIP: usual interstitial pneumonia.

Table 3. Connective tissue disease symptoms and signs of patients with antisynthetase syndrome presenting as IIP at first encounter. Values are n (%).

Symptom or Sign	Patients with IIP, n = 33
At least 1, excluding symptomatic reflux	28 (84.8)
Fever	7 (21.2)
Cutaneous or peripheral vascular	
Mechanic hands	13 (39.4)
Raynaud phenomenon	11 (33.3)
Gottron papules	10 (30.3)
Nailfold capillaries abnormalities*	5 (15.2)
Periungueal erythema	5 (15.2)
Muscle	
Subjective weakness	9 (27.3)
Myalgias	7 (21.2)
Elevated CPK	12 (36.4)
Electromyography, only 2 done	0 (0.0)
Muscle biopsy, only 1 done	0 (0.0)
Arthritis	14 (42.4)
Gastrointestinal	
Swallowing trouble	2 (6.1)
Symptomatic reflux	20 (60.6)
GERD on esophagogram	11 (33.3)
Distended and/or thickened esophagus on thoracic HRCT scan	23 (69.7)
New symptoms or signs at last followup**	5/33
Fever	1 (3.0)
Mechanic hands	3 (9.1)
Increased CPK	3 (9.1)
Arthritis	1 (3.0)
Gottron papules	2 (6.0)
Swallowing trouble	1 (3.0)
Symptomatic reflux	2 (6.0)

* Either visible to the naked eye or by capillaroscopy. ** Median followup: 934.0 (interquartile range 548.0–1453.0). IIP: idiopathic interstitial pneumonia; CPK: creatine phosphokinase; GERD: gastroesophageal reflux disease; HRCT: high-resolution computed tomography.

published studies that highlight how IIM is a "spectrum" disease[2,6,15,16,17,18,19,20,21], with ILD occasionally being the most clinically apparent manifestation. Further, our study demonstrates the value, in patients who present with IIP, of a multidisciplinary evaluation that includes dedicated consultation with pulmonary and rheumatology providers and attention to clinical, serologic, radiographic, and histopathologic features.

Watanabe, *et al* retrospectively screened sera from 198 consecutive patients with IIP for 6 anti-tRNA-synthetase antibodies[15]. They found 13 (6.6%) who were positive for anti-tRNA-synthetase (EJ in 6, PL-12 in 3, and Jo1, PL-7, KS, and OJ each in 1). Arthralgias or joint deformities were found in 2 of 13 patients (15.6%), and cutaneous manifestations (Gottron or heliotrope rash) were present in 4 of 13 patients (30.8%). Extrapulmonary features of SynS were not identified in 6 of 13 patients who were positive for an anti-tRNA-synthetase antibody (46.2%).

Somewhat paradoxically, patients with IIM may present without clinically apparent myositis[2,6,16,17,18]. Muscle involvement in SynS can postdate other manifestations, especially ILD, by up to several years, and some patients remain amyopathic indefinitely[19]. In their very large retrospective series of 202 patients with SynS, Douglas, *et al* demonstrated that ILD was the first manifestation of IIM in one-quarter of their cohort. Other CTD manifestations (e.g., arthritis, Raynaud phenomenon, fever, or rash) were the presenting manifestation in some patients, but they were less frequently identified than ILD[17]. After 15 years of followup, most patients (75%) developed myositis (85.2% in Jo1-positive vs 60.0% in non-Jo1–positive).

Although we cannot be certain, we suspect that referral bias likely accounts for the relative lack of clinically apparent

Personal non-commercial use only. The Journal of Rheumatology Copyright © 2016. All rights reserved.

Downloaded on April 19, 2024 from www.jrheum.org

Table 4. Antibody profile of patients with antisynthetase syndrome presenting as IIP at first encounter. Values are n (%) unless otherwise specified.

Antibody	Patients with IIP, n = 33
Classification based on antibody profile	
Anti-Jo1	11 (33.3)
Anti-PL-7	5 (15.2)
Anti-PL-12	5 (15.2)
Anti-PM/Scl75 and/or anti-PM/Scl100	3 (9.1)
Anti-Ku	1 (3.0)
Anti-EJ	3 (9.1)
Anti-OJ	2 (6.1)
Anti-Jo1/Anti-Ku	1 (3.0)
ANA-negative but Ro52-positive	2 (6.1)
ANA positivity	10 (30.3)
ANA pattern, n	10
Speckled	2
Homogeneous	1
Nucleolar	5
Nucleolar + speckled	1
Centromere	0
Unknown	1
Anti-dsDNA positivity	0 (0.0)
Anti-Sm positivity	0 (0.0)
Anti-RNP positivity	0 (0.0)
Anti-SSA positivity	19 (57.6)
Anti-Ro52 positivity*	15 (45.5)
Either SSA-positive or Ro52-positive	22 (66.7)
Anti-SSB positivity	2 (6.1)
Anti-CCP positivity	0 (0.0)
RF positivity	4 (12.1)
Anti-Scl70, topoisomerase I, positivity	0 (0.0)

* Tested concomitantly with myositis-specific antibodies on the myositis panel. IIP: idiopathic interstitial pneumonia; anti-PM: antipolymyositis; Scl: systemic sclerosis; ANA: antinuclear antibody; anti-CCP: anticyclic citrullinated peptide antibodies; RF: rheumatoid factor.

myositis in our cohort. More specifically, our cohort consists of patients referred to a respiratory medical center and ILD specialty program for evaluation of a lung-predominant disease (i.e., IIP), not patients referred to a rheumatologist for unexplained muscle inflammatory symptoms. In another large cohort of 95 patients with SynS, myositis was present in only 60 of them (63.2%). Interestingly, it appears that antibody status may reveal something about the clinical phenotype in these patients: 69.3% of Jo1 versus only 40.0% of the non-Jo1 patients at diagnosis[19]. Also, Raynaud phenomenon (46.7% in Jo1 vs 40.0% in non-Jo1), mechanic hands (29.3% vs 30.0%), esophageal involvement (22.7% vs 20.0%), and arthritis (63.3% vs 40.0%) were frequently encountered at diagnosis. Similarly, Hervier, *et al* described 233 patients with SynS[20]. At diagnosis, myositis was present in 133 (57%), arthritis in 47 (20%), Raynaud phenomenon in 99 (42%), mechanic hands in 45 (19%), fever in 66 (28%), and cutaneous signs of dermatomyositis in 65 (28%). Finally, in a group of 31 PL-12–positive patients[21], 65% of the 28 patients with ILD first presented to an outside pulmonologist. ILD preceded the CTD diagnosis in 15 (53%), was concurrent in 8 (29%), and developed during the course of the CTD in 5 (18%). Myositis was diagnosed in 16 (52%), and it was subclinical in 5. Joint symptoms were present in 18 (58%), Raynaud phenomenon in 20 (65%), fever in 14 (45%), and mechanic hands in 5 (16%). Because of the small sample size in the cohort, we are unable to draw conclusions regarding the clinical phenotype of those with and without Jo1 antibodies.

When evaluating patients with IIP, careful attention to subtle extrathoracic clinical features is useful because they may suggest the presence of an underlying systemic autoimmune disease. Eighty-five percent of our cohort had at least 1 symptom or sign associated with CTD at presentation, including recurrent fevers, Raynaud phenomenon, mechanic hands, Gottron sign, nailfold capillary abnormalities, and periungueal erythema. Autoantibody testing can be an important component of the ILD evaluation as part of the assessment for underlying CTD as well. However, if the investigation is limited to the assessment of ANA, the myositis spectrum, and SynS in particular, may be missed. Indeed, in our cohort, a positive ANA was identified in less than one-third of the patients, and yet each patient had a myositis-specific or myositis-associated autoantibody.

Because the tRNA-synthetase proteins reside in the cytoplasm of the cell[22], and not the nucleus, detection of autoimmunity, as assessed by nuclear antibodies (i.e., the ANA), can be misleading. ANA assessment by immunofluorescence can be an important tool for detecting a cytoplasmic staining pattern that is potentially indicative of Ro-52 and/or other myositis-specific or myositis-associated antigen targets. Clinicians who wish to assess for these disorders by autoantibody testing should consider obtaining SSA, Ro52, and a more extensive panel that includes myositis-specific and myositis-associated antibodies.

Thoracic HRCT scan and findings on histopathology may also yield valuable insights into whether a CTD is present. The patterns of NSIP and/or OP should heighten suspicion for the presence of a CTD. The thoracic HRCT scan in patients with SynS-ILD most classically demonstrates NSIP with OP[23,24], as characterized by a combination of ground-glass opacities with consolidation in a peripheral, subpleural, bibasilar distribution, "pancaking" the diaphragms[9]. Although these findings are not specific for SynS, such radiographic findings should increase the level of suspicion for CTD and prompt an evaluation for myositis autoantibodies and the subtle extrathoracic manifestations of the disease. Similarly, the primary patterns of NSIP, OP, and lymphocytic interstitial pneumonia and the secondary features of interstitial lymphoid aggregates with germinal centers and diffuse lymphoplasmacytic infiltration with or without lymphoid follicles should also raise strong suspicions for underlying CTD[25].

Our study has limitations. We present data that were retro-

Personal non-commercial use only. The Journal of Rheumatology Copyright © 2016. All rights reserved.

Downloaded on April 19, 2024 from www.jrheum.org

spectively collected from a single specialized respiratory referral center and so the cohort described may not be representative of the larger SynS population. Further, because we were unable to determine the total number of patients that presented with an IIP during the time frame of our study, we cannot provide an estimate of the frequency with which patients who present with IIP are ultimately diagnosed with SynS or myositis spectrum of disease. This is an important question to be addressed through additional, prospective studies.

Our study highlights the importance of a multidisciplinary evaluation among those that present with an IIP and the integration of a combination of clinical, morphologic (both histopathologic and radiographic), and serologic features to help confirm the diagnosis of occult SynS and/or myositis spectrum of disease.

REFERENCES

1. Chatterjee S, Prayson R, Farver C. Antisynthetase syndrome: not just an inflammatory myopathy. Cleve Clin J Med 2013;80:655-66.
2. Friedman AW, Targoff IN, Arnett FC. Interstitial lung disease with autoantibodies against aminoacyl-tRNA synthetases in the absence of clinically apparent myositis. Semin Arthritis Rheum 1996;26:459-67.
3. Plastiras SC, Soliotis FC, Vlachoyiannopoulos P, Tzelepis GE. Interstitial lung disease in a patient with antisynthetase syndrome and no myositis. Clin Rheumatol 2007;26:108-11.
4. Koreeda Y, Higashimoto I, Yamamoto M, Takahashi M, Kaji K, Fujimoto M, et al. Clinical and pathological findings of interstitial lung disease patients with anti-aminoacyl-tRNA synthetase autoantibodies. Intern Med 2010;49:361-9.
5. Hervier B, Uzunhan Y, Hachulla E, Benveniste O, Nunes H, Delaval P, et al. Antisynthetase syndrome positive for anti-threonyl-tRNA synthetase (anti-PL7) antibodies. Eur Respir J 2011;37:714-7.
6. Lefèvre G, Meyer A, Launay D, Machelart I, DeBandt M, Michaud J, et al. Seronegative polyarthritis revealing antisynthetase syndrome: a multicentre study of 40 patients. Rheumatology 2015;54:927-32.
7. Lega JC, Fabien N, Reynaud Q, Durieu I, Durupt S, Dutertre M, et al. The clinical phenotype associated with myositis-specific and associated autoantibodies: a meta-analysis revisiting the so-called antisynthetase syndrome. Autoimmun Rev 2014;13:883-91.
8. Aggarwal R, Cassidy E, Fertig N, Koontz DC, Lucas M, Ascherman DP, et al. Patients with non-Jo-1 anti-tRNA-synthetase autoantibodies have worse survival than Jo-1 positive patients. Ann Rheum Dis 2014;73:227-32.
9. Fischer A, Swigris JJ, du Bois RM, Lynch DA, Downey GP, Cosgrove GP, et al. Anti-synthetase syndrome in ANA and anti-Jo-1 negative patients presenting with idiopathic interstitial pneumonia. Respir Med 2009;103:1719-24.
10. Hansell DM, Bankier AA, MacMahon H, McLoud TC, Müller NL, Remy J. Fleischner Society: glossary of terms for thoracic imaging. Radiology 2008;246:697-722.
11. Raghu G, Collard HR, Egan JJ, Martinez FJ, Behr J, Brown KK, et al; ATS/ERS/JRS/ALAT Committee on Idiopathic Pulmonary Fibrosis. An official ATS/ERS/JRS/ALAT statement: idiopathic pulmonary fibrosis: evidence-based guidelines for diagnosis and management. Am J Respir Crit Care Med 2011;183:788-824.
12. Crapo RO, Morris AH. Standardized single breath normal values for carbon monoxide diffusing capacity. Am Rev Respir Dis 1981;123:185-9.
13. Bohan A, Peter JB. Polymyositis and dermatomyositis (first of two parts). N Engl J Med 1975;292:344-7.
14. Bohan A, Peter JB. Polymyositis and dermatomyositis (second of two parts). N Engl J Med 1975;292:403-7.
15. Watanabe K, Handa T, Tanizawa K, Hosono Y, Taguchi Y, Noma S, et al. Detection of antisynthetase syndrome in patients with idiopathic interstitial pneumonias. Respir Med 2011;105:1238-47.
16. Mumm GE, McKown KM, Bell CL. Antisynthetase syndrome presenting as rheumatoid-like polyarthritis. J Clin Rheumatol 2010;16:307-12.
17. Douglas WW, Tazelaar HD, Hartman TE, Hartman RP, Decker PA, Schroeder DR, et al. Polymyositis-dermatomyositis-associated interstitial lung disease. Am J Respir Crit Care Med 2001; 164:1182-5.
18. Marie I, Josse S, Decaux O, Dominique S, Landron C, Roblot P, et al. Outcome of anti-PL12 positive patients with antisynthetase syndrome. Presse Med 2013;42:e153-8.
19. Marie I, Josse S, Decaux O, Dominique S, Diot E, Landron C, et al. Comparison of long-term outcome between anti-Jo1- and anti-PL7/PL12 positive patients with antisynthetase syndrome. Autoimmun Rev 2012;11:739-45.
20. Hervier B, Devilliers H, Stanciu R, Meyer A, Uzunhan Y, Masseau A, et al. Hierarchical cluster and survival analyses of antisynthetase syndrome: phenotype and outcome are correlated with anti-tRNA synthetase antibody specificity. Autoimmun Rev 2012;12:210-7.
21. Kalluri M, Sahn SA, Oddis CV, Gharib SL, Christopher-Stine L, Danoff SK, et al. Clinical profile of anti-PL-12 autoantibody. Cohort study and review of the literature. Chest 2009;135:1550-6.
22. Mahler M, Miller FW, Fritzler MJ. Idiopathic inflammatory myopathies and the anti-synthetase syndrome: a comprehensive review. Autoimmun Rev 2014;13:367-71.
23. Ingegnoli F, Lubatti C, Ingegnoli A, Boracchi P, Zeni S, Meroni PL. Interstitial lung disease outcomes by high-resolution computed tomography (HRCT) in Anti-Jo1 antibody-positive polymyositis patients: a single centre study and review of the literature. Autoimmun Rev 2012;11:335-40.
24. Marie I, Josse S, Hatron PY, Dominique S, Hachulla E, Janvresse A, et al. Interstitial lung disease in anti-Jo-1 patients with antisynthetase syndrome. Arthritis Care Res 2013;65:800-8.
25. Leslie KO, Trahan S, Gruden J. Pulmonary pathology of the rheumatic diseases. Semin Respir Crit Care Med 2007;28:369-78.

Personal non-commercial use only. The Journal of Rheumatology Copyright © 2016. All rights reserved.

Downloaded on April 19, 2024 from www.jrheum.org